

- COMPU. PATHOLOGY • ALLERGY TESTING
- DIGITAL WHOLE BODY X-RAYS
- DIGITAL 3D SONOGRAPHY
- DIGITAL WHOLE BODY COLOUR DOPPLER
- DIGITAL 2-D ECHO WITH COLOUR DOPPLER
- E.C.G. • LUNG FUNCTION TEST
- MAMMOGRAPHY & BONE MINERAL DENSITOMETRY

- COMPUTERISED STRESS TEST
- DENTAL
- ADVANCED DENTISTRY
- PHYSIOTHERAPY
- AUDIOMETRY & SPEECH THERAPY
- FULL BODY HEALTH CHECK-UPS
- CORPORATE HEALTH CHECKUPS



**HEALTHCARE**

MEDICAL CENTRE & DIAGNOSTICS

<b>NAME</b>	<b>MR KUSHAL RUWATIA</b>	<b>DATE</b>	<b>27.03.2022</b>
		<b>AGE</b>	<b>31 YRS</b>
<b>REF. BY DR.</b>	<b>MEDIWHEEL</b>	<b>SEX</b>	<b>MALE</b>

## X-RAY CHEST (PAVIEW).

The lungs on the either side show equal translucency.

The pleural spaces are normal.

The cardiac size is normal.

The domes of the diaphragms are normal in position, and show smooth outline.

Ribs appear normal.

### **IMPRESSION :**

**NO EVIDENCE OF PLEURAL OR PARENCHYMAL PATHOLOGY IS NOTED.**

**DR. SHRIKANT BODKE**  
(Consultant Radiologist)

Note : Investigations have their limitations. Solitary radiological investigations never confirm the final diagnosis. They only help in diagnosing the disease in correlation to clinical symptoms and other related tests. Please interpret accordingly

- BORIVALI CENTRE** 1ST FLR., YOGI AVENUE, YOGI NAGAR, BORIVALI (W), MUMBAI - 400092. • TEL.: 2899 6565 / 2899 1376 • MOB.: 90222 39301
- KANDIVALI CENTRE** MAHAVIR SURYADARSHAN SOC., SATYANAGAR RD., MAHAVIR NAGAR, KANDIVALI (W), MUMBAI - 67. • TEL.: 2868 0090 / 6522 6565 / 2869 7808 • MOB.: 90220 54458
- KANDIVALI CENTRE** SHOP NO. 44/49, EMP 71, EVERSHINE MILLENNIUM PARADISE, THAKUR VILLAGE, 120 FEET ROAD, KANDIVALI (E) MUMBAI - 400101. • TEL.: 2885 7171 / 89288 41541
- DAHISAR CENTRE** NILANGI APARTMENT, KANDERPADA JUNCTION, DAHISAR (W), MUMBAI - 400068. • TEL.: 2893 3427 • MOB.: 90220 58504
- GORAI CENTRE** VICTORY HEIGHTS, GORAI MAIN ROAD, OPP. SUVIDYA SCHOOL, BORIVALI (W), MUMBAI - 400092. • TEL.: 2869 6556 • MOB.: 90224 88354 / 72080 02565
- GOREGAON CENTRE** M.G. ROAD, NEAR JAIN MANDIR, GOREGAON (W), MUMBAI - 400062. • TEL.: 2873 3030 / 2873 3131 • MOB.: 93213 83806
- GOREGAON (EAST)** SATELLITE GARDENS, FILM CITY ROAD, NEAR SATELLITE TOWER, GOREGAON (EAST), MUMBAI - 400063 • TEL.: 79773 74838 / 79773 62922
- MIRA ROAD** UNIT NO. R13, RNA LIBERTY REST, NEAR JANGID CIRCLE, VIJAY PARK, MIRA ROAD (EAST), MUMBAI - 401107. • TEL.: 70218 04221 / 70218 27389

Website : [www.healthcarediag.com](http://www.healthcarediag.com) • E-mail : [healthcare.medicals@gmail.com](mailto:healthcare.medicals@gmail.com)

- COMPU. PATHOLOGY • ALLERGY TESTING
- DIGITAL WHOLE BODY X-RAYS
- DIGITAL 3D SONOGRAPHY
- DIGITAL WHOLE BODY COLOUR DOPPLER
- DIGITAL 2-D ECHO WITH COLOUR DOPPLER
- E.C.G. • LUNG FUNCTION TEST
- MAMMOGRAPHY & BONE MINERAL DENSITOMETRY

- COMPUTERISED STRESS TEST
- DENTAL
- ADVANCED DENTISTRY
- PHYSIOTHERAPY
- AUDIOMETRY & SPEECH THERAPY
- FULL BODY HEALTH CHECK-UPS
- CORPORATE HEALTH CHECKUPS



**Patient's Name :** MR KUSHAL RUWATIA

**Referred By Dr :** MEDIWHEEL

**Sex :** MALE **Age :** 31 Years

**Collected At :** YOGI NAGAR MAIN BRANCH

**Lab No. :** JCA8615 \*JCA8615\*

**Reg. Date :** 26-Mar-2022 9:47 am

**Report Date:** 28-Mar-2022 9:22 am

**Print Date :** 28-Mar-2022 11:25 am

### USG ABDOMEN & PELVIS ( MALE )

#### LIVER :

Liver is normal in size showing homogenous paranchymal echotexture. There is no evidence of solid or cystic mass .The portal and the hepatic venous system appears normal.

- (a) Portal vein measures 11.6 mms.  
 (b) C.B.D. measures 2.9 mms.

#### Gall bladder :

The Gall bladder is physiologically distended .The gall bladder wall of normal thickness . No evidence of gall stones.

#### PANCREAS :

Pancreas is normal in size with smooth margin.and homogenous paranchymal echotexture.No focal lesion seen.

#### KIDNEYS :

Both kidneys are normal in size and shows homogenous cortical echotexture.Central calyceal echoes appears normal.

- (a) Right kidney measures : 96 x 45 mm with hydronephrosis. hydroureter.  
 (b) Left kidney measures : 99 x 42 mm

#### SPLEEN :

The spleen is normal in size with homogenous paranchymal echotexture.No focal lesion are seen.

#### URINARY BLADDER :

Urinary bladder is minimally distended.No evidance of calculus or intraluminal mass seen in the bladder.

#### PROSTATE :

<b>DR. SHAILESH SANGALE</b> CONS. RADIOLOGIST	<b>DR. SHRIKANT BODKE</b> CONS. RADIOLOGIST	<b>DR. NIKUNJ KOTHIA</b> CONS. RADIOLOGIST	<b>DR. BHAGYA SANNANANJA</b> CONS. RADIOLOGIST
<b>KANDIVALI CENTRE</b> SHOP NO. 44/49, EMP 71, EVERSHERE MILLENNIUM PARADISE, THAKUR VILLAGE, 120 FEET ROAD, KANDIVALI (E) MUMBAI - 400101. • TEL.: 2885 7171 / 89288 41541	<b>DAHISAR CENTRE</b> NILANGI APARTMENT, KANDERPADA JUNCTION, DAHISAR (W), MUMBAI - 400068. • TEL.: 2893 3427 • MOB.: 90220 58504	<b>GORAI CENTRE</b> VICTORY HEIGHTS, GORAI MAIN ROAD, OPP. SUVIDYA SCHOOL, BORIVALI (W), MUMBAI - 400092. • TEL.: 2869 6556 • MOB.: 90224 88354 / 72080 02565	<b>GOREGAON CENTRE</b> M.G. ROAD, NEAR JAIN MANDIR, GOREGAON (W), MUMBAI - 400062. • Tel.: 2873 3030 / 2873 3131 • MOB.: 93213 83806
<b>GOREGAON (EAST)</b> SATELLITE GARDENS, FILM CITY ROAD, NEAR SATELLITE TOWER, GOREGAON (EAST), MUMBAI - 400063 • TEL.: 79773 74838 / 79773 62922	<b>MIRA ROOD</b> UNIT NO. R13, RNA LIBERTY REST, NEAR JANGID CIRCLE, VIJAY PARK, MIRA ROAD (EAST), MUMBAI - 401107. • TEL.: 70218 04221 / 70218 27389		

- COMPU. PATHOLOGY
- DIGITAL X-RAY
- DIGITAL SONOGRAPHY
- DIGITAL COLOR DOPPLER
- 2D ECHO CARDIOGRAPHY
- MAMMOGRAPHY & BONE MINERAL DENSITOMETRY ( BMD )
- ECG ■ PFT
- COMPU. TREADMILL TEST
- PHYSIOTHERAPY
- DENTAL
- HEALTH CHECK-UP



**HEALTHCARE**  
MEDICAL CENTRE & DIAGNOSTICS


MR KUSHAL RUWATIA  
EJC8615  
26-Mar-2022



# ELECTROCARDIOGRAM (ECG)

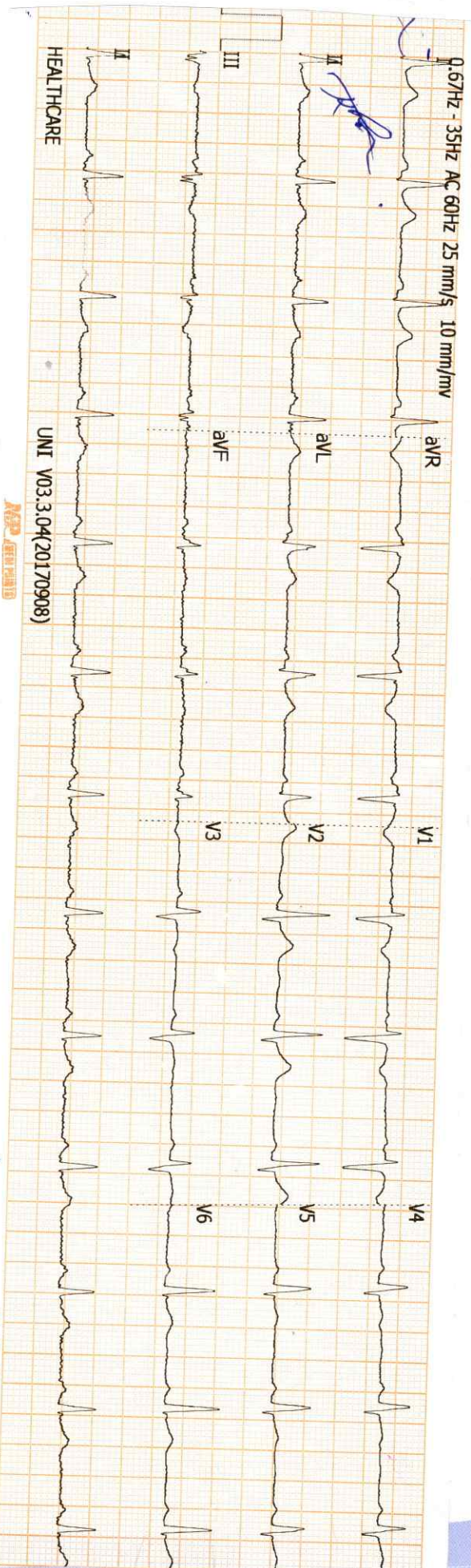
PATIENT MR. KUSHAL RUWATIA AGE 31 SEX M  
 REF. BY DR. MEDIWHEEL DATE 26/3/22

INTERPRETATION : LMC



Dr. [Signature]  
**Dr. NUPUR RAI**  
 MBBS, DIPLOMA CARDIOLOGY (PGDCC)  
 Reg. No.: 2018115643

**HEALTHCARE**  
Medical Centre And Diagnostics  
Yogi Awaraj, Mumbai-400 089  
Tel : 28986565



History : .....

B.P. : .....

Drugs : .....

Standard : .....

Auricular Rate : ..... 72 bpm

Ventricular Rate : ..... 87

Rhythm : .....

Mechanism : .....

Voltage : .....

Axis : .....

P Waves : .....

PR Interval : .....

Q Waves : ..... (2)

QRS Interval : .....

ST Segment : .....

T Waves : .....

QT Interval : .....

Extra Systoles : .....

REMARKS & CONCLUSIONS : ..... hxr