

भारत सरकार
Government of India

जुडी सोलंकी
Guddi Solanki
जन्म तिथि/DOB: 07/07/1990
महिला/ FEMALE

Download Date: 30/09/2020

Issue Date: 23/01/2017

5024

VID : 9178 0068 1181 8321

मेरा आधार, मेरी पहचान

Guddi Solanki

Dr. Nand Kishore Chhangani
MD-Physician & Cardiologist
RMC No.-2087
JODHPUR



Complete Diagnostic Solution

Name : Mrs. GUDDI SOLANKI	Visit Date & Time : 12-02-2022 4:17PM	Ref. Doctor : .
Age : 31 Year(s) Sex : Female	Reg. No. : 19825997	Ref. Lab/Hsp. : S.R. Diagnostic Centre
	LIS / LAB No. : 19825997 / 3287	
	Sample Accepted at : 12-02-2022 4:17PM	Test Authenticated at : 12-02-2022 4:58PM

HORMONES & MARKERS



Name of the Test : **Thyroid function test**

Methodology & Other Information

Method	Chemiluminescence
Type of Specimen	Serum
Instrument Used	Seimens / Beckman Access 2 / Diasorin Liaison
Reagent Kit	Seimens / Beckman / Diasorin

REPORT

Investigations	Status	Result	Biological Reference Interval
T3		1.26 ng/ml	0.60 - 1.81 ng/ml
T4		8.10 ug/dl	4.5 - 12.6
TSH		2.97 uIU/ml	Adult 0.35 - 5.50 >20 Years

*** End of Report ***

Interpretation of TSH :

Kindly correlate with age & clinical findings.

Biological reference range:

Children:

1 - 2 days	3.20 - 34.6 uIU/ml
3 - 4 days	0.70 - 15.4 uIU/ml
15 days - 5 mths	1.70 - 9.10 uIU/ml
5 mths - 20 yrs	0.70 - 6.40 uIU/ml

Pregnancy:

1 st Trimester	: 0.10 - 2.50
2 nd Trimester	: 0.20 - 3.00
3 rd Trimester	: 0.30 - 3.00

Primary malfunction of the thyroid gland may result in excessive(hyper) or low(hypo) release of T3 or T4. In additional, as TSH directly affect thyroid function,malfunction of the pituitary or the hypothalamus influences the thyroid gland activity.Disease in any portion of the thyroid-pituitary-hypothalamus system may influence the level of T3 and T4 in the blood,in Primary hypothyroidism,TSH levels are significantly elevated,while in secondary and tertiary hypothyroidism,TSH levels may be low.IN addition,In Euthyroid sick Syndrom,multiple alterations in serum thyroid function test findings have been recognized.

Authentically Scan			
	Dr. G.N. Gupta M.D. Pathology (Chief Pathologist)	Dr. Rini Bishnoi Consultant (Pathology)	Dr. Manish Dodwani Consultant (Pathology)
			Technologist

Abbreviations Meaning : H - High, L - Low, HH - Critically High, LL - Critically Low, @ - Repeat

Test(s) performed on collected sample(s) received. Please correlate with clinical findings & other related investigations. Subject to Jodhpur Jurisdiction only.

ई.सी.जी. | डिजिटल एक्सरे | टी. एम. टी. | ई. ई. जी. | ई. एम. जी | एन. सी. वी. | बेरा | पी. एफ. टी. | ऑडियोमैट्री

ब्रह्म बाग, पुष्पक कोरियर के पास, ईदगाह रोड, जालोरी गेट, जोधपुर (राज.)

फोन : 0291-2620214 E-mail : srdmedical@gmail.com

THIS REPORT IS NOT VALID FOR MEDICO LEGAL PURPOSES



Pt Name : GUDDI SOLANKI
Ref By. : Dr.
Serial No : 15383

Age : 31 Yrs.
Sex : Female
Date : 12/02/2022

URINE EXAMINATION REPORT

Test	Result(s)
PHYSICAL	
COLOUR	PALE YELLOW
APPEARANCE	CLEAR
CHEMICAL	
REACTION pH	6.0
SPECIFIC GRAVITY	1.030
ALBUMIN	NIL
SUGAR - (F)	NIL
MICROSCOPIC	
PUS CELLS	1-2 /HPF
RED BLOOD CELLS	NIL
EPITHELIAL CELLS	0-1 /HPF
CASTS	NIL
CRYSTALS	NIL
BACTERIA	NIL

[TECHNOLOGIST]

_____ END OF REPORT _____

Dr. V. A. Malhotra
MD - Pathology & Micro.
RMC No. 587
[PATHOLOGIST]

ई.सी.जी. | डिजिटल एक्सरे | टी. एम. टी. | ई. ई. जी. | ई. एम. जी. | एन. सी. वी. | बेरा | पी. एफ. टी. | ऑडियोमैट्री

ब्रह्म बाग, पुष्पक कोरियर के पास, ईदगाह रोड़, जालोरी गेट, जोधापुर (राज.)

फोन : 0291-2620214 E-mail : srdmedical@gmail.com

THIS REPORT IS NOT VALID FOR MEDICO LEGAL PURPOSES



 **SRD**
Complete Diagnostic Solution



Pt Name : GUDDI SOLANKI
Ref By. : Dr.
Serial No : 15383

Age : 31 Yrs.
Sex : Female
Date : 12/02/2022

TEST	RESULT	NORMAL RANGE
BLOOD GROUP (RH) (ABO)	O POSITIVE	

HAEMOGRAM COMPLETE

W.B.C (WHITE BLOOD CELL COUNT)	5,000	4000 - 11000 /CUMM
DLC (DIFFERENTIAL LEUCOCYTE COUNT)		
NEUTROPHILS	61.8	40 - 70 %
LYMPHOCYTES	34.0	20 - 40 %
EOSINOPHILS	2.0	00 - 06 %
MONOCYTES	2.2	00 - 10 %
BASOPHILS	00	1 %
HB (HEMOGLOBIN)	12.0	12-16 GM%
PLATELET COUNT	1.84	1.5 - 4.5 LACS/CUMM
R.B.C (RED BLOOD CELL COUNT)	5.3	3.2 - 5.5
H.C.T. (HEMATOCRIT)	36.2	34-48 %
M.C.V(MEAN CORPUSCULAR VOLUME)	81.2	80 - 100 fL
MCH (MEAN CORPUSCULAR HEMOGLOBIN)	27.15	27 - 32 pg
MCHC (MEAN CORP.Hb CONCENTRATION)	34.09	32-36 g/dl
ERYTHROCYTE SEDIMENTATION RATE	20	02-20 MM FALL 1ST HOUR.

[TECHNOLOGIST]

END OF REPORT

[PATHOLOGIST]

Dr. V. P. Malhotra
MD - Path & Micro.
RMC No.: 977

ई.सी.जी. | डिजीटल एक्सरे | टी. एम. टी. | ई. ई. जी. | ई. एम. जी. | एन. सी. वी. | बेरा | पी. एफ. टी. | ऑडियोमैट्री

ब्रह्म बाग, पुष्पक कोरियर के पास, ईदगाह रोड़, जालोरी गेट, जोधापुर (राज.)

फोन : 0291-2620214 E-mail : srdmedical@gmail.com

THIS REPORT IS NOT VALID FOR MEDICO LEGAL PURPOSES



Pt Name : GUDDI SOLANKI
Ref By. : Dr.
Serial No : 15383

Age : 31 Yrs.
Sex : Female
Date : 12/02/2022

LIVER FUNCTION TEST

Test	Result	Normal Value
S.G.O.T	34.0	0-40 U/L
S.G.P.T	33.0	0-40 U/L
S.BILIRUBIN TOTAL	0.84	0-1.2 mg/dl
S.BILIRUBIN DIRECT	0.24	0-0.3 mg/dl
S.BILIRUBIN INDIRECT	0.6	0-0.9 mg/dl
S. ALKALINE PHOSPHATASE	118.3	25-140 (adult) 37 c IU/L
S.TOTAL PROTEIN	7.10	6-8 gm/dl
S.ALBUMIN	4.03	3.7-5.3 gm/dl
GLOBULIN	3.1	2.5-3.5 gm/dl
S. A/G RATIO	1.30	1-2.3

[TECHNOLOGIST]

END OF REPORT

Dr. V.K. Malhotra
MD - Pathology
RMC No. : 977
[PATHOLOGIST]

ई.सी.जी. | डिजीटल एक्सरे | टी. एम. टी. | ई. ई. जी. | ई. एम. जी. | एन. सी. वी. | बेरा | पी. एफ. टी. | ऑडियोमैट्री

ब्रह्म बाग, पुष्पक कोरियर के पास, ईदगाह रोड, जालोरी गेट, जोधापुर (राज.)

फोन : 0291-2620214 E-mail : srdmedical@gmail.com

THIS REPORT IS NOT VALID FOR MEDICO LEGAL PURPOSES



 **SRD**
Complete Diagnostic Solution



Pt Name : GUDDI SOLANKI
Ref By. : Dr.
Serial No : 15383

Age : 31 Yrs.
Sex : Female
Date : 12/02/2022

BIO - CHEMISTRY EXAMINATION REPORT

Test	Result	Normal Value
BLOOD SUGAR - (F)	: 98.2	70-110 mg/dl
BLOOD SUGAR - (PP)	: 112.0	<140 mg/dl
BLOOD UREA (BUN)	: 18	10-20mg/dl
S.CREATININE	: 0.98	0.6-1.2 mg/dl
S.URIC ACID	: 4.8	3.5 - 7.2 mg/dl

LIPID PROFILE

S.CHOLESTEROL	: 169.2	130-250 mg/dl
S.TRIGLYCERIDES.	: 149.5	60-170 mg.dl
S.HDL CHOLESTEROL [DIRECT]	: 38.1	30-85 mg/dl
S.LDL CHOLESTEROL [DIRECT]	: 102	65-160 mg/dl
S.VLDL CHOLESTEROL	: 29	up to 35 mg/dl
CHOLESTEROL/HDL RATIO	: 4.44 :1	LESS THEN 4.5
LDL/HDL RATIO	: 2.68 :1	1.5 - 3.5


[TECHNOLOGIST]

_____ END OF REPORT _____


[PATHOLOGIST]

Dr. V.K. Malhotra
MD - Pathology
RMC No. : 97

ई.सी.जी. | डिजीटल एक्सरे | टी. एम. टी. | ई. ई. जी. | ई. एम. जी. | एन. सी. वी. | बेरा | पी. एफ. टी. | ऑडियोमैट्री

ब्रह्म बाग, पुष्पक कोरियर के पास, ईदगाह रोड, जालोरी गेट, जोधापुर (राज.)

फोन : 0291-2620214 E-mail : srdmedical@gmail.com

THIS REPORT IS NOT VALID FOR MEDICO LEGAL PURPOSES



Pt Name : GUDDI SOLANKI
Ref By. : Dr.
Serial No : 15383

Age : 31 Yrs.
Sex : Female
Date : 12/02/2022

GLYCOSYLATED HEMOGLOBIN (HbA1C)

<u>INVESTIGATION</u>	<u>RESULT</u>	<u>UNIT</u>
Glycosylated Hemoglobin (HbA1C)	5.3	%

INTERPRETATION

<u>HBA1c (%)</u>	<u>Interpretation</u>
> 8 %	Action Suggested
7-8 %	Good Control
< 7 %	Goal
6 - 7 %	Near Normal Glycemia
< 6 %	Normal Level

[TECHNOLOGIST]

_____ END OF REPORT _____

[PATHOLOGIST]

Dr. V. K. Malhotra
MD - Pathology
RMC No. : 957

ई.सी.जी. | डिजिटल एक्सरे | टी. एम. टी. | ई. ई. जी. | ई. एम. जी. | एन. सी. वी. | बेरा | पी. एफ. टी. | ऑडियोमैट्री

ब्रह्म बाग, पुष्पक कोरियर के पास, ईदगाह रोड़, जालोरी गेट, जोधापुर (राज.)

फोन : 0291-2620214 E-mail : srdmedical@gmail.com

THIS REPORT IS NOT VALID FOR MEDICO LEGAL PURPOSES



Complete Diagnostic Solution
X-RAY CHEST PA-VIEW



NAME : GUDDI SOLANKI

AGE-31Yrs

SEX : FEMALE

DATE 12-02-2022

BOTH LUNG -

PARENCHYMA.

BOTH C.P ANGLES -

NORMAL.

CARDIAC SHADOW IS WITHIN -

NORMAL LIMITS.

DOMES OF DIAPHRAGM -

NORMAL.

BONY CAGE -

NORMAL.

MEDIA STERNUM CENTRAL

/'L'/


THORACIC INLET -

NORMAL.

Complete Diagnostic Solution

IMPRESSION :-

NORMAL CHEST PA-VIEW.


DR. RAKESH GAUR (M.D)

(RADIO LOGIST) R.M.C NO. 5698

ई.सी.जी. | डिजीटल एक्सरे | टी. एम. टी. | ई. ई. जी. | ई. एम. जी | एन. सी. वी. | बेरा | पी. एफ. टी. | ऑडियोमैट्री

ब्रह्म बाग, पुष्पक कोरियर के पास, ईदगाह रोड़, जालोरी गेट, जोधापुर (राज.)

फोन : 0291-2620214 E-mail : srdmedical@gmail.com

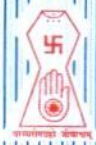THIS REPORT IS NOT VALID FOR MEDICO LEGAL PURPOSES



Amit Sonography Centre

9/10, OLYMPIC TOWER, JODHPUR - 342001
PH : 0291-2657059, 60. P.C.P.N.D.T. Reg. No. - 160

DR. SANJAY KHEMCHANDANI
MD, DNB, Consultant Radiologist
RMC Reg. No. 14919



NAME: MRS. GUDDI

AGE: 31 YRS/F

REF BY: DR. L. L. SUTHAR

DATE: February 12, 2022

R.NO: 1689

SONOGRAPHY OF ABDOMEN

LIVER:

NORMAL IN SIZE, SHAPE AND CONTOUR AND HAVING SMOOTH MARGINS. HEPATIC PARENCHYMAL ECHOTEXTURE IS NORMAL HOMOGENOUS AND UNIFORM. HEPATIC VEINS ARE NORMAL IN DISTRIBUTION AND CALIBER. NO FOCAL PARENCHYMAL LESION IS SEEN. INTRAHEPATIC BILIARY RADICLES ARE NORMAL.

PORTAL VEIN:

PORTAL VEIN IS NORMAL IN DIAMETER MEASURING - 10 mm PORTAL VEIN AND ITS RAMIFICATION IS NORMAL. NO INTRALUMINAL ECHOES ARE SEEN.

GALL BLADDER:

SEEN IN NORMAL DISTENTION. WALLS ARE SMOOTH AND NORMAL IN THICKNESS. LUMEN IS ANECHOIC.

COMMON BILE DUCT:

COMMON BILE DUCT IS NORMAL IN DIAMETER MEASURING - 04 mm. CBD IS NORMAL IN COURSE AND CALIBER. NO INTRALUMINAL MASS LESION OR CALCULI ARE SEEN.

PANCREAS:

HEAD, BODY AND TAIL ARE NORMAL IN DIMENSION AND ECHOTEXTURE. PANCREATIC DUCT IS NORMAL IN CALIBER.

SPLEEN:

NORMAL IN SIZE, SHAPE AND CONTOURS. PARENCHYMAL ECHOTEXTURE IS NORMAL. SPLENIC VEIN IS NORMAL IN COURSE AND CALIBER.

RIGHT KIDNEY:

RT. KIDNEY:- 112 X 45 mm.

RIGHT KIDNEY IS NORMAL IN SIZE, SHAPE AND CONTOUR. PARENCHYMAL ECHOTEXTURE IS NORMAL. CORTICO-MEDULLARY DIFFERENTIATION IS MAINTAINED. CENTRAL ECHO-COMPLEXES IS NORMAL.

CONT.PAGE NO. 2



NOT VALID FOR MEDICOLEGAL CASES

भ्रण लिंग परीक्षण की शिकायत
104 टोल फ्री सेवा पर की जा सकती है।





Amit Sonography Centre

9/10, OLYMPIC TOWER, JODHPUR - 342001
PH : 0291-2657059, 60. P.C.P.N.D.T. Reg. No. - 160

DR. SANJAY KHEMCHANDANI
MD, DNB, Consultant Radiologist
RMC Reg. No. 14919

::2::

LEFT KIDNEY:

LT. KIDNEY:- 118 X 49 mm.

LEFT KIDNEY IS NORMAL IN SIZE, SHAPE AND CONTOUR. PARENCHYMAL ECHOTEXTURE IS NORMAL. CORTICO-MEDULLARY DIFFERENTIATION IS MAINTAINED. CENTRAL ECHO-COMPLEXES IS NORMAL.

URINARY BLADDER:

SEEN IN FULL DISTENTION. WALLS ARE SMOOTH AND NORMAL IN THICKNESS. LUMEN IS ANECHOIC.

UTERUS:

NORMAL IN SIZE 79 X 37 X 44 mm. NORMAL ECHOTEXTURE. ENDOMETRIUM THICKENS MEASURE 13 MM.

OVARIES:

RT. OVARY:→ 31 X 17 mm.

LT. OVARY:→ 35 X 19 mm.

- BOTH THE OVARIES ARE IDENTIFIED AND THEY APPEAR NORMAL SONOLOGICALLY.
- NO FREE FLUID IS SEEN IN CUL-DE-SAC.
- NO LYMPHADENOPATHY SEEN.
- NO ASCITES SEEN.

OPINION:

U.S.G FINDINGS SUGGESTIVE OF:-

NORMAL: - LIVER, G.B, PANCREAS, SPLEEN, KIDNEYS, URINARY BLADDER & UTERUS.

ADV:- KINDLY CORRELATE WITH CLINICAL FINDINGS AND RELEVANT INVESTIGATION.
NOTE: THIS IS A RADIOLOGICAL/IMAGING OPINION AND NOT THE FINAL DIAGNOSIS.IT ONLY HELPS IN ARRIVING AT THE DIAGNOSIS. ALL FINAL DIAGNOSIS ARE TAKEN IN CORRELATION WITH DETAILS OF CLINICAL AND LAB DATA.IN CASE OF DISCREPANCY WITH IMAGING OPINION,REVIEW OF THE SAME MAY BE DONE WITH CLINICAL CORRELATION. THIS REPORT IS NOT VALID FOR MEDICO-LEGAL-PURPOSES.

DR. SANJAY KHEMCHANDANI.
M.D., D.N.B.
(CONSULTANT RADIOLOGIST)

बर्तंधारण पूर्व या बाद त्रिंभ चयन या शृण के त्रिंभ चयन या शृण के त्रिंभ का पता तबाना दम्भनीय अपराध इ
त्रिंभ परीक्षण की शिकायत 104 पर निःशुल्क दर्ज की जा सकती इ

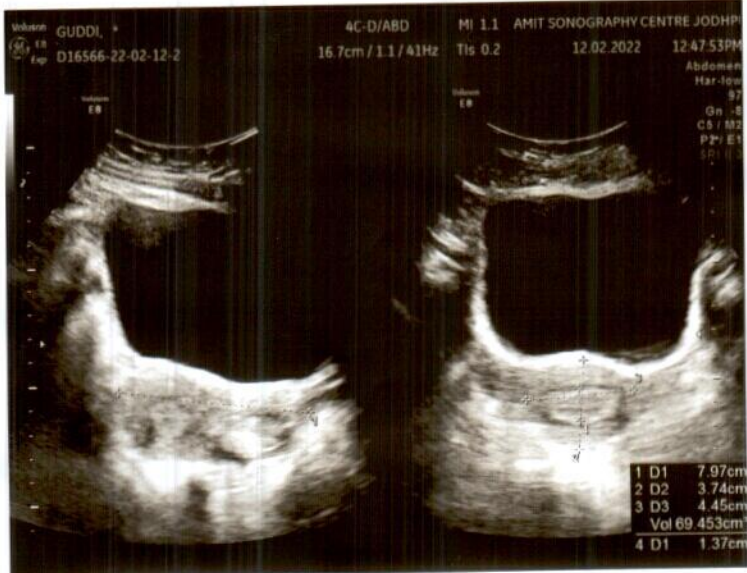
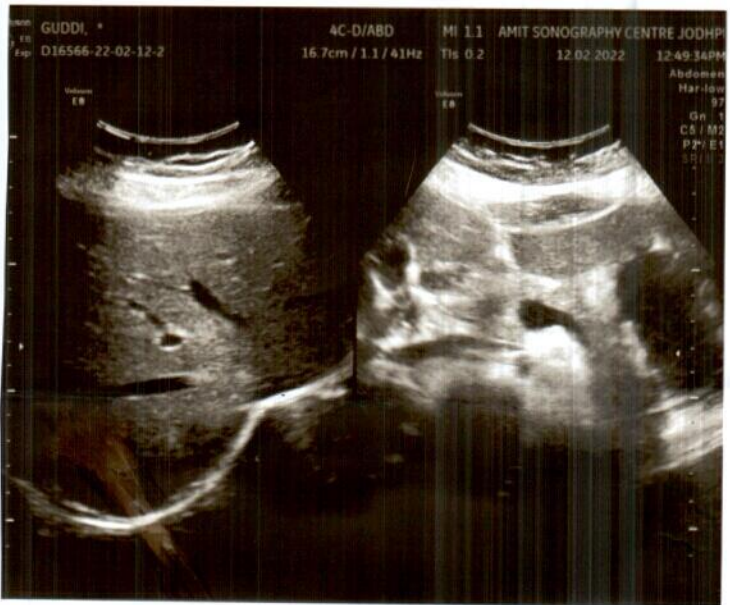
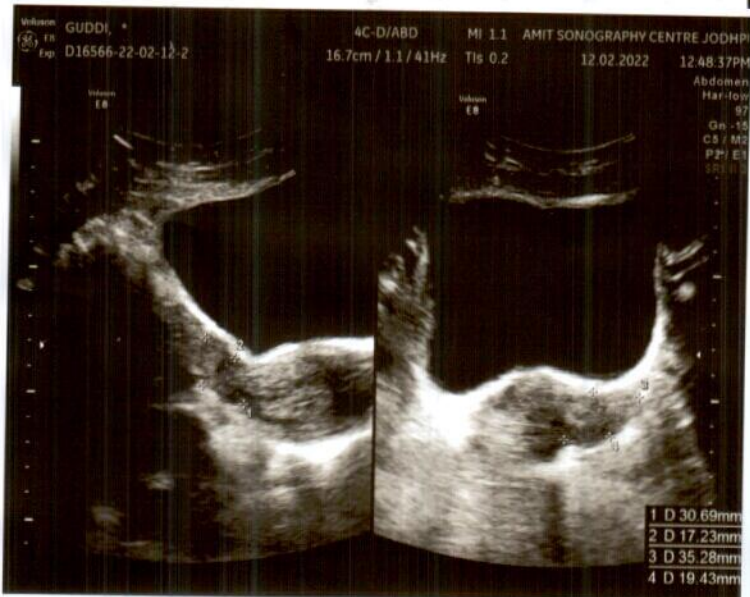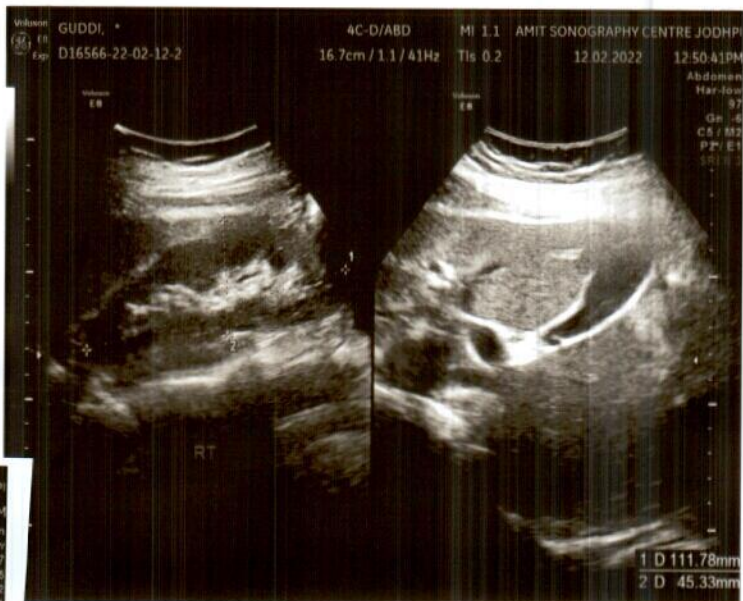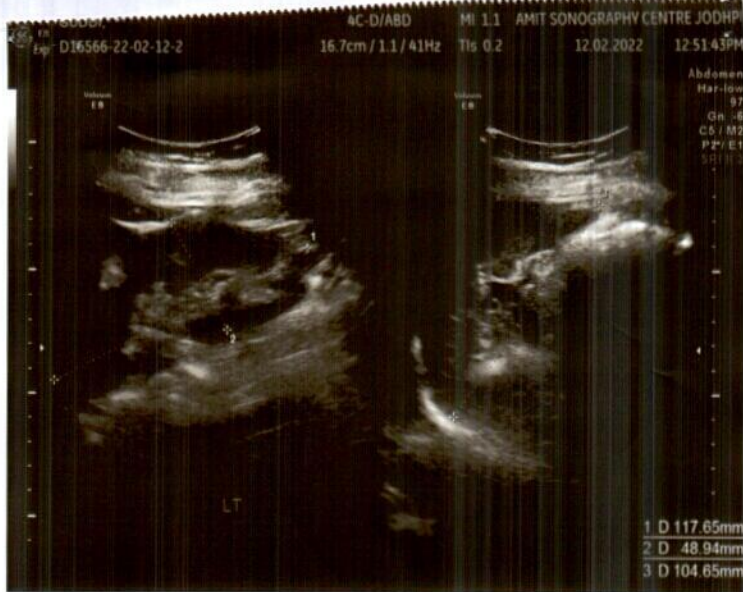Dr. SANJAY KHEMCHANDANI
M.D., D.N.B. Consultant Radiologist
Reg. No. 14919



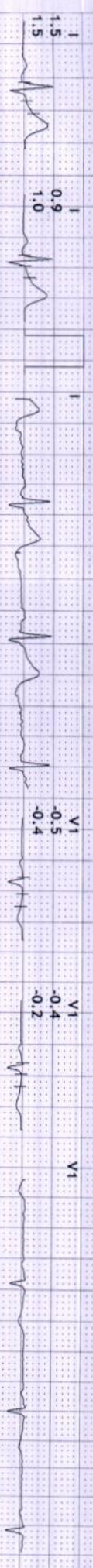
NOT VALID FOR MEDICOLEGAL CASES

भ्रण लिंग परीक्षण की शिकायत
104 टोल फ्री सेवा पर की जा सकती है।





Baseline Current 80ms Post J Current Raw Rhythm *awadi* Baseline Current Current Raw Rhythm *12/02/22*



← T wave

awadi
Dr. Nand Kishore Chhangani
 MD-Internal Medicine
 RMC No.-2087
 JODHPUR