

HEALTH CHECKUP REPORT

DATE: 26/11/2022

Patient Name: AYUSHI SHARMA
Age/Gender: 27/F
Reg. No: 390570
Package: MEDIWHEEL

COMPLAINTS (IF ANY):

- Asymptomatic

HISTORY OF HEALTH STATUS:

- Dyslipidemia

PRESENT MEDICATIONS:

- Taking ayur vedik medicine for dyslipidemia

HYPERSENSITIVITY TO ANY DRUG: No

PERSONAL HISTORY:

- Bowel : Regular
- Micturition : Normal
- Sleep : Adequate
- Appetite : Adequate

Diet : Veg
Habits : No
Physical Activity/Exercise: Activity

HISTORY OF ILLNESS (WITH PAST MEDICATIONS):

- Lmp :- 15/10/202(irregular)

FAMILY HISTORY:

- Mother – hyperthyroidism , Dyslipidemia

VITAL SIGNS:

- Height : 152 cms
- Weight : 50.6 Kgs

Pulse : 74/min
B.P: 128/80mmHg





Marengo CIMS Hospital

PHYSICIAN CONSULTATION:

1) Clinical Impression

- Primary hypothyroidism
- Polycystic ovaries

2) Recommendations

- Gynec opinion for PCOS
- Repeat TSH after 1 month
- Healthy life style

(Dr. Rashmi chovtai)

LE

6/6

(Dr. Jignesh Shah)

OPHTHALMO CONSULTATION:

RE.

Best corrected visual acuity

6/6

DENTAL CONSULTATION:

Adv:

- Cleaning

(Dr. Parvin Chandarana)

GYNEC CONSULTATION:

M/H: PMP- irregular

LMP: mid mow

Q/H: - AML -

G P2 L2 A - FTND, FTLSCS

H/O: TL

P/H: Any other surgeries -

O/E: P/A - Soft

P/S -

P/V -

Adv: USG Pelvis/TVS

Mammography

Pap Smear

Follow up with reports

(Dr. Devang patel)

Please take regular medicine as prescribed by the Doctor. (If given)

CIMS Hospital Private Limited

Plot No 67/1, Opp. Panchamrut Bungalows, Near Shukan Mall, Off Science City Road, Sola, Ahmedabad - 380015

1800 309 9999 CIN No. U85110GJ2001PTC039962

CIMS HOSP/2021/



At CIMS, we care



Patient ID 321887
Patient Name Miss AYUSHI SHARMA
Gender/Age Female/27
Ref Doctor

Dt : 26/11/2022

Rx

	Drug Name	Generic Name	Morning	Afternoon	Evening	Night	Duration
Tab.	EUTHYROX empty stomach	LEVOTHYROXIN. (25 mcg)	1	0	0	0	3 Month(s)

Dr. Rashmi Chovatia



Reg. No : CIMS/A/2022/390570	VisitNo : HQ/261122/14 [HCV]
Patient Name : Miss AYUSHI SHARMA	Age(Y-M-D)/Sex : 27 Y 1 M 20 D. /Female
Referring Doctor : Dr. CIMS DOCTOR	Doctor
Ward/Room :	Bed

ORD/261122/374 Lab No : 2022174554 LSN : 937176 (Whole Blood) Sample Quality : Normal
 Collection Time : 26/11/2022 8:58:00 Arrival : 26/11/2022 9:16:02 Validation Time : 26/11/2022 11:27:10AM

	Result	Unit	Reference Range
CBC With ESR			
TOTAL COUNT			
Hemoglobin <i>(SLS Hemoglobin Detection method)</i>	12.3	g/dl	12.5 - 16.0 g/dl
Total RBC Count <i>(Hydro Dynamic Focusing Method)</i>	4.5	mill/Cmm	4.2 - 5.4 mill/Cmm
HCT <i>(Hydro Dynamic Focusing Method)</i>	37.8	%	37 - 47 %
Total WBC Count <i>(Flow Cytometry)</i>	6980	/Cmm	4000 - 10500 /Cmm
Platelet Count <i>(Hydro Dynamic Focusing Method)</i>	264000	/Cmm	150000 - 450000 /Cmm

DIFFERENTIAL COUNT (by Flow Cytometry)

Polymorphs	45	%	40 - 70 %
Lymphocytes	47	%	22 - 45 %
Eosinophils	03	%	01 - 04 %
Monocytes	05	%	01 - 06 %
Basophils	00	%	00 - 01 %
Immature Granulocytes	00	%	0 - 2 %
Smear Study			

RBCs are Normochromic & Normocytic.
 Platelets are adequate in number.
 Malarial Parasites are not seen.
 No Premature cells are seen.

BLOOD INDICES (by Calculated Method)

M.C.V	84	fl	78 - 100 fl
M.C.H	27.3	pg	27 - 31 pg
M.C.H.C.	32.5	gm/dl	32 - 38 gm/dl
RDW-CV	12.3	%	11.5 - 14.0 %

ESR (Red Cell Aggregation)


After One Hour	11	mm	0 - 12 mm
----------------	----	----	-----------

Blood Group Rh

ABO	"B"
-----	-----

Dr. Manisha Shah
 MD (Path & Bact)
 Consultant Pathologist
 Reg. No. : G-15496

Dr. Jitendra Nayak
 MD (Path)
 Consultant Pathologist
 Reg. No. : G-14786



Dr. Shreya Patel
 MD(Path)
 Consultant Pathologist



CIMS Hospital Private Limited

Plot No 67/1, Opp. Panchanrut Bunglows, Near Shukan Mail, Off Science City Road, Sola, Ahmedabad - 380060, Gujarat

© 1800 309 9999 CIN No. U83106GJ2007P LC039962

Print By : ankita rainut

Reg. No : CIMS/A/2022/390570	Visit No : HC/281122/14 [HCV]
Patient Name : Miss AYUSHI SHARMA	Age(Y-M-D)/Sex : 27 Y 1 M 20 D. / Female
Referring Doctor : Dr. CIMS DOCTOR	Doctor :
Ward/Room :	Bed :

ORD/261122/374 Lab No : 2022174554 LSN : 937176 (Whole Blood) Sample Quality : Normal
 Collection Time : 26/11/2022 8:58:00 Arrival : 26/11/2022 9:16:02 Validation Time : 26/11/2022 11:27:11AM

Rh POSITIVE

**HbA1c (Glycosylated Haemoglobin)
TEST**


HbA1c (Glyoco Hb) <i>(Immuno Turbidimetric)</i>	5.65	%	4.8-5.9% Normal 5.9-7.0% Good diabetic control 7.0-10.0% Fair diabetic control >10.0% Poor diabetic control
--	------	---	--

Mean Plasma Glucose 123.7 mg/dL 80 - 140 mg/dL

*** END OF REPORT ***

Dr. Manisha Shah
MD (Path & Bact)
Consultant Pathologist
Reg. No. : G-15496

Dr. Jitendra Nayak
MD (Path)
Consultant Pathologist
Reg. No. : G-14786



Dr. Shreya Patel
MD(Path)
Consultant Pathologist




Reg. No : CIMS/A/2022/390570	Visit No : HC/261122/14 [HCV]
Patient Name : Miss AYUSHI SHARMA	Age(Y-M-D)/Sex : 27 Y 1 M 20 D. / Female
Referring Doctor : Dr. CIMS DOCTOR	Doctor :
Ward/Room :	Bed :

ORD/261122/374 Lab No : 2022174555 LSN : 937176 (SERUM) Sample Quality : Normal
 Collection Time : 26/11/2022 8:58:00 Arrival : 26/11/2022 9:16:02 Validation Time : 26/11/2022 11:33:05AM

Liver Function Test

	<u>Result</u>	<u>Unit</u>	<u>Reference Range</u>
Alkaline Phosphatase <i>(PNPP, AMP Buffer Method, Colorimetric)</i>	119.1	U/L	35 - 104 U/L
Bilirubin			
Total Billirubin <i>(Diazospectral Iazonium Iron with Blank)</i>	0.35	mg/dL	0.0 - 1.0 mg/dL
Direct Billirubin <i>(Diazospectral Evelyn Malloy) with Blank)</i>	0.15	mg/dL	0.0 - 0.2 mg/dL
Indirect Billirubin <i>(Calculated from Total and Direct Billirubin)</i>	0.2	mg/dL	0.0 - 0.8 mg/dL
SGPT (ALT) <i>(IFCC without pyridoxal phosphate)</i>	23.4	U/L	0 - 33 U/L
SGOT (AST) <i>(IFCC without pyridoxal phosphate)</i>	28.3	U/L	0 - 32 U/L
Total Protein			
Total Proteins <i>(Biuret Method)</i>	8.21	gm/dl	6.4 - 8.3 gm/dl
Albumin <i>(Bromocresol Green Colorimetric)</i>	5.09	gm/dl	3.97 - 4.95 gm/dl
Globulin	3.12	gm/dl	2.2 - 3.5 gm/dl
A/G Ratio	1.63		0.9 - 2.1

RECEIVED BY PATHOLOGY



Dr. Shreya Patel
MD(Path)
Consultant Pathologist



Dr. Manisha Shah
MD (Path & Bact)
Consultant Pathologist
Reg. No. : G-15496

Dr. Jitendra Nayak
MD (Path)
Consultant Pathologist
Reg. No. : G-14786

CIMS Hospital Private Limited

Reg. No : CIMS/A/2022/390570	VisitNo : HC/261122/14 [HCV]
Patient Name : Miss AYUSHI SHARMA	Age(Y-M-D)/Sex : 27 Y 1 M 20 D. / Female
Referring Doctor : Dr. CIMS DOCTOR	Doctor
Ward/Room	Bed


ORD/261122/374 Lab No : 2022174555 LSN : 937176 (SERUM) Sample Quality : Normal
 Collection Time : 26/11/2022 8:58:00 Arrival : 26/11/2022 9:16:02 Validation Time: 26/11/2022 11:33:04AM

	Result	Unit	Reference Range
Creatinine <i>(Buffered Jaffe Reaction Kinetic Compensated)</i>	0.47	mg/dL	0.5 - 0.9 mg/dL
Estimated GFR	141.92	mL/min/1.73m ²	72 - 110 mL/min/1.73m ²
Fasting Glucose <i>(Hexokinase)</i>	91.2	mg/dL	70 - 100 mg/dL
Thyroid Function Test			
TOTAL T3 (T3) * <i>(Electrochemiluminescence Assay)</i>	1.28	ng/ml	0.846 - 2.02 ng/ml
TOTAL T4 (T4) * <i>(Electrochemiluminescence Assay)</i>	7.83	µg/dl	5.13 - 14.08 µg/dl
TSH <i>(Electrochemiluminescence Assay)</i>	9.56	µIU/ml	0.27- 4.20 µIU/ml
Advice : FT3,FT4.			
Uric Acid <i>(Uricase Colorimetric Enzymatic)</i>	5.91	mg/dL	2.4 - 5.7 mg/dL

*** END OF REPORT ***

Dr. Manisha Shah
MD (Path & Bact)
Consultant Pathologist
Reg. No. : G-15496

Dr. Jitendra Nayak
MD (Path)
Consultant Pathologist
Reg. No. : G-14786



Dr. Shreya Patel
MD (Path)
Consultant Pathologist



Reg No : CIMS/A/2022/390570	Visit No : HC/261122/14 : [HCV]
Patient Name : Miss AYUSHI SHARMA	Age(Y-M-D)/Sex : 27 Y 1 M 20 D. / Female
Referring Doctor : Dr. CIMS DOCTOR	Doctor :
Ward/Room :	Bed :

ORD/261122/374 Lab No : 2022174555 LSN : 937176 (SERUM) Sample Quality : Normal
 Collection : 26/11/2022 8:58:00AM Arrival: 26/11/2022 9:22:19 Validation Time 26/11/2022 11:20:22

<u>Lipid Profile (With Direct LDL)</u>	<u>Result</u>	<u>Unit</u>	<u>Reference Range</u>
Type of Sample	: Fasting	.	
Cholesterol <i>(Enzymatic/Colorimetric, Cholesterol Oxidase, Esterase, Peroxidase Gen. 2)</i>	: 164.4	mg/dL	Less than 160 mg/dl Excellent Less than 200 mg/dl Desirable 200-239 mg/dl Borderline High 240 mg/dl & over High
glyceride <i>(Enzymatic Colorimetric without Glycerol Blank without Serum Blank)</i>	: 109.8	mg/dL	Less than 150 mg/dl Normal 150 - 199 mg/dl Borderline High 200-499 mg/dl High 500 mg/dl or greater Very High
HDL Cholesterol <i>(Direct Measure Homogenous Technique Modified Enzymatic Colorimetric Gen. 3)</i>	: 48.5	mg/dL	Less than 40 mg/dl Low 60 mg/dl or above Excellent
L D L Cholesterol (DIRECT) <i>(Homogenous Enzymatic colorimetric Assay)</i>	: 104.2	mg/dL	Less than 80 mg/dl Excellent Less than 100 mg/dl Optimal 100 - 129 mg/dl Near or above optimal 130 - 159 mg/dl Borderline High 160 - 189 mg/dl High 190 mg/dl & above Very High
VLDL Cholesterol <i>(Calculated)</i>	: 21.92	mg/dL	15 - 30 mg%
Cholesterol/HDL Ratio <i>(Calculated)</i>	: 3.39		Normal upto 4.5
LDL/HDL Ratio <i>(Calculated)</i>	: 2.15		Less than 3.5

Remarks :



Dr. Shreya Patel
MD(Path)
 Consultant Pathologist

Dr. Manisha Shah
 MD (Path & Bact)
 Consultant Pathologist
 Reg. No. : G-15496

Dr. Jitendra Nayak
 MD (Path)
 Consultant Pathologist
 Reg. No. : G-14785



Reg. No : CIMS/A/2022/390570	VisitNo : HC/261122/14 [HCV]
Patient Name : Miss AYUSHI SHARMA	Age(Y-M-D)/Sex : 27 Y 1 M 20 D. / Female
Referring Doctor : Dr. CIMS DOCTOR	Doctor
Ward/Room	Bed

ORD/261122/374 Lab No : 2022174680 LSN : 937176 (Urine) Sample Quality : Normal
 Collection Time : 26/11/2022 11:28:52 Arrival : 26/11/2022 11:28:52 Validation Time: 26/11/2022 11:58:36AM


MARENGO CIMS HOSPITAL

	Result	Unit	Reference Range
Urine R & M			
PHYSICAL EXAMINATION			
Quantity	20 cc		
Colour	Pale Yellow		
Transperancy	Clear		
Reaction	6.5		
(QDS-10 Strip)			
Sp. Gravity	1.015		1.005 - 1.035
(QDS-10 Strip)			
CHEMICAL EXAMINATION			
U. Albumin	Nil		
(QDS-10 Strip/Manual)			
U. Glucose	Nil		
(QDS-10 Strip/Manual)			
U. Acetone	Absent		
(QDS-10 Strip/Manual)			
BS/BP	Absent		
(QDS-10 Strip/Manual)			
MICROSCOPIC EXAMINATION			
Pus Cell	Occasional	/H.P.F.	/H.P.F.
Red Blood Cell	Nil	/H.P.F.	/H.P.F.
Epithelial Cell	1-2	/H.P.F.	/H.P.F.
Cast	Not Seen		
Crystals	Not Seen		
Amorphous	Absent		
Monilia	Absent		

*** END OF REPORT ***

Dr. Manisha Shah
MD (Path & Bact)
Consultant Pathologist
Reg. No. : G-15496

Dr. Jitendra Nayak
MD (Path)
Consultant Pathologist
Reg. No. : G-14786



Dr. Shreya Patel
MD(Path)
Consultant Pathologist



ID: 1091

Years

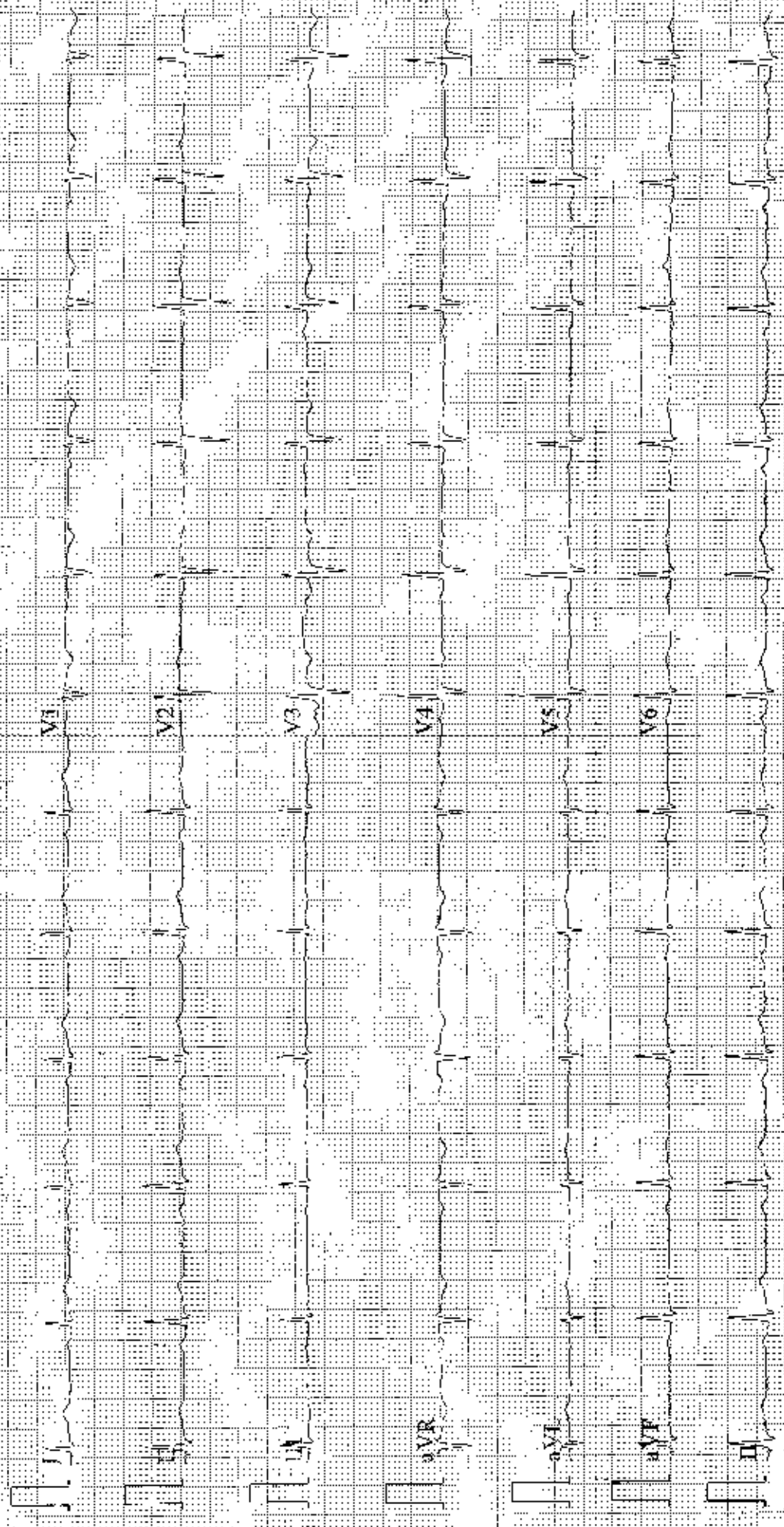
HR: 99 bpm
 P: 117 ms
 PR: 188 ms
 QRS: 90 ms
 QT/QTc: 362/389 ms
 P/QRST: 52/59/27
 RV5.SVI: 0.755/0.420 mV

Diagnosis Information

Name: Miss AYUSHI SHARMA
 Reg No: CIMS/A2022/390570
 DoB / Sex: 06/10/1995 / Female

STU T L V
 V3 V4

Report Completed by



Patient's Name : AYUSHI SHARMA	Age, Sex : 27Y/F
Reg. No. (IP/OP): HC-390570	Date : 26/11/2022
Referred By Dr. : CIMS	

USG OF ABDOMEN & PELVIS

LIVER: Liver is normal in size and echotexture. No evidence of focal SOL or dilatation of IHBR seen. Porta hepatis appear normal.

GALLBLADDER: Gallbladder appeared normal. No calculus or mass lesion seen.

PANCREAS: Visualised pancreas appeared normal in size and echotexture. No focal lesion, mass or pancreatitis.

SPLEEN: Spleen appears normal in size and echotexture.

PARAAORTIC REGION: Aorta grossly appeared normal. No paraaortic lymphnodes seen.

KIDNEYS: Both kidneys appear normal in size, shape and in position.

Cortex and collecting system of both kidneys appeared normal.

No evidence of calculus or obstructive uropathy on either side.

Right kidney: 100x35mm. Left kidney: 95x45mm.

URINARY BLADDER: Bladder appeared normal. No calculus or mass lesion is seen.

UTERUS: Uterus appears bulky and measures 85x41x58mm.

Uterus shows homogenous endometrial and myometrial echotexture.

Endometrial thickness appears normal and measures 9mm.

No fibroid or GS seen.

OVARIES: Both ovaries are enlarged and shows multiple small nondominant follicles peripherally suggesting polycystic changes

Right ovary: 41x17x31mm. Left ovary: 55x30mm and shows presence of a haemorrhagic cyst measuring 46x28x39mm.

No adnexal mass lesion seen on either side.

No evidence of free fluid or collection is seen in peritoneal spaces.

Normal small bowel peristalsis noted.

COMMENTS: Appearance suggests

- > Bulky uterus
- > Polycystic ovaries with haemorrhagic cyst in left ovary

Kindly correlate clinically.



ULTRASONOGRAPHY REPORTS ONLY

DR KIRTAN SHAH M.D. RADIOLOGIST CONS. RADIOLOGIST	DR DEEPA SHAH M.D., D.M.R.E CONS. RADIOLOGIST	DR UMA MEHTA D.M.R.D. F.R.C.R CONS. RADIOLOGIST	DR NIMISH SHARMA D.M.R.D. (D.N.B.) CONS. RADIOLOGIST	DR RAVINA CHAUHAN M.D. RADIOLOGIST CONS. RADIOLOGIST	DR YASH PATEL M.D., D.N.B. CONS. RADIOLOGIST	DR SUNALI DESAI MD, DNB, DII, FRCR CONS. RADIOLOGIST NEURORADIOLOGIST
---	---	---	--	--	--	---

Note: This is only a radiological impression and not the final diagnosis. All diagnostic modalities have their own limitations. Therefore radiological modality report should be interpreted in correlation with clinical and pathological findings.



Patient's Name : AYUSHI SHARMA
Reg. No. (IP/OP): HC-390570
Referred By Dr. : CIMS

Age, Sex : 27Y/F
Date : 26/11/2022

Plain Skiagram of Chest PA Standing View:
(Serial No-7289)

Both lung fields appear normal.

No evidence of pleural effusion or pneumothorax is seen on either side.

Mediastinal shadow appears normal.

Heart size and aorta appear normal.

Domes of diaphragm appear normal.

Bones under view appears normal.

Kindly correlate clinically.

DR KIRTAN SHAH M.D., D.M.R.E. DR DEEPA SHAH M.D., D.M.R.E. DR UMA MEHTA D.M.R.D. F.R.C.R. DR NIMISH SHARMA D.M.R.D. (D.N.B.) DR RAVINA CHAUHAN M.D. RADIOLOG. DR YASH PATEL M.D., D.M.B. DR SUNALI DESAI MD, DNB, DM, FRCR
CONS. RADIOLOGIST CONS. RADIOLOGIST CONS. RADIOLOGIST CONS. RADIOLOGIST CONS. RADIOLOGIST CONS. RADIOLOGIST CONS. RADIOLOGIST RADIOLOGIST
CONS. RADIOLOGIST RADIOLOGIST

Note: This is only a radiological impression and not the final diagnosis. All diagnostic modalities have their own limitations. Therefore radiological modality report should be interpreted in correlation with clinical and pathological findings.

FOR RADIOLOGY REPORTS ONLY

