


Hand mediwheel X



भारत सरकार
Government of India



दीपक सोलिवाल
Deepak Soliwal
जन्म तिथि/ DOB: 02/05/1993
पुरुष / MALE



4526 4599 9867

मेरा आधार, मेरी पहचान

Soliwal

DR. HARI CHHABLANI
M.B.B.S. (P) (RESPIRATORY MEDICINE) PGDHHM, PGDMLS
FELLOW INTENSIVE CARE
MMC REG. NO. - 91702

29/11

www.uidai.gov.in



help@uidai.gov.in



1947

4526 4599 9867

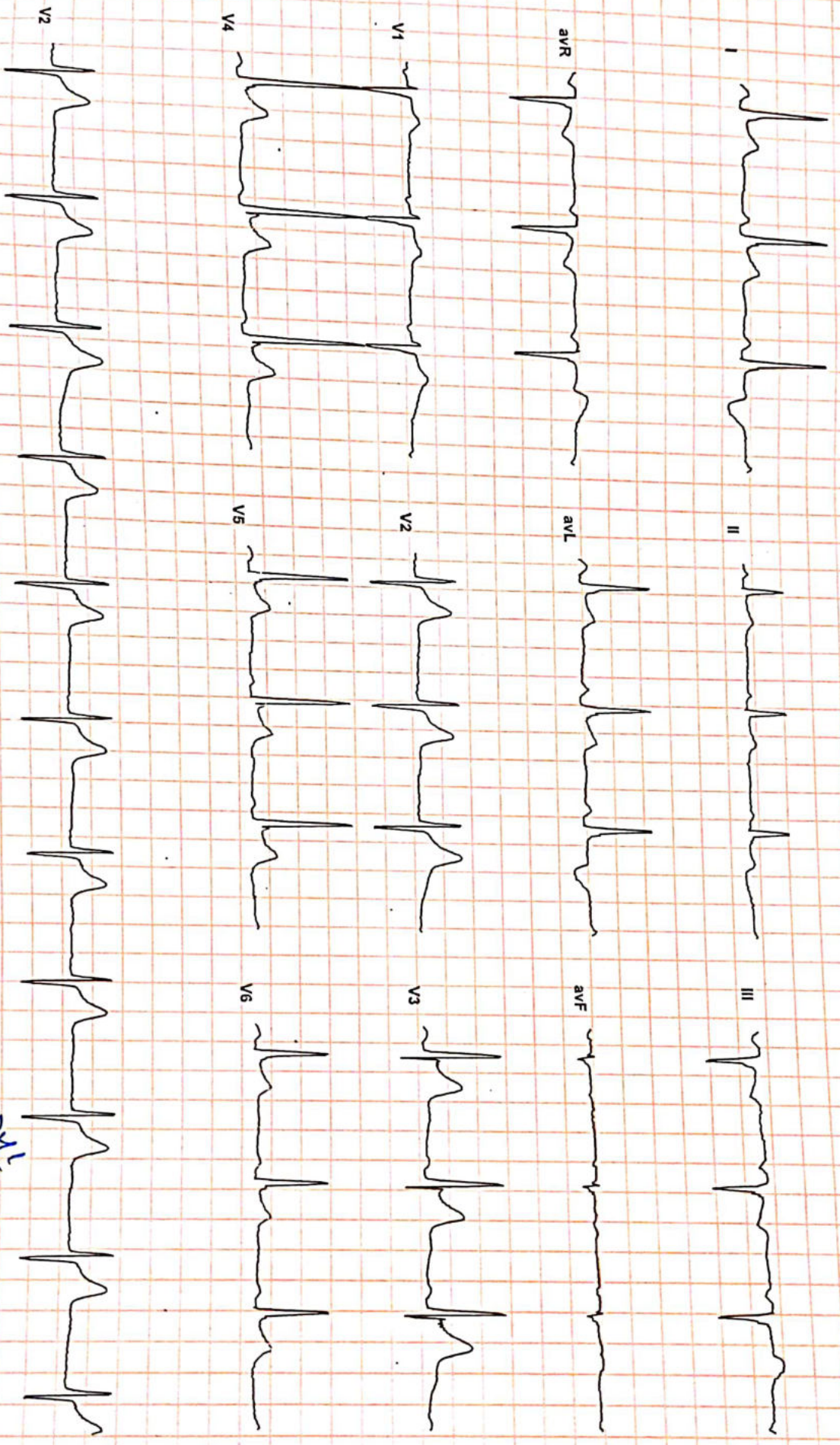
Address:
S/O Omprakash Soliwal, ward
no 03, dharam shala marg,
barotha, barotha, Barotha,
Dewas,
Madhya Pradesh - 455001

पता:
S/O ओम्प्रकाश सोलिवाल, वार्ड न
03, धर्म शाला मार्ग, बरोठा, बरोठा,
बरौठा, देवास,
मध्य प्रदेश - 455001

Unique Identification Authority of India

भारतीय पहचान प्राधिकरण





Handwritten signature

DR. PURVI CHHABLANI
Reported **MBBS, PDM, DM (Medical)**
Consultant Physician And Intensivist

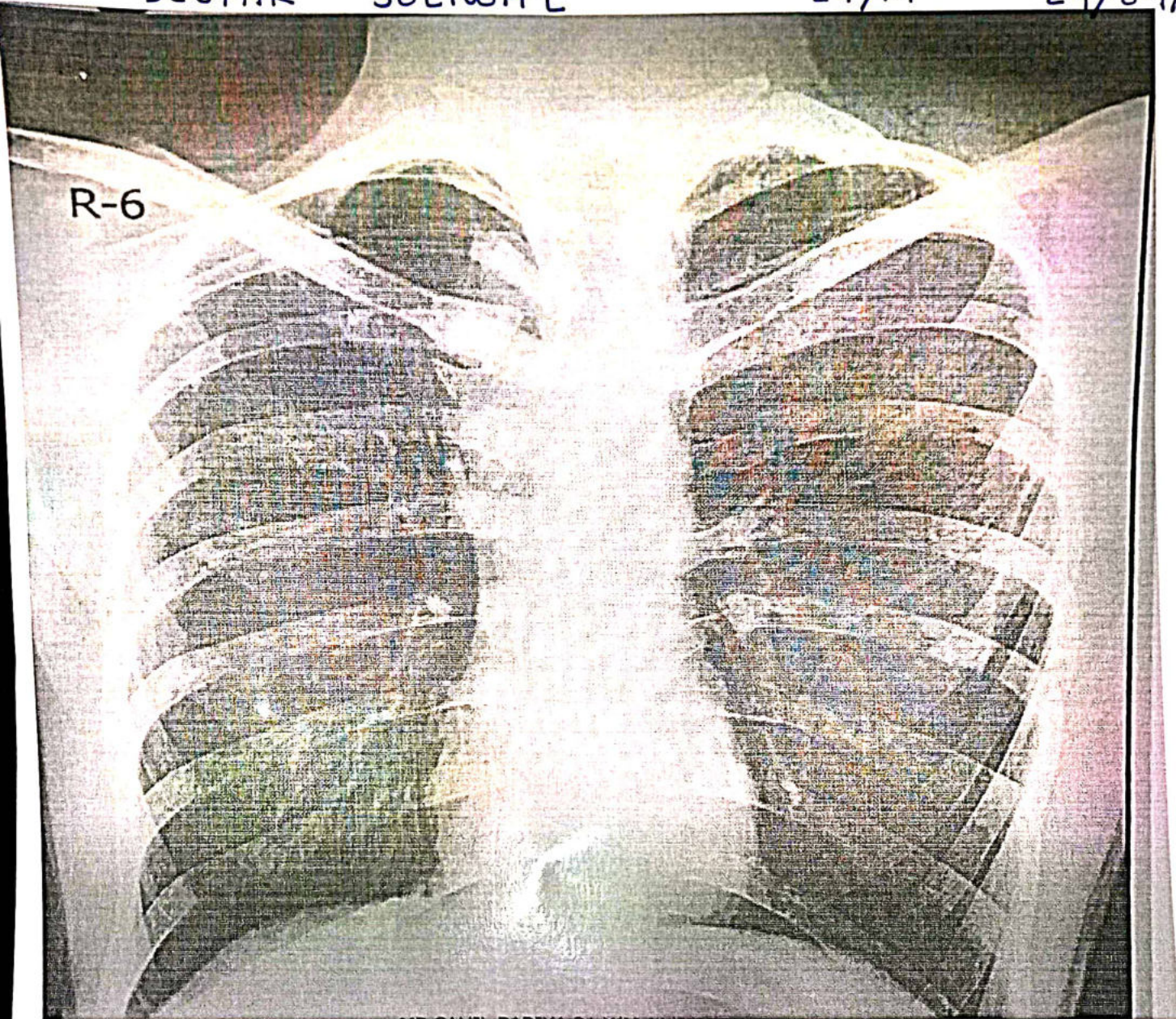
Reg No 7790F

DEEPAK SOLIWAL

29/M

24/09/22

R-6



"DR. PLUS HEALTHCARE CENTRE"
NATHANI HEIGHTS', B-WING,
42, MUMBAI CENTRAL (EAST)



Dr-Plus Healthcare Centre

NATHANI HEIGHTS, B-Wing, Shop No. 51, Ground Floor, Opp. Mumbai Central Station (East), Mumbai - 400 008.

Patient's Name : DEEPAK SOLIWAL

Referred By : SELF

Report Date : 24/09/2022

Age : 29 Years

Sex : MALE

X- RAY CHEST

BOTH THE LUNG FIELDS ARE CLEAR.

THE HILAR SHADOWS APPEAR NORMAL.

THE COSTO-PHRENIC ANGLES ARE CLEAR.

THE CARDIAC SHADOWS APPEAR NORMAL.

THE TRACHEAL IS CENTRAL IN POSITION.

THE BONY CAGE APPEARS NORMAL.

IMPRESSION : THE ABOVE EXAMINATION IS WITHIN NORMAL LIMITS.

DR. A. J. MAZUMDAR

MD. DMRE, MDRD

'DR. PLUS HEALTHCARE CENTRE'
NATHANI HEIGHTS', B-WING
42, MUMBAI CENTRAL (EAST)



Dr-Plus Healthcare Centre

NATHANI HEIGHTS, B-Wing, Shop No. 51, Ground Floor, Opp. Mumbai Central Station (East), Mumbai - 400 008.

NAME : DEEPAK SOLIWAL

29/M

DATE:24/09/2022

REF BY: SELF

2D-ECHO. AND COLOR DOPPLER REPORT

- NORMAL CARDIAC VALVES WITH TRIVIAL TR.
- NORMAL CARDIAC CHAMBERS
- NO E/O REGIONAL WALL MOTION ABNORMALITY. WITH NORMAL LVEF OF 65 %.
- NO E/O PULMONARY HYPERTENSION .PASP 28 mmHg by TR jet.
- NO E/O LEFT VENTRICULAR HYPERTROPHY.
- NO E/O DIASTOLIC DYSFUNCTION.
- NO E/O PERICARDIAL EFFUSION.
- NO E/O INTRACARDIAC CLOT OR VEGETATION
- INTACT IAS / IVS
- **CONVENTIONL DOPPLER :**
 - E TO A RATIO IS MORE THAN ONE IN LV INFLOW.
 - THERE IS NO GRADIENT ACROSS AV,LVOT OR RVOT
 - PASP FROM TR JET IS 28 mm OF Hg.
- **COLOUR DOPPLER:**
 - TRIVIAL TR

EF Slope	110	85-120 mm/sec		
Opening Amplitude	23			
Posterior leaflet				
E.P.S.S	02	mm		
Mitral valve prolapse				
Vegetations				
TRICUSPID VALVE	OBSERVED	NORMAL VALUES		
PULMONARY VALVE	OBSERVED	NORMAL VALUES		
EF Slope				
'A' Wave				
Midsystolic notch				
Flutter				
Other Findings				
AORTIC VALVE	OBSERVE	NORMAL VALUES		
Cuspal opening	17	mm		
Closure line	Central			
Eccentricity index	1			
Other Findings				
DIMENSIONS	OBSERVED	NORMAL VALUES		
1. Lvd (Diastolic)	39	26-52		
2. Lvd (Systolic)	25	24-42mm		
3. RVD (Diastolic)	17	7-23mm		
4. IVST (Diastolic)	10	6-11mm		
5. IVST (Systolic)	16			
6. LVPWT (Diastolic)	10	6-11mm		
7. LVPWT (Systolic)	16			
8. Aortic root	35	22-37mm		
9. left Atrium	31	19-40mm		
	STRUCTURE	REGURG GRADING	VELOCITY m/sec	STENOSIS GRADIENT mm/Hg
			Max mean	Peak mean
MITRAL VALVE	NORMAL	0/3	/	/
TRICUSPID VELVE	NORMAL	TRIVIAL	/	/
PULMONARY VELVE	NORMAL	0/4	/	/
AORTIV VALVE	NORMAL	0/4	/	/

PC
DR.P.H.CHHABLANI
 M.B.B.S, DNB.(MEDICINE)
 CONSULTANT PHYSICIAN AND CARDIOLOGIST.

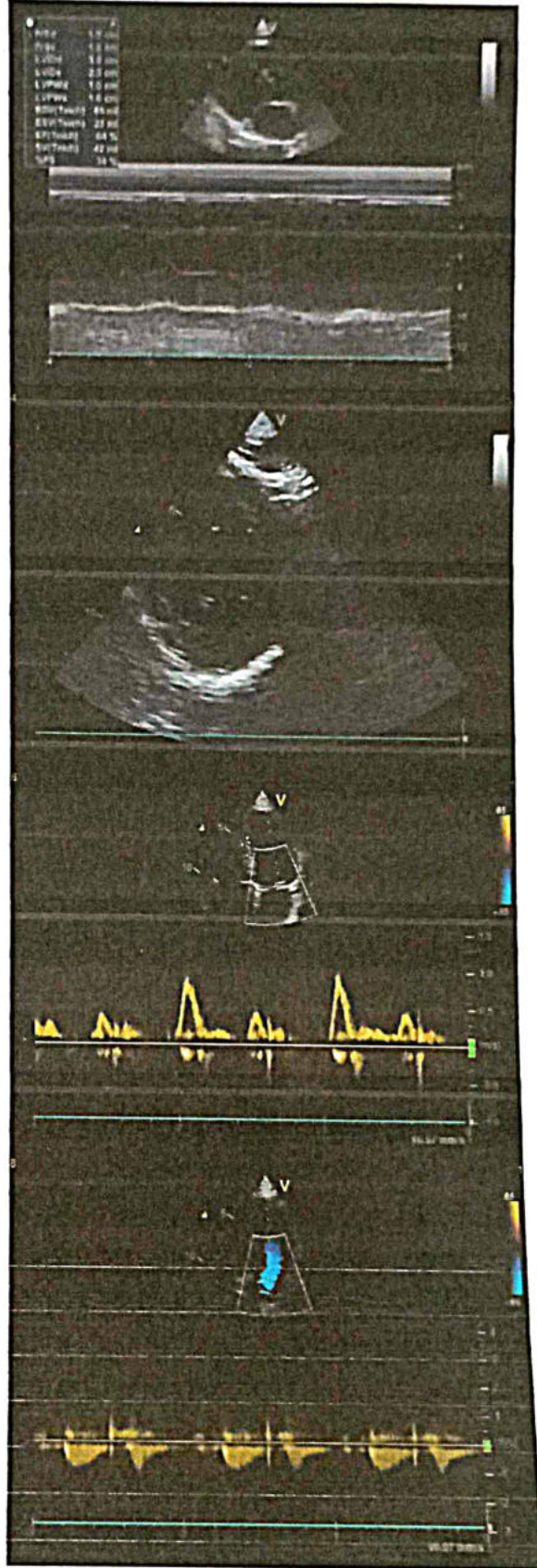
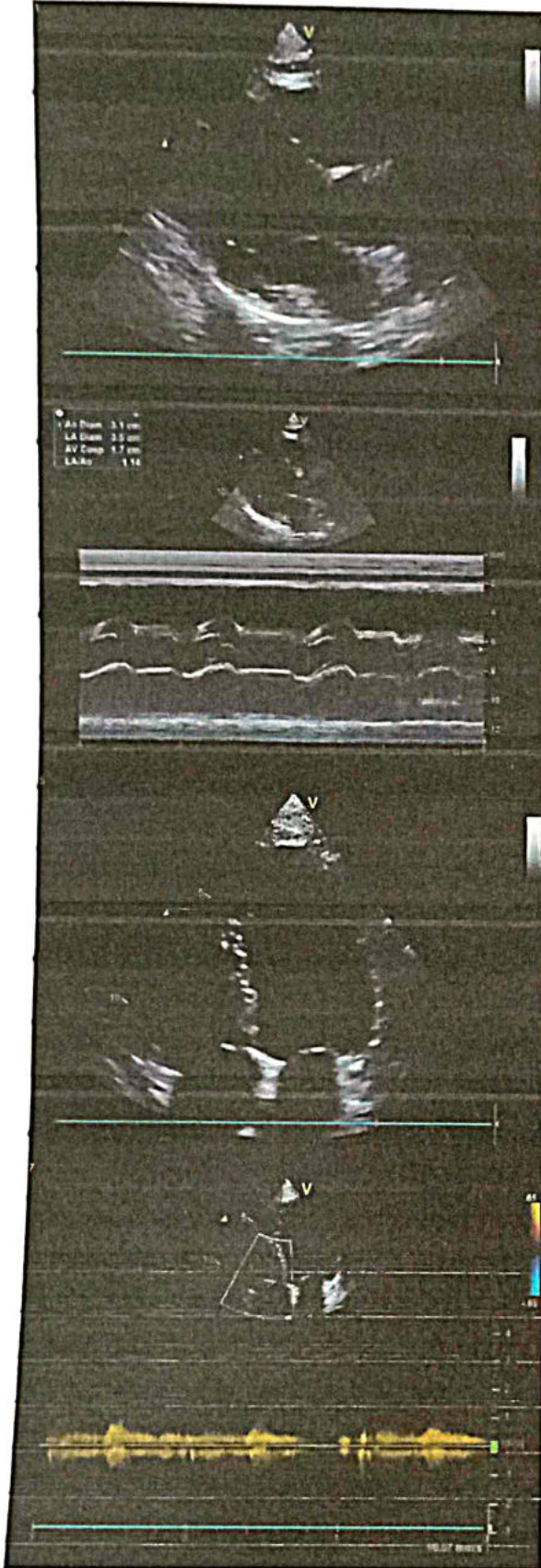
DR. PURVI CHHABLANI
 MBBS, DNB. (Medicine);
 Consultant Physician And Intensive
 Reg No 77896

Name DEEPAK SOLIWAL

Sex Male

Age 29

Date 24/09/2022





Dr-Plus Healthcare Centre

NATHANI HEIGHTS, B-Wing, Shop No. 51, Ground Floor, Opp. Mumbai Central Station (East), Mumbai - 400 008.

Full Name DEEPAK SOLIWAL 29/M 24/09/2022
Life to be assured:

HAEMOGRAM Normal Range

1.	Red Blood Cell Count	4.61	[M : 4.5 – 5.6 / F : 3.5 – 5.5/cu.mm]
2.	Hb%	15.2	[M: 14-18 / F : 11-16%]
3.	Hematocrit	45.4	[M : 40-53 / F : 30-47 %]
4.	Indices:		
(a)	MCV(Mean Corpuscular Volume)	89.7	[79-101 cu.mi.]
(b)	MCH(Mean Corpuscular Hb)	29.5	[27-32 pg]
(c)	MCHC(Mean Corpuscular Hb Concentration)	33.1	[32-38%]
5.	Morphology		
	Macrocytes :	--	Microcytes: -- Hypochromia: --
	Poikilocytosis:	--	Anisocytosis: --
6.	Target cells:	--	
	Spherocytes:	--	Elliptocytes: --
7.	TOTALW.B.C.Count	6,200	{4000-1100/cu.mm}
Differential Count			
a)	Neutrophils :	62	[45 -70%] c) Eosinophils: 04 [01 - 06%]
b)	Lymphocytes :	29	[20 - 45%] d) Monocytes: 05 [00 - 08%]
e)	Basophils :	00	[00 - 01%]
8.	Platelets :2.82	1.5-4.5 Lacks/cu.mm	
9.	Erythrocyte Sedimentation Rate:-12	20 mm at end of 1 hour	Method : Westergrens

ROUTINE URINE EXAMINATION (RUA)

1. Physical Examination:

(i)	Colour :	YELLOW	(ii)	Sediment:	CLEAR
(iii)	Transparency:	CLEAR	(iv)	Reaction:	ACIDIC
(v)	Specific gravity	1.010			

2. Chemical Examination:

(i)	Protein :	NIL	(ii)	Sugar:	NIL
(iii)	Bile salt:	NIL	(iv)	Bile pigment:	NIL

3. Microscopic Examination:

(i)	Red Blood Cells:	ABSENT	(ii)	Epithelial Cells:	2 TO 3/ HPF
(iii)	Crystals:	ABSENT	(iv)	Pus Cells:	2 TO 3/HPF
(v)	Casts:	ABSENT	(vi)	Deposits:	ABSENT
(vii)	Bacteria's :	ABSENT			

DR. RAKESH PATKAR
M.D., D.N.B. (Pathology)
2019/1880



Dr-Plus Healthcare Centre

NATHANI HEIGHTS, B-Wing, Shop No. 51, Ground Floor, Opp. Mumbai Central Station (East), Mumbai - 400 008.

Full Name
Life to be assured:

DEEPAK SOLIWAL

29/M

24/09/2022

	Type of Test	Actual Reading	Normal Range
1	Fasting Blood Sugar	89.6	70-100 mg%
2	PPBS	110.6	110 TO 140 mg%
3	Total Cholesterol	168.2	120-200 mg%
4	VERY LOW DENSINTY LEVEL(VLDL)	23.2	10-30 mg/dl
5	High Density Lipid (HDL)	46.9	40-60 mg%
6	Low Density Lipid (LDL)	98.1	Upto 150
7	S. Triglycerides	128.3	50-150 mg%
8	CHOL/HDL	3.5	Upto 5
9	HDL/LDL	0.4	
10	S. Creatinine	0.7	0.5-1.2 mg%
11	Blood Urea Nitrogen (BUN)	14.5	7-21 mg%
12	BUN/CREAT RATIO	20.7	
13	S. Proteins	6.8	6.0-7.9 mg%
14	(a) Albumin	4.5	3.5-5.5 mg%
15	(b) Globulin	2.3	2.0-3.5 mg%
16	A/G RATIO	1.9	
17	S. Bilirubin	1.0	0.3-1.3mg%
18	(a) Direct	0.7	0.0-0.8 mg%
19	(b) Indirect	0.3	0.0-0.5 mg%
20	SGOT (AST)	26.2	05-34 IU
21	SGPT (ALT)	32.4	05-40 IU
22	GGTP (GGT)	41.2	05-50 IU
23	SGOT/SGPT	0.8	
24	HBA1C	5.6	UPTO 6.5
25	S. Alkaline Phosphatase	95.1	30-115 IU
26	T3	108.8	80-180ng/dl
27	T4	6.6	4.6-12 ug/dl
28	TSH	2.8	0.4-4.0 mIU/L
29	SERUM URIC ACID	5.6	2.5-7.2mg/dl
30	URINE SUGAR PP	ABSENT	
31	URINE SUGAR FASTING	ABSENT	
32	BLOOD GROUP	"B POSITIVE "	

DR. AKESH PATKAR
M.D., D.P.L. (Pathology)
Reg. No. 2013/05/1800



Dr. Hari Chhablani

Cardiometabolic Physician & Intensivist
M.B.B.S., F.C.C.P. (RESP. MED.), PGDHMM,
PGDMLS, FELLOW INTENSIVE CARE MED.

ATTACHED TO : Wockhardt Hospital • Saifee Hospital • Apollo Spectra Hospital

NATHANI HEIGHTS, B-Wing, Shop No. 42, Ground Floor, Opp. Mumbai Central Station (East),
Mumbai - 400 008. • Cell : 98206 46163 • E : drharichhablani@gmail.com

PHYSICIAN REPORT

DATE : 24/09/2022

NAME : DEEPAK SOLIWAL 29/M

PRESENTING COMPLAINS : NIL.

PAST HISTORY : H/O RT. RENAL CALCULI - AUG. 2022 .

FAMILY HISTORY: NOT SIGNIFICANT.

TREATMENT : NIL

HABITS: SMOKING +,ALCOHOL+

HT.- 173 CM. WT.- 75 Kg. BMI.-25

P: 64/MIN ., REGULAR BP: 110/70

EYE EXAMINATION : NEAR VISION -B/E- N6 , DISTANT VISION -B/E -6/6 COLOR VISION : NORMAL

RS: CLEAR

CVS: S1,S2 REGULAR

PA: SOFT

CNS: CLINICALLY NAD

ENT EXAMINATION : WNL

LABS: ATTACHED

2-D- ECHO : ATTACHED

ECG: ATTACHED

X-RAY : ATTACHED

ADVICE : : SONO KUB .


DR. HARICHHABLANI
M.B.B.S., F.C.C.P. (RESP. MEDICINE) PGDHMM, PGDMLS
FELLOW INTENSIVE CARE
MMG REG. NO. - 91702



Mumbai, Maharashtra, India

Shop No 65, Nathani Heights, Marzban Parsi Colony, Dalal Estate, Mumbai Central, Mumbai, Maharashtra 400008, India

Lat 18.968783°

Long 72.819975°

24/09/22 11:30 AM GMT +05:30

