

# DR. NETRAVALKAR'S ASHWINI PATHOLOGY LABORATORY

(For all Investigation in Histopathology, Cytopathology, Haematology, Clinical Pathology, Microbiology & Hormonal Chemistry)

Consultant Pathologist **Dr. Prasad Netravalkar** MBBS, MD. (Path) BOM

(HOME COLLECTION FACILITY AVAILABLE)

**Panaji** : 1st, Floor, Rizvi Sadan, Above Saroj Emporium, Near Inox Theatre, Opp. Municipal Market, Panaji.

Ph.: 2229142, 8407912840, 8390242524

E-mail: ashwinilabpanaji@gmail.com, drprasadnetravalkar@gmail.com

**Mapusa** : F8, Ramchandra Chambers, 1st Floor, Mapusa Clinic Road, Mapusa - Bardez, Goa. Ph.: 2252320, 2250709

**Sanquelim** : 1st floor, Shanta Commercial Complex, Sanquelim - Goa. Ph.: 2364524, 9119574524

Pt.No. : 45 270224

Pt.Name : Mr. Madhukar Belpatre Rao

Age : 59 Yrs. Sex : M

Ref. By : -

Date : 27-02-2024

## Normal Range

### COMPLETE HEMOGRAM


Haemoglobin	: 14.4	g/dl	13.5 - 18 g/dl
W.B.C Count	: 7700	cells/ cu-mm	4000 - 11000 cells/ cu-mm
R.B.C Count	: 4.71	millions / cu-mm	4.5 - 6.5 millions / cu-mm
MCV	: 83.8	fl	80 - 96 fl
MCH	: 30.6	Pg	27 - 33 Pg
MCHC	: 36.6	%	32 - 37 %
PCV	: 39.5	%	40 - 54 %
Platelet Count	: 3.14	lakhs /cu mm	1.5 - 4.5 lakhs /cu mm
E.S.R (Westergren)	: 10	mm/hr	0 - 20 mm/hr

### DIFFERENTIAL COUNT

Stab Cells	: 04	%	1-5 %
Neutrophils	: 57	%	40 - 60 %
Lymphocytes	: 30	%	20 - 45 %
Eosinophils	: 02	%	1 - 6 %
Monocytes	: 07	%	0 - 10 %
Basophils	: 00	%	0 - 1 %
Abnormal Cells	: Nil		

### SMEAR EXAMINATION

RBC Morphology	: Normocytic , Normochromic
W.B.C Morphology	: Within Normal Limits
Platelets on Smear	: Adequate
Parasites	: Absent
Blood Group	: 'O' Rh Positive



Pathologist

**Dr. Prasad Netravalkar**  
MBBS, MD (Bom)  
GMC Reg. No. 1294

*We Care*

*All Diagnostic facilities under one roof in Panaji centre - Lab. ultrasound, X ray, ECG, TMT, ECHO*

# DR. NETRAVALKAR'S ASHWINI PATHOLOGY LABORATORY

(For all Investigation in Histopathology, Cytopathology, Haematology, Clinical Pathology, Microbiology & Hormonal Chemistry)

Consultant Pathologist **Dr. Prasad Netravalkar** MBBS, MD (Path) BOM

(HOME COLLECTION FACILITY AVAILABLE)

**Panaji** : 1st. Floor, Rizvi Sadan, Above Saroj Emporium, Near Inox Theatre, Opp. Municipal Market, Panaji.  
Ph.: 2229142, 8407912840, 8390242524

E-mail: ashwinilabpanaji@gmail.com, drprasadnetravalkar@gmail.com

**Mapusa** : F8, Ramchandra Chambers, 1st Floor, Mapusa Clinic Road, Mapusa - Bardez, Goa. Ph.: 2252320, 2250709

**Sanquelim** : 1st floor, Shanta Commercial Complex, Sanquelim - Goa. Ph.: 2364524, 9119574524

Pt.No. : 45 270224

Pt.Name : Mr. Madhukar Belpatre Rao

Age : 59 Yrs. Sex : M

Ref. By : -

Date : 27-02-2024

		Normal Range
Fasting Blood Sugar	: 161.0 mg/dl	70 - 110 mg/dl
2 Hrs. Blood Sugar	: 128.0 mg/dl	110 - 140 mg/dl

## GLYCOSYLATED HAEMOGLOBIN IN BLOOD ( HPLC METHOD )

HbA1C : 8.30 %

Mean Blood Glucose : 192 mg %

INTERPRETATION:

HbA1c %

NORMAL

Below 6.5 %

GOOD DIABETIC CONTROL

6.5 % - 7.5 %

FAIR CONTROL

7.5 % - 8.0 %

UNSATISFACTORY CONTROL

8.0 % - 10.0 %

POOR CONTROL

Above 10.0 %



Pathologist

**Dr. Prasad Netravalkar**

MBBS, MD (Bom)

GMC Reg. No. 1294

*We Care*

*All Diagnostic facilities under one roof in Panaji centre - Lab, ultrasound, X ray, ECG, TMT, Echo*

# DR. NETRAVALKAR'S ASHWINI PATHOLOGY LABORATORY

(For all Investigation in Histopathology, Cytopathology, Haematology, Clinical Pathology, Microbiology & Hormonal Chemistry)

Consultant Pathologist: **Dr. Prasad Netravalkar** MBBS, MD (Path) BOM

(HOME COLLECTION FACILITY AVAILABLE)

**Panaji** : 1st, Floor, Rizvi Sadan, Above Saroj Emporium, Near Inox Theatre, Opp. Municipal Market, Panaji.  
Ph.: 2229142, 8407912840, 8390242524

E-mail: ashwinilabpanaji@gmail.com, drprasadnetravalkar@gmail.com

**Mapusa** : F8, Ramchandra Chambers, 1st Floor, Mapusa Clinic Road, Mapusa - Bardez, Goa. Ph.: 2252320, 2250709

**Sanquelim** : 1st floor, Shanta Commercial Complex, Sanquelim - Goa. Ph.: 2364524, 9119574524

Pt.No. : 45 270224

Pt.Name : Mr. Madhukar Belpatre Rao

Age : 59 Yrs. Sex : M


Ref. By : -

Date : 27-02-2024

Normal Range

## LIPID PROFILE

Total Cholesterol	: 144.0 mg/dl	130 - 220 mg/dl
S. Triglycerides	: 89.0 mg/dl	35 - 170 mg/dl
HDL Cholesterol	: 37.0 mg/dl	> 35 mg/dl
LDL Cholesterol	: 89 mg/dl	< 130 mg/dl
VLDL Cholesterol	: 18 mg/dl	Upto 35 mg/dl
TC/HDLC Ratio	: 3.9	< 4.5
LDLC/HDLC Ratio	: 2.4	2.5 - 3.5



  
Pathologist

**Dr. Prasad Netravalkar**  
MBBS, MD (Bom)  
GMC Reg. No. 1294

*We Care*

*All Diagnostic facilities under one roof in Panaji centre - Lab. ultrasound, X ray, ECG, TMT, ECHO*

# DR. NETRAVALKAR'S ASHWINI PATHOLOGY LABORATORY

(For all Investigation in Histopathology, Cytopathology, Haematology, Clinical Pathology, Microbiology & Hormonal Chemistry)

Consultant Pathologist : **Dr. Prasad Netravalkar** MBBS, MD. (Path) BOM

(HOME COLLECTION FACILITY AVAILABLE)

**Panaji** : 1st, Floor, Rizvi Sadan, Above Saroj Emporium, Near Inox Theatre, Opp. Municipal Market, Panaji.  
Ph.: 2229142, 8407912840, 8390242524

E-mail: ashwinilabpanaji@gmail.com, drprasadnetravalkar@gmail.com

**Mapusa** : F8, Ramchandra Chambers, 1st Floor, Mapusa Clinic Road, Mapusa - Bardez, Goa. Ph.: 2252320, 2250709

**Sanquelim** : 1st floor, Shanta Commercial Complex, Sanquelim - Goa. Ph.: 2364524, 9119574524

Pt.No. : 45 270224

Pt.Name : Mr. Madhukar Belpatre Rao

Age : 59 Yrs. Sex : M

Ref. By : -

Date : 27-02-2024

Normal Range

## LIVER FUNCTION TEST

S. Bilirubin (Total)	: 0.70 mg/dl	0 - 1 mg/dl
S. Bilirubin (Direct)	: 0.20 mg/dl	0 - 0.25 mg/dl
S. Bilirubin (Indirect)	: 0.5 mg/dl	0 - 0.75 mg/dl
S.G.O.T	: 22.0 U/L	0 - 42 U/L
S.G.P.T	: 17.0 U/L	0 - 42 U/L
S. Alkaline Phosphatase	: 100.0 IU/L	15 - 112 IU/L
GGTP	: 20.0 U/L	11-43 U/L
Total Proteins	: 6.85 g/dl	6.0 - 10.0 g/dl
S. Albumin	: 4.10 gm%	3.2 - 5.5 gm%
S. Globulin	: 2.8 g/dl	2.3 - 3.5 g/dl
A/G Ratio	: 1.5 : 1	



  
Pathologist

**Dr. Prasad Netravalkar**  
MBBS, MD (Bom)  
GMC Reg. No. 1294

*We Care*

*All Diagnostic facilities under one roof in Panaji centre - Lab. ultrasound, X ray, ECG, TMT, ECHO*

# DR. NETRAVALKAR'S ASHWINI PATHOLOGY LABORATORY

(For all investigation in Histopathology, Cytopathology, Haematology, Clinical Pathology, Microbiology & Hormonal Chemistry)  
Consultant Pathologist : **Dr. Prasad Netravalkar** MBBS, MD. (Path) BOM

(HOME COLLECTION FACILITY AVAILABLE)

**Panaji** : 1st, Floor, Rizvi Sadan, Above Saroj Emporium, Near Inox Theatre, Opp. Municipal Market, Panaji.  
Ph.: 2229142, 8407912840, 8390242524

E-mail: ashwinilabpanaji@gmail.com, drprasadnetravalkar@gmail.com

**Mapusa** : F8, Ramchandra Chambers, 1st Floor, Mapusa Clinic Road, Mapusa - Bardez, Goa. Ph.: 2252320, 2250709

**Sanquelim** : 1st floor, Shanta Commercial Complex, Sanquelim - Goa. Ph.: 2364524, 9119574524

Pt.No. : 45 270224

Pt.Name : Mr. Madhukar Belpatre Rao

Age : 59 Yrs. Sex : M

Ref. By : -

Date : 27-02-2024

Normal Range

## KIDNEY FUNCTION TESTS

Blood Urea	: 26.0	mg/dl	15 - 40 mg/dl
S. Creatinine	: 0.83	mg/dl	0.7 - 1.4 mg/dl
S. Uric Acid.	: 3.80	mg/dl	2.5-7.5 mg/dl
S. Sodium	: 141.2	mEq/L	135 - 155 mEq/L
S. Potassium	: 3.90	mEq/L	3.5 - 5.5 mEq/L
S. Chlorides	: 102.6	mEq/L	99 - 108 mEq/L



Pathologist

**Dr. Prasad Netravalkar**  
MBBS, MD (Bom)  
GMC Reg. No. 1294

*We Care*

*All Diagnostic facilities under one roof in Panaji centre - Lab. ultrasound, X ray, ECG, TMT, ECHO*

# DR. NETRAVALKAR'S ASHWINI PATHOLOGY LABORATORY

(For all Investigation in Histopathology, Cytopathology, Haematology, Clinical Pathology, Microbiology & Hormonal Chemistry)

Consultant Pathologist : **Dr. Prasad Netravalkar** MBBS, MD. (Path) BOM.

(HOME COLLECTION FACILITY AVAILABLE)

**Panaji** : 1st, Floor, Rizvi Sadan, Above Saroj Emporium, Near Inox Theatre, Opp. Municipal Market, Panaji.  
Ph.: 2229142, 8407912840, 8390242524

E-mail: ashwinilabpanaji@gmail.com, drprasadnetravalkar@gmail.com

**Mapusa** : F8, Ramchandra Chambers, 1st Floor, Mapusa Clinic Road, Mapusa - Bardez, Goa. Ph.: 2252320, 2250709

**Sanquelim** : 1st floor, Shanta Commercial Complex, Sanquelim - Goa. Ph.: 2364524, 9119574524

Pt.No. : 45 270224

Pt.Name : Mr. Madhukar Belpatre Rao

Age : 59 Yrs. Sex : M

Ref. By : -

Date : 27-02-2024

## EXAMINATION OF URINE

### PHYSICAL EXAMINATION


Quantity : 20 ml  
Colour : Pale Yellow  
Appearance : Slightly Hazy  
pH : 6.5  
Specific Gravity : 1.010

### CHEMICAL EXAMINATION

Proteins : Absent  
Glucose : Absent  
Ketone Bodies : Absent  
Bile Salts : Absent  
Bile Pigments : Absent  
Occult Blood : Negative  
Urobilinogen : Normal

### MICROSCOPIC EXAMINATION [As per hpf]

Epithelial Cells : 0 - 1 /hpf  
Pus Cells : 10 - 12 /hpf  
Red Blood Cells : Absent  
Casts : Absent  
Crystals : Absent



Pathologist

**Dr. Prasad Netravalkar**  
MBBS, MD (Bom)  
GMC Reg. No. 1294

*We Care*

*All Diagnostic facilities under one roof in Panaji centre - Lab. ultrasound, X ray, ECG, TMT, ECHO*

# DR. NETRAVALKAR'S ASHWINI PATHOLOGY LABORATORY

(For all Investigation in Histopathology, Cytopathology, Haematology, Clinical Pathology, Microbiology & Hormonal Chemistry)

Consultant Pathologist : **Dr. Prasad Netravalkar** MBBS, MD. (Path) BOM

(HOME COLLECTION FACILITY AVAILABLE)

**Panaji** : 1st, Floor, Rizvi Sadan, Above Saroj Emporium, Near Inox Theatre, Opp. Municipal Market, Panaji.  
Ph.: 2229142, 8407912840, 8390242524

E-mail: ashwinilabpanaji@gmail.com, drprasadnetravalkar@gmail.com

**Mapusa** : F8, Ramchandra Chambers, 1st Floor, Mapusa Clinic Road, Mapusa - Bardez, Goa. Ph.: 2252320, 2250709

**Sanquelim** : 1st floor, Shanta Commercial Complex, Sanquelim - Goa. Ph.: 2364524, 9119574524

**Patient Name** : MR. MADHIKAR BELPATRE RAO

**Referral** : SELF

**Age / Gender** : 59 / Male

**Reporting Time** : Feb 27, 2024, 01:31 p.m.

**Patient ID** : 30962


**Sample ID** :



**Source** : DIRECT

Test Description	Value(s)	Reference Range	Unit
<b><u>Thyroid Profile</u></b>			
T3 (Total) Method : Serum ECL	1.51	1.30 - 3.10	nmol/l
T4 (Total)* Method : Serum ECL	91.40	66.0 - 181.0	nmol/l
TSH(Ultrasensitive)* Method : Serum ECL	1.20	0.270 - 4.20	uIU/ml

\*\*END OF REPORT\*\*



Pathologist

**Dr. Prasad Netravalkar**  
MBBS, MD (Bom)  
GMC Reg. No. 1294

Page 1 of 1

*We Care*

*All Diagnostic facilities under one roof in Panaji centre - Lab, ultrasound, X ray, ECG, TMT, ECHO*

# DR. NETRAVALKAR'S ASHWINI PATHOLOGY LABORATORY

(For all Investigation in Histopathology, Cytopathology, Haematology, Clinical Pathology, Microbiology & Hormonal Chemistry)

Consultant Pathologist : **Dr. Prasad Netravalkar** MBBS, MD. (Path) BOM.

(HOME COLLECTION FACILITY AVAILABLE)

**Panaji** : 1st, Floor, Rizvi Sadan, Above Saroj Emporium, Near Inox Theatre, Opp. Municipal Market, Panaji.  
Ph.: 2229142, 8407912840, 8390242524

E-mail: ashwinilabpanaji@gmail.com, drprasadnetravalkar@gmail.com

**Mapusa** : F8, Ramchandra Chambers, 1st Floor, Mapusa Clinic Road, Mapusa - Bardez, Goa. Ph.: 2252320, 2250709

**Sanquelim** : 1st floor, Shanta Commercial Complex, Sanquelim - Goa. Ph.: 2364524, 9119574524

**Patient Name** : MR. MADHIKAR BELPATRE RAO

**Referral** : SELF

**Age / Gender** : 59 / Male

**Reporting Time** : Feb 27, 2024, 01:31 p.m.

**Patient ID** : 30962

**Sample ID** :



**Source** : DIRECT

Test Description	Value(s)	Reference Range	Unit
------------------	----------	-----------------	------

### PSA (Prostate Specific Antigen)-Total


PSA- Prostate Specific Antigen\* 1.94 0 - 4 ng/mL

### **INTERPRETATION :**

Prostate-specific antigen (PSA) is a glycoprotein that is produced by the prostate gland, the lining of the urethra, and the bulbourethral gland. PSA exists in serum mainly in two forms, complexed to alpha-1-anti-chymotrypsin (PSA-ACT complex) and unbound (free PSA). Increases in prostatic glandular size and tissue damage caused by benign prostatic hypertrophy, prostatitis, or prostate cancer may increase circulating PSA levels. Transient increase in PSA can also be seen following per rectal digital or sonological examinations.

**Note:** Patients on Biotin supplement may have interference in some immunoassays. With individuals taking high dose Biotin (more than 5 mg per day) supplements, at least 8-hour wait time before blood draw is recommended.

\*\*END OF REPORT\*\*



Pathologist

**Dr. Prasad Netravalkar**  
MBBS, MD (Bom)  
GMC Reg. No. 1294

Page 1 of 1

*We Care*

*All Diagnostic facilities under one roof in Panaji centre - Lab. ultrasound, X ray, ECG, TMT, ECHO*



# DR. NETRAVALKAR'S ASHWINI PATHOLOGY LABORATORY

(For all Investigation in Histopathology, Cytopathology, Haematology, Clinical Pathology, Microbiology & Hormonal Chemistry)

Consultant Pathologist : **Dr. Prasad Netravalkar** MBBS, MD. (Path) BOM

(HOME COLLECTION FACILITY AVAILABLE)

**Panaji** : 1st, Floor, Rizvi Sadan, Above Saroj Emporium, Near Inox Theatre, Opp. Municipal Market, Panaji.

Ph.: 2229142, 8407912840, 8390242524

E-mail: ashwinilabpanaji@gmail.com, drprasadnetravalkar@gmail.com

**Mapusa** : F8, Ramchandra Chambers, 1st Floor, Mapusa Clinic Road, Mapusa - Bardez, Goa. Ph.: 2252320, 2250709

**Sanquelim** : 1st floor, Shanta Commercial Complex, Sanquelim - Goa. Ph.: 2364524, 9119574524

**Patient Name** : MR. MADHIKAR BELPATRE RAO

**Referral** : SELF

**Age / Gender** : 59 / Male

**Reporting Time** : Feb 27, 2024, 01:31 p.m.

**Patient ID** : 30962

**Sample ID** :



**Source** : DIRECT

Test Description	Value(s)	Reference Range	Unit
------------------	----------	-----------------	------

## Vitamin D3 Total


Vitamin D3 Total	60.12	30.0 - 100.0	ng/ml
------------------	-------	--------------	-------

Method : ECL

Interpretations

1. Cholecalciferol (VitaminD3) is synthesized in the skin from 7 dehydrocholesterol in response to sunlight, some part also comes from Diet and supplements. Ergocalciferol(Vitamin D2) comes essentially from diet and supplements.
2. Both Cholecalciferol and Ergocalciferol are converted in the liver to 25 OH Vitamin D. 25 OH Vitamin D is further hydroxylated in the kidneys to produce 1, 25 Dihydroxy Vitamin D.
3. The measurement of 1,25 Dihydroxy Vitamin D is indicated in several disorders affecting calcium metabolism such as sarcoidosis, renal failure, hyper or hypo -parathyroidism, rickets, tumour associated hypercalcemia, vitamin resistant dysfunction and treatment with anti-convulsive medication.

\*\*END OF REPORT\*\*



**Pathologist**

**Dr. Prasad Netravalkar**  
MBBS, MD (Bom)  
GMC Reg. No 1294

Page 1 of 1

*We Care*

*All Diagnostic facilities under one roof in Panaji centre - Lab, ultrasound, X ray, ECG, TMT, ECHO*



भारत सरकार  
GOVERNMENT OF INDIA



मधुकर राव बेल्पात्रे  
Madhukar Rao Belpatre

जन्म वर्ष / Year of Birth 1964  
पुरुष / Male



6713 2993 8451

आधार – सामान्य माणसाचा अधिकार



भारतीय विशिष्ट ओळख प्राधिकरण  
UNIQUE IDENTIFICATION AUTHORITY OF INDIA

पत्ता S/O सुंदर राव, #3 फ्ल शान्तावन  
शान्तावन वसतिगृह, मर्सेस चिम्बेल रोड,  
मर्सेस नॉर्थ गोवा, गोवा, 403005

Address S/O Sunder Rao, #7 F1  
Shantaban Housing Complex,  
Merces Chimbel Road, Merces,  
North Goa, Goa, 403005



1947  
1800 180 1947




help@uidai.gov.in



www.uidai.gov.in



P.O. Box No. 1947  
Bengaluru-560 001




MER- MEDICAL EXAMINATION REPORT

Date of Examination	27/2/24
NAME	Madhukar Rao
AGE	59
HEIGHT(cm)	172
B.P.	130 / 78 mmHg
ECG	Normal
X Ray	Normal
Vision Checkup	Color Vision: Normal
	Far Vision Ratio: 6/6
	Near Vision Ratio: 6/6
Present Ailments	-NO-
Details of Past ailments (If Any)	-NO-
Comments / Advice : She /He is Physically Fit	He is Physically fit

*(Handwritten Signature)*

Signature with Stamp of Medical Ex



## CERTIFICATE OF MEDICAL FITNESS

This is to certify that I have conducted the clinical examination

of Madhuka Rao on 27/2/24

After reviewing the medical history and on clinical examination it has been found that he/she is

• Medically Fit

• Fit with restrictions/recommendations

Though following restrictions have been revealed, in my opinion, these are not impediments to the job.

1.....

2.....

3.....


However the employee should follow the advice/medication that has been communicated to him/her.

Review after \_\_\_\_\_

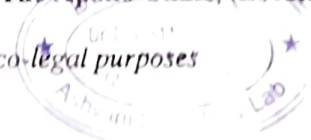
• Currently Unfit

Review after \_\_\_\_\_ recommended

• Unfit

Dr.   
Medical Officer  
The Apollo Clinic, (Location)


*This certificate is not meant for medico-legal purposes*





Dr. Netravalkar  
Dr. Prasad Netravalkar  
M.D., M.S. (M.D.)  
GMC Reg.  
Genl. Pathology Lab

GPS Map Camera



Panaji, Goa, India  
B 165, New Municipal Market, Panaji, Goa 403001, India  
Lat 15.498496°  
Long 73.822377°  
27/02/24 08:58 AM GMT +05:30

201,202,203, Rizvi Sadan, 2nd Floor, Near Municipal Market, Next to Vaidya Hospital, Panaji - Goa.  
Tel.: 0832 2238122 | Email : drashanetravalkar@gmail.com

NAME: MR.MADHUKAR BELPATRE  
AGE: 59/YRS  
REF BY: DR. SELF

DATE: 27/02/2024  
SEX: M

**ULTRASONOGRAPHY OF ABDOMEN AND PELVIS**

**LIVER** – It shows mild increased echotexture but normal size. No mass or focal lesions is seen. Biliary and portal radicals appear normal. Length of right lobe of liver is 12.7cm.PV-9mm.

**PANCREAS**— It shows normal echotexture and size. No focal lesions are seen.

**GALL BLADDER**---It is moderately distended. Two calculi aggregate measuring 8mm and 6mm are seen in GB. GB wall thickness is 4mm. Pericholecystic space appears normal.CBD is 3mm.

**SPLEEN**----- It shows normal echotexture and size. Length of spleen is 8.3cm.

**BOTH KIDNEYS** Both kidneys show normal echotexture and size. Corticomedullary junction appears normal.Perirenal space is normal. No hydronephrosis or calculus is seen .

Right kidney--measures 11.1cm x 4.9cms .

Left kidney—measures 10.2cms x 5.7cms.

**Urinary Bladder** is well distended .No calculus or mass is seen .Wall thickness is 4mm .Fine trabeculations are seen.Both VUJs are normal.

FV-445ml.PVR-1 is 120ml .PVR-2 is 130ml.

**Prostate** measures 4.9cms x 4.8cmx 3.7cms Weight is 47gms.


No calcification or mass is seen.

No free fluid is seen in pelvis.Plenty of bowel gases are seen.

**Impression** : Fatty liver-Grade-1.

Prostatomegaly with Significant PVR.

With regards,

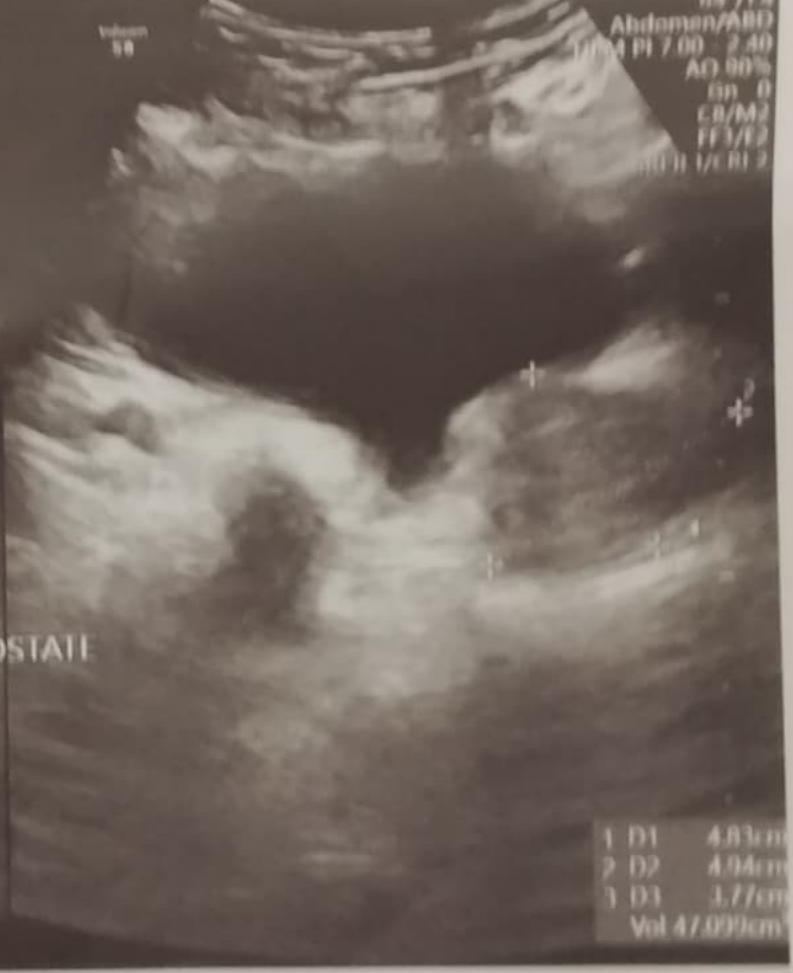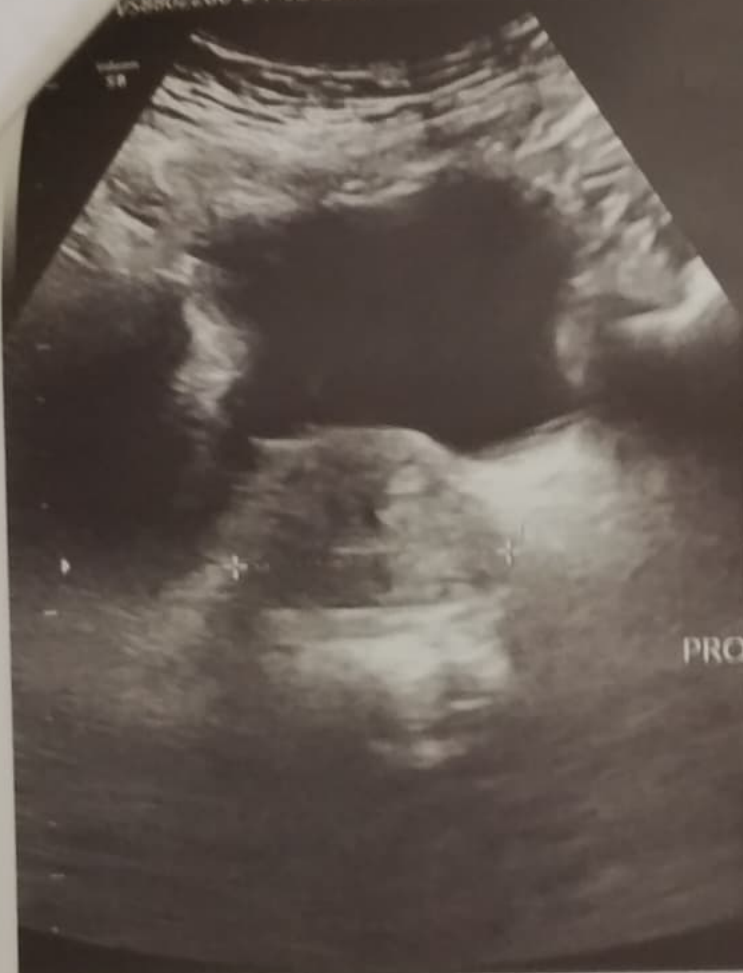  
DR .ASHADEVI NETRAVALKAR,MD  
RADIOLOGIST

DR. ASHADEVI NETRAVALKAR, MD  
RADIOLOGIST  
201, 202, 203, Rizvi Sadan,  
Near Municipal Market,  
Next to Vaidya Hospital,  
Panaji - Goa.

ADHIKAR BELPATRE 59,  
VS8802280-24-02-27-1

ASHWINI LABORATORY

Tls = 0.1 27.02.2024  
Tlb = 0.1 11:19:12 AM  
MI 0.7 CI 5 RS  
23Hz/16.9cm  
64/14  
Abdomen/ABD  
10/4 PI 7.00 - 2.40  
AO 90%  
Gn 0  
CB/M2  
FF3/E2  
MI 1/CR 2



PROSTATE

1 D1 4.83cm  
2 D2 4.04cm  
3 D3 3.77cm  
Vol 47.099cm<sup>3</sup>

201,202,203, Rizvi Sadan, 2nd Floor, Near Municipal Market, Next to Vaidya Hospital, Panaji - Goa.  
Tel.: 0832 2238122 | Email : drashanetravalkar@gmail.com

NAME: MR.MADHUKAR BELPATRE  
AGE: 59/YRS  
REF BY: DR. SELF

DATE: 27/02/2024  
SEX: M

X-RAY CHEST--- PA VIEW

Lung fields are clear.

Both costophrenic angles are clear.


Cardiac size is normal. Aortic knuckle is prominent.

Both domes of diaphragm are normal.

Rib cage is normal.

**IMPRESSION :** Normal study

With regards,



RADIOLOGIST

DR.ASHADEVI NETRAVALKAR,MD  
DR. ASHADEVI NETRAVALKAR  
MBBS., MD, AFIH  
Consultant Radiologist & Sonologist  
201,202,203, Rizvi Sadan, Panaji  
Tel.: 0832 2238122



201,202,203, Rizvi Sadan, 2nd Floor, Near Municipal Market, Next to Vaidya Hospital, Panaji - Goa.  
Tel.: 0832 2238122 | Email : drashanetravalkar@gmail.com

## Cardiology Report

Page 1/2

## ASHWINI LABORATORY

Patient / Exam Information

Date of Exam: 27.02.2024

Patient ID VS8802280-24-02-27-1  
Name MADHUKAR BELPATRE 59  
DOB.Age  
Sex Other  
Height  
Weight  
BSA  
HR

Perf. Phys Ref. Phys. Sonographer  
Comment Indication

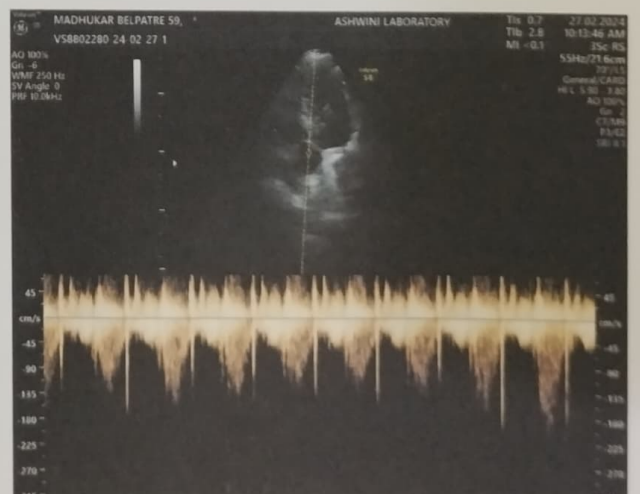
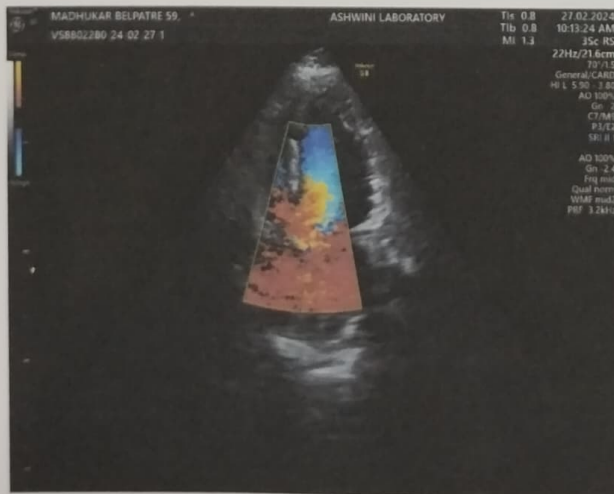
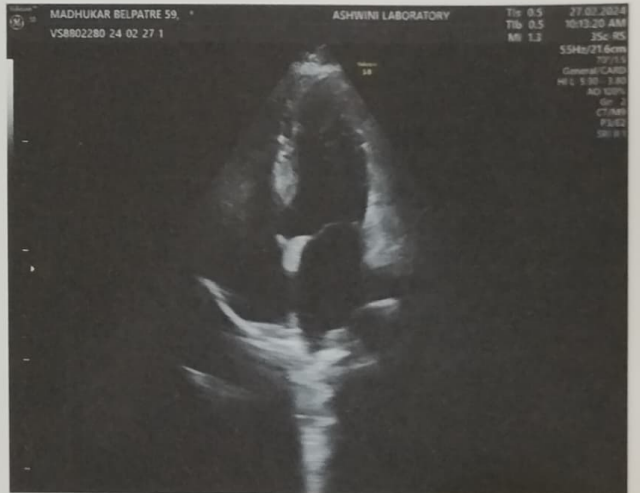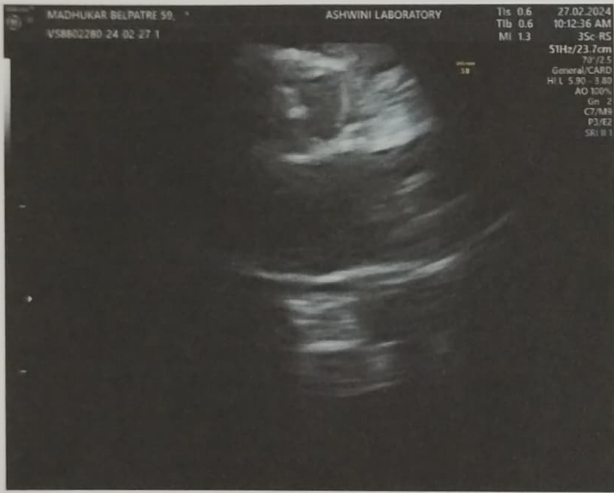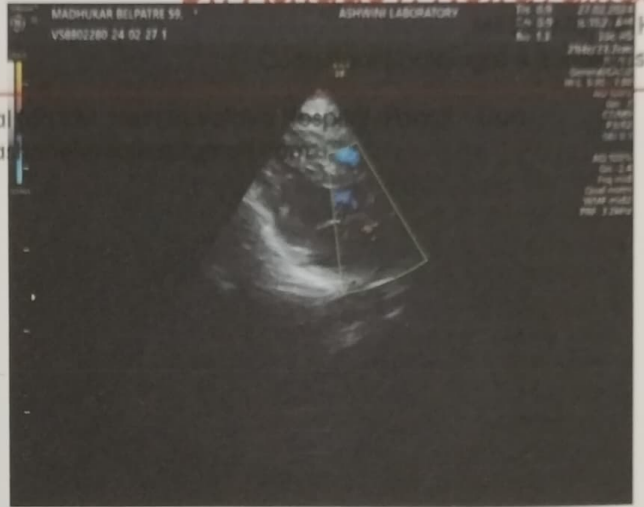
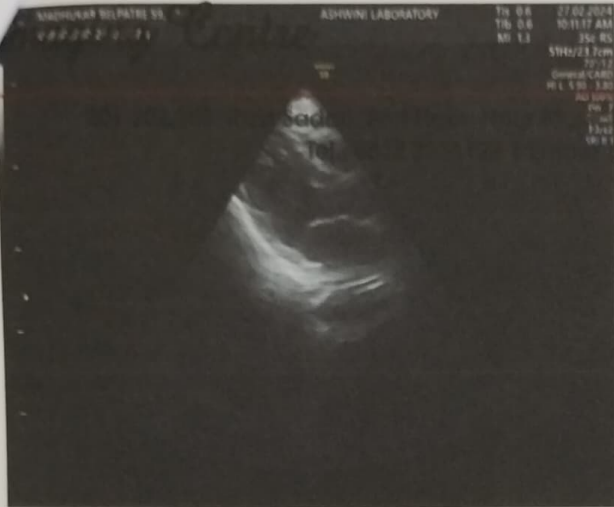M-Mode Measurements	Value	m1	m2	m3	m4	m5	m6	Meth.
<b>AV/LA</b>								
Ao Root Diam.	2.96 cm	2.96						avg.
LA Diam.	3.33 cm	3.33						avg.
<b>Left Ventricle</b>								
IVSd	0.97 cm	0.97						avg.
LVDd	4.96 cm	4.96						avg.
LVPWd	1.15 cm	1.15						avg.
IVSs	2.00 cm	2.00						avg.
LVDs	3.20 cm	3.20						avg.
LVPWs	1.51 cm	1.51						avg.
EDV (Teich)	116.055 ml	116.055						
EDV (Cubed)	122.024 ml	122.024						
ESV (Teich)	40.960 ml	40.960						
ESV (Cubed)	32.768 ml	32.768						
SV (Teich)	75.095 ml	75.095						
SV (Cube)	89.256 ml	89.256						
EF (Teich)	64.71 %	64.71						
EF (Cube)	73.15 %	73.15						
Fract. Short.	35.48 %	35.48						
LV Mass	228.59 g	228.59						

### Comment

NON-DILATED AND NON-HYPERTROPHIED LEFT VENTRICLE WITH PRESERVED EJECTION FRACTION  
NO REGIONAL WALL MOTION ABNORMALITIES. AORTIC VALVE SCLEROSIS. OTHER VALVES ARE  
GROSSLY NORMAL. AORTIC ROOT IS NORMAL. PERICARDIUM IS NORMAL.

*Ashadevi*

1/2  
27.02.2024 10:16:45 AM



# Dr. Netravalkar's Imaging Centre

**Dr. Ashadevi Netravalkar**

MBBS., MD, AFIH

Consultant Radiologist & Sonologist

Name : Madhukar Belpatre  
Age : 59 M/F M Date : 27.02.24  
Investigation : ECG  
Ref. by Dr. : \_\_\_\_\_

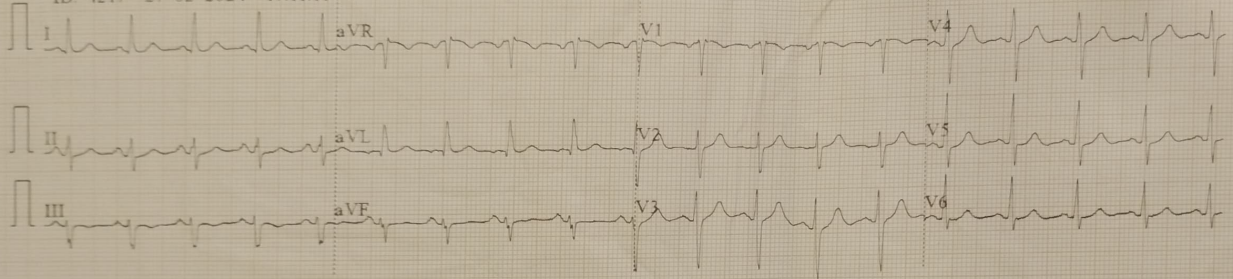
201,202,203, Rizvi Sadan, 2nd Floor, Near Municipal Market,  
Next to Vaidya Hospital, Panaji - Goa.

Tel.: 0832 2238122 | Email : drashanetravalkar@gmail.com

Timing : 8.00 am to 1.00 pm | 4.00 pm to 7.00 pm

ID: 4217 27-02-2024 17:11:11

BPL



0.5-100Hz 25mm/s 10mm/mV ♥113 V1.0 SEMIP V1.7


CARDIART

ID: 4217

Male mmHg  
59 Years  
cm kg

HR 111 bpm  
P 106 ms  
PR 137 ms  
QRS 77 ms  
QT/QTc 307/419 ms  
P/QRS/T 66/-24/21 °  
RV5/SV1 0.954/0.752 mV

ECG shows Sinus Tachycardia



Signature

DR. SIGN.