



डॉ. बी. एम. शरणागत

एम.डी. (मेडिसिन)

रजि.नं. - 4612

कार्डियो - डायबेटोलॉजिस्ट

एवं परामर्श चिकित्सक



रजि.क्र.-NHA/REG./BGT/2012/21

क्रिटिकल केयर युनिट I.C.C.U. सुविधायुक्त

आयुष्मान हॉस्पिटल
एंड डायग्नोस्टिक रिसर्च सेंटर

सर्किट हाउस रोड, बालाघाट 07632-241070 | समय-सुबह 10 बजे से संध्या 8.00 बजे तक

Name MR. SANJAY BANGDE R/O

Date 08/10/2022

General Physical Examination

Date of Examination 08/10/2022

Name MR. SANJAY BANGDE Age 36.7 DOB 08/08/1985 Sex MALE

Referred by M.E.D.I.WHEEL

Photo Id AADHAAR CARD ID

Ht 1.75 (CM)

Wt 73 (kg)

Chest (Expiration): 95 (cm)

Abdomen Circumference 101 (cm)

Blood Pressure 130/80 mm Hg

PR 16 /min

RR 21 /min

Temp 98.6 F

BMI 22.7

Eye Examination

NO LE
6/6 6/6

Other: MI

On examination he/she appears physically and mentally fit: Yes/No

Signature of Examinee:

Name of Examinee: MR. SANJAY BANGDE

Signature Medical Examiner:

Name Medical Examiner: Dr. B. M. SHARNAGAT

M.D (Medicine) Regd No 4612
AYUSHMAN HOSPITAL
& Diagnostic Research Center
BALAGHAT (M.P.) 481001

उपलब्ध सुविधाएं

- क्रिटिकल केयर युनिट/आई.सी.सी.यू., सेंट्रल ऑक्सीजन पाइप लाईन युक्त
- फेफड़ों के कार्य क्षमता की कम्प्यूटराईज्ड जॉच (P.F.T.)
- मल्टीपैरा, पल्स ऑक्स, डीफ्रिबीलेटर एवं वेंटीलेटर सुविधाएं
- फिजियोथेरेपी युनिट एवं डायटिशियन परामर्श।
- कम्प्यूटराईज्ड ई.सी.जी., टी.एम.टी., होल्टर मॉनिटरिंग व अल्ट्रासोनो नेबुलाईजेशन
- डायबीटिज, अस्थमा एवं किडनी क्लिनिक।
- एक्सरे, पैथालॉजी, मेडिकल स्टोर्स व कैंटीन सुविधा
- मनोचिकित्सक, चर्मरोग, कैंसर एवं किडनी विशेषज्ञ द्वारा परामर्श - प्रति रविवार
- सेन्ट्रली एयर कूल्ड एवं ए.सी.युक्त प्राइवेट एवं जनरल वार्ड
- 24 घंटे इमरजेन्सी सेवा, एम्बुलेन्स एवं विद्युत जनरेटर व्यवस्था।



2D ECHOCARDIOGRAPHY & DOPPLER REPORT

NAME - MR.SANJAY BANGDE

REFD. BY - SELF

AGE - 36YRS/M

DATE - 08.10.2022

M-Mode & Essential Measurements :-

Heart Rate : 74 Bpm	LVID(D) : 36 mm	MV Annulus : 25 mm	RVID(d) : 34 mm
Aortic Root : 28 mm	LVID(S) : 18 mm	TV Annulus : 24 mm	IVC : 16 mm
Left Atrium : 34 mm	IVSd (D) : 11 mm	AO Annulus : 19 mm	Mitral-Epss : 06 mm
LVEF : 60 %	LVPWd(D) : 12 mm	PV Annulus : 20 mm	TAPSE : 16 mm

2D Echo Findings :-

RWM(LV) : NORMAL
 CHAMBERS : NORMAL SIZED
 IAS/IVS : INTACT
 I/C - CLOT/VEGETATION : NIL
 PERICARDIAL EFFUSION : NIL
 PLEURAL EFFUSION : NIL

Doppler Study :-

	Peak Gradient (mm of Hg)	Mean Gradient (mm of Hg)	Valve area (Normal Range)	Grade of Regurgitation
Mitral Valve	--	--	4.0-6.0	NIL
Aortic Valve	--	--	2.5-4.0	NIL
Tricuspid Valve	--	--	7.0-9.0	NIL
Pulmonary Valve	--	--	2.0-3.0	NIL

Estimated PASP by TR jet = 25 mm of Hg.

FINAL DIAGNOSIS :-

NO RWMA , LVEF = 60%
 NO LVDD
 NORMAL VALVES
 NORMAL LV SYSTOLIC FUNCTION
 NORMAL RV FUNCTION.

Dr. B. M. SHARNAGAT
 M.D. (Medicine) Regd No. 4612
 AYUSHMAN HOSPITAL
 & Diagnostic Research Center
 Dr. B. M. Sharnagat (MD-Medicine)

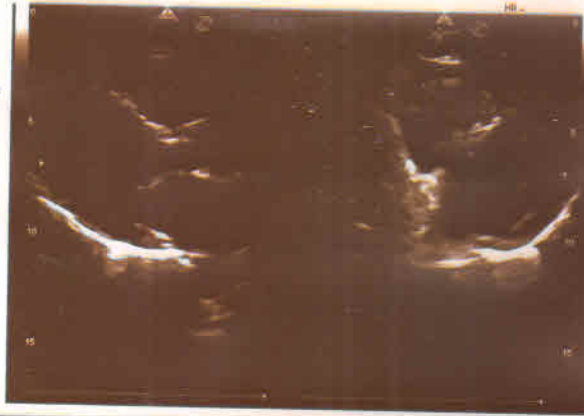BANGDE,36Y,M

08 OCT 2022 11:34:56

AM

TEI D GEN M G
PRC 74/26 X/M CB-
PR3 2

F 80% M 1.1
TIS 0.4



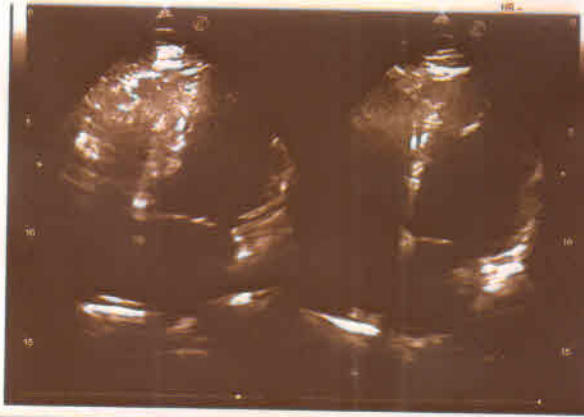MR. SANJAY BANGDE,36Y,M

08 OCT 2022 11:35:36

AM

TEI D GEN M G
PRC 74/26 X/M CB-
PR3 2

F 80% M 1.1
TIS 0.4



MR. SANJAY BANGDE,36Y,M


08 OCT 2022 11:36:07

AM

TEI D GEN M G
PRC 74/26 X/M CB-
PR3 2

PW F 2.5 MHz G
PRF 4.1 kHz WF 300 Hz
PRC 40

F 80% M 0.8
TIS 0.9
TIR 2.8



MR. SANJAY BANGDE,36Y,M

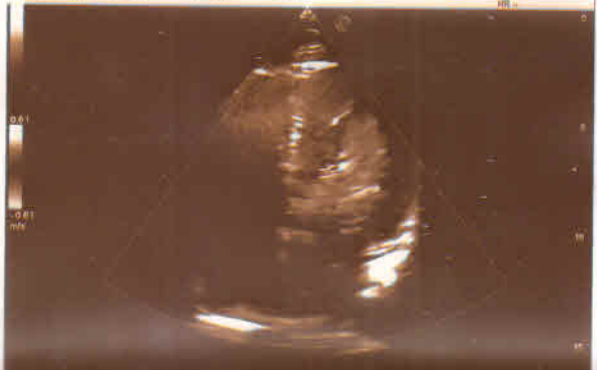08 OCT 2022 11:36:15

AM

TEI D GEN M G
PRC 74/26 X/M CB-
PR3 2

CFM F 2.5 MHz G
PRF 3.3 MHz WF 3
PRC L/3 PRS 4

F 80% M 0.5
TIS 0.7





ULTRASOUND REPORT

Name - MR. SANJAY BANGDE

Age – 36Yrs/M

Refd. By - SELF

Date -8.10.2022

LIVER : The liver is normal in size and shape . It shows normal parenchymal echo texture.

The IHBR , IHPR and porta hepatis appear normal.

There is no e/o any lesion.

GALLBLADDER : Normal , There is no e/o evidence of calculi.

PANCREAS : Normal in size and shows normal echotexture.

SPLEEN : Spleen is normal in size and shows homogenous echo texture.

KIDNEYS : Both kidneys are normal in size, shape, contour and in position .

There is no renal calculi and no pelvi calyceal dilatation .

LEFT KIDNEY MEASURES : 8.5 X 6.3 CM

RIGHT KIDNEY MEASURES : 6.2 X 4.7 CM

PROSTATE : The prostate is normal in size and shows normal echo texture .

There is no e/o free fluid in pelvis .

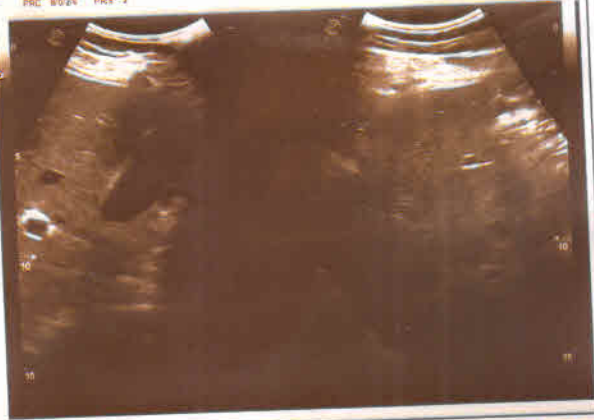IMPRESSION : NORMAL STUDY OF ABDOMEN .

Dr. B.M. SHARNAGAT
M.D.(Medicine) Regd No. 4612
AYUSHMAN HOSPITAL
& Diagnostic Research Center
BALAGHAT (M.P.) 481001
Dr. B.M. Sharnagat (MD Medicine)

08 OCT 2022 11:38:09 AM

GDE, 36Y, M

RES L G
TEI 0 152 mm X/M CT-
PRC 8/24 PRS 2

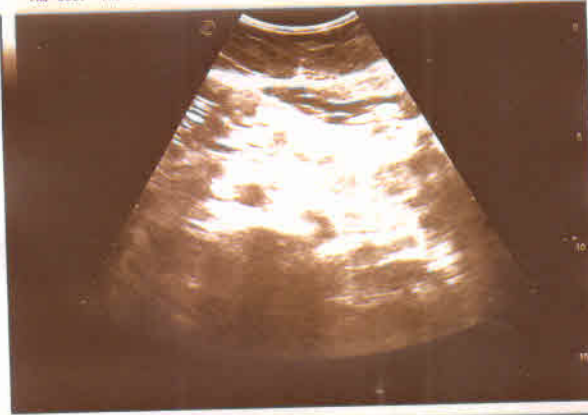

08 OCT 2022 11:38:41 AM

MR. SANJAY BANGDE, 36Y, M

ABDOMINAL
AC2541 ABO

RES L G
TEI 0 152 mm X/M CT-
PRC 8/24 PRS 2

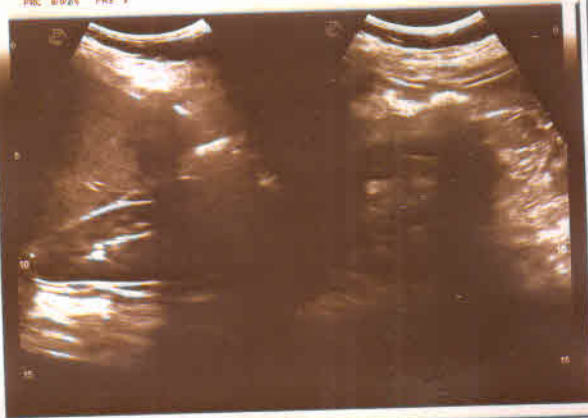

08 OCT 2022 11:39:05 AM

MR. SANJAY BANGDE, 36Y, M

ABDOMINAL
AC2541 ABO

RES L G
TEI 0 152 mm X/M CT-
PRC 8/24 PRS 2

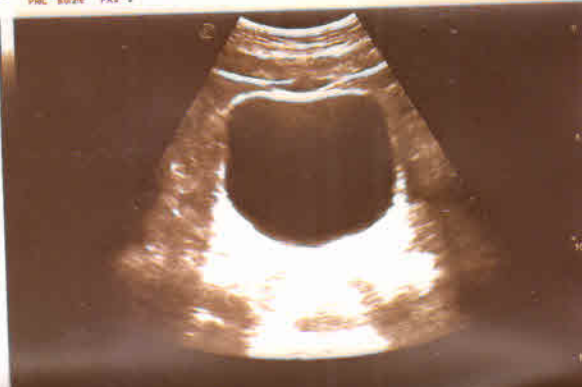

08 OCT 2022 11:39:19 AM


MR. SANJAY BANGDE, 36Y, M

ABDOMINAL
AC2541 ABO

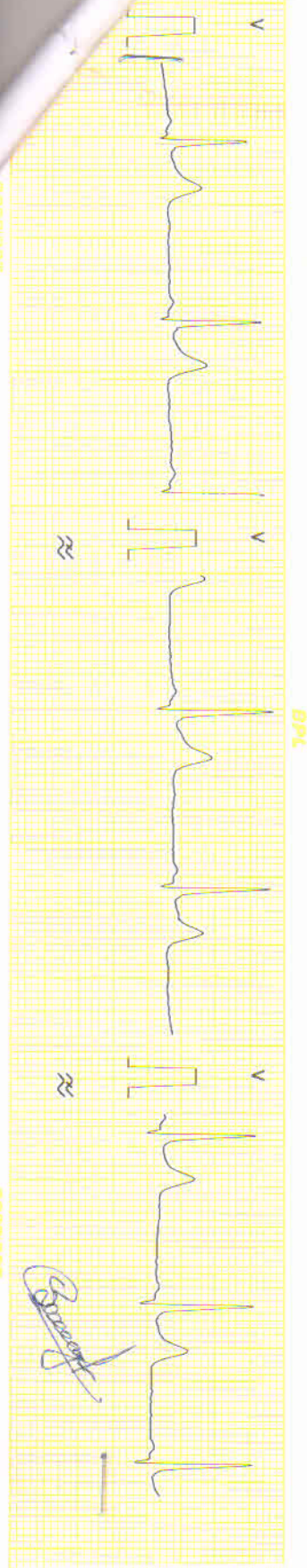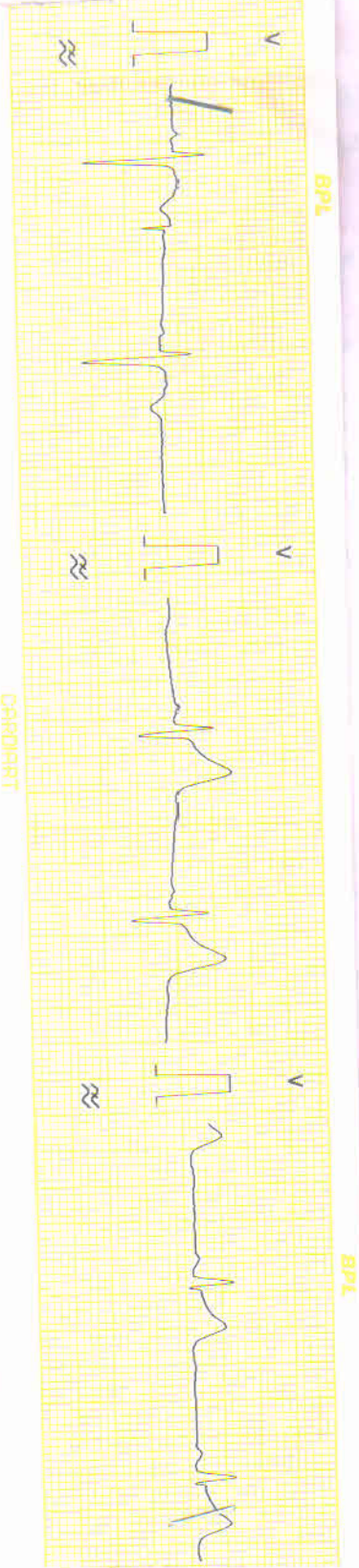
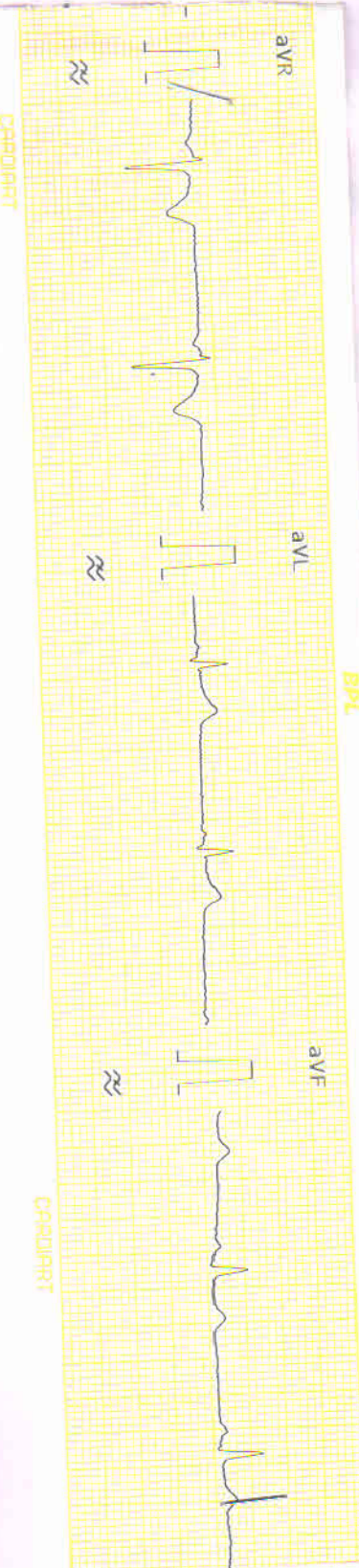
RES L G
TEI 0 152 mm X/M CT-
PRC 8/24 PRS 2



CARDIART



Bede - 8/16/22



Signature

Signature
Dr. B.M. SHARNAGAT
M.D. (Medicine) Reg. No. 4612
AYUSHMAN HOSPITAL
& Diagnostic Research Center
BALAGHAT (M.P.) 481001

CBC Report by the analyzer

ID: 6

Mode: Whole

Time: 08-10-2022 11:08

Name: MR. SANJAY BANGDE

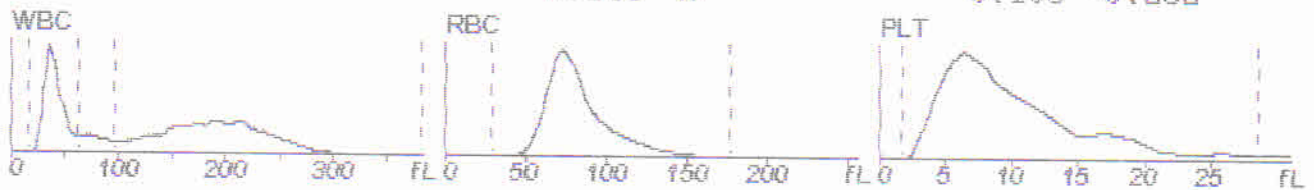
Gender: Male Age: 37 Years

Chart No.:

Dept.: PATHOLOGY

Bed No.:

Parameter		Result	Ref. range
WBC	L	3.8 x 10 ⁹ /L	4.0 - 10.0
Lymph#		1.2 x 10 ⁹ /L	0.8 - 4.0
Mid#		0.3 x 10 ⁹ /L	0.1 - 1.5
Gran#		2.3 x 10 ⁹ /L	2.0 - 7.0
Lymph%		31.5 %	20.0 - 40.0
Mid%		7.5 %	3.0 - 15.0
Gran%		61.0 %	50.0 - 70.0
HGB		12.9 g/dL	12.0 - 16.0
RBC	L	3.97 x 10 ¹² /L	4.00 - 5.50
HCT	L	31.7 %	40.0 - 54.0
MCV		80.0 fL	80.0 - 100.0
MCH		32.4 pg	27.0 - 34.0
MCHC	H	40.6 g/dL	32.0 - 36.0
RDW-CV		15.7 %	11.0 - 16.0
RDW-SD		45.4 fL	35.0 - 56.0
PLT		176 x 10 ⁹ /L	100 - 300
MPV		8.2 fL	6.5 - 12.0
PDW		16.1	9.0 - 17.0
PCT		0.144 %	0.108 - 0.282



Sender: DR. B. M. SHARNAGAT

Tester: L. T. BASANT TANDE

Checker: DR. B. M. SHARNAGAT


Dr. B. M. SHARNAGAT

 M.D. (Medicine) Regd No 4612
 I/C Pathologist/Technician
 (Ayushman Hospital, Balaghat)
 BALAGHAT (M.P.) 481001

- This Report is not valid for MLC purpose.
- This Report is only for Physician's help to confirm the diagnosis.



क्रिटिकल केयर युनिट I.C.C.U. सुविधायुक्त

आयुष्मान हॉस्पिटल

एण्ड डॉयग्नोस्टिक रिसर्च सेन्टर

सर्किल हाऊस रोड, बालाघाट ☎ 07632:241070

REGD.No. : NHA/REG/BGT/2012/24

PATHOLOGY REPORT

• Auto Analyzer • Hematology Analyzer • A.B.G. • Computerised Lab

NAME : MR. SANJAY BANGDE AGE : 37Yrs.

SEX : M

REF. BY : Dr. B. M. SHARNAGAT (M.D.)

DATE : 08/10/2022

TESTS	RESULTS	UNITS	REF. RANGE
BIOCHEMISTRY			
LIPID PROFILE			
S. Cholesterol	:158	mg/dl	UP TO <200
S. Triglycerides	:140	mg/dl	UP TO <150
HDL Cholesterol	:34	mg/dl	32 -60
LDL Cholesterol	:99	mg/dl	UP TO <100
VLDL Cholesterol	:22	mg/dl	7 - 35
LDL / HDL Ratio	:3.6	%	2.5 - 5.0
S. Cholesterol / HDL Ratio	:4.3	%	3.5 - 5.0
KFT			
Serum CREATININE	:0.96	mg/dl	0.8-1.2
BUN	:14	mg/dl	8-20
BUN Creatinine Ratio	:14.9		
LFT			
Bilirubin-Total	:0.9	mg%	0-1.2
Direct	:0.5	mg%	0-0.6
Indirect	:0.4	mg%	0-0.5
SGPT(ALT)	:32	IU/L	7-35
SGOT(AST)	:28	IU/L	8-40
Alk.Phosphatase	:105	U/L	86-306 Adult
TOTAL PROTEINS	6.4	gm/dl	6.2-8.2
Albumin	4.5	g/dl	3.5-5.5
Globulin	2.5	g/dl	2.5-3.2
A/G Ratio	2.0		1.5-2.5
GGT	21	U/L	9-48
S.URIC ACID	4.9	mg/dl	3.4- 7.2

Dr. B. M. SHARNAGAT
M.D. (Medicine) 4612
Pathologist/Technician
(Ayushman Hospital, Balaghat)
& Diagnostic Research Centre
BALAGHAT (M.P.) 481001

• This Report is not valid for MLC purpose.

• This Report is only for Physician's help to confirm the diagnosis.



क्रिटिकल केयर युनिट I.C.C.U. सुविधायुक्त

आयुष्मान हॉस्पिटल

एण्ड डॉय्मनीस्टिक रिसर्च सेन्टर

सर्कित हाऊस रोड, बालाघाट ☎ 07632:241070


REGD.No. : NHA/REG/BGT/2012/24

PATHOLOGY REPORT

• Auto Analyzer • Hematology Analyzer • A.B.G. • Computerised Lab

NAME : MR. SANJAY BANGDE **AGE :** 37Yrs. **SEX :** M
REF. BY : Dr. B. M. SHARNAGAT (M.D.) **DATE :** 08/10/2022

TESTS	RESULTS	UNITS	REF. RANGE
BIOCHEMISTRY			
BLOOD SUGAR			
B.SUGAR (f)	:88	mg/ dl	60-100
(p.p)	:126	mg/dl	120-160
METHOD : GOD-POD			
HbA1C	5.6 %		
			Nondiabetic :4.5 -6.2
			Good Control:6.0 -7.0%
			Fair Control: 7.0 -8%
			Poor Control: >8%
			(Action Suggested)
Blood group	B		
Rh Type	Positive		
ESR	:08 1st Hr	0-10	
Method		westerangreen	
THYROID HORMONE			
TSH	3.0	uIU/ml	0.3 - 5.0
T3	0.78	ng/ml	0.6-1.8
T4	6.7	ug/dl	5.0-12.5


Dr. B. M. SHARNAGAT
M.D (Medicine) Regd No 4612
AYUSHMAN HOSPITAL
& Diagnostic Research Center
(Ayushman Hospital Balaghat)

- This Report is not valid for MLC purpose.
- This Report is only for Physician's help to confirm the diagnosis.

आयुष्मान हॉस्पिटल

एण्ड डॉय्मनीस्टिक रिसर्च सेन्टर

सर्किट हाऊस रोड, बालाघाट ☎ 07632:241070

PATHOLOGY REPORT

• Auto Analyzer • Hematology Analyzer • A.B.G. • Computerised Lab

NAME : MR. SANJAY BANGDE AGE : 37Yrs. SEX : M
 REF. BY : Dr. B. M. SHARNAGAT (M.D.) DATE : 08/10/2022

URINE ANALYSIS REPORT (By urometer120 analyzer)**PHYSICAL EXAMINATION**


Colour : pale Yellow
 Quantity : 10ml
 Apperance : clear

CHEMICAL EXAMINATION


Sugar : nil
 Bile Pigment : nil
 Nitrite : nil
 Protein : nil
 Bilirubin : nil
 Ketone : nil
 Albumin : nil
 Urobilinogen : Normal 0.01 mg/ml
 Specific gravity : 1.025 1.010-1.030
 Reaction(pH) : 6.0 (Acidic3-6,Alkaline8-10)

MICROSOPIC EXAMINATION

Pus(WBCs) Cells : NIL/ hpf
 RBC : nil/hpf
 Crystals : Absent
 Spermatozoa : Absent
 Epithelial Cells : Absent
 Bacteria : Absent


 Dr. B. M. SHARNAGAT
 M.D. (Pathologist/Technician)
 AYUSHMAN HOSPITAL
 (Ayushman Hospital) Balaghat
 & Diagnostic Research Center
 BALAGHAT (M.P.) 481001

- This Report is not valid for MLC purpose.
- This Report is only for Physician's help to confirm the diagnosis.



मिडिकल केयर युनिट। C.C.U. सुविधायुक्त

आयुष्मान हॉस्पिटल
एण्ड डॉयग्नोस्टिक रिसर्च सेन्टर

Regd.No. : NHA/REG/BGT/2012/21

NAME - MR.SANJAY BANDE

Age - 36Y/M

R / By -MEDIWHEEL

Date - 08/10/22

X- RAY CHEST (PA VIEW)

- *Bony cage - Normal.
- *Trachea - Normal.
- * Heart - Position --- Normal.
C-T ratio---Within normal limits.
Cardiac borders--- Normal.
Specific chamber enlargement---None.
- *Aorta- Position---Normal.
- *Mediastinum- Relative Position ---Normal.
Any Lesion---None.
- *Angles- Cardiophrenic angles---Clear.
Costophrenic angles---Clear.
- *Pleura- Normal.
- *Lungs- .Lung apices seen clear.
.Both lungs seen clear.
.No evidence of any focal active lesion in lung fields.
.Broncho-vascular markings appear normal.
- *Hilar shadows- Normal.
- *Diaphragms- Relative position---Normal.
Outline---Normal.

OPINION

"X-RAY CHEST APPEARS NORMAL."

"NO ABNORMALITY DETECTED."

Thanks for referral.


Dr. B.M. SHARNAGAT
M.D.(Medicine) Reg. No.4612
AYUSHMAN HOSPITAL
& Diagnostic Research Center
BALAGHAT - 431001



Sanjay Bangde

Dr. B. M. Sharnagat

Dr. B. M. SHARNAGAT
M.D (Medicine) Regd. No. 4612
AYUSHMAN HOSPITAL
& Diagnostic Research Center
BALAGHAT (M.P.) 481001