

भारतीय पहचान निदेशिका
Unique Identification Authority of India

Address:
S/O Jugal Kohore Singh, Indira
gandhi nagar, behind power house,
near shiv temple, d c m, Kota, Udyog
Puri Kota, Kota,
Rajasthan - 324004

पता:
S/O युगल कोहरे सिंह, इंदिरा
गान्धी नगर, बिजली घर के पीछे,
शिव मंदिर के पास, डी सी एम,
कोटा, उद्योग पुरी कोटा, कोटा,
राजस्थान - 324004

2184 9030 1803

भारत सरकार
Government of India

सुनील सिंह
Sunil Singh
जन्म तिथि/DOB: 31/07/1988
पुरुष/ MALE

2184 9030 1803

मेरा आधार, मेरी पहचान

[Handwritten signature]

Dr. NITIN AGGARWAL
MBBS, MD
Regn. No. DMC-R-1436

ONEPLUS ULTRASOUND LAB
47, Harsh Vihar, Pitam Pura,
Delhi-110034
Ph. 011-42480101, 9599913051
E-mail: oneplusul@gmail.com



Handwritten signature in blue ink

Handwritten signature in blue ink

Dr. NITIN AGARWAL
MBBS, MD
Regn. No. DMC-R-1436

ONEPLUS ULTRASOUND LAB
47, Harsh Vihar, Pitam Pura,
Delhi-110034
Ph. 011-42480101, 9599913051
E-mail: oneplusul@gmail.com





OnePLUS Ultrasound Lab

QUALITY FIRST... ALWAYS!

Dr. Nitin Agarwal
Pathologist & Director
Ex. Sr. Res. MAMC
& Lok Nayak Hospital
Ex. Chief of Lab Dr. Lal Path Labs.

Dr. Pooja (Garg) Agarwal
Radiologist & Director
MAMC & Lok Nayak Hospital



| | | | |
|-------------|-------------------------|-------------------|----------------------|
| NAME | :Mr. SUNIL SINGH | Barcode No | :10132421 |
| AGE/GENDER | :34 YRS/Male | SPECIMEN DATE | :26/Nov/2022 08:59AM |
| PATIENT ID | :105354 | SPECIMEN RECEIVED | :26/Nov/2022 09:09AM |
| REFERRED BY | :Dr. MEDIWHEEL | REPORT DATE | :26/Nov/2022 02:33PM |
| CENTRE NAME | :ONEPLUS ULTRASOUND LAB | LAB NO. | :012211260012 |

| Test Name | Result | Unit | Ref. Range |
|-----------|--------|------|------------|
|-----------|--------|------|------------|

HAEMATOLOGY

Health checkup 2 Male

| | | | |
|--|-----|---|--|
| Glycosylated Hemoglobin (HbA1c) | 5.1 | % | Non Diabetic adults <5.7 Prediabetic (at risk) 5.7-6.4 Diabetes >6.4 |
| Estimated average blood glucose (eag) | 100 | | |

Reference range (mg/dl):

90 - 120:Excellent control, 121 - 150:Good Control, 151 - 180:Average Control, 181 - 210:Action Suggested

>211:Panic value

BLOOD GROUP (ABO)

B

Rh typing

NEGATIVE

NOTE :

- * Apart from major A,B,H antigens which are used for ABO grouping and Rh typing, many minor blood group antigens exist. Agglutination may also vary according to titre of antigen and antibody.
- * So before transfusion, reconfirmation of blood group as well as cross-matching is needed.
- * Presence of maternal antibodies in newborns, may interfere with blood grouping.
- * Auto agglutination (due to cold antibody, falciparum malaria, sepsis, internal malignancy etc.) may also cause erroneous result.

CBC

| | | | |
|-------------------------------------|-------|--------------|------------|
| Haemoglobin | 16.2 | g/dl | 13.0-17.0 |
| Total Leucocyte Count | 6800 | /cumm | 4000-10000 |
| Differential leucocyte count | | | |
| Neutrophils | 60.6 | % | 40-80 |
| Lymphocyte | 32.50 | % | 20-40 |
| Monocytes | 4.90 | % | 2-10 |
| Eosinophils | 01 | % | 1-6 |
| Basophils | 01 | % | 0-2 |
| RBC Count | 5.40 | million/cumm | 4.5 - 5.5 |

Checked By.

Dr NITIN AGARWAL
M B B S , MD (Path)
DMC/R/01436

DR. NITIN AGARWAL
MBBS,MD(PATHOLOGIST)

47, Harsh Vihar, Pitampura, New Delhi-110034 | Ph.: 011-42480101, 9599913051

E-mail: oneplusul@gmail.com | Web.: www.oneplusul.in

Page 1 of 4



OnePLUS

Ultrasound Lab

QUALITY FIRST... ALWAYS!

Dr. Nitin Agarwal
Pathologist & Director
Ex. Sr. Res. MAMC
& Lok Nayak Hospital
Ex. Chief of Lab Dr. Lal Path Labs.

Dr. Pooja (Garg) Agarwal
Radiologist & Director
MAMC & Lok Nayak Hospital



| | | | |
|-------------|-------------------------|-------------------|----------------------|
| NAME | :Mr. SUNIL SINGH | Barcode No | :10132421 |
| AGE/GENDER | :34 YRS/Male | SPECIMEN DATE | :26/Nov/2022 08:59AM |
| PATIENT ID | :105354 | SPECIMEN RECEIVED | :26/Nov/2022 09:09AM |
| REFERRED BY | :Dr. MEDIWHEEL | REPORT DATE | :26/Nov/2022 02:33PM |
| CENTRE NAME | :ONEPLUS ULTRASOUND LAB | LAB NO. | :012211260012 |

| Test Name | Result | Unit | Ref. Range |
|------------------------|--------|--------------|---------------|
| PCV(Hematocrit) | 51.3 | % | 40-50 |
| MCV | 95 | fL | 83-101 |
| MCH | 30 | Pg | 27-32 |
| MCHC | 31.6 | G/dL | 32-35 |
| Platelet count | 201000 | /cumm | 150000-450000 |
| RDW-CV | 13.1 | % | 11.4-14.0 |
| ESR(WESTEGRENs METHOD) | 10 | mm in 1st hr | 0-20 |

BIOCHEMISTRY

| | | | |
|----------------------------------|-------|-------|------------|
| <u>Blood sugar fasting</u> | 91 | mg/dL | 70-110 |
| <u>Blood sugar pp</u> | 119 | mg/dL | 70.0-140.0 |
| <u>Bun (blood urea nitrogen)</u> | 14.60 | mg/dl | 8.9-21.6 |
| <u>Uric acid, serum</u> | 4.4 | mg/dl | 3.5-7.2 |
| <u>Creatinine, serum</u> | 0.7 | mg/dl | 0.60-1.2 |

LFT(LIVER FUNCTION TEST)

| | | | |
|-------------------------------|------|-------|-------------|
| Bilirubin Total | 0.68 | mg/dl | 0.1-1.2 |
| Bilirubin Conjugated | 0.27 | mg/dl | 0-0.4 |
| Bilirubin Unconjugated | 0.41 | mg/dl | up to 0.7 |
| SGOT (AST) | 44 | U/L | 0-46 |
| SGPT (ALT) | 32 | U/L | 0-49 |
| Alkaline phosphatase | 95 | U/L | 40-129 |
| Gamma glutamyl transpeptidase | 26 | U/L | 10-45 |
| Total Protein | 6.7 | gm/dl | 6.60 - 8.70 |
| Albumin serum | 3.8 | g/dL | 3.0-5.2 |
| Globulin | 2.90 | gm/dl | 1.8-3.4 |
| Albumin/Globulin Ratio | 1.31 | | 1.10 - 2.50 |

LIPID PROFILE

| | | | |
|---------------|-----|-------|--------|
| Cholesterol | 173 | mg/dl | 50-200 |
| Triglycerides | 99 | mg/dL | 25-150 |

Checked By.

Dr NITIN AGARWAL
M B B S , MD (P&S)
DMC/R/01436
DR. NITIN AGARWAL
MBBS, MD (PATHOLOGIST)

47, Harsh Vihar, Pitampura, New Delhi-110034 | Ph.: 011-42480101, 9599913051

E-mail: oneplusul@gmail.com | Web.: www.oneplusul.in

Page 2 of 4

Clinical correlation is essential for final diagnosis. • If test results are unsatisfactory please contact personally or on phone. • This report is for perusal of doctors only.
• All disputes Subject to Delhi Jurisdiction only. • Not for medicolegal purposes. • All congenital anomalies in a foetus may not be diagnosed in routine obstetric ultrasound.



OnePLUS Ultrasound Lab

— QUALITY FIRST... ALWAYS! —

Dr. Nitin Agarwal
Pathologist & Director
Ex. Sr. Res. MAMC
& Lok Nayak Hospital
Ex. Chief of Lab Dr. Lal Path Labs.

Dr. Pooja (Garg) Agarwal
Radiologist & Director
MAMC & Lok Nayak Hospital



| | | | |
|-------------|-------------------------|-------------------|----------------------|
| NAME | :Mr. SUNIL SINGH | Barcode No | :10132421 |
| AGE/GENDER | :34 YRS/Male | SPECIMEN DATE | :26/Nov/2022 08:59AM |
| PATIENT ID | :105354 | SPECIMEN RECEIVED | :26/Nov/2022 09:09AM |
| REFERRED BY | :Dr. MEDIWHEEL | REPORT DATE | :26/Nov/2022 02:33PM |
| CENTRE NAME | :ONEPLUS ULTRASOUND LAB | LAB NO. | :012211260012 |

| Test Name | Result | Unit | Ref. Range |
|-----------------------|--------|-------|--|
| HDL Cholesterol | 48 | mg/dL | 40 - 60 |
| LDL cholesterol | 105 | mg/dL | <130 |
| VLDL cholesterol | 19.8 | mg/dL | 5-40 |
| Cholesterol/HDL Ratio | 3.6 | | Low Risk 3.3-4.97 Average Risk 4.4-7.1 Moderate Risk 7.1-11.0 High Risk >11.0 |
| LDL/HDL Ratio | 2.2 | | 0 - 3.55 |

According to ATP III and NCEP guidelines

| Parameter | Normal | Desirable | Borderline | High |
|-------------------|--------------------------------------|-----------|------------|------|
| Total cholesterol | <200 | | 200-239 | 240 |
| Triglycerides | <150 | 150-199 | 200-499 | 500 |
| LDL | Optimal <100 Near Optimal 100-129 | 130-159 | 160-180 | 190 |
| HDL | <40 : LOW 60 : HIGH | | | |

ENDOCRINOLOGY

PSA TOTAL

Prostatic specific antigen, Total 0.32 ng/ml <4.0

| | |
|------------|--------------------|
| < 40 years | 0.21 to 1.72 ng/ml |
| 40 - 49 | 0.27 to 2.19 ng/ml |
| 50 - 59 | 0.27 to 3.42 ng/ml |
| 60 - 69 | 0.22 to 6.16 ng/ml |
| > 69 | 0.21 to 6.77 ng/ml |

Notes:

Checked By.

Dr. NITIN AGARWAL
M B B S , MD (Path)
DMC/R/01436

DR. NITIN AGARWAL
MBBS, MD(PATHOLOGIST)

47, Harsh Vihar, Pitampura, New Delhi-110034 | Ph.: 011-42480101, 9599913051

E-mail: oneplusul@gmail.com | Web.: www.oneplusul.in

Page 3 of 4



OnePLUS Ultrasound Lab

QUALITY FIRST... ALWAYS!

Dr. Nitin Agarwal
Pathologist & Director
Ex. Sr. Res. MAMC
& Lok Nayak Hospital
Ex. Chief of Lab Dr. Lal Path Labs.

Dr. Pooja (Garg) Agarwal
Radiologist & Director
MAMC & Lok Nayak Hospital



| | | | |
|-------------|-------------------------|-------------------|----------------------|
| NAME | :Mr. SUNIL SINGH | Barcode No | :10132421 |
| AGE/GENDER | :34 YRS/Male | SPECIMEN DATE | :26/Nov/2022 08:59AM |
| PATIENT ID | :105354 | SPECIMEN RECEIVED | :26/Nov/2022 09:09AM |
| REFERRED BY | :Dr. MEDIWHEEL | REPORT DATE | :26/Nov/2022 02:33PM |
| CENTRE NAME | :ONEPLUS ULTRASOUND LAB | LAB NO. | :012211260012 |

| Test Name | Result | Unit | Ref. Range |
|-----------|--------|------|------------|
|-----------|--------|------|------------|

PSA is principally produced by the glandular epithelium of the prostate, and is secreted in the seminal fluid. PSA is also present in urine and blood. PSA acts on seminal fluid to fluidify and increase sperm mobility. PSA levels rise in prostatic pathologies such as benign prostatic hyperplasia (BPH) or prostate cancer.

THYROID PROFILE(T3,T4,TSH)

| | | | |
|-----------------------------------|------|--------|------------|
| Triiodothyronine total [t3] | 0.72 | ng/dl | 0.52-1.9 |
| Thyroxine total [t4] | 7.40 | µg/dl | 4.4 - 10.8 |
| TSH (Thyroid Stimulating Hormone) | 3.40 | µIU/ml | 0.25-5.0 |

AGE WISE VARIATION IN TSH

| AGE | TSH(µIU/ml) | AGE | TSH(µIU/ml) |
|-----------|-------------|-----------------------------|-------------|
| 1-4 weeks | 1.00 - 19.0 | 16-20 yrs | 0.25 - 5.0 |
| 1-12 mths | 1.70 - 9.1 | 21 - 80 yrs | 0.25 - 5.0 |
| 1-5 yrs | 0.80 - 8.2 | I st trimester | 0.25 - 5.0 |
| 6-10 yrs | 0.25 - 5.0 | II nd trimester | 0.50 - 5.0 |
| 11-15 yrs | 0.25 - 5.0 | III rd trimester | 0.4 - 6.0 |

Reference ranges - Interpretation of Diagnostic tests - (Jacques Wallach)

1. Primary hypothyroidism is accompanied by depressed serum T3 and T4 values and elevated serum TSH level.
2. Primary hyperthyroidism is accompanied by elevated serum T3 and T4 levels along with depressed TSH values.
3. Slightly elevated T3 levels may be found in pregnancy and estrogen therapy, while depressed levels may be encountered in severe illness, renal failure and during therapy with drugs like propranolol and propyl thiouracil.
4. Although elevated TSH levels are nearly always indicative of primary hypothyroidism, and may be seen in secondary thyrotoxicosis

*** End Of Report ***

Checked By.

Dr. NITIN AGARWAL
M B B S . MD (Path)
DMC/R/01436

DR. NITIN AGARWAL
MBBS,MD(PATHOLOGIST)

47, Harsh Vihar, Pitampura, New Delhi-110034 | Ph.: 011-42480101, 9599913051

E-mail: oneplusul@gmail.com | Web.: www.oneplusul.in

Page 4 of 4



OnePLUS Ultrasound Lab

Dr. Nitin Agarwal
Pathologist & Director
Ex. Sr. Res. MAMC
& Lok Nayak Hospital
Ex. Chief of Lab Dr. Lal Path Labs.

Dr. Pooja (Garg) Agarwal
Radiologist & Director
MAMC & Lok Nayak Hospital



QUALITY FIRST... ALWAYS!

| | | | |
|-------------|-------------------------|-------------------|----------------------|
| NAME | :Mr. SUNIL SINGH | Barcode No | :10132421 |
| AGE/GENDER | :34 YRS/Male | SPECIMEN DATE | :26/Nov/2022 08:59AM |
| PATIENT ID | :105354 | SPECIMEN RECEIVED | :26/Nov/2022 01:28PM |
| REFERRED BY | :Dr. MEDIWHEEL | REPORT DATE | :26/Nov/2022 05:04PM |
| CENTRE NAME | :ONEPLUS ULTRASOUND LAB | LAB NO. | :012211260012 |

| Test Name | Result | Unit | Ref. Range |
|-----------|--------|------|------------|
|-----------|--------|------|------------|

CLINICAL PATHOLOGY

Health checkup 2 Male

URINE ROUTINE

Physical examination

| | | | |
|--------------|-------------|--|-------------|
| Quantity | 30 | | ML |
| Colour | PALE YELLOW | | |
| Transparency | CLEAR | | CLEAR |
| Sp.gravity | 1.015 | | 1.010-1.030 |
| pH | 6.00 | | |
| Reaction | ACIDIC | | ACIDIC |

Chemical examination

| | | | |
|------------------|----------|--|----------|
| Urine protein | NIL | | NIL |
| Urine sugar | NIL | | NIL |
| Bilirubin, urine | NEGATIVE | | NEGATIVE |
| Urobilinogen | NORMAL | | NORMAL |
| Ketones | NEGATIVE | | NEGATIVE |

Microscopic examination

Pus cells.

| | | | |
|------------------|-----|------|-----|
| Epithelial cells | 1-2 | /HPF | 0-2 |
| R.B.C. | 2-3 | /HPF | NIL |
| Casts | NIL | /HPF | NIL |
| Crystals | NIL | /HPF | NIL |
| Bacteria | NIL | /HPF | NIL |
| Others. | NIL | /HPF | NIL |

Physical examination

| | |
|--------|----------|
| Colour | BROWNISH |
|--------|----------|

STOOL ROUTINE

Checked By.

Dr. NITIN AGARWAL
M B B S, MD (Path)
DMC/R/01436

47, Harsh Vihar, Pitampura, New Delhi-110034 | Ph.: 011-42480101, 9599913051
E-mail: oneplusul@gmail.com | Web.: www.oneplusul.in

Page 1 of 2



OnePLUS Ultrasound Lab

Dr. Nitin Agarwal
Pathologist & Director
Ex. Sr. Res. MAMC
& Lok Nayak Hospital
Ex. Chief of Lab Dr. Lal Path Labs.

Dr. Pooja (Garg) Agarwal
Radiologist & Director
MAMC & Lok Nayak Hospital



QUALITY FIRST... ALWAYS!

| | | | |
|-------------|-------------------------|-------------------|----------------------|
| NAME | :Mr. SUNIL SINGH | Barcode No | :10132421 |
| AGE/GENDER | :34 YRS/Male | SPECIMEN DATE | :26/Nov/2022 08:59AM |
| PATIENT ID | :105354 | SPECIMEN RECEIVED | :26/Nov/2022 01:28PM |
| REFERRED BY | :Dr. MEDIWHEEL | REPORT DATE | :26/Nov/2022 05:04PM |
| CENTRE NAME | :ONEPLUS ULTRASOUND LAB | LAB NO. | :012211260012 |

| Test Name | Result | Unit | Ref. Range |
|---|-------------|------|-------------|
| Consistency | SEMI FORMED | | Semi Formed |
| Blood | ABSENT | | Absent |
| Mucus | ABSENT | | Absent |
| <u>Chemical examination, stool</u> | | | |
| pH | 6.00 | | |
| <u>Microscopic examination</u> | | | |
| Pus cells | 0-1 | /HPF | |
| R.B.C. | NIL | /HPF | NIL |
| Ova | NIL | | NIL |
| Cysts | NIL | | NIL |
| Bacteria | PRESENT | /HPF | NIL |
| Others | NIL | | |

*** End Of Report ***

Checked By.

Dr NITIN AGARWAL
M B B S , MD (Path)
DMC/R/01436

DR. NITIN AGARWAL
MBBS,MD(PATHOLOGIST)

47, Harsh Vihar, Pitampura, New Delhi-110034 | Ph.: 011-42480101, 9599913051
E-mail: oneplusul@gmail.com | Web.: www.oneplusul.in

Page 2 of 2

Clinical correlation is essential for final diagnosis. • If test results are unsatisfactory please contact personally or on phone. • This report is for perusal of doctors only.
• All disputes Subject to Delhi Jurisdiction only. • Not for medicolegal purposes. • All congenital anomalies in a foetus may not be diagnosed in routine obstetric ultrasound.

ONEPLUS ULTRASOUND LAB

47, HARSH VIHAR, PITAMPURA, DELHI- 110034

Mr. SUNIL SINGH
Age : 34/M
Ref. by : MEDIWHEEL
Indication1 :
Indication2 :
Indication3 :
COMMENTS : Sinus Tachycardia.

ID : 2049
HTWT : 181/65
Recorded : 26-11-2022 12:53
Medication1 :
Medication2 :
Medication3 :

BPM : 111
BP : 136/86
P Axis : 79 deg
QRS Axis : 65 deg
T Axis : 57 deg

P duration : 86 msec
PR duration : 126 msec
QRS duration : 103 msec
QT interval : 283 msec
QTc interval : 372 msec

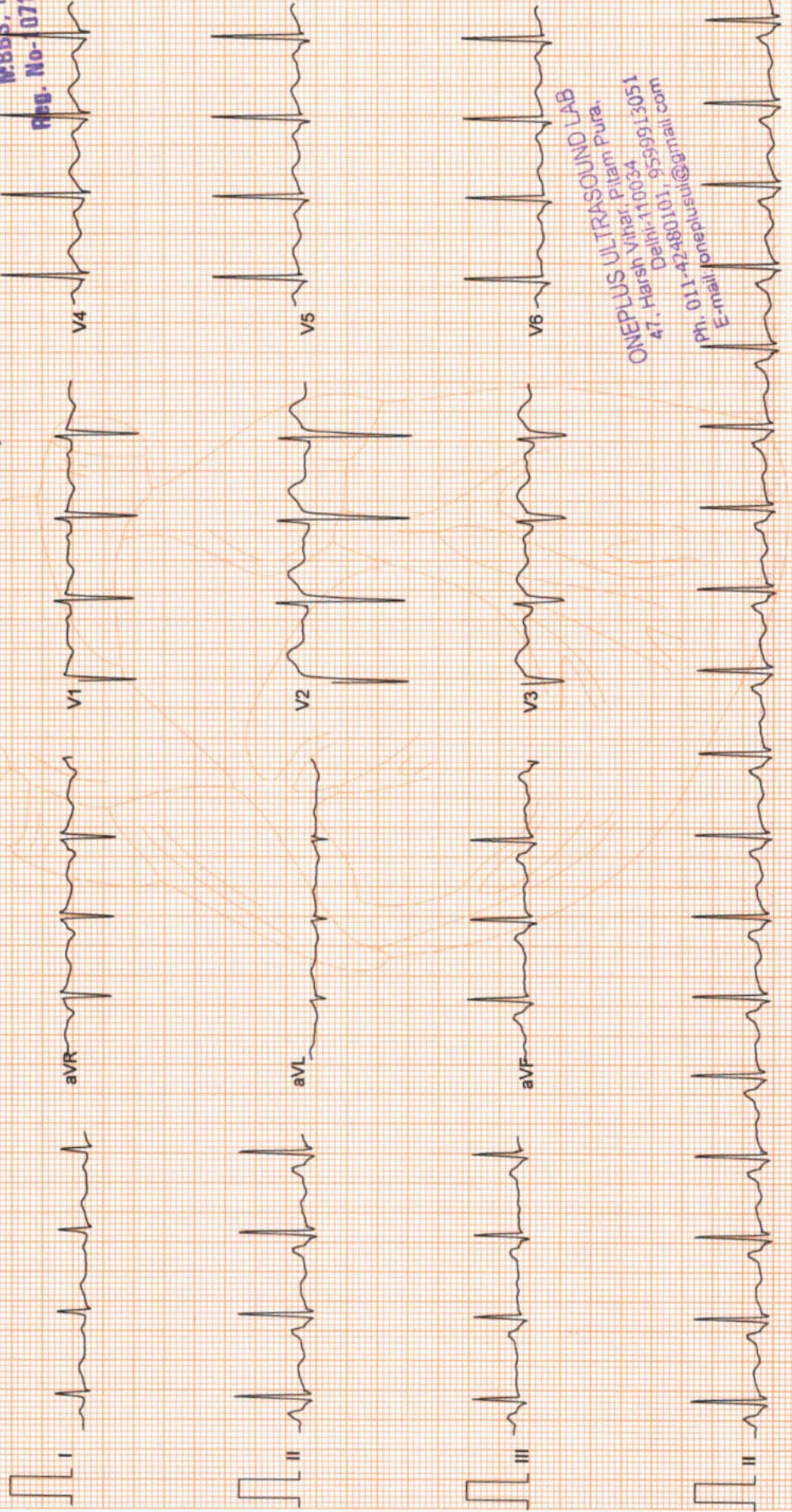
Raw E.C.G.(Seq)

Unconfirmed Report Reviewed By:

Cardiologist

SINUS

P.K. GUPTA
P.K. GUPTA
M.B.B.S, MD
RSG. No- 071



ONEPLUS ULTRASOUND LAB
Harsh Vihar Pitampura
Delhi-110034
Ph: 011-0110101, 9559913051
Email: @oneplusultrasound.com

ONEPLUS ULTRASOUND LAB

47, HARSH VIHAR PITAMPURA DELHI 110034

Mr. SUNIL SINGH
 Age/Sex : 34/M
 Ref. by : MEDIWHEEL
 Indication1 :
 Indication2 :
 Indication3 :

ID : 996
 Ht/Wt : 181/65
 Recorded : 26-11-2022 12:57

TREADMILL TEST SUMMARY REPORT
 Protocol: BRUCE
 History:
 Medication1 :
 Medication2 :
 Medication3 :

| PHASE | PHASE TIME | STAGE TIME | SPEED (Km./Hr.) | GRADE (%) | H.R. (BPM) | B.P. (mmHg) | RPP X100 | II | ST LEVEL (mm) V2 | V5 | METS |
|-----------------|------------|------------|-----------------|-----------|------------|------------------|------------|------------|------------------|------------|------|
| STANDING SUPINE | | | | | 111 112 | 136/86 136/86 | 150 152 | 0.8 0.8 | 2.4 2.4 | 0.9 0.9 | |
| STAGE 1 | 2:59 | 2:59 | 2.70 | 10.00 | 128 | 136/86 | 174 | 0.9 | 2.8 | 0.9 | 4.80 |
| STAGE 2 | 5:59 | 2:59 | 4.00 | 12.00 | 149 | 148/88 | 220 | 0.9 | 2.6 | 0.9 | 7.10 |
| STAGE 3 | 7:14 | 1:14 | 5.40 | 14.00 | 165 | 160/90 | 264 | 0.4 | 2.1 | 0.5 | 8.30 |
| PEAK EXER | 7:17 | 1:17 | | | 164 | 160/90 | 262 | 0.4 | 2.1 | 0.5 | 8.35 |
| RECOVERY | 2:59 | 2:59 | 0.00 | 0.00 | 119 | 136/86 | 161 | 0.6 | 2.0 | 0.6 | |

RESULTS

Exercise Duration : 7:17 Minutes
 Max Heart Rate : 165 bpm 88 % of target heart rate 186 bpm
 Max Blood Pressure : 160/90 mmHg
 Max Work Load : 8.35 METS

Reason of Termination : *negative for inducible ischemia*

IMPRESSIONS

.....

ONEPLUS ULTRASOUND LAB
 47, Harsh Vihar, Pitampura
 Delhi-110034
 Ph: 011-424280101, 9539913051
 Email: onepusul@gmail.com

[Signature]
Dr. P.M. GUPTA
 MBBS MD
 Cardiologist
 Reg. No. 1011

[Signature]

ONEPLUS ULTRASOUND LAB

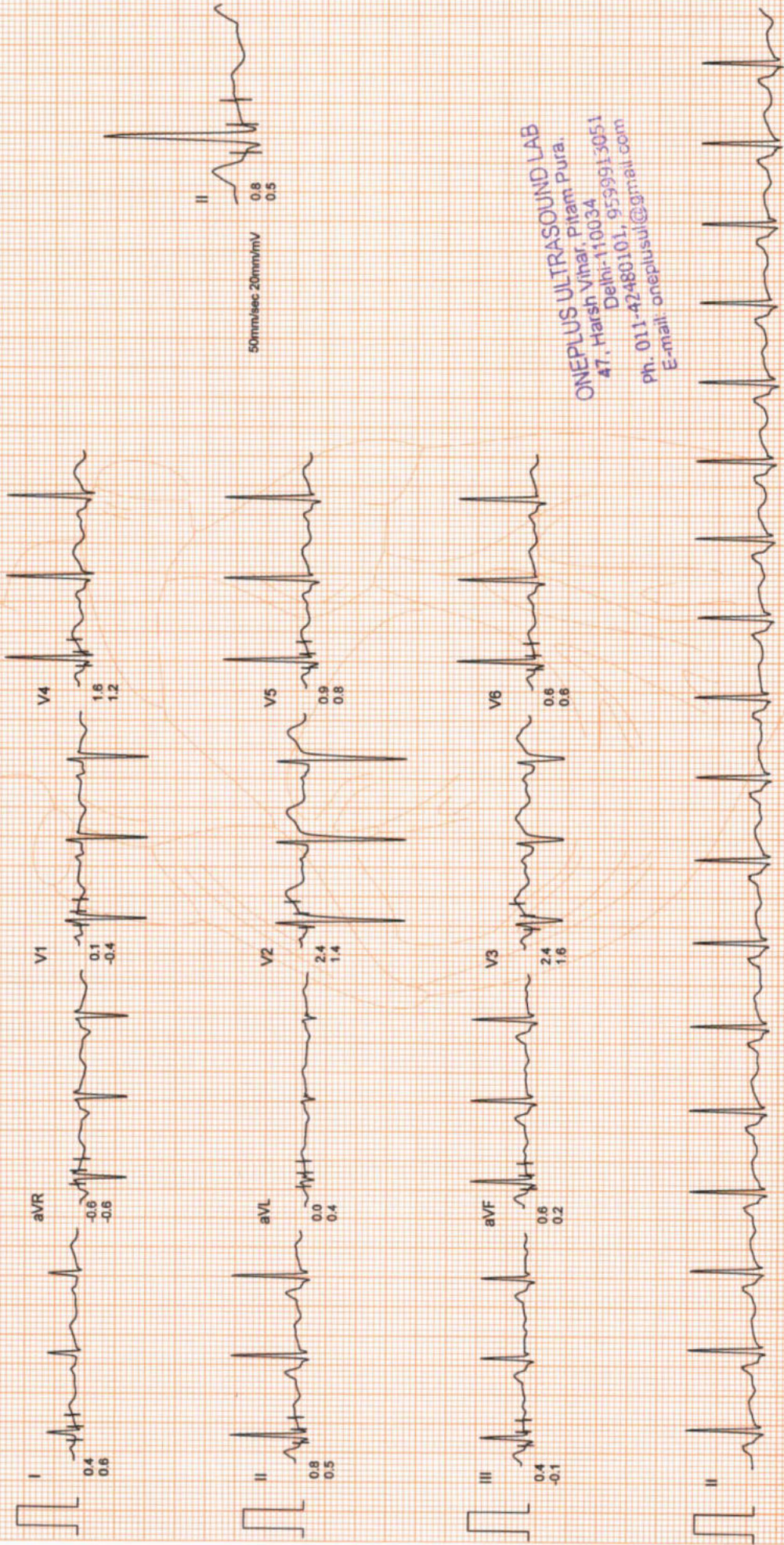
Mr. SUNIL SINGH
I.D. : 996
AGE/SEX : 34/M

STANDING
PRETEST

RECORDED : 26-11-2022 12:57
RATE : 111 BPM
B.P. : 136/86 mmHg

ST @ 10mm/mV
80ms PostJ

LINKED MEDIAN



ONEPLUS ULTRASOUND LAB

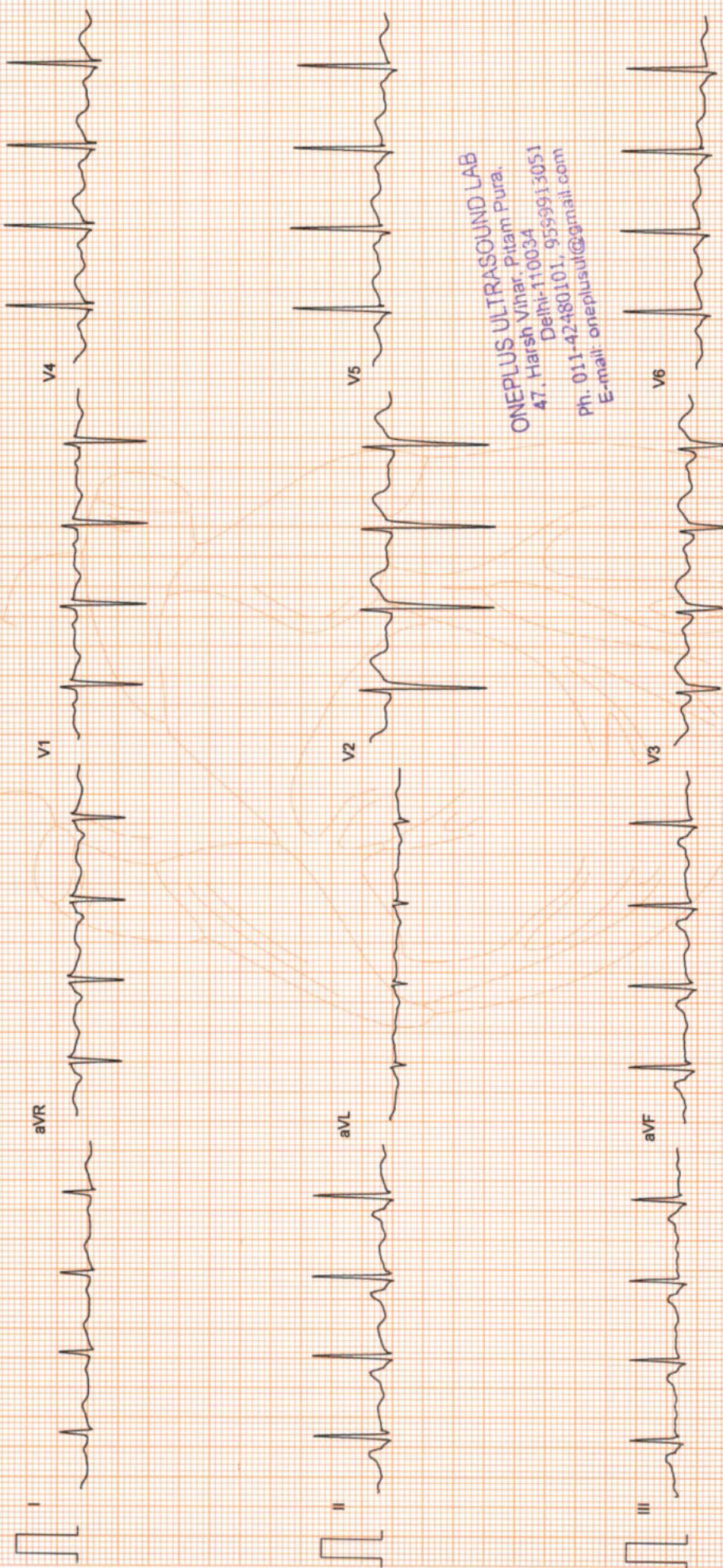
Mr. SUNIL SINGH
I.D. : 996
AGE/SEX : 34/M

RECORDED : 26-11-2022 12:57
RATE : 112 BPM
B.P. : 136/86 mmHg

ST @ 10mm/mV
80ms PostJ

SUPINE
PRETEST

RAW E.C.G.



ONEPLUS ULTRASOUND LAB
47, Harsh Vihar, Pitam Pura,
Delhi-110034
Ph. 011-42480101, 9559913051
E-mail: oneplusul@gmail.com

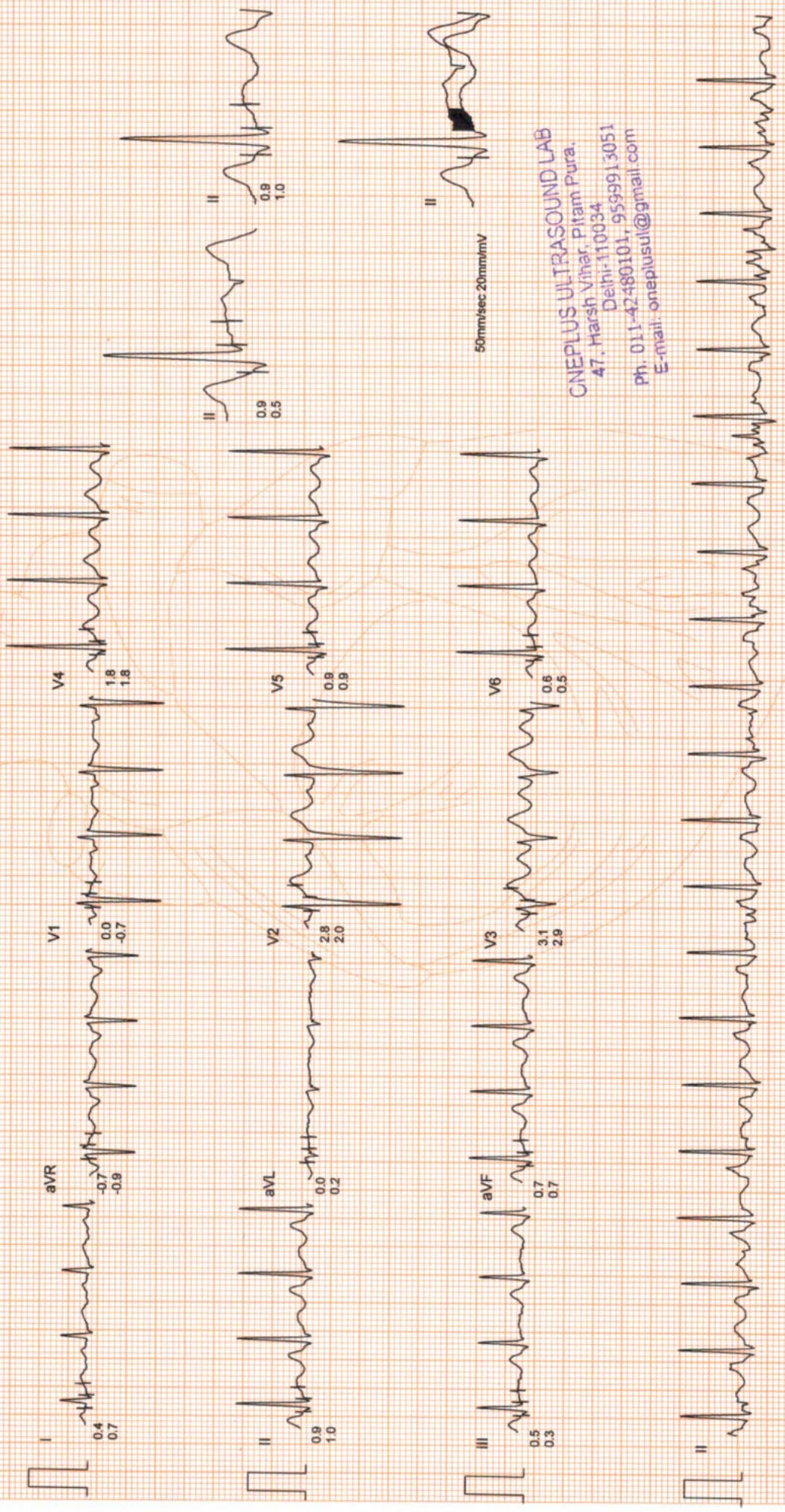
ONEPLUS ULTRASOUND LAB

Mr. SUNIL SINGH
 I.D. : 996
 AGE/SEX : 34/M
 RECORDED : 26-11-2022 12:57

RATE : 128 BPM
 B.P. : 136/86 mmHg

ST @ 10mm/mV
 80ms PostJ
 SPEED : 2.7 Km/Hr.
 GRADE : 10.0 %
 LINKED MEDIAN

BRUCE
 EXERCISE 1
 PHASE TIME : 2:59
 STAGE TIME : 2:59



50mm/sec 20mm/mV

CNEPLUS ULTRASOUND LAB
 47, Harsh Vihar, Pitam Pura,
 Delhi-110034
 Ph. 011-42480101, 9599913051
 E-mail: oneplusul@gmail.com

ONEPLUS ULTRASOUND LAB

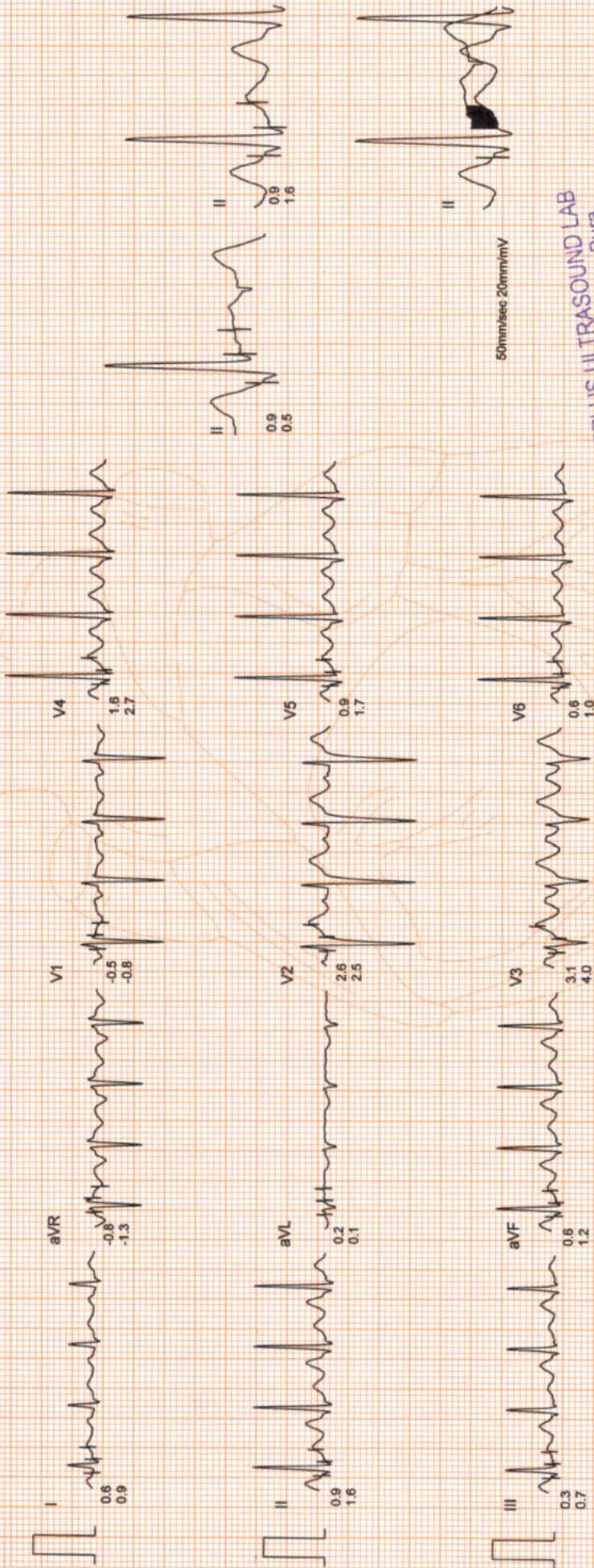
Mr. SUNIL SINGH
I.D. : 996
AGE/SEX : 34/M
RECORDED : 26-11-2022 12:57

RATE : 149 BPM
B.P. : 148/88 mmHg

BRUCE
EXERCISE 2
PHASE TIME : 5:59
STAGE TIME : 2:59

ST @ 10mm/mV
80ms PostJ
SPEED : 4.0 Km./Hr.
GRADE : 12.0 %

LINKED MEDIAN



ONEPLUS ULTRASOUND LAB
47, Harsh Vihar, Pitam Pura,
Delhi-110034
Ph. 011-42480101, 9599913051
E-mail: oneplusul@gmail.com

ONEPLUS ULTRASOUND LAB

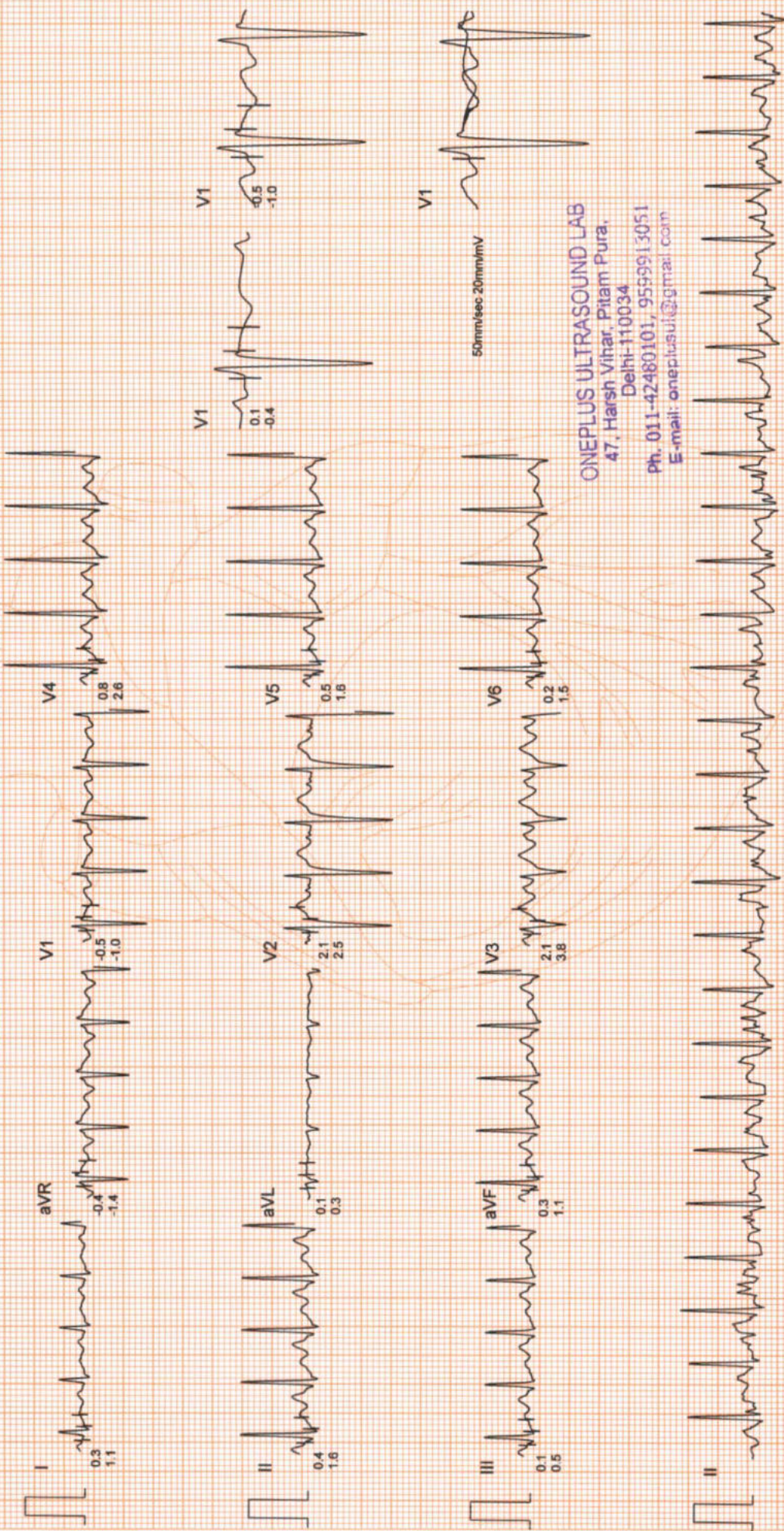
Mr. SUNIL SINGH
I.D. : 996
AGE/SEX : 34/M

RECORDED : 26-11-2022 12:57
RATE : 165 BPM
B.P. : 160/90 mmHg

BRUCE
EXERCISE 3
PHASE TIME : 7:14
STAGE TIME : 1:14

ST @ 10mm/mV
80ms PostJ
SPEED : 5.4 Km./Hr.
GRADE : 14.0 %

LINKED MEDIAN



ONEPLUS ULTRASOUND LAB
47, Harsh Vihar, Pitam Pura,
Delhi-110034
Ph. 011-42480101, 9599913051
E-mail: oneplusul@gmail.com

ONEPLUS ULTRASOUND LAB

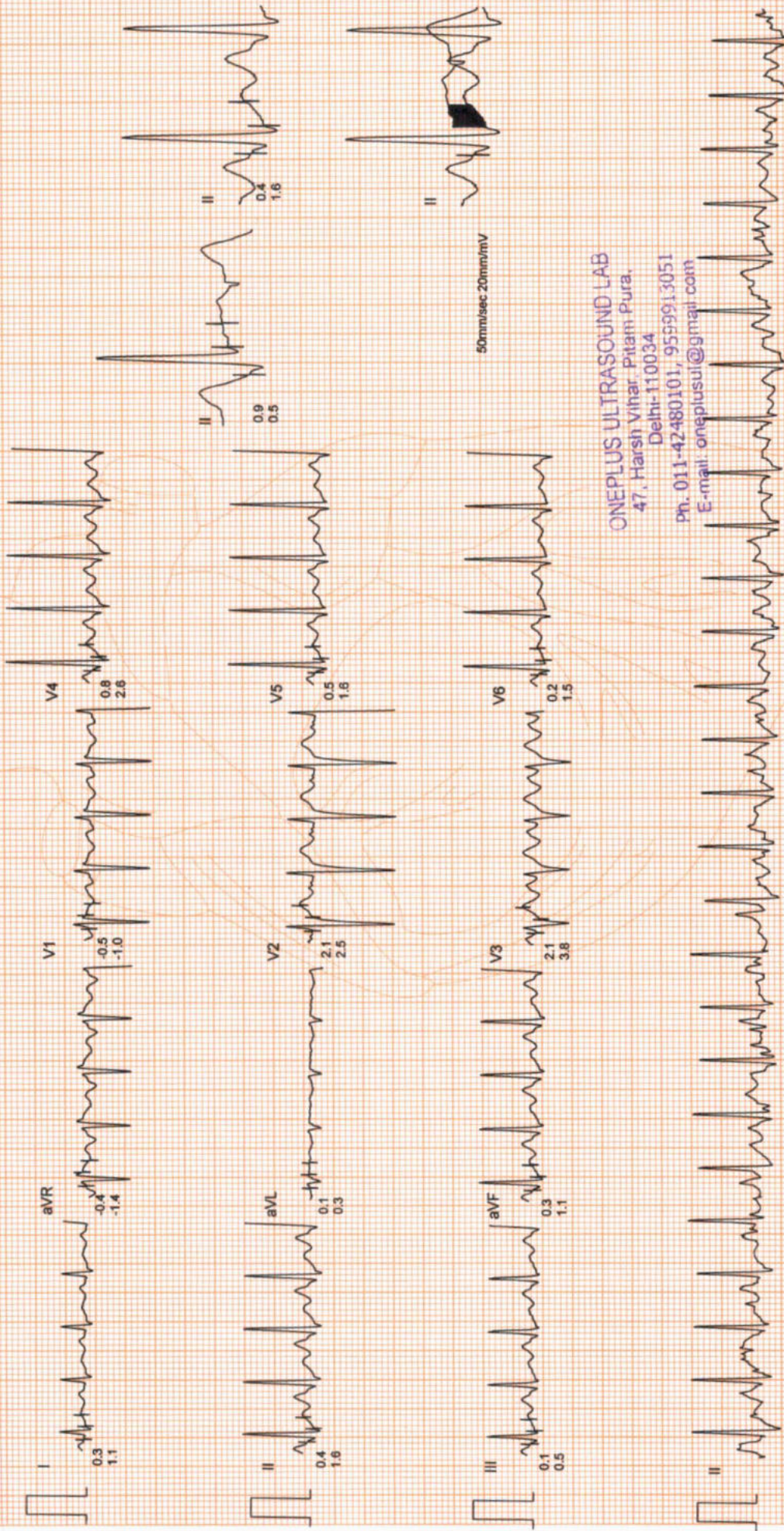
Mr. SUNIL SINGH
I.D. : 996
AGE/SEX : 34/M

RECORDED : 26-11-2022 12:57
RATE : 164 BPM
B.P. : 160/90 mmHg

BRUCE
PEAK EXER
PHASE TIME : 7:17
STAGE TIME : 1:17

ST @ 10mm/mV
80ms PostJ
SPEED : 5.4 Km./Hr.
GRADE : 14.0 %

LINKED MEDIAN



ONEPLUS ULTRASOUND LAB
47, Harsh Vihar, Pitam Pura,
Delhi-110034
Ph. 011-42480101, 9559913051
E-mail: oneplusul@gmail.com

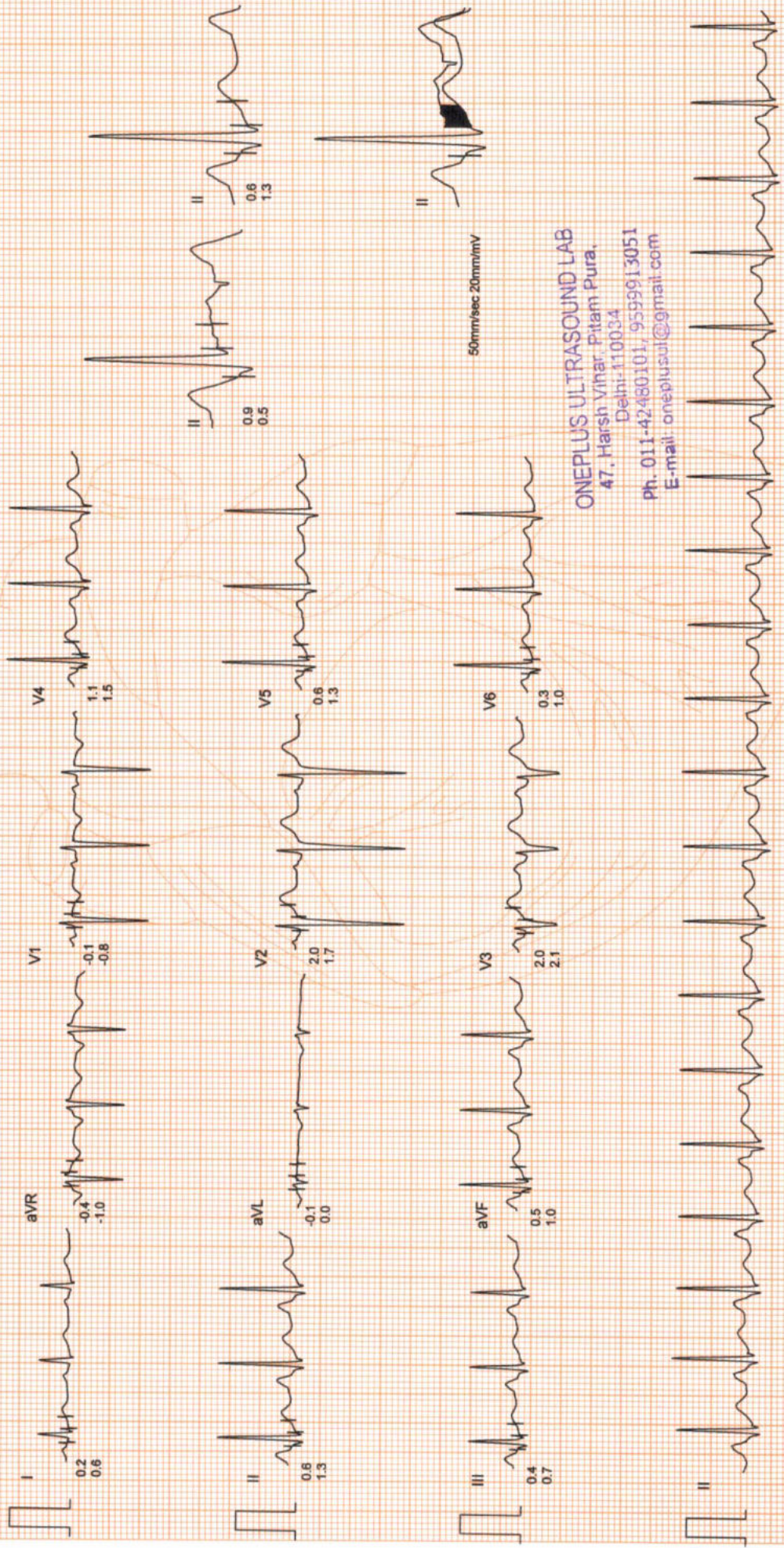
ONEPLUS ULTRASOUND LAB

Mr. SUNIL SINGH
I.D. : 996
AGE/SEX : 34/M

RECORDED : 26-11-2022 12:57
RATE : 119 BPM
B.P. : 136/86 mmHg

ST @ 10mm/mV
80ms PostJ
SPEED : 0.0 Km./Hr.
GRADE : 0.0 %

LINKED MEDIAN



50mm/sec 20mm/mV

ONEPLUS ULTRASOUND LAB
47, Harsh Vihar, Pitam Pura,
Delhi-110034
Ph. 011-42480101, 9599913051
E-mail: oneplusul@gmail.com

ONEPLUS ULTRASOUND LAB

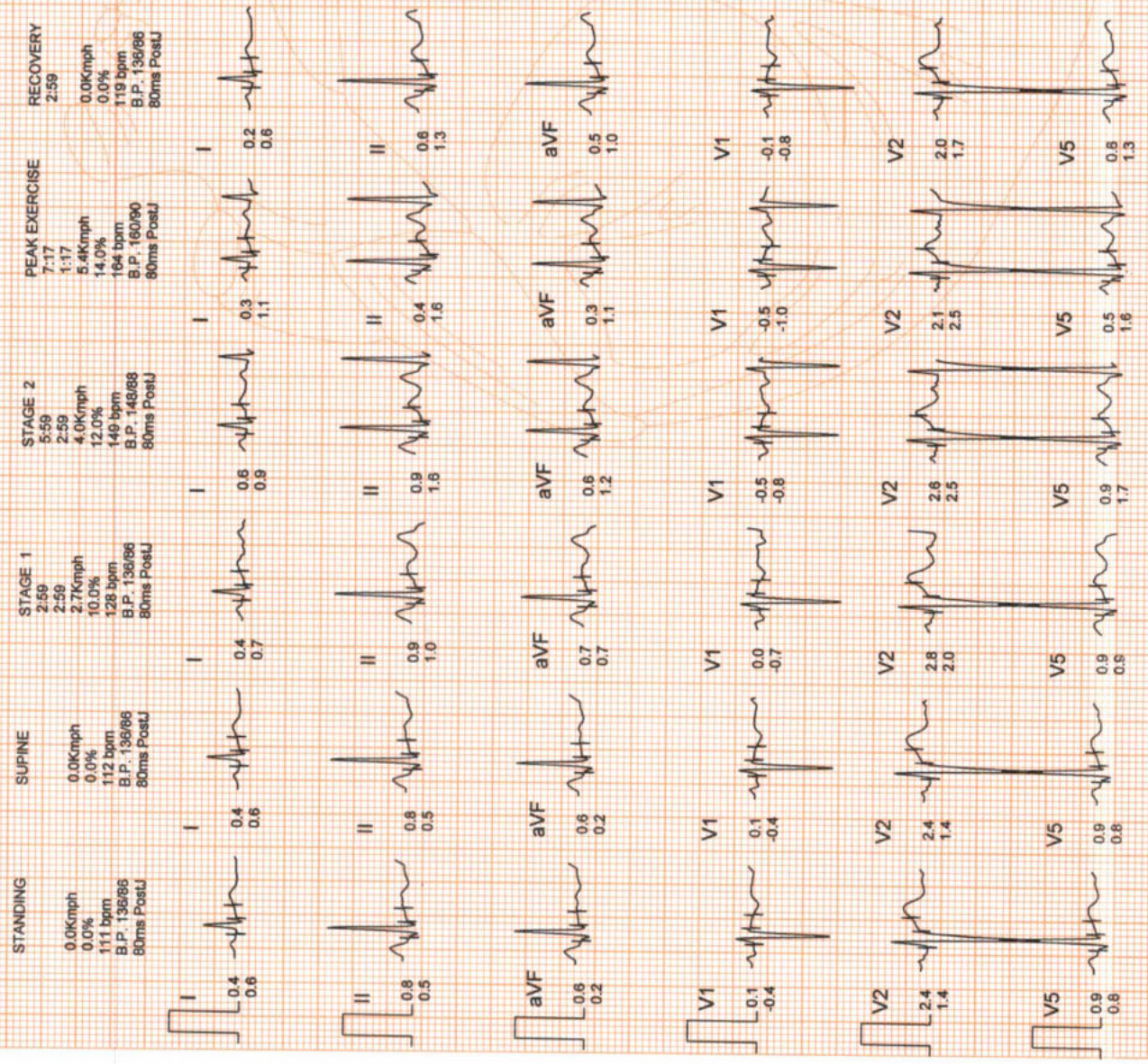
Mr. SUNIL SINGH

I.D. : 996

AGE/SEX : 34/M

RECORDED : 26-11-2022 12:57

AVG E.C.G.



ONEPLUS ULTRASOUND LAB
 47, Harsh Vihar, Pitam Pura,
 Delhi-110034
 Ph. 011-42480101, 9599913051
 E-mail: oneplusul@gmail.com

ONEPLUS ULTRASOUND LAB

AGE/SEX : 34/M

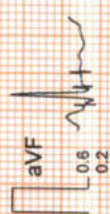
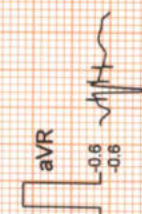

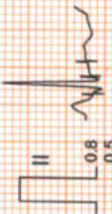

I.D. : 996

RECORDED : 26-11-2022 12:57

COMPARISON REPORT

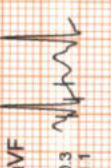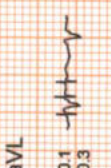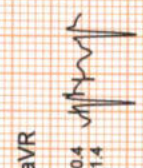
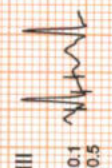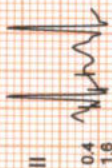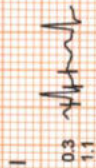SUPINE

0.0Kmph
0.0%
112 bpm
B.P. 136/86
80ms PostJ



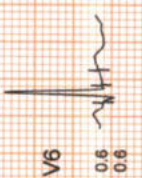
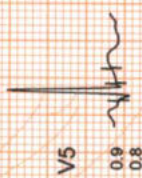
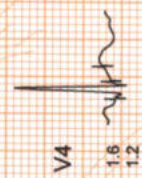
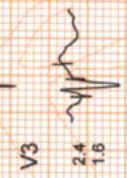
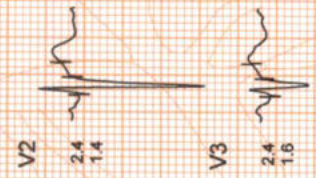
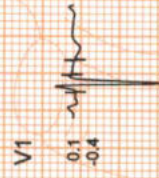
PEAK EXERCISE

7:17
1:17
5.4Kmph
14.0%
164 bpm
B.P. 160/90
80ms PostJ



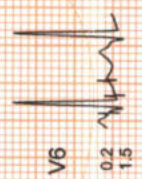
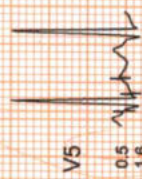
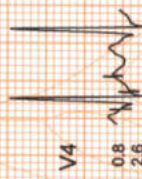
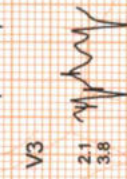
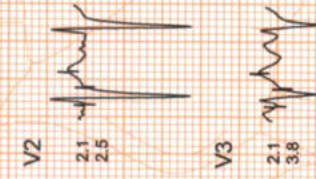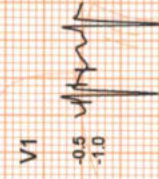
SUPINE

0.0Kmph
0.0%
112 bpm
B.P. 136/86
80ms PostJ



PEAK EXERCISE

7:17
1:17
5.4Kmph
14.0%
164 bpm
B.P. 160/90
80ms PostJ



ONEPLUS ULTRASOUND LAB

47, Harsh Vihar, Pitam Pura,

Delhi-110034

Ph. 011-42480101, 9599913051

E-mail: oneplusul@gmail.com



OnePLUS
Ultrasound Lab

— QUALITY FIRST... ALWAYS! —

Dr. Nitin Agarwal

Pathologist & Director
Ex. Sr. Res. MAMC
& Lok Nayak Hospital
Ex. Chief of Lab Dr. Lal Path Labs.

Dr. Pooja (Garg) Agarwal

Radiologist & Director
MAMC & Lok Nayak Hospital

| | | | |
|----------------|-------------------|-------------------|----------------|
| Name | : Mr. SUNIL SINGH | Age/Sex | : 34 YRS/Male |
| Ref. By | : Dr. MEDIWHEEL | Lab No | : 012211260012 |
| Date | : 26-Nov-2022 | Patient ID | : LSHHI105354 |

ULTRASOUND EXAMINATION----WHOLE ABDOMEN

Liver is normal in size (14.3 cm) and outline with normal echopattern. No abscess or mass lesion seen. Hepatic veins, portal vein, IVC and aorta are normal. Intrahepatic biliary radicles are not dilated. CBD is normal in caliber.

Gall bladder is well distended with anechoic lumen .Wall thickness is normal.

Both kidneys are normal in size, shape, position, outline and echopattern. Corticomedullary differentiation is maintained. No pelvicalyceal dilation or calculus or mass lesion is seen.

Spleen is normal in size and echotexture. No mass lesion seen.

Pancreas is normal in size, outline and echotexture .

Urinary bladder is normal in shape and position. No evidence of intravesical stone or mass seen.

Prostate is normal in size, shape and echopattern.

Prostate measures 4.4 x 3.2 x 2.4 cm. **Weight of prostate is 18.4 grams.**

No abnormal bowel wall thickening seen in right iliac fossa.

No free fluid seen anywhere in abdomen.

IMPRESSION: Normal Study.

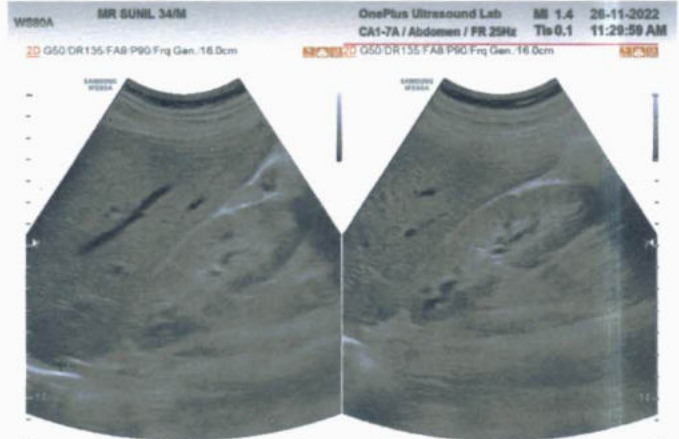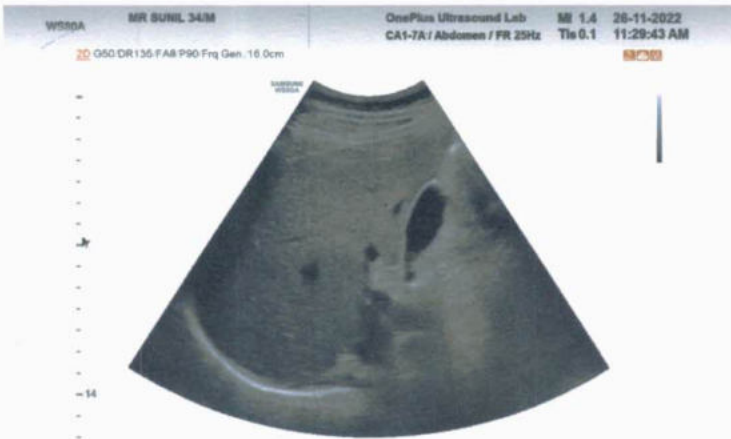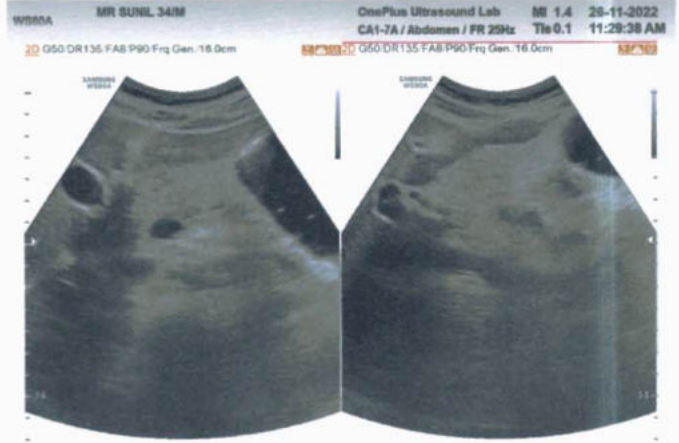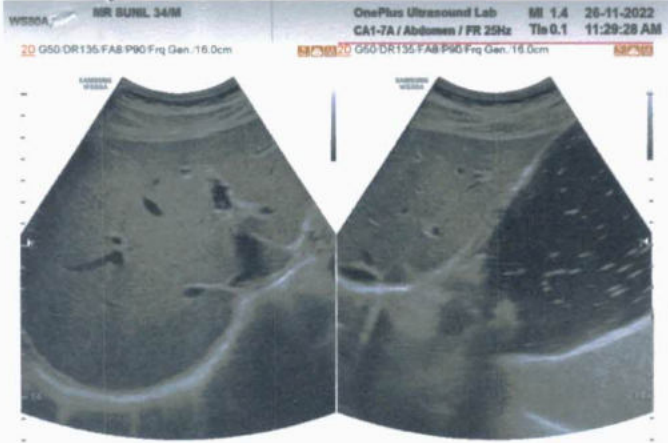DR. POOJA GARG
RADIOLOGIST
REG NO- DMC/R/03398

Dr. POOJA GARG
M.B.B.S., D.M.R.D.
Reg No. DMC/R/03398
Radiologist

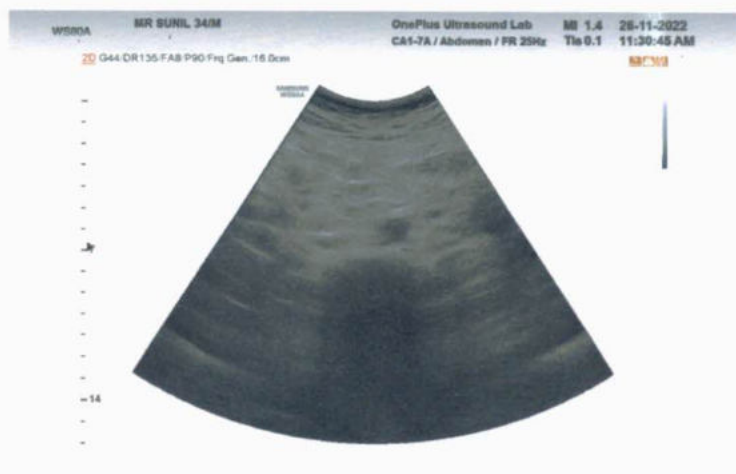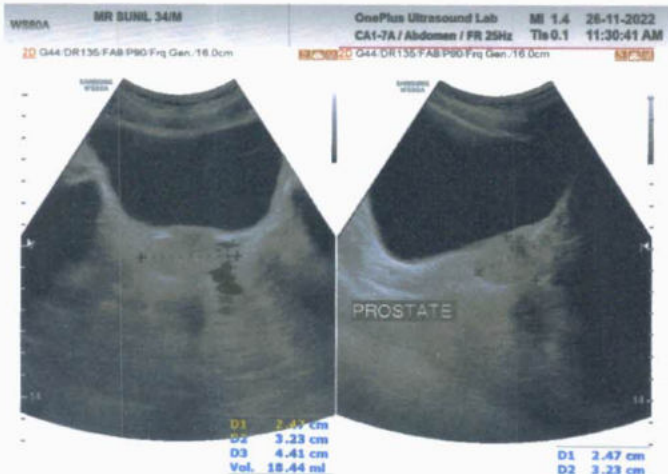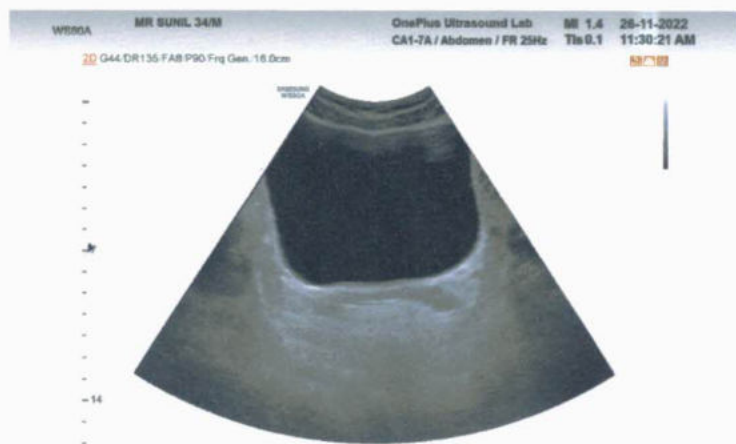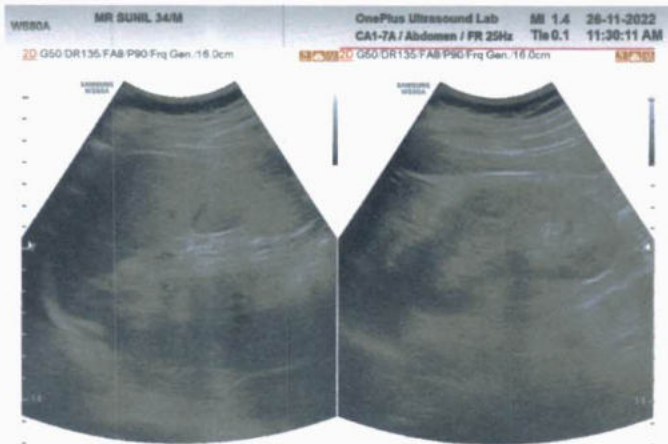Type By : darshita

47, Harsh Vihar, Pitampura, New Delhi-110034 | Ph.: 011-42480101, 9599913051

E-mail: oneplusul@gmail.com | Web.: www.oneplusul.in



D1 14.35 cm





OnePLUS
Ultrasound Lab
— QUALITY FIRST... ALWAYS! —

Dr. Nitin Agarwal

Pathologist & Director
Ex. Sr. Res. MAMC
& Lok Nayak Hospital
Ex. Chief of Lab Dr. Lal Path Labs.

Dr. Pooja (Garg) Agarwal

Radiologist & Director
MAMC & Lok Nayak Hospital

| | | | |
|----------------|-------------------|-------------------|----------------|
| Name | : Mr. SUNIL SINGH | Age/Sex | : 34 YRS/Male |
| Ref. By | : Dr. MEDIWHEEL | Lab No | : 012211260012 |
| Date | : 26-Nov-2022 | Patient ID | : LSHHI105354 |

X-ray-Chest PA view

Bony cage and soft tissues are normal.
Cardiothoracic ratio is normal.
Mediastinum is normal.
Both hila are normal.
Both costophrenic angles are clear.
Both domes of diaphragm are normal.
Lung fields are clear. No parenchymal lesion seen.

IMPRESSION: Normal Study.

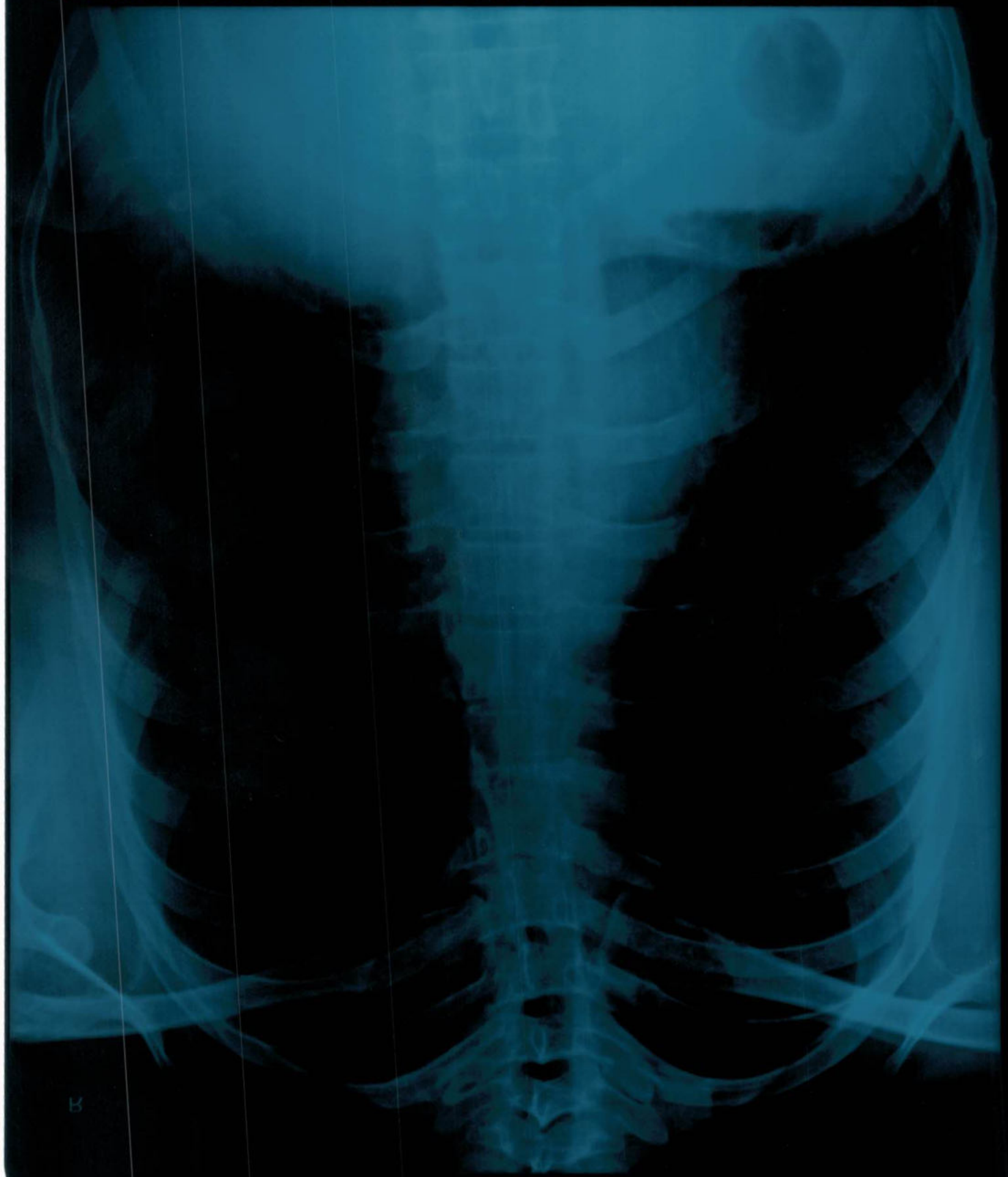DR. POOJA GARG
RADIOLOGIST
REG NO- DMC/R/03398

Dr. POOJA GARG
M.B.B.S., D.M.R.D.
Reg No. DMC/R/03398
Radiologist

Type By : darshita

47, Harsh Vihar, Pitampura, New Delhi-110034 | Ph.: 011-42480101, 9599913051
E-mail: oneplusul@gmail.com | Web.: www.oneplusul.in

WEI A TSE T A M M M CHEST PA VIEW
34 YRS 250217182 MB. SUNIG 210CH



R

R

MR. SUNIL SINGH 34 YRS 26/11/2022 M CHEST PA VIEW
ONEPLUS ULTRASOUND LAB,47-HARSH VIHAR,PITAMPURA