




भारत सरकार
Government of India

अजीक पायिदा
Abhik Pakhira
जन्म तिथि / DOB: 06/11/1987
पुरुष / MALE

5710 9483 4158

मेरा आधार, मेरी पहचान

Issue Date: 09/06/2015



Abhik Pakhira

 **भारतीय विशिष्ट पहचान प्राधिकरण**
Unique Identification Authority of India





प्लॉट नं 12 फ्लॉट 3बी, सड़क नं 83, समाहार इलाका के
साथ, एकाइ इलाका 1 न्यू टाउन, न्यू टाउन, नॉर्थ 24
पार्गना, वेस्ट बंगाल, 700156

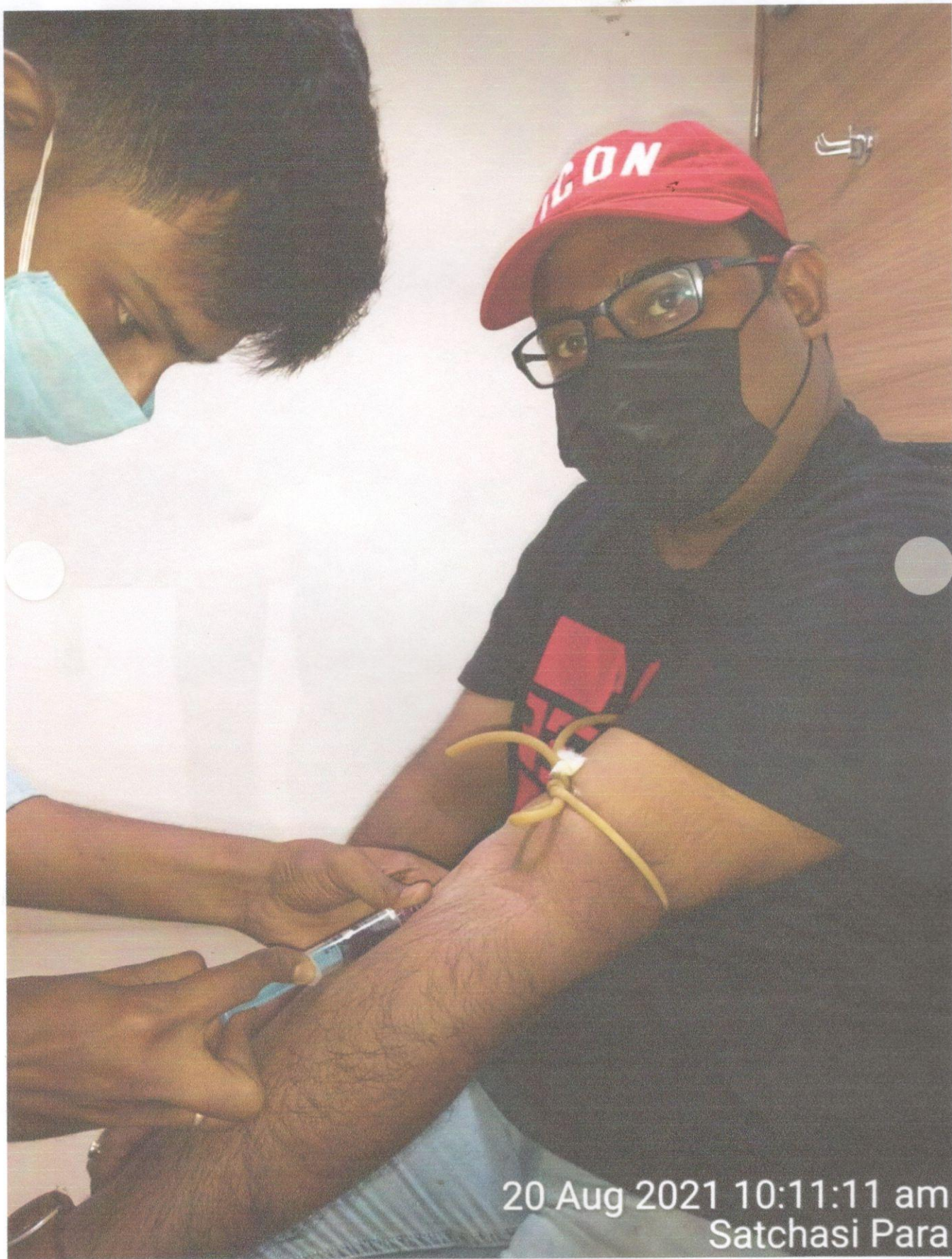Print Date: 09/05/2021

Address: AC12 FLAT 3B, STREET NO 43,
OPPOSITE TO SAMAHAR HOUSING,
ACTION AREA 1 NEWTOWN, New Town,
North 24 Parganas, West Bengal, 700156

 1947  help@uidai.gov.in  www.uidai.gov.in

5710 9483 4158

Signature



20 Aug 2021 10:11:11 am
Satchasi Para



20 Aug 2021 9:39:19 am

DR. ABHIRUP MUKHERJEE

BDS (WBUHS)
Oral & Dental Surgeon
Regn.No. 3726 Part A (Wbdc)

TO WHOM IT MAY CONCERN

THIS IS TO CERTIFY THAT **MR. ABHIK PAKHIRA,**
33Y/ MALE, HAS NO ORAL PROBLEM.

THERE IS NO CAVITY AND BAD SMELL OBSERVED IN HIS MOUTH.

DATE: 21.08.21.....

DR. ABHIRUP MUKHERJEE
BDS (WBUHS)
Oral & Dental Surgeon
Regn. No. 3726 Part A (WBDC)
A. Mukherjee

SIGNATURE

DC STAMP

APOLLO CLINIC OM TOWER
36C, B.T ROAD OPP "RBU"
KOL. 700002
Ph 033 25565555
033 25563333



DR. SOURADEEP RAY


MBBS, MS (ENT)
ASSOCIATE PROFESSOR R.G. KAR MEDICAL, KOLKATA.
REGD.NO. 63999 (WBMC)

TO WHOM IT MAY CONCERN

THIS IS TO CERTIFY THAT **MR. ABHIK PAKHIRA,**
33Y/ MALE,
HAS NO PROBLEM IN HIS EAR, NOSE AND THROAT.

HIS EAR IS CLEAN, NO HEARING PROBLEM.
HIS NASAL PASAGE IS CLEAR, WITH PROPER SMELLING CAPACITY.
HIS THROAT IS CLEAR, NO INFECTION FOUND IN TONSILS.

DATE: 21-08-21




SIGNATURE

DC STAMP

APOLLO CLINIC OM TOWER
36C, B.T ROAD OPP "RBU"
KOL 700002
Ph 033 25565555
033 25563333

APOLLO CLINIC @ OM TOWER
Opp. of Rabindra Bharati University
Licensee : Satyam Credit Pvt. Ltd.
36C, B.T. Road, Kolkata - 700 002
E-mail : sinthimor@theapolloclinic.com
satyamcreditpvtltd@gmail.com

 033 2556 3333

 033 2556 5555

 +91 98521 66666

 +91 74392 97827

DR. BOUDHAYAN BHATTACHARJEE

MBBS. (MEDICAL COLLEGE, KOLKATA) MD (TROPICAL MEDICINE)
CONSULTANT PHYSICIAN & INTENSIVIST REGN. NO. 65631WBMC

TO WHOM IT MAY CONCERN

THIS IS TO CERTIFY THAT, MR. ABHIK PAKHIRA,
33Y/ MALE IS PHYSICALLY FIT.

HIS ALL REPORTS ARE IN NORMAL RANGE.

DATE: 21.08.21

Dr. BOUDHAYAN BHATTACHARJEE
MBBS, MD (TROPICAL MEDICINE)
65631 of WBMC

Boudhayan Bhattacharjee

SIGNATURE

STAMP

APOLLO CLINIC OM TOWER
36C, B.T ROAD OPP "RBU"
KOL 700002
Ph 033 25565555
033 25563333



DEPARTMENT OF RADIOLOGY X-RAY OF CHEST (PA) VIEW

MR. NO- FSIN.0000000

SEX-MALE

NAME: -MR. ABHIK PAKHIRA

EXAMINATION DATE- 20/08/2021


AGE- 33 YRS

REPORT DATE- 20/08/2021

REF DR.: -SELF

FINDINGS:

- Bilateral lung fields are clear.
- Tracheal shadow is in the midline.
- Bilateral CP angle are clear
- Both hilum appear normal .
- CTR appears normal .
- No definite bone fracture is noted.



DR. ARNAB MANDAL

MD, Physician, PGDUS (Delhi) CEPT-USG (WBUHS KOLKATA)
Fellow of Jefferson Ultrasound Radiology and Education Institute
Philadelphia Ex-Radiology Resident (S.E. Railway)
Regd.No:72022(WBMC)

APOLLO CLINIC @ OM TOWER
Opp. of Rabindra Bharati University
Licensee : Satyam Credit Pvt. Ltd.

36C, B. T. Road, Kolkata - 700 002

E-mail : sinthimor@theapolloclinic.com
satyamcreditpvtltd@gmail.com



033 2556 3333



033 2556 5555



+91 98521 66666



+91 74392 97827

To
The Apollo Clinic
Sinthi more,

Respected Sir/Madam,

I do hereby declare that I have
not done USG willingly, with my full concern
and also TMT with my full concern.

Regards.
Abhir Pakeira.

Sumita Saha.
APOLLO CLINIC OM TOWER
36C, B.T ROAD OPP "RBU"
KOL 700002
Ph 033 25565555
033 25563333

Patient Name: Mr. ABHIK PAKHIRA 33/M

Resting ECG Report

August 20, 2021

QT / QTc : 0.260 / 0.277 Sec

PR Interval : 0.15 sec

RR Interval : 0.88 sec

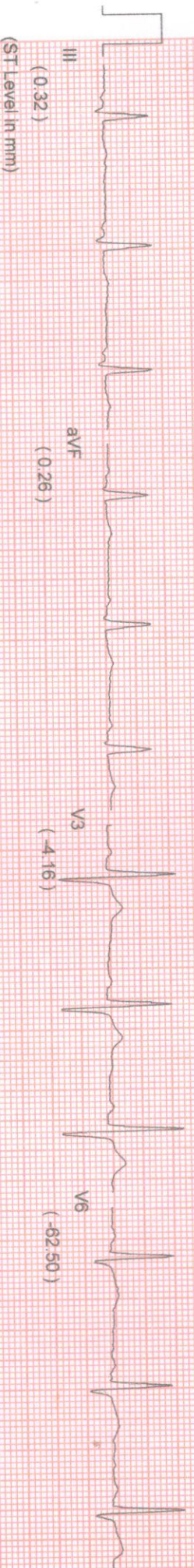
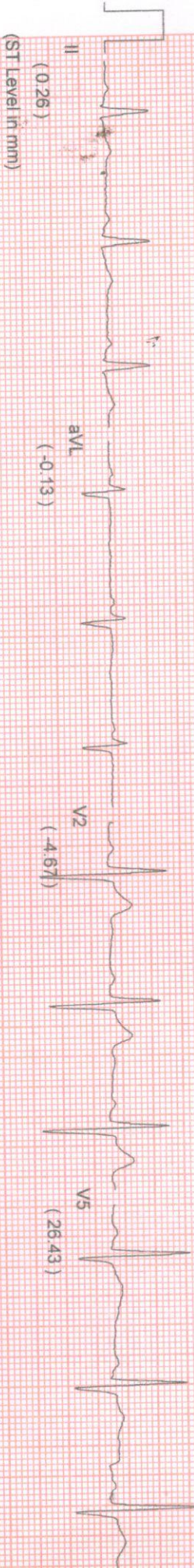
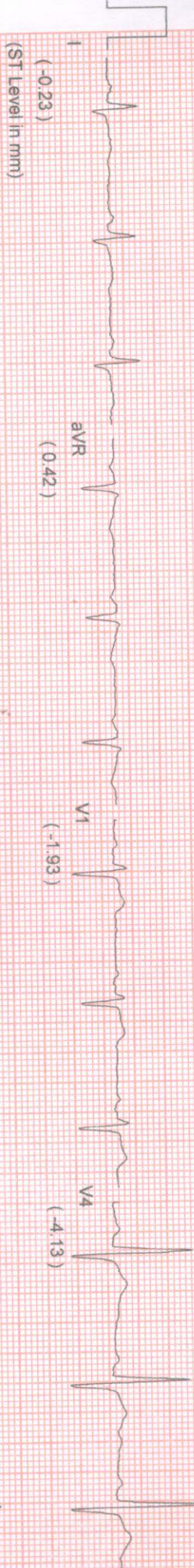
HR : 68 bpm

BP : 120 / 80 mmHg

Time: 11:45:31

P-QRS-T Axis (158),(48),(102) deg

QRS Duration : 0.120 Sec



Comments :-

Abhik Pakhira

NAME: MR. ABHIK PAKHIRA	MR NO: FSIN-0000	DATE : 20.08.2021
AGE: 33YRS.	SEX:MALE	REF BY: CORPORATE(SELF)

ECG REPORT

HR	:	68 b/min
AXIS	:	NORMAL
RHYTHM	:	SINUS
PR INTERVAL	:	0.15 sec
QT INTERVAL	:	0.277 sec
QRS DURATION	:	0.120 sec
T-WAVE	:	NORMAL

IMPRESSION:

- RESTING ECG IS WITHIN NORMAL LIMITS.



Dr. SIDDHARTHA KUNDU
MBBS (Cal), PGDCC, CCEBDM
Clinical Cardiologist
Ex Sr Resident, Cardiology Dept.
B.R Singh Hospital, Eastern Railway