



MEDICOVER
HOSPITALS

NAVI MUMBAI

MEDICAL CERTIFICATE

I, Dr. Ahmed Khan.....do hereby certify that I have carefully examined .

Sri./Smt. Vishal..... , son / daughter.

Of Nivruddi..... is physically fit / unfit to join Organization .

Signature of Doctor: [Signature].....

Registration No :

Place : Kharghar.....

Date : 08-05-24.....

Dr. AHMED KHAN
MBBS, MD (Internal Medicine)
Reg. No. MMC 2015/01/0236

Seal :





DEPARTMENT OF LABORATORY

NAVI MUMBAI

Patient Name : Mr. VISHAL NIVRUTTI JADHAV	Age /Gender : 39 Y(s)/Male
Bill No/ UMR No : NMBC69475/NMU0052767	Referred By : Dr. DMO
Received Dt : 08-May-24 09:58 am	Report Date : 08-May-24 02:55 pm

FINAL REPORT

<u>Parameters</u>	<u>Specimen</u>	<u>Result</u>	<u>Biological Reference Intervals</u>	<u>Method</u>
CUE(COMPLETE URINE EXAMINATION)				
<u>PHYSICAL EXAMINATION</u>				
VOLUME	Urine	30 ml		
COLOUR		PALE YELLOW	PALE YELLOW	
APPEARANCE		SLIGHTLY HAZY	CLEAR	
DEPOSIT		ABSENT	ABSENT	
<u>CHEMICAL EXAMINATION</u>				
SPECIFIC GRAVITY	Urine	1.015	1.000 - 1.030	Dipstick
PH		5.5	5.0 - 8.0	Dipstick
PROTEIN		NEGATIVE	NEGATIVE	Dipstick/Heat coagulation test
GLUCOSE		ABSENT	ABSENT	Dipstick/Benedict's test
UROBILINOGEN		NORMAL	NORMAL	Dipstick
KETONE		NEGATIVE	NEGATIVE	Dipstick/Rothera's Nitroprusside test.
BILIRUBIN		NEGATIVE	NEGATIVE	Dipstick/Fouchet's test
BILE SALT		NEGATIVE	NEGATIVE	Hay's sulphur powder test
BILE PIGMENT		NEGATIVE	NEGATIVE	Fouchet test
NITRITE		NEGATIVE	NEGATIVE	Dipstick
LEUCOCYTE ESTERASE		NEGATIVE	NEGATIVE	
<u>MICROSCOPIC EXAMINATION</u>				
PUS CELLS	Urine	4-5	0 - 5 /hpf	MICROSCOPIC EXAMINATION
RBC		1-2	0 - 5 /hpf	MICROSCOPIC EXAMINATION
EPITHELIAL CELLS		2-3	0 - 5 /hpf	MICROSCOPIC EXAMINATION
CRYSTALS		NIL	NIL	MICROSCOPIC EXAMINATION
CASTS		NIL	NIL	MICROSCOPIC EXAMINATION
BACTERIA		ABSENT		MICROSCOPIC EXAMINATION
YEAST		ABSENT		MICROSCOPIC EXAMINATION
AMORPHOUS DEPOSITS		ABSENT		MICROSCOPIC EXAMINATION
SPERMATOZOA				MICROSCOPIC EXAMINATION

NOTE

Microscopic examination of urine is carried out on centrifuged urinary sediment.

*** End Of Report ***





MEDICOVER
HOSPITALS

DEPARTMENT OF LABORATORY

NAVI MUMBAI

Patient Name : Mr. VISHAL NIVRUTTI JADHAV

Age / Gender : 39 Y(s)/Male

Bill No/ UMR No : NMBC69475/NMU0052767

Referred By : Dr. DMO

Received Dt : 08-May-24 09:58 am

Report Date : 08-May-24 02:55 pm

Parameters

Specimen

Result

Biological Reference In Method





DEPARTMENT OF LABORATORY

NAVI MUMBAI

Patient Name : Mr. VISHAL NIVRUTTI JADHAV	Age / Gender : 39 Y(s)/Male
Bill No/ UMR No : NMBC69475/NMU0052767	Referred By : Dr. DMO
Received Dt : 08-May-24 09:58 am	Report Date : 08-May-24 11:30 am

FINAL REPORT

<u>Parameter</u>	<u>Specimen</u>	<u>Result Values</u>	<u>Biological Reference</u>	<u>Method</u>
COMPLETE BLOOD COUNT				
RBC				
R B C COUNT	Blood	5.42	4.5 - 5.5 $10^6/\mu\text{L}$	
HEMOGLOBIN		16.2	13.0 - 17.0 g/dl	
PCV/HCT		48.4	40 - 50 % 36 - 46 %	
MCV		89	83 - 101 fl 83 - 101 fl	
MCH		29.9	27 - 32 pg	
MCHC		33.4	31.5 - 34.5 g/dL	
RDW(cv)		13.7	11.6 - 14.0 %	
PLATELETS				
PLATELET COUNT	Blood	234	150 - 400 $10^3/\mu\text{L}$	
MPV		8.3	7.5 - 11.5 fl	
WBC				
TC (TOTAL LEUCOCYTE COUNT)	Blood	6.0	4.0 - 11.0 $10^3/\mu\text{l}$	
DIFFERENTIAL COUNT				
NEUTROPHILS	Blood	57	40 - 80 %	
LYMPHOCYTES		37	20 - 40 %	
MONOCYTES		05	02 - 10 %	
EOSINOPHILS		01	00 - 06 %	
BASOPHILS		00	00 - 01 %	
ESR	CITRATED BLOOD	05	0 - 10 mm/1st hour	WESTERGREN'S METHOD
BLOOD GROUPING AND RH				
BLOOD GROUP		" B "		TUBE AGGLUTINATION
RH TYPE		POSITIVE		

*** End Of Report ***





MEDICOVER
HOSPITALS

DEPARTMENT OF LABORATORY

NAVI MUMBAI

Patient Name : Mr. VISHAL NIVRUTTI JADHAV	Age / Gender : 39 Y(s)/Male
Bill No/ UMR No : NMBC69475/NMU0052767	Referred By : Dr. DMO
Received Dt : 08-May-24 09:58 am	Report Date : 08-May-24 01:05 pm

Parameters

Specimen **Result**

TUBE AGGLUTINATI





DEPARTMENT OF LABORATORY

NAVI MUMBAI

Patient Name : Mr. VISHAL NIVRUTTI JADHAV	Age /Gender : 39 Y(s)/Male
Bill No/ UMR No : NMBC69475/NMU0052767	Referred By : Dr. DMO
Received Dt : 08-May-24 09:58 am	Report Date : 08-May-24 12:06 pm

FINAL REPORT

<u>Parameters</u>	<u>Specimen</u>	<u>Result</u>	<u>Biological Reference Intervals</u>	<u>Method</u>
FBS (FASTING BLOOD GLUCOSE)				
FASTING BLOOD GLUCOSE		101	Normal Range : 70 - 99 mg/dL	Hexokinase
SERUM CREATININE				
CREATININE		0.88	0.8 - 1.3 mg/dl	Method : jaffe
BUN(BLOOD UREA NITROGEN)				
BUN (Blood Urea Nitrogen.)		6	7.0 - 21.0 mg/dL	Calculated
SGPT (ALT)		48	<= 41 U/L	Method : UV without P5P
SERUM BILIRUBIN TOTAL		0.6	0.2 - 1.3 mg/dL	Jendrassik Grof
DIRECT BILIRUBIN		0.2	<= 0.20 mg/dL	Method: Diazo Method
INDIRECT BILIRUBIN		0.4	<= 1.0 mg/dL	
PLBS (POST LUNCH BLOOD GLUCOSE)		150	Norma Range : - < 140 mg/dL Impaired Glucose Tolerance : 140 - 199 mg/dL Diabetes Mellitus : - > 200 mg/dL	Hexokinase

*** End Of Report ***

Lab Incharge

(Signature)
Dr. VISHAL MEHROTRA, MD Pathology
Head, Laboratory Services

Verified By : : 026979

Test results related only to the item tested.

No part of the report can be reproduced without written permission of the laboratory.



Patient ID:	NMU0052767	Patient Name:	VISHAL NIVRUTTI JADHAV
Age:	39 Years	Sex:	M
Accession Number:	NMBC69475	Modality:	DX
Referring Physician:	DR.DMO	Study:	CHEST
Study Date:	08-May-2024		

X RAY CHEST PA VIEW

Both lungs are clear.

The frontal cardiac dimensions are normal.

The pleural spaces are clear.


Both hilar shadows are normal in position and density.

No diaphragmatic abnormality is seen.

The soft tissues and bony thorax are normal.

Impression:

- **No significant abnormality is seen.**



DR. SUYOG SANGALE
MBBS DMRE
CONSULTANT RADIOLOGIST

Date: 08-May-2024 10:10:26

39 Years

VISHAL JADHAV

Male

5/8/2024 9:48:07 AM

Rate 88 . Sinus rhythm.....normal P axis, V-rate 50- 99
 . Abnormal R-wave progression, early transition.....QRS area>0 in V2
 PR 144
 QRSD 82
 QT 377
 QTc 457

--AXIS--

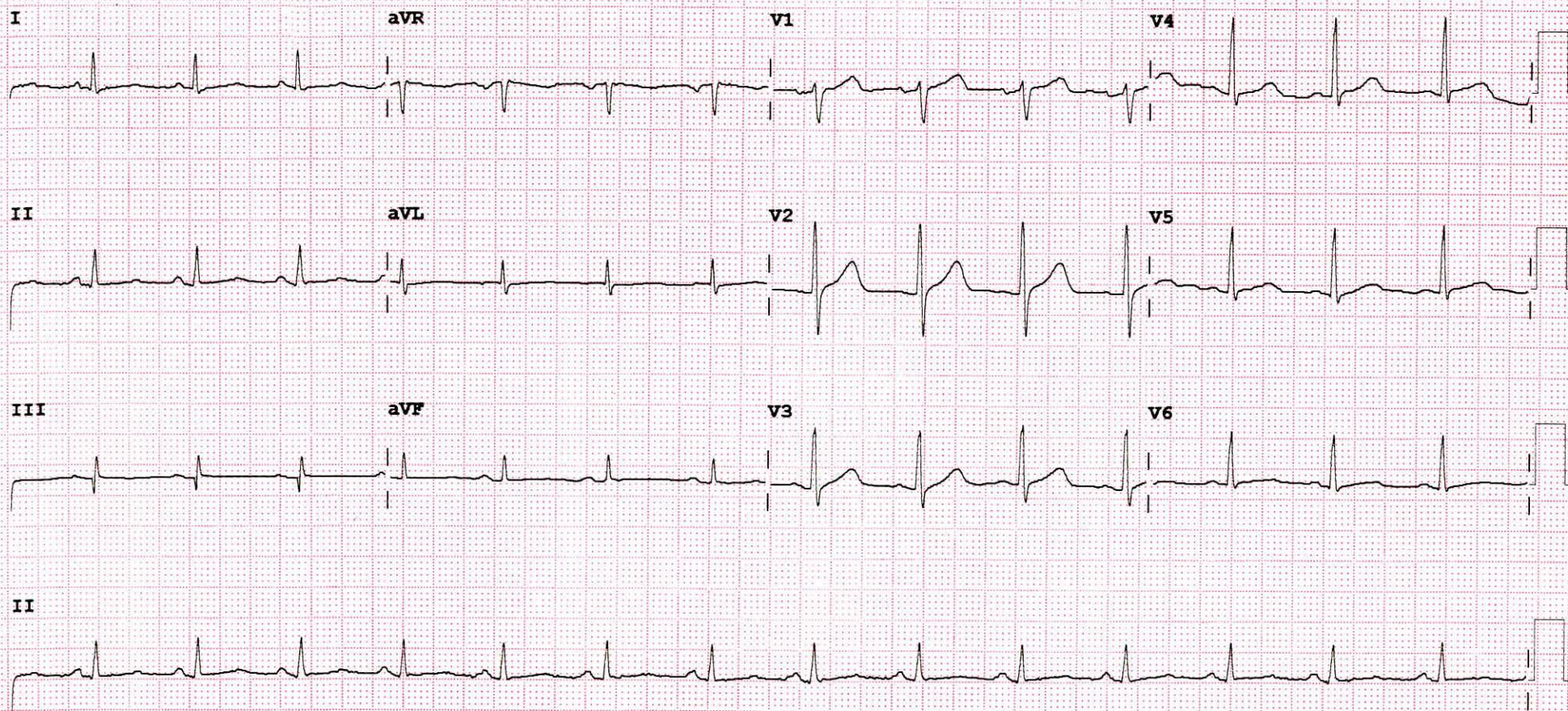
P 50
 QRS 46
 T 22

- OTHERWISE NORMAL ECG -

12 Lead; Standard Placement

Unconfirmed Diagnosis

MIR
S



Device: Speed: 25 mm/sec Limb: 10 mm/mV Chest: 10.0 mm/mV F 60~ 0.50~ 40 Hz W 100B CL P?



DEPARTMENT OF OPHTHALMOLOGY

MEDICOVER HOSPITALS

DATE: 08/05/24

PATIENT NAME: Mr Vishal Jadhav

AGE / SEX: 39 / m NAVI MUMBAI

UMR NO: NMU0052787

	RE	LE
VA (DISTANCE)	6/6	6/6
VA (NEAR)	N6 (Blur)	N6 (Blur)
COLOUR VISION	Normal	Normal

		SPHERE	CYLINDER	AXIS	VA	
MRx	O D	Plano	_____		6/6	Aden + 1.00 NG
	O S	Plano	_____		6/6	+ 1.00 NG

HISTORY :

- NO H/O spectacle use

- NO H/O DM, HTN, thyroid

- NO H/O ocular disease Allergies & surgeries.

OCULAR FINDINGS :

(BE) - Ant seg WNL

(indicated) Disc T 0.3
0.3

ADVICE:

Refresh Tears dd qid 1777 x 1 month

AS
CDR. ANUSHREE VAN KARK

