

PA Bld, urine, BMI, ECG, 2D-echo/TMI.
CXR, USG, Sonomamography
General physician, Eye, Dental, Dietician
Gynaec female
Pap-smear

Contact No: M

8275007701

Name/नाव : Mrs. Lata Madhukar Bhopre

Personal information (वैयक्तिक माहिती)

Age/ वय-

53

birth date/जन्मतारीख

01-06-1970

Any habit/सवयी

Identification Mark:-

NO

Any disease like diabetes, blood pressure, /आजार डायबिटीज, ब्लड प्रेशर, रक्तचाप — NO —

Any surgery/ operation/ accident during last 5 years/मागच्या 5 वर्षांत आजार किंवा अपघात — NO —

Family history/संबंधी माहिती

G8 A5 P3 L3

Father/वडील

Live/हयात

Age/वय

Disease/काही आजार

♀ 27
♀ 24
♀ 19

✓ Death/मृत

✓ Age When died/ मृत्युचे वय 78 Cause/कारण — old age —

Mother/आई

menopause ::
4 years.

Live/हयात

Age/वय

Cause/कारण

Age When died/ मृत्युचे वय 73 Cause/कारण — old age —

✓ Brother/भाऊ (3) Age/वय 70, 67, 55.

Disease/ health/ आजार/निर्गम — Diabetic

Sister/बहीण (2) Age/वय

→ 68 ⇒ Normal

Disease/health/आजार/निर्गम

→ 65 ⇒ Healthy

COVID VACCINE NAME

✓ 1st DOSE

✓ 2nd DOSE

EDUCATION S.B.C.

OCCUPATION House wife.

MARRIED — YES —

Signature: 

HOSPITAL USE ONLY

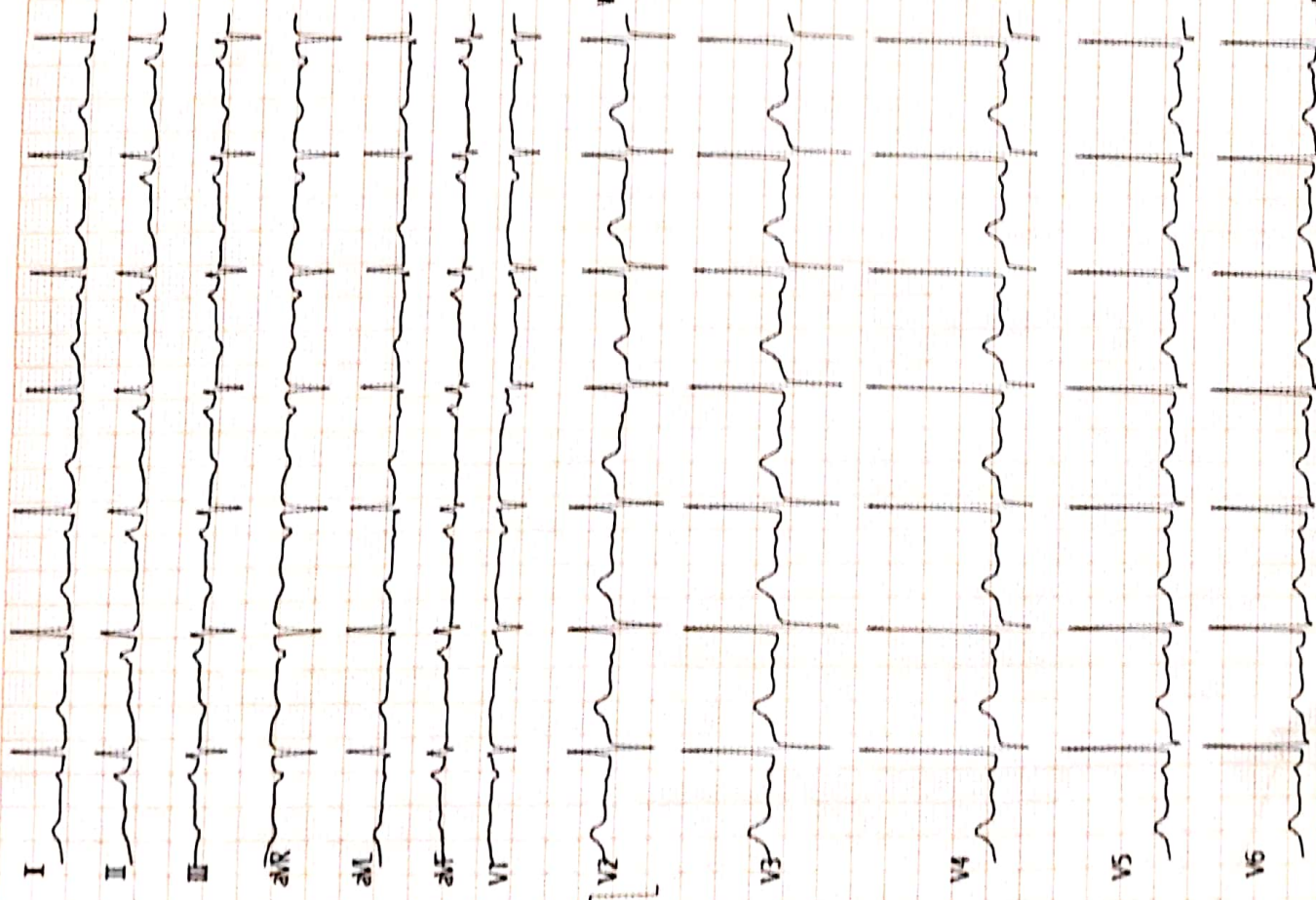
Height: 141

Weight: 58 kg

Chest: 60

Abdomen: 63

Blood Pressure: 132/82



(ECG Analysis Result):

Vent. Rate (bpm): 84

300 Normal Sinus Rhythm

PR Int. (ms): 132

203 Mild Left Axis Deviation

P-QRS/T Int. (ms): 94 94 134

*** Normal ECG ***

QT/QTc Int. (ms): 393 467

P-QRS/T Axis (Deg.): 75 14 10

RVL/SVL Amp. (mV): 0.07 0.16

RVS/SVS Amp. (mV): 1.57 0.38

Dr. Sunil Suresh
 Note: Unambiguously Report Need to Review
 M.D. (Medicine)
 Reg. No. 2222

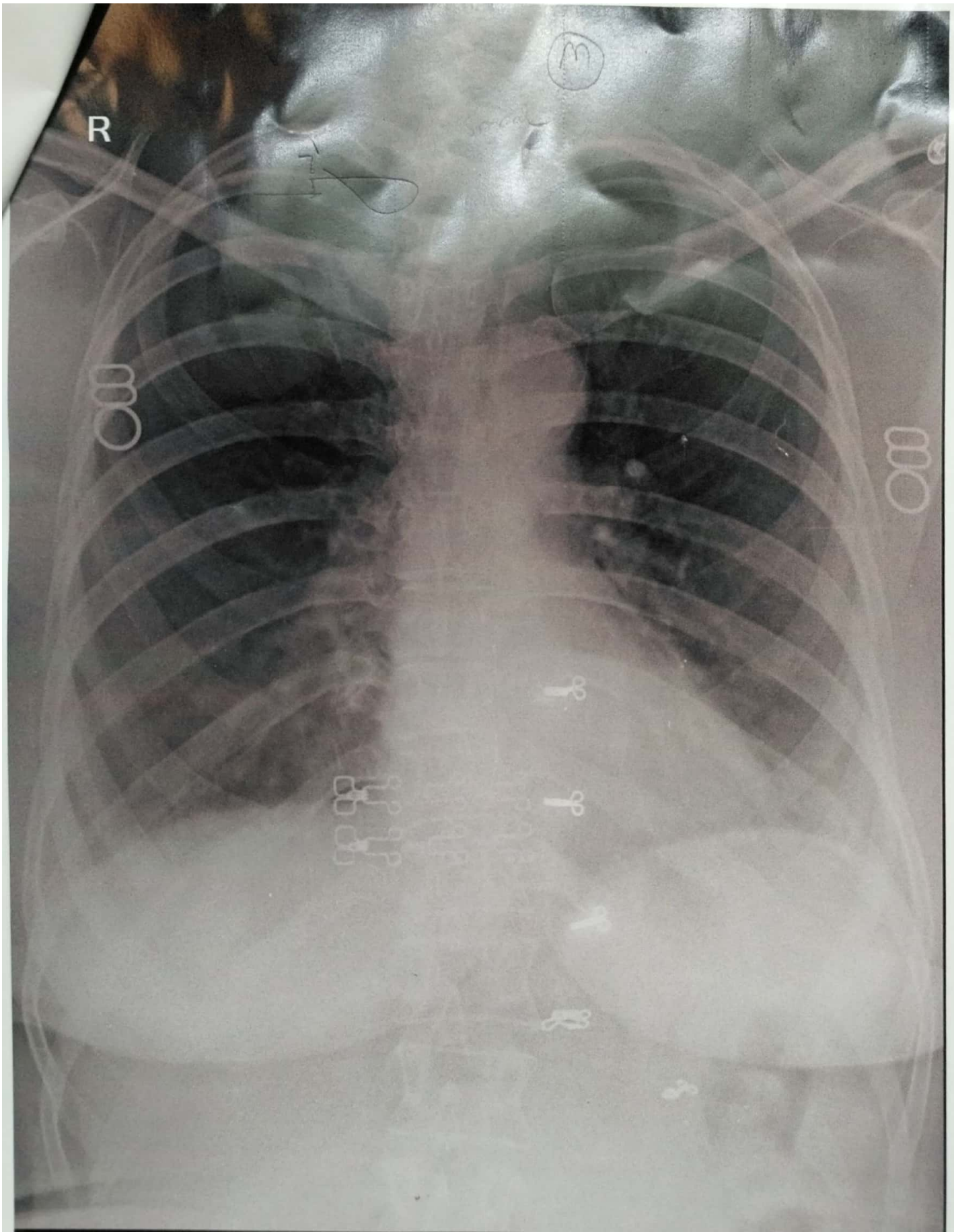
V2.35 Technician :

ST T/E (mV)

I	II	III	aR	aL	aF
-0.00	-0.01	-0.04	+0.04	+0.00	-0.00
V1	V2	V3	V4	V5	V6
-0.01	-0.02	+0.00	-0.04	-0.02	-0.02



25mm/s ACS0 ECG AUS 2023-12-11 09:47:40 <AIA B0PE > 3740003528 F 52Y 147/58 cm/A5 125/79 mmHg
 SUNAY HOSPITAL PM
 UNI-CARD ENTERPRISES PH NO. 9822002652



LATA BHOPE 52Y 1112202301 CHEST PA 11-Dec-23

SUJAY HOSPITAL AND MATERNITY HOME, JALGAON

सुजय हॉस्पिटल व मॅटर्निटी होम

अतिदक्षता विभाग

डॉ. सौ. जयश्री सुर्यवंशी
एम.बी.
(स्त्रीरोग व प्रसूतीशास्त्र तज्ञ)
रजि.नं. 3712

डॉ. सुनिल सुर्यवंशी
एम.बी. (मेडिसीन) एफो
कन्सल्टिंग फिजिशियन
रजि.नं. 2223

घरणा : गैंग वेलिफोन एक्सचेंज सभौर, पारिख
पार्क जवळ, नविन बस स्टॅन्डच्या मागे,
जळगाव. फोन : (0257) 2227821

उपलब्ध सुविधा : • एक्स रे • सोनोग्राफी • इकोकार्डिओग्राफी • सुरुज्य ऑपरेशन थिएटर • कॉम्प्युटराईज्ड व्ही.सी.जी. • एड्स टेस्ट • पल्सोमीट्री फॅक्शन टेस्ट

R

दि / /

(-RAY CHEST PA VIEW

NAME- LATA BHOPE

AGE- 52 YRS FEMALE DATE- 11.12.23

SOFT TISSUE AND SKELETON NORMAL.

BOTH HILA ARE NORMAL IN SIZE AND HAVE EQUAL DENSITY.

NORMAL CARDIAC SIZE.

NORMAL BRONCHOVASCULAR MARKINGS.


COSTOPHRENIC AND CARDIOPHRENIC ANGLES ARE CLEAR.

THE DOMES OF DIAPHRAGMS ARE NORMAL IN POSITION AND SHOW SMOOTH OUTLINE.

THE PLURAL SPACES ARE NORMAL.

IMPRESSION -

NORMAL XRAY CHEST


Dr. Sunil Suryawanshi
M.D. (Medicine)
Reg. No. 2223

परत येतांना कागद सोबत आणावा.



DR. CHETAN S. KAKLIYA

M.B.B.S., D.M.R.D. (Sion Hospital, Mumbai University)

• Ex-Consultant Radiologist In Asian Heart Hospital (Mumbai)

• Ex - Radiologist Wockhardt Hospital (Mulund)

SAGAR IMAGING CENTRE

• Whole body sonography • Colour doppler • Digital X-ray

54-B, Onkar Nagar, Near Parikhpark, Jalgaon - 425001. Phone : 0257-2237634, e-mail : drchetanjj@rediffmail.com

Name	: LATA BHOPE	Date	: 11-12-2023
Ref By	: SUJAY HOSPITAL	Age/Sex	: 52 / Female

SONOGRAPHY OF ABDOMEN AND PELVIS

The liver is normal in size, shape and has smooth margins. No focal lesion. The portal vein appears normal.

The gall bladder is partially distended. No evidence of calculus, wall thickening or mass lesion.

The common bile duct is normal in caliber. No evidence of calculus is noted in common bile duct.

The pancreas is normal in size, shape and echotexture. No focal lesion is noted.

The spleen is normal in size and shape. No evidence of focal lesion is noted.

There is no evidence of enlarged coeliac, mesentric, portal pre or para aortic lymph nodes. No vascular mass lesion. No evidence of ascitis or pleural effusion.

Both kidneys are normal in size and echotexture. No evidence of calculus, hydronephrosis or cortical scarring.

Right renal cortical cyst is noted measures 31 x 26 mm at mid pole.

Right kidney measures - 9.8 x 4.2 cms.

Left kidney measures - 10.8 x 4.8 cms.

The urinary bladder is well distended. No evidence of calculus, wall thickening or mass lesion.

Uterus is normal size measures 6.2 x 4.2 x 3.5 cms and no focal lesion is noted. **Lower uterine segment at posterlor wall show hypochoic lesion measures 33 x 25 mm.....fibroid likely.**
The endometrium is thin and appears normal.

Both adnexa are clear. Both ovaries are normal for age. No evidence of free fluid or mass in pouch of Douglas.

IMPRESSION:

Uterine fibroid.

Right renal clear cortical cyst

REPORT WITH THANKS.

Clinico pathological correlation is suggested.

DR.CHETAN KAKLIYA

DR. CHETAN S. KAKLIYA

MB.B.S., D.M.R.D. (Sion Hospital, Mumbai University)

• Ex-Consultant Radiologist In Asian Heart Hospital (Mumbai)

• Ex - Radiologist Wockhardt Hospital (Mulund)



SAGAR IMAGING CENTRE

• Whole body sonography • Colour doppler • Digital X-ray

54-B, Onkar Nagar, Near Parikhpark, Jalgaon - 425001. Phone : 0257-2237634, e-mail : drchetanj@rediffmail.com

Name	:	LATA BHOPE	Date	:	11-12-2023
Ref By	:	SUJAY HOSPITAL	Age/Sex	:	52 / Female

SONOGRAPHY OF BREAST

The skin is seen as homogenous echogenic band. The skin thickness is normal.

The nipple is visualised as well defined nodul, causing distal attenuation of sound beam. The sub areolar tissue is normal. The lactiferous duct is well visualised and is normal in caliber.

The subcutaneous fibro fatty tissue shows normal echo texture and is normal in thickness. There is no evidence of dilated lymphatics.

There is no evidence of enlarged intramammary lymph nodes.

The retromammary region consisting of fat ribs, and muscles is normal.

The axillary fat shows normal thickness and echo texture.

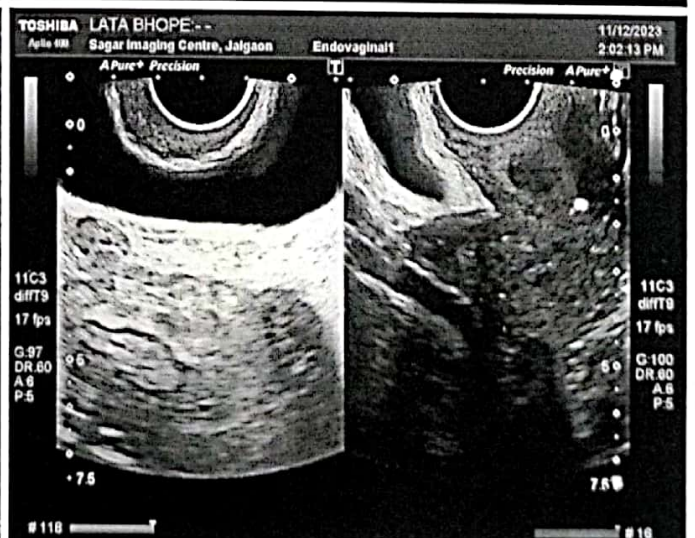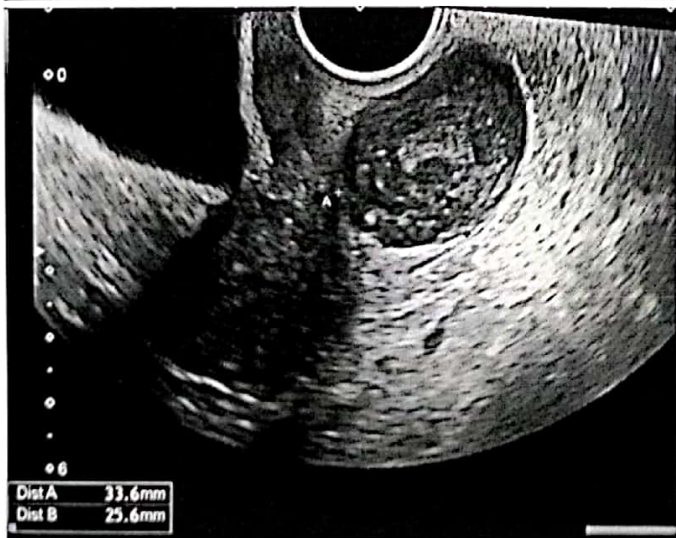
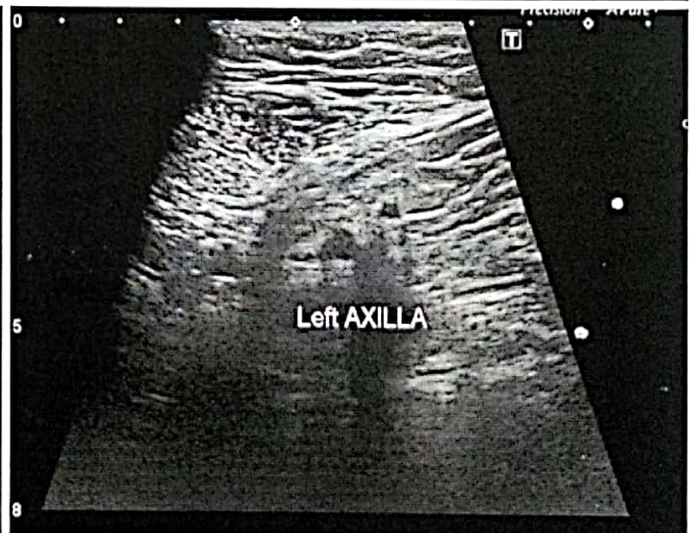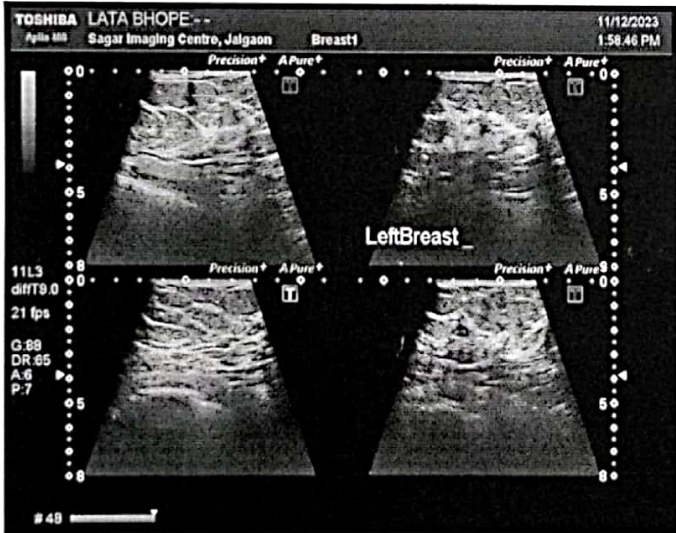
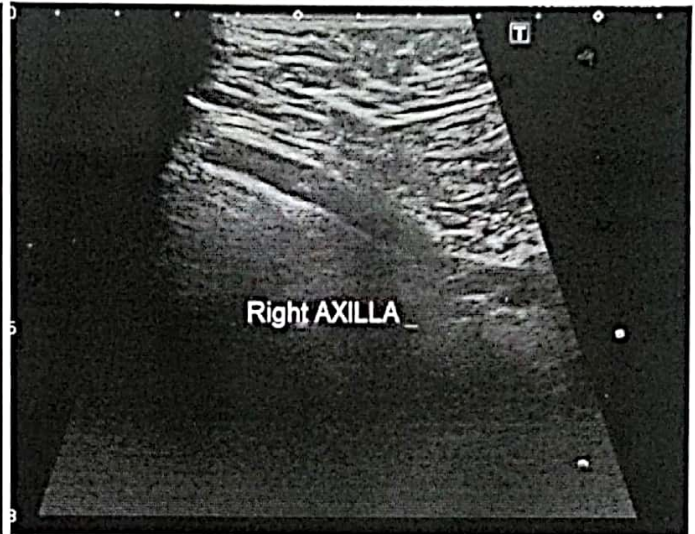
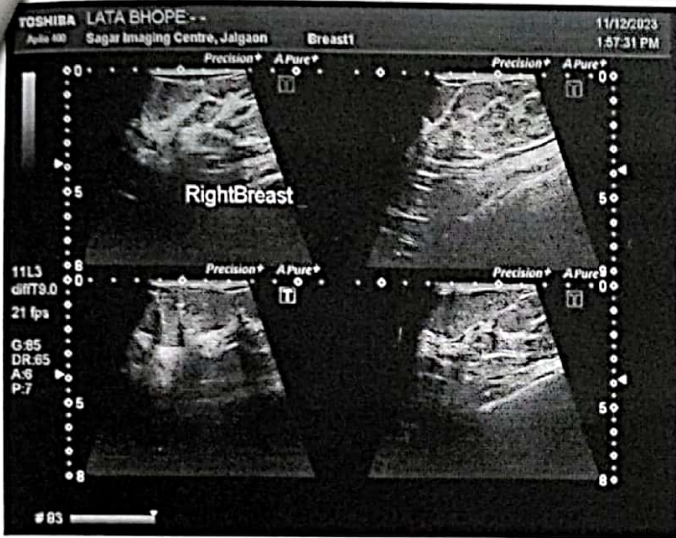IMPRESSION :

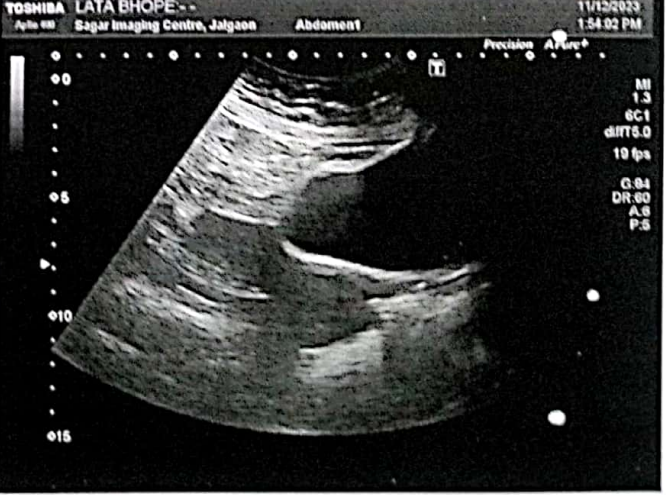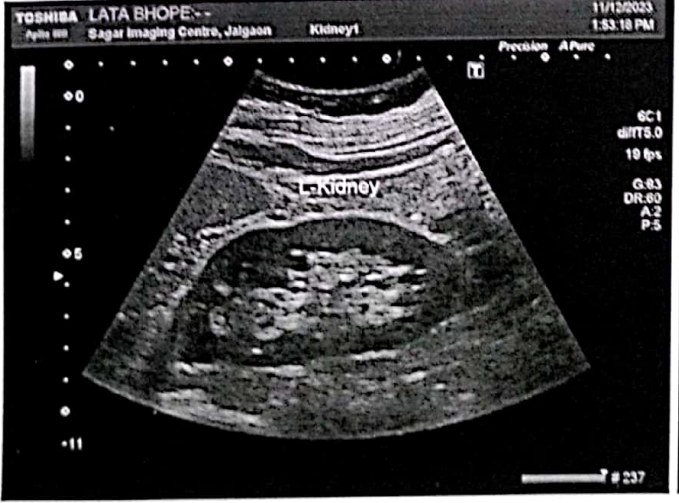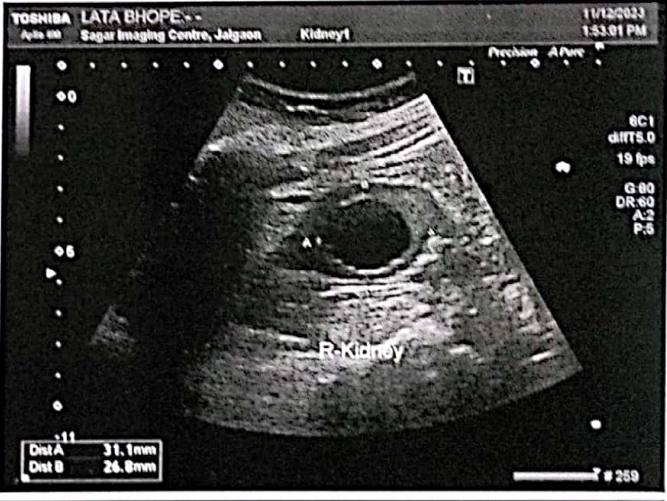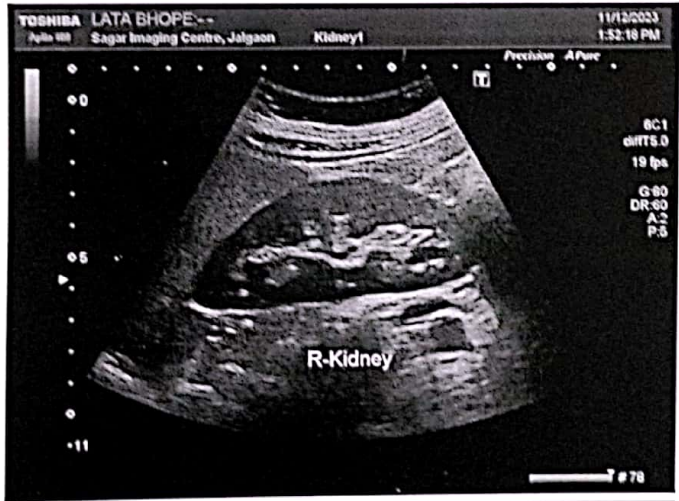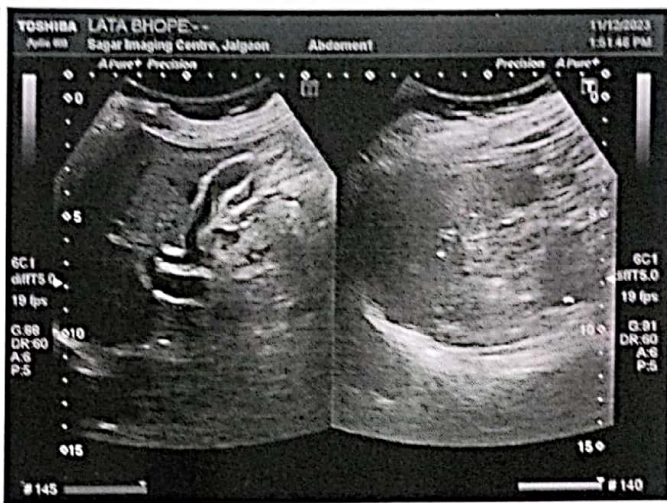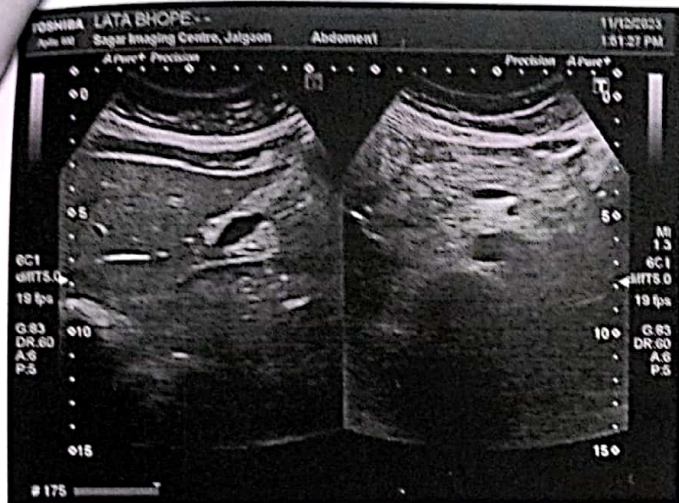Normal examination of breast.

**Histopathological correlation is suggested for confirmation
REPORT WITH THANKS.**

Clinico pathological correlation is suggested.


DR. CHETAN KAKLIYA





सुजय हॉस्पिटल व मॅटर्निटी होम

अतिदक्षता विभाग

डॉ. सौ. जयश्री सुर्यवंशी
एम.डी.
(स्त्रीरोग व प्रसूतीशास्त्र तज्ञ)
रजि.नं. 3712

डॉ. सुनिल सुर्यवंशी
एम.डी. (मेडीसीन) पुणे
कन्सल्टिंग फिजिशियन
रजि.नं. 2223

पत्ता : मेन टेलिफोन एक्सचेंज समोर, पारिख
पार्क जवळ, नविन बस स्टॅन्डच्या मागे,
जळगांव. फोन : (0257) 2227821

उपलब्ध सुविधा : • एक्स रे • सोनोग्राफी • इकोकार्डिओग्राफी • सुमज्ज ऑपरेशन थिएटर • कॉम्प्युटाईज्ड इ.सी.जी. • स्ट्रेस टेस्ट • पल्मोनरी फंक्शन टेस्ट

Rx

दि / /

2D – ECHOCARDIOGRAPHY

Name – LATA MADHUKAR D BHOPE

Age- 53 Yrs FEMALE

Date – 11/12/2023

IMPRESSION –

NORMAL SIZE CARDIAC CHAMBERS.

STRUCTURALLY NORMAL CARDIAC VALVES.

NORMAL LV SYSTOLIC FUNCTION . EF- 58 %.

NORMAL LV DIASTOLIC FUNCTION .

NO RWMA .

NO CLOTS OR VEGETATION.

IAS AND IVS INTACT.

NORMAL PERICARDIUM.

Dr Sunil Suryawanshi

Dr Sunil Suryawanshi
M.D. (Medicine)
Reg.No.2223

परत येतांना कागद सोबत आणावा.

सुजय हॉस्पिटल व मॅटर्निटी होम

अतिदक्षता विभाग

डॉ. सौ. जयश्री सुर्यवंशी
एम.डी.
(स्त्रीरोग व प्रसुतीशास्त्र तज्ञ)
रजि.नं. 3712

डॉ. सुनिल सुर्यवंशी
एम.डी.(मेडीसीन) पुणे
कन्सल्टिंग फिजिशियन
रजि.नं. 2223

पत्ता : मेन टेलिफोन एक्सचेंज समोर, पारिख
पार्क जवळ, नविन बस स्टॅन्डच्या मागे,
जळगांव. फोन : (0257) 2227821

उपलब्ध सुविधा : • एक्स-रे • सोनोग्राफी • इकोकार्डिओग्राफी • सुसज्ज ऑपरेशन थिएटर • कॉम्प्युटाइज्ड इ.सी.जी. • स्ट्रेस टेस्ट • पल्मोनरी फंक्शन टेस्ट

Rx

दि / /

DATE-11.12.23

PHYSICIAN CONSULTATION

MRS LATA MADHUKAR BHOPE , 53 YRS FEMALE

NO CARDIORESPIRATORY COMPLAINTS.

NOT A K/C/O HT,DM ,IHD,BRONCHIAL ASTHAMA

NO ALLERGY TO ANY MEDICATIONS.

NO ADDICTION.

O/E

AFEBRILE, P- 84/ MIN, BP-130/80 mmHg, NO PALLOR /ICTERUS/EDEMA

JVP-NORMAL

RS/CVS/PA/CNS- NORMAL


DENTAL CONSULTATION-NORMAL, ROUTE CANAL DONE

EYE CHECK UP- NORMAL VISION WITH SPECS

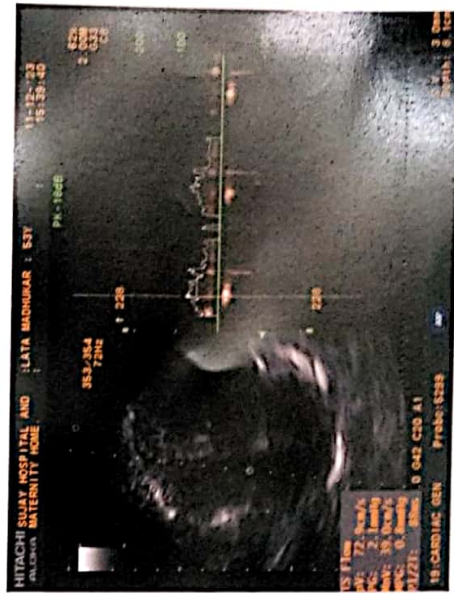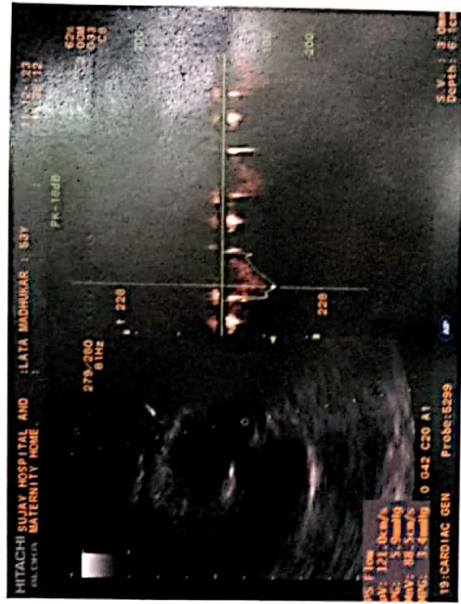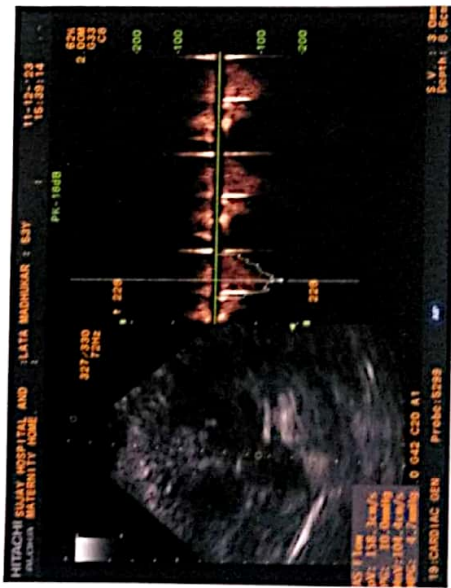
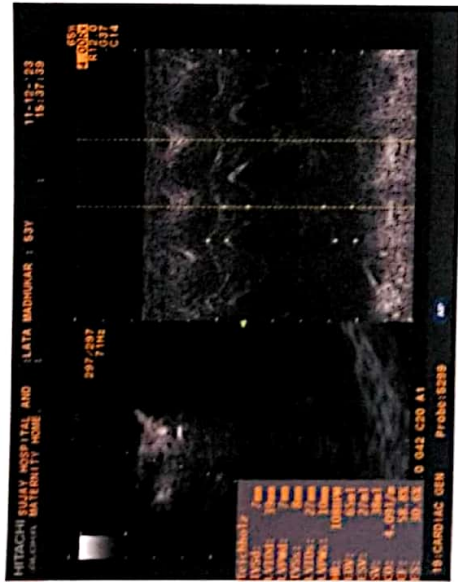
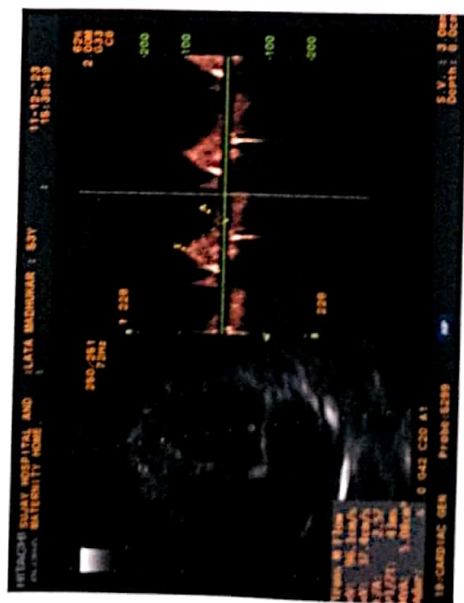
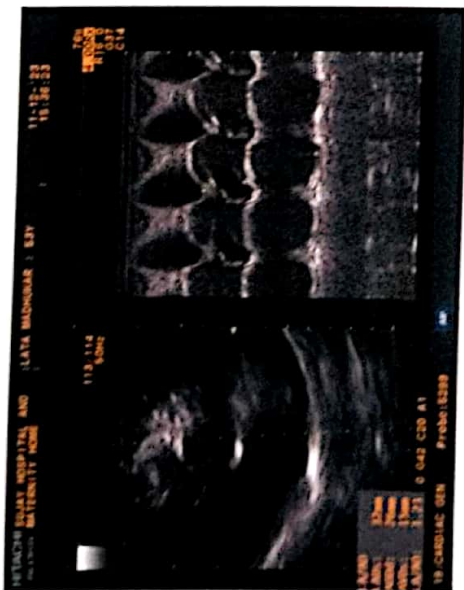ENT CHECK UP- NORMAL

DIET- LOW FAT, LOW CARBOHYDRATE , HIGH PROTEIN DIET

BMI-29.2- OVERWEIGHT



Dr. Sunil Suryawanshi
M.D.(Medicine)
Reg. No. 2223

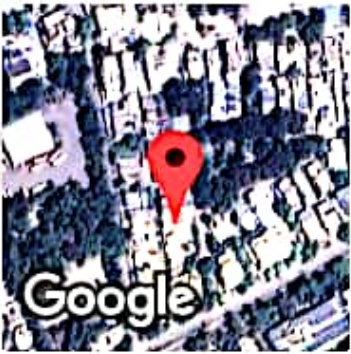परत येतांना कागद सोबत आणावा.



able to get improvement for Eyns. & Rs
30,000/- as fine
PCPNOT Helpline No. 18002534475



 GPS Map Camera



Jalgaon, Maharashtra, India

A4/1279, RR School Rd, Omkar Nagar, Sbi Colony, Jalgaon,
Maharashtra 425001, India

Lat 21.006766°

Long 75.566423°

11/12/23 09:47 AM GMT +05:30



भारतीय विशिष्ट ओळख प्राधिकरण

भारत सरकार
Unique Identification Authority of India
Government of India

नोंदविण्याचा क्रमांक / Enrollment No.: 2189/32561/74407

To,
लता मधुकर भोपे
Lata Madhukar Bhope
Plot Number 86,
Shree Swami Samarth Nagar
Korli Road
Nandurbar
Nandurbar Nandurbar Nandurbar
Maharashtra 425412
9860917070

Ref: 549 / 12V / 130326 / 130480 / P



SB462220149FH



आपला आधार क्रमांक / Your Aadhaar No. :

7392 8643 7980

माझे आधार, माझी ओळख



भारत सरकार

Government of India



लता मधुकर भोपे
Lata Madhukar Bhope
जन्म तारीख / DOB : 01/06/1970
स्त्री / Female



7392 8643 7980

माझे आधार, माझी ओळख



Manavata

Pathology & Microbiology Laboratory

Dr. Kailash B. Wagh
M.D. Microbiology D.C.P
Reg No. 2001/07/2704

REG NO. : 12-2023-OPD / 4
NAME : Mrs. LATA BHOPE
REF BY :

AGE : 53 Years
SEX : Female
DATE : 11-Dec-2023

HAEMOGRAM

TESTS	RESULTS	UNIT	REFERENCE RANGE
Haemoglobin	: 11.9	g/dl	11 - 18
WBC COUNT			
Total WBC Count	: 6900	/cmm	4000 - 11000
DIFFERENTIAL COUNT			
Neutrophil	: 56	%	40 - 74
Lymphocyte	: 34	%	15 - 45
Eosinophil	: 04	%	0 - 7
Monocyte	: 06	%	1 - 10
Basophil	: 00	%	0 - 1
RBC INDICES			
Hct	: 35.2	%	33 - 60
R.B.C. count	: 4.59	mil./cmm.	4.0 - 6.0
Mcv	: 86.2	fL	76 - 94
Mch	: 32.5	pg	25 - 33
Mchc	: 36.2	%	32 - 38
PLATELETS INDICES			
Plt Count	: 256000	/cmm	150000 - 450000
RBC Morphology	: Normocytic Normocytic		
WBC Studies	: Normal Morphology		
Platelet	: Adequate		
ESR	: 12	mm/hr	00 - 20

THANKS FOR REFERRAL

KBW
Dr. Kailash B. Wagh
MD (Micro) DCP

Dr. Kailash B. Wagh
M.D. Microbiology D.C.P.
Reg No. 2001/07/2704



9 98 Jilha Peth, Kantai Sabhagruh Road, Near Barde Medical, Jalgaon- 425001
☎ 0257-2970978, 2225322 ☐ 9405887735



Manavata

Pathology & Microbiology Laboratory

Dr. Kailash B. Wagh
M.D. Microbiology D.C.P.
Reg. No. 2001/07/2704

REG NO. : 12-2023-OPD / 4
NAME : Mrs. LATA BHOPE
REF BY :

AGE : 53 Years
SEX : Female
DATE : 11-Dec-2023

BLOOD GROUP

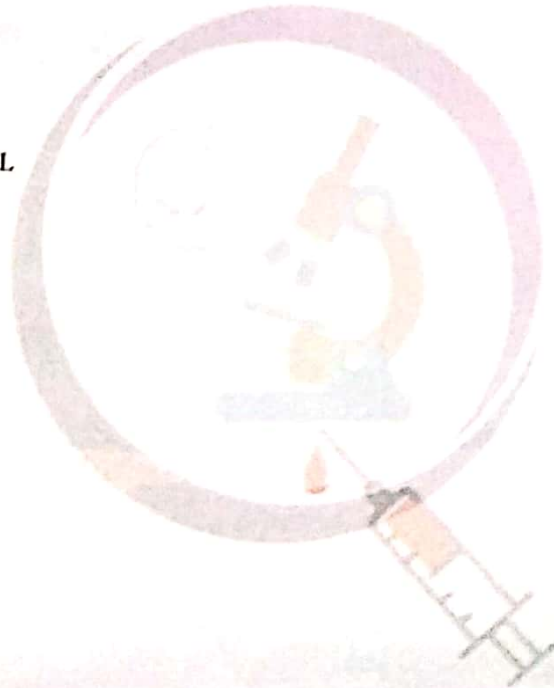
BLOOD GROUP : "A" Rh Positive.

NOTE : Grouping and cross matching is compulsory before blood transfusion, as errors can occur due to irregular antibodies.

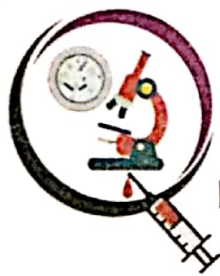THANKS FOR REFERRAL

^{KBW}
Dr. Kailash B. Wagh
MD (Micro) DCP

Dr. Kailash B. Wagh
M.D. Microbiology D.C.P.
Reg. No. 2001/07/2704



9 98 Jilha Peth, Kantai Sabhagruh Road, Near Barde Medical, Jalgaon- 425001
☎ 0257-2970978, 2225322 ☑ 9405887735



Manavata

Pathology & Microbiology Laboratory

Dr. Kailash B. Wagh

M.D. Microbiology D.C.P

Reg No. 2001/07/2704

REG NO. : 12-2023-OPD / 4
NAME : Mrs. LATA BHOPE
REF BY :

AGE : 53 Years

SEX : Female

DATE : 11-Dec-2023

BLOOD SUGAR FASTING & POST-PRANDIAL

<u>TESTS</u>	<u>RESULTS</u>	<u>UNIT</u>	<u>REFERENCE RANGE</u>
BLOOD SUGAR FASTING	: 80	mg/dl	70 - 110
URINE SUGAR FASTING	: Nil		
BLOOD SUGAR PP	: 89	mg/dl	70 - 140
URINE SUGAR PP	: Nil		

LIVER FUNCTION TEST

<u>TESTS</u>	<u>RESULTS</u>	<u>UNIT</u>	<u>REFERENCE RANGE</u>
BILIRUBIN- TOTAL	: 0.89	mg/dl	0 - 1.0
BILIRUBIN- DIRECT	: 0.23	mg/dl	0 - 0.3
BILIRUBIN- INDIRECT	: 0.66	mg/dl	0.1 - 1.0
SGPT	: 21	IU/L	0 - 40
SGOT	: 32	IU/L	0 - 45
ALKALINE PHOSPHATASE	: 258	IU/L	25 - 350
TOTAL PROTIEIN	: 6.10	gm/dl	6 - 8
ALBUMIN	: 3.56	gm/dl	3.5 - 5
GLOBULIN	: 2.54	gm/dl	2 - 3.5
A/G Ratio	: 2.02		2 - 2.5
GGTP	: 14	IU/l	0 - 25

THANKS FOR REFERRAL



KBW
Dr. Kailash B. Wagh
MD (Micro) DCP

Dr. Kailash B. Wagh
M.D. Microbiology D.C.P.
Reg No. 2001/07/2704

98 Jilha Peth, Kantai Sabhagruh Road, Near Barde Medical, Jalgaon- 425001
☎ 0257-2970978, 2225322 ☐ 9405887735



Manavata

Pathology & Microbiology Laboratory

Dr. Kailash B. Wagh

M.D. Microbiology D.C.P
Reg No. 2001/07/2704

REG NO. : 12-2023-OPD / 4
NAME : Mrs. LATA BHOPE
REF BY :

AGE : 53 Years
SEX : Female
DATE : 11-Dec-2023

KIDNEY FUNCTION TEST

<u>TESTS</u>	<u>RESULTS</u>	<u>UNIT</u>	<u>REFERENCE RANGE</u>
BLOOD UREA NITROGEN	: 12	mg/dl	5 - 21
CREATININE	: 0.86	mg/dl	0.7 - 1.4
URIC ACID	: 5.23	mg/dl	2.6 - 6.0

LIPID PROFILE

<u>TESTS</u>	<u>RESULTS</u>	<u>UNIT</u>	<u>REFERENCE RANGE</u>
TOTAL CHOLESTEROL	: 175	mg/dl	140 - 250
TRIGLYCERIDES	: 75	mg/dl	40 - 140
HDL- CHOLESTEROL	: 43	mg/dl	32 - 90
LDL- CHOLESTEROL	: 117	mg/dl	80 - 150
VLDL-CHOLESTEROL	: 15	mg/dl	10 - 35
TOTAL CHO/HDL RATIO	: 4.07		0 - 5.1
LDL/HDL RATIO	: 2.72	mg/dl	0 - 3.5
NON HDL CHOLESTEROL	: 132	mg/dl	0 - 160

KBW
Dr. Kailash B. Wagh
MD (Micro) DCP

THANKS FOR REFERRAL

Dr. Kailash B. Wagh
M.D. Microbiology D.C.P.
Reg. No. 2001/07/2704



9 98 Jilha Peth, Kantai Sabhagruh Road, Near Barde Medical, Jalgaon- 425001
☎ 0257-2970978, 2225322 ☐ 9405887735



Manavata

Pathology & Microbiology Laboratory

Dr. Kailash B. Wagh

M.D. Microbiology D.C.P.
Reg No. 2001/07/2704

REG NO. : 12-2023-OPD / 4
NAME : Mrs. LATA BHOPE
REF BY :

AGE : 53 Years
SEX : Female
DATE : 11-Dec-2023

THYROID TEST

<u>TESTS</u>	<u>RESULTS</u>	<u>UNIT</u>	<u>REFERENCE RANGE</u>
T3	: 102	ng/ml	87 - 178
T4	: 9.42	µg/dl	6.06 - 12.23
ULTRA TSH	: 1.023	µIU/ml	0.34 - 5.6

NOTE

: Test Done On Fully Automated Mindray CL 900i Hormone Assay BY CLIA

KBW
Dr. Kailash B. Wagh
MD (Micro) DCP

THANKS FOR REFERRAL

Dr. Kailash B. Wagh
M.D. Microbiology D.C.P.
Reg. No. 2001/07/2704



9 98 Jilha Peth, Kantai Sabhagruh Road, Near Barde Medical, Jalgaon- 425001
☎ 0257-2970978, 2225322 ☐ 9405887735



Manavata

Pathology & Microbiology Laboratory

Dr. Kailash B. Wagh

M.D. Microbiology D.C.P.
Reg No. 2001/07/2704

REG NO. : 12-2023-OPD / 4

NAME : Mrs. LATA BHOPE

REF BY :

AGE : 53 Years

SEX : Female

DATE : 11-Dec-2023

URINE ANALYSIS REPORT

TESTS	RESULTS	UNIT	REFERENCE RANGE
PHYSICAL EXAMINATION			
QUANTITY	: 10 ml		
COLOUR	: Pale Yellow		
APPEARANCE	: Clear		
DEPOSITS	: Absent		
SPECIFIC GRAVITY	: 1.010		1.002 - 1.030
REACTION (PH)	: Acidic		
CHEMICAL EXAMINATION			
PROTEINS	: Absent		
SUGAR	: Absent		
KETONE	: Absent		
BILE SALTS/BILE PIGMENTS	: Absent		
MICROSCOPIC EXAMINATION			
RBC	: Absent	/hpf	
PUS CELLS	: 2-3	/hpf	
EPITHELIAL CELLS	: Occasional	/hpf	
CASTS	: Absent		
CRYSTALS	: Absent		
AMORPHOUS DEPOSITS	: Absent		

THANKS FOR REFERRAL

Kes
Dr. Kailash B. Wagh
MD (Micro) DCP

Dr. Kailash B. Wagh
M.D. Microbiology D.C.P.
Reg. No 2001/07/2704



98 Jilha Peth, Kantai Sabhagruh Road, Near Barde Medical, Jalgaon- 425001
☎ 0257-2970978, 2225322 ☎ 9405887735