



Name : Mrs. VEENA PRASHURAM PAVALE Age : 33Yr Gender : Female  
UHID : MHN1.0000124075 / NSKAH27272 W/BNo/RefNo : AHC  
Lab No : AHN1.C2200448 LRN : 650999  
Ref Doctor : DR. Rajashri Dhongade



Collected on : 10-AUG-2022 10:55:41 AM Received on : 10-AUG-2022 10:55:41 AM Reported on : 10-AUG-2022 02:03:35 PM

**MediWheel Full Body Health Checkup Female Below 40 Package**

**CERVICAL/VAGINAL SMEAR II SLIDE**

**SOURCE OF SPECIMEN :**

Cervical Smear-Conventional

**II. General Categorization :**

Negative for intraepithelial lesion or malignancy

**Other non neoplastic findings:**

Smears show Intermediate and para basal squamous cells. Moderate neutrophilic infiltrate is seen. There is no evidence of dysplasia or malignancy. There is no evidence of candida or trichomonas.

Negative for intraepithelial lesion or malignancy benign cellular changes of inflammation

**Epithelial abnormalities:**

Absent

\* Negative for intraepithelial lesion or malignancy .Suggests benign cellular changes of inflammation  
Adv.: Follow up

\* END OF REPORT \*

Reported By:

Dr.KISHOR KHODKE

Typed By: 721947

Printed On : 10-AUG-2022 02:11:25 PM

Name : Mrs. VEENA PRASHURAM PAVALE (38/F)

Address : AAI NIVAS SAI NAGAR MERILINK ROAD BEHIND SAISHIV NAGAR AMRUTDHAM  
NASHIK, NASHIK, NASHIK, MAHARASHTRA, INDIA

Examined by :

UHID : MHN1.0000124075

Package : MediWheel Full Body Health Checkup Female Below 40  
Package

AHC No : NSKAH27272

## CHIEF COMPLAINTS

For corporate health checkup  
No specific complaints

## DRUG ALLERGY

NO KNOWN ALLERGY :10/08/2022

## SYSTEMIC REVIEW

**Cardiovascular system**  
- Nil Significant

## Past medical history

Do you have any allergies? - No  
Do you have any drug allergies? - No  
Past medical history - nil significant  
Covid 19 - No

## Surgical history

Surgical history - Nil

## Personal history

Marital status - Married  
No. of children - 02  
Diet - Vegetarian  
Alcohol - does not consume alcohol  
Smoking - No  
Chews tobacco - No  
Chews paan - No  
Uses snuff - No  
Illicit substance use - No  
Physical activity - Active

## Family history

Father - has expired  
Aged - 56 yrs  
Mother - alive  
Aged - 51 yrs  
Sisters - 3  
Diabetes - father  
Hypertension - father  
Coronary artery disease - father  
Cancer - None  
Thyroid/other endocrine disorder - sister

## PHYSICAL EXAMINATION

### General

General appearance - normal  
Build - normal  
Height - 155 Cm  
Weight - 57.3 Kg  
BMI - 23.85  
Pallor - No  
Oedema - no  
Temperature - 97.1  
SpO2 - 98

### Cardiovascular system

H Swaminarayan Nagar, Off Mumbai-Agra Highway,  
Panchvati, Nashik - 422 003.

+91- 253 - 2510250 / 350 / 450 / 550 / 750

apollonashik@apollohospitals.com  
www.askapollo.com

QFAHN/BILL/003/V1



Date : 09/08/2022

Name : Mrs. VEENA PRASHURAM PAVALE (33 /F)  
OHID : MHNT.0000124075

Package : MediWheel Full Body Health Checkup Female Below 40 Package

AHC No : NSKAH27272

Heart rate (Per minute) - 79  
Rhythm - Regular  
- B.P. Supine  
Systolic(mm of Hg) - 110  
Diastolic(mm of Hg) - 80  
Heart sounds - S1S2+

### Respiratory system

Breath sounds - Normal vesicular breath sounds

### Abdomen

Onomegaly - No  
Tenderness - No



Printed By : Shweta Sharad Shardul



Name : Mrs. VEENA PRASHURAM PAVALE (33 /F)  
UHID : MH11.0000124075

Date : 09/08/2022

Package : MediWheel Full Body Health Checkup Female Below 40 Package

AHC No : NSKAH27272

**URINE ROUTINE (CUE)**

Test Name	Result	Unit	Level	Range
Specific Gravity	1.025		●	1.016-1.026
Color,:	PALE YELLOW			
Transparency:	Clear			
Reaction:	Acidic			7.2-7.8
Protein :	Nil			
Sugar:	Nil			
pH	5.5		●	4.6-8
Blood:	Negative			
Ketone	Negative			
Bile Pigments:	Negative			
Bile Salts :	Negative			
Urobilinogen	Normal			
Nitrite	Negative			
RBC	0	/hpf	●	0-2
WBC/Pus Cells	0-2/HPF	/hpf		
Tc/Sqc(Transitional/Squamous epithelial cells)	5-7/HPF	/hpf		

Lymphocytes	40	%	●	20-45
Eosinophils	03	%	●	1-6
Monocytes	03	%	●	1-10
Basophils	00	%	●	0-1
ERYTHROCYTE SEDIMENTATION RATE (ESR)	22 *	mm/1st hr	●	0-20
RBC,:	Normocytic to mild microcytic and normochromic			
WBC,:-	Leucopenia			
platelets,:	Adequate			

**BLOOD GROUPING AND TYPING (ABO and Rh)**

Test Name	Result	Unit	Level	Range
ABO Group:	O			
Rh (D) Type:	POSITIVE			

**LIVER FUNCTION TEST (PACKAGE)**

Test Name	Result	Unit	Level	Range
ALT(SGPT) - SERUM / PLASMA	42	U/L	●	30-65
ALBUMIN - SERUM	4.5	g/dL	●	3.5-5
ALKALINE PHOSPHATASE - SERUM/PLASMA	56	U/L	●	0-100
AST (SGOT) - SERUM	60 *	U/L	●	15-37
BILIRUBIN, TOTAL - SERUM	0.8	mg/dL	●	0.0-1.0

**C B C WITH ESR (AUTOMATION + STANDARD METHOD)**

Test Name	Result	Unit	Level	Range
Hemoglobin	9.7 *	g/dl	●	11.0-16.0
Haematocrit	32.3 *	%	●	34.0-48.0
WBC COUNT	4.1	Million/ul	●	3.7-5.6
MCV	78.9	fl	●	75.0-95.0
MCH	23.7 *	pg	●	26.0-32.0
MCHC	30 *	g/dl	●	31.0-36.0
RDW	17.8 *	%	●	11-16
Platelet Count(Optical/Impedance)	419	10 <sup>3</sup> /m <sup>3</sup>	●	140-440
TLC Count	3.7 *	10 <sup>3</sup> /m <sup>3</sup>	●	4.0-11.0
Neutrophils	54	%	●	40-75

**LIPID PROFILE TEST (PACKAGE)**

Test Name	Result	Unit	Level	Range
Total Cholesterol	184	mg/dL	●	0-200

**CREATININE - SERUM / PLASMA**

Test Name	Result	Unit	Level	Range
CREATININE - SERUM / PLASMA	0.8	mg/dL	●	0.6-1.0

**LIVER FUNCTION TEST (PACKAGE)**

Test Name	Result	Unit	Level	Range
GGTP: GAMMA GLUTAMYL TRANSPEPTIDASE - SERUM	42	U/L	●	0-50

● Within Normal Range    ● Borderline High/Low    ● Out of Range

H Swaminarayan Nagar, Off Mumbai-Agra Highway,  
Panchvati, Nashik - 422 003.

+91- 253 - 2510250 / 350 / 450 / 550 / 750

apollonashik@apollohospitals.com

www.askapollo.com

QFAHN/BILL/003/V1



Date: 09/08/2022

Name : Mrs. VEENA PRASHURAM PAVALE (33 /F) UHID : MHN1.0000124075

Package : MediWheel Full Body Health Checkup Female Below 40 Package

AHC No : NSKAH27272

**GLUCOSE - SERUM / PLASMA (FASTING)**

Test Name	Result	Unit	Level	Range
Glucose - Plasma (Fasting)	114 *	mg/dL	●	70-100
URINE GLUCOSE(FASTING): (Strip Method)	Nil			

TOTAL T3: TRI IODOTHYRONINE - SERUM	180	ng/dL	●	Healthy Adults: 69 - 215 Pregnant Women: 1st Trimester:121-308 2nd & 3rd Trimesters:152-362
-------------------------------------	-----	-------	---	---

**GLUCOSE - SERUM / PLASMA (POST PRANDIAL)**

Test Name	Result	Unit	Level	Range
Glucose - Plasma (POST PRANDIAL)	118	mg/dL	●	70-140
URINE GLUCOSE(POST PRANDIAL):(Strip Method)	Nil			

TOTAL T4: THYROXINE - SERUM	10.0	µg/dL	●	Healthy Adults: 5.2 - 12.7 Pregnancy:1st Trimester:7.8 - 16.2 2nd & 3rd Trimesters: 9.1 - 18.3
-----------------------------	------	-------	---	--

**GLYCOSYLATED HEMOGLOBIN (HbA1C) - WHOLE BLOOD**

Test Name	Result	Unit	Level	Range
Glycosylated Hemoglobin (HbA1c)	5.6	%	●	0.0-6.0
Mean Plasma Glucose (MPG) Estimate:	122.06	mg/dL		

**LIPID PROFILE TEST (PACKAGE)**

Test Name	Result	Unit	Level	Range
Triglycerides - Serum	141	mg/dL	●	0-150

**THYROID PROFILE - I(T3,T4 AND TSH)**

Test Name	Result	Unit	Level	Range
TSH: THYROID STIMULATING HORMONE - SERUM	2.6	uIU/mL	●	Euthyroid: 0.3 - 4.5 Hypothyroid: 7.1 - >75.0 Pregnancy(All Trimesters):0.2 -3.5

**LIPID PROFILE TEST (PACKAGE)**

Test Name	Result	Unit	Level	Range
HDL CHOLESTEROL - SERUM / PLASMA	41	mg/dL	●	40-60
TOTAL CHOLESTEROL/HDL CHOLESTEROL RATIO(Calculated)	4.5		●	0.0-4.5
LDL Cholesterol (Direct LDL)	143	mg/dL		

**UREA - SERUM / PLASMA**

Test Name	Result	Unit	Level	Range
UREA - SERUM / PLASMA	18	mg/dL	●	15-38
UREA NITROGEN SERUM/PLASMA: (Calculated)	8	mg/dL	●	7-18

**LIVER FUNCTION TEST (PACKAGE)**

Test Name	Result	Unit	Level	Range
PROTEIN, TOTAL - SERUM / PLASMA	8.2	g/dL	●	6.4-8.2
PROTEIN, TOTAL - SERUM / PLASMA	8.2	g/dL	●	6.4-8.2

**URIC ACID - SERUM**

Test Name	Result	Unit	Level	Range
URIC ACID - SERUM	4.4	mg/dL	●	2.6-6.0

**THYROID PROFILE - I(T3,T4 AND TSH)**

Test Name	Result	Unit	Level	Range
-----------	--------	------	-------	-------

**LIVER FUNCTION TEST (PACKAGE)**

Test Name	Result	Unit	Level	Range
-----------	--------	------	-------	-------

● Within Normal Range    ● Borderline High/Low    ● Out of Range

Name : Mrs. VEENA PRASHURAM PAVALE (33  
/F)

UHID : MHN1.0000124075

Date : 09/08/2022

Package : MediWheel Full Body Health Checkup Female Below 40 Package

AHC No : NSKAH27272

BILIRUBIN 0.1 mg/dL ● 0.0-0.3  
CONJUGATED  
(DIRECT) - SERUM

BILIRUBIN 0.7 mg/dL ● 0.0-0.7  
UNCONJUGATED -  
SERUM(Calculated)

### CARDIAC STRESS TEST - (TMT)

### ECG

### ULTRASOUND - WHOLE ABDOMEN

Mild hepatosplenomegaly.

Bulky uterus.

A rim of fluid collection within the left half of the  
endometrial cavity.

A small intramural fibroid in the anterior wall of the  
uterus.

Suggest : Clinical correlation.

### X-RAY CHEST PA

..  
INVESTIGATIONS NOT DONE / NOT YET REPORTED / NOT  
PART OF PACKAGE(LAB,RADIOLOGY & CARDIOLOGY)

### Haematology

STOOL ROUTINE

### Histopathology

CERVICAL/VAGINAL SMEAR II SLIDE

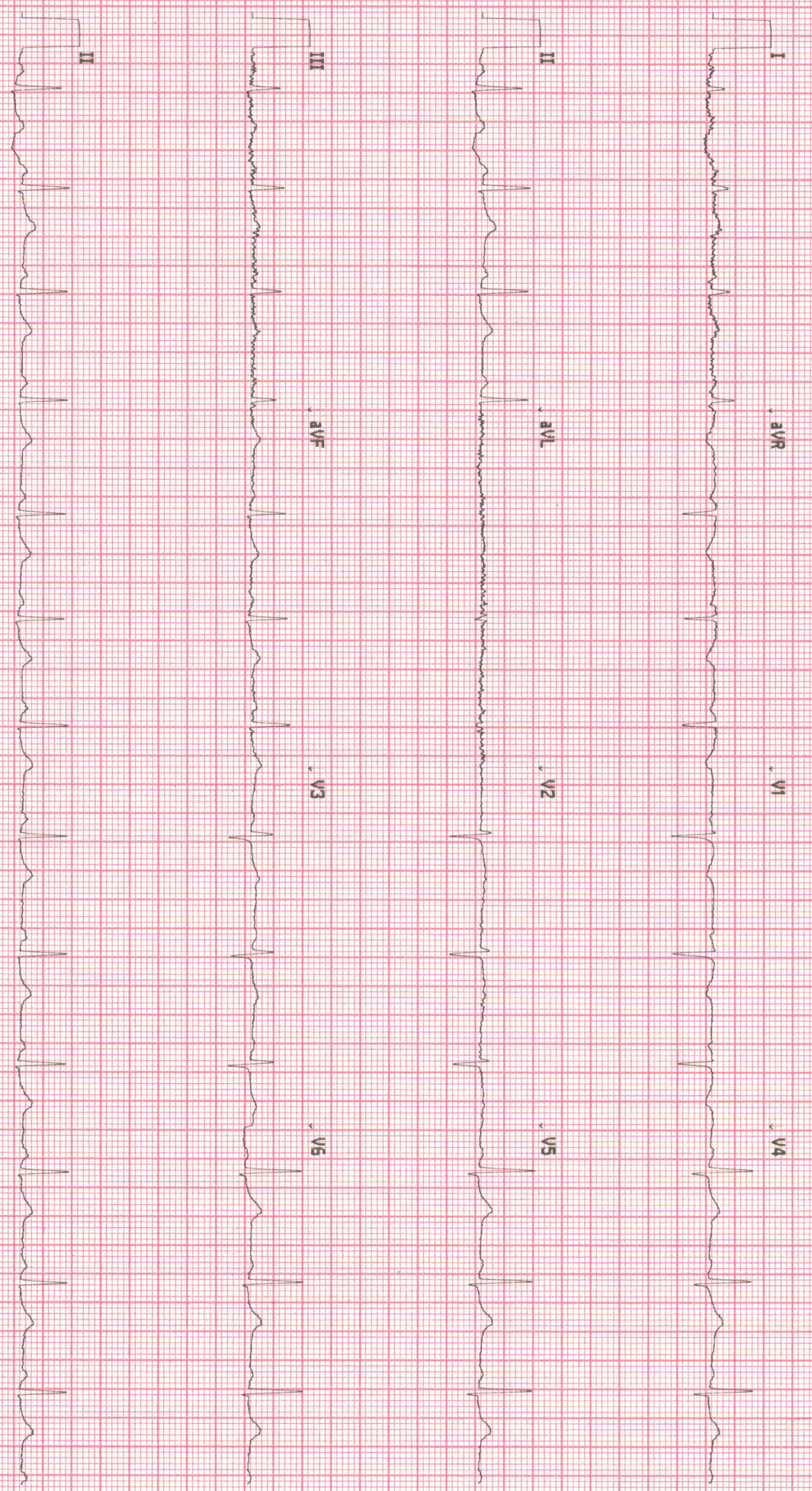
● Within Normal Range    ● Borderline High/Low    ● Out of Range

Pavale, Veena  
ID:  
DOB:  
33yr, Female

9-Aug-2022 13:53:10

Vent rate: 79 BPM  
PR int: 146 ms  
QRS dur: 72 ms  
QT/QTc: 369/403 ms  
P-R-T axes: 49 72 72

SINUS RHYTHM  
MINIMAL ST DEPRESSION [0.025+ mv ST DEPRESSION]  
BORDERLINE ECG  
UNCONFIRMED REPORT




113500188213

No Site Name

Site # 0 Cart # 2 Version 2.0.4.0 Sequence #19719 25mm/s 10mm/mV 0.05-40 Hz



### Radiology

**Patient Details** : Mrs. VEENA PRASHURAM PAVALE | Female | 33Yr 0Mth 0Days  
**UHID** : MHN1.0000124075 **Patient Location:** AHC  
**Patient Identifier:** NSKAH27272   
**DRN** : 222017684 **Completed on :** 09-AUG-2022 11:22  
**Ref Doctor** : DR. Rajashri Dhongade

### ULTRASOUND - WHOLE ABDOMEN

**LIVER** : Mildly enlarged in size and measures 16cm. Echotexture is uniform and normal.  
No I.H.B.D./ focal lesions.

**PORTAL VEIN**: Normal in size.

**GALL BLADDER**: Well distended with normal walls and lumen.  
No calculi/pericholecystic fluid.

**COMMON BILE DUCT**: Normal in size.

**PANCREAS** : Visualized portion of head and body of pancreas appears normal in size and echotexture. Rest of the pancreas is obscured due to bowel gases.

**AORTA, IVC and para aortic areas** are normal.

**SPLEEN** : Mildly enlarged in size (12.3cm) and shows normal echotexture.

**KIDNEYS**: Both kidneys are normal in site, size and echotexture.

No evidence of calculi/ hydronephrosis.

Right kidney measures : 10 x 3.3 cm.

Left kidney measures : 11.6 x 3.7cm.

**URINARY BLADDER**: Well distended with normal walls.

No evidence of calculi/ growth/ diverticula .

**UTERUS**: Anteverted. Bulky in size and shows normal echotexture.

Uterus measures : 11.2 x 6.8 x 4.0 cm.

Combined endometrial thickness is normal and measures 10mm.



Mrs. VEENA PRASHURAM PAVALE

MHN1.0000124075

NSKAH27272

**ULTRASOUND - WHOLE ABDOMEN**

A thin rim of fluid collection is seen within the left half of the endometrial cavity, measuring 3mm in maximum thickness.

A small intramural fibroid measuring 1 x 0.8cm is seen in the anterior wall of the uterus.

OVARIES: Normal in size and echotexture.

Visualized bowel loops appear grossly normal.

No evidence of any free fluid in the peritoneal cavity.

**Impression**



Mild hepatosplenomegaly.

Bulky uterus.

A thin rim of fluid collection within the left half of the endometrial cavity.

A small intramural fibroid in the anterior wall of the uterus.

Suggest : Clinical correlation.



Dr. Harshal S Dhongade

Consultant - Radiology

H Swaminarayan Nagar, Off Mumbai-Agra Highway,  
Panchvati, Nashik - 422 003.

+91- 253 - 2510250 / 350 / 450 / 550 / 750

apollonashik@apollohospitals.com

www.askapollo.com

QFAHN/BILL/003/V1



## Radiology

**Patient Details** : Mrs. VEENA PRASHURAM PAVALE | Female | 33Yr 0Mth 0Days

**UHID** : MHN1.0000124075

**Patient Location:** AHC

**Patient Identifier:** NSKAH27272



**DRN** : 122029307

**Completed on :** 09-AUG-2022 10:07

**Ref Doctor** : DR. Rajashri Dhongade

### X-RAY CHEST PA

Mild rotation.

Mild perihilar bronchovascular prominence.

Rest of the lung fields are clear.

Costophrenic angles are clear.

Cardiac size and contour are within normal limits.

Rib cage is normal.

Soft tissues are normal.

Breast shadow related artefacts are noted.

Suggest : Clinical correlation.

#### Impression

..

--- END OF THE REPORT ---

Dr.Gorakhnath T

CONSULTANT-RADIOLOGY

DEPARTMENT OF ENT

Patients Name Mrs. Veena Parale Date 9/18/22  
Age / Sex 33 yr / F UHID 124075  
Consultant : Dr. Purwa Totala Birla ( MS ENT, DNB)

Came for regular ENT checkup  
Right Left

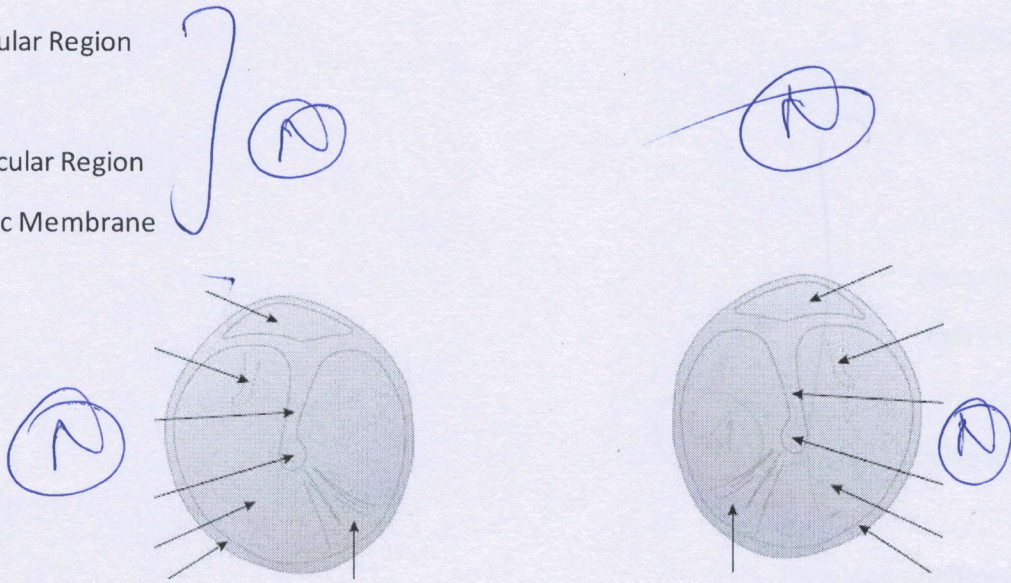
EAR

Preauricular Region

Pinna

Postauricular Region

Tympanic Membrane



Tuning Fork Test

Rinnies 256 Hz

512 Hz

1024 Hz

Weber test

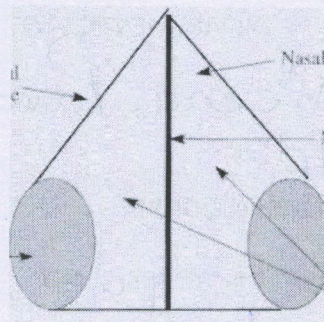
ABC test

Pure Tone Audiometry (PTA)

central  
Same as examiner

NOSE

Anterior Rhinoscopy



PNS tenderness *absent*

ORAL Cavity

Lip

Teeth

Tongue

Buccal mucosa

Anterior Pillar

Tonsils

Posterior pillar

Uvula

Posterior pharyngeal wall\



NECK

Laryngeal crepitus

Laryngeal widening

Cervical Lymph node

Others

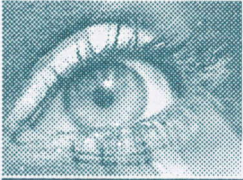


COMMENT

*ENT examination at present  
normal*

ADVICE

*[Signature]*  
Signature



# OPHTHALMOLOGY



Name : Mrs. Neena Pavate  
 Occupation : \_\_\_\_\_  
 Age : 33 Sex : Male  Female  S/M/W/D  
 Address : NSK  
 \_\_\_\_\_ Tel. No. \_\_\_\_\_

Date 09/08/22 UNIT \_\_\_\_\_  
 Room No. \_\_\_\_\_ Out Patient   
 Ref. Physician : \_\_\_\_\_  
 Copies to : \_\_\_\_\_

## REPORT ON OPHTHALMIC EXAMINATION

HISTORY : \_\_\_\_\_

PRESENT COMPLAINT : No Complaint

PAST HISTORY : DM / HTN / ALLERGY

**ON EXAMINATION**

VISION :

RE

LE

RIGHT

LEFT

	PGP	SPH	CYL	AXIS	VA	PGP	SPH	CYL	AXIS	VA
DIST		_____					_____			
NEAR		_____					_____			

**AR / Retinoscopy :**

RIGHT

LEFT

RIGHT			LEFT		
SPH	CYL	AXIS	SPH	CYL	AXIS
-2.00	-0.75	155°	-1.75	-0.50	160°

**Refraction or Acceptance :**

RIGHT

LEFT


	SPH	CYL	AXIS	VA	SPH	CYL	AXIS	VA
DIST	-0.75	_____		6/6	-0.75	_____		6/6
NEAR	_____			N/A	_____			N/A

Are Bhe. ud.


Dr. V. N. N.

CONSULTANT OPTOMETRIST

**Anterior Sigmoid :**



**Fundus :**



**Diagnosis :**

(Bn) Myopia

**Advise / Rx:**

• Eyemi ot cyedropi (Bn)

The text "Eyemi ot cyedropi" is written in a stylized script. To its right, "(Bn)" is circled. A horizontal line with three small circles is drawn below the text.

# ORAL EXAMINATION FORM



Date: 9/2/22

Patient ID: \_\_\_\_\_ MHC

Patient Name: Mrs. Veena Panale Age: 33 Sex: Male  Female

Chief Complaint:

Medical History:

Drug Allergy:

Medication currently taken by the Guest:

Initial Screenign Findings:

Dental Caries:

Missing Teeth: -

Impacted Teeth:

Attrition / Abrasion: -

Bleeding:

Pockets / Recession: -

Calculus / Stains: white stains

Mobility:

Restored Teeth:

Non - restorable Teeth for extraction / Root Stumps:

Malocclusion:

Class 2 malocclusion bilaterally

Others:

Advice:- Scaling Req.

Doctor Name & Signature: Dr. Prayank Patil  
9096986298

ID: 000124075  
Visit:  
9-Aug-2022  
12:54:50

33years Asian Female

BRUCE  
Max HR: 156bpm 90% of max predicted 173bpm  
Max BP: 130/70  
Reason for Termination: Max HR attained  
Comments:

Total Exercise time: 6:04  
Maximum workload: 7.0METS

25.0 mm/s  
10.0 mm/mV  
100hz

Referred by:  
Test ind:

Phase Name	Stage Name	Time in Stage	Speed (mph)	Grade (%)	WorkLoad (METS)	HR (bpm)	BP (mmHg)	RPP (x100)
PRETEST	SUPINE	1:08	***	***	1.0	86	110/70	95
	STANDING	0:05	***	***	1.0	93	110/70	102
	HYPERTENT	0:11	0.8	0.0	1.0	83	110/70	91
EXERCISE	STAGE 1	3:00	1.7	10.0	4.6	138	110/70	152
	STAGE 2	3:00	2.5	12.0	7.0	151		
	STAGE 3	0:04	3.4	13.5	7.0	151	130/70	196
RECOVERY	Post	3:16	***	***	1.0	98	130/70	127

TMT Negative for STI