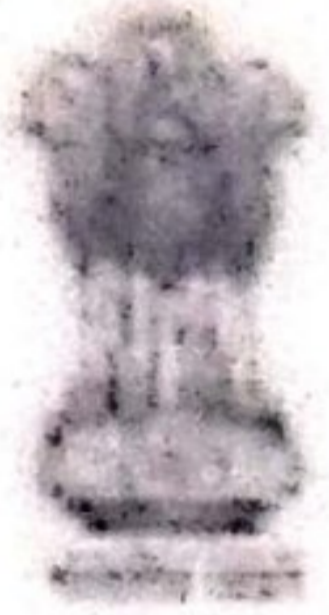



भारत सरकार

GOVERNMENT OF INDIA

Babita Punia

YoB:1978

Female



3511 0031 0510

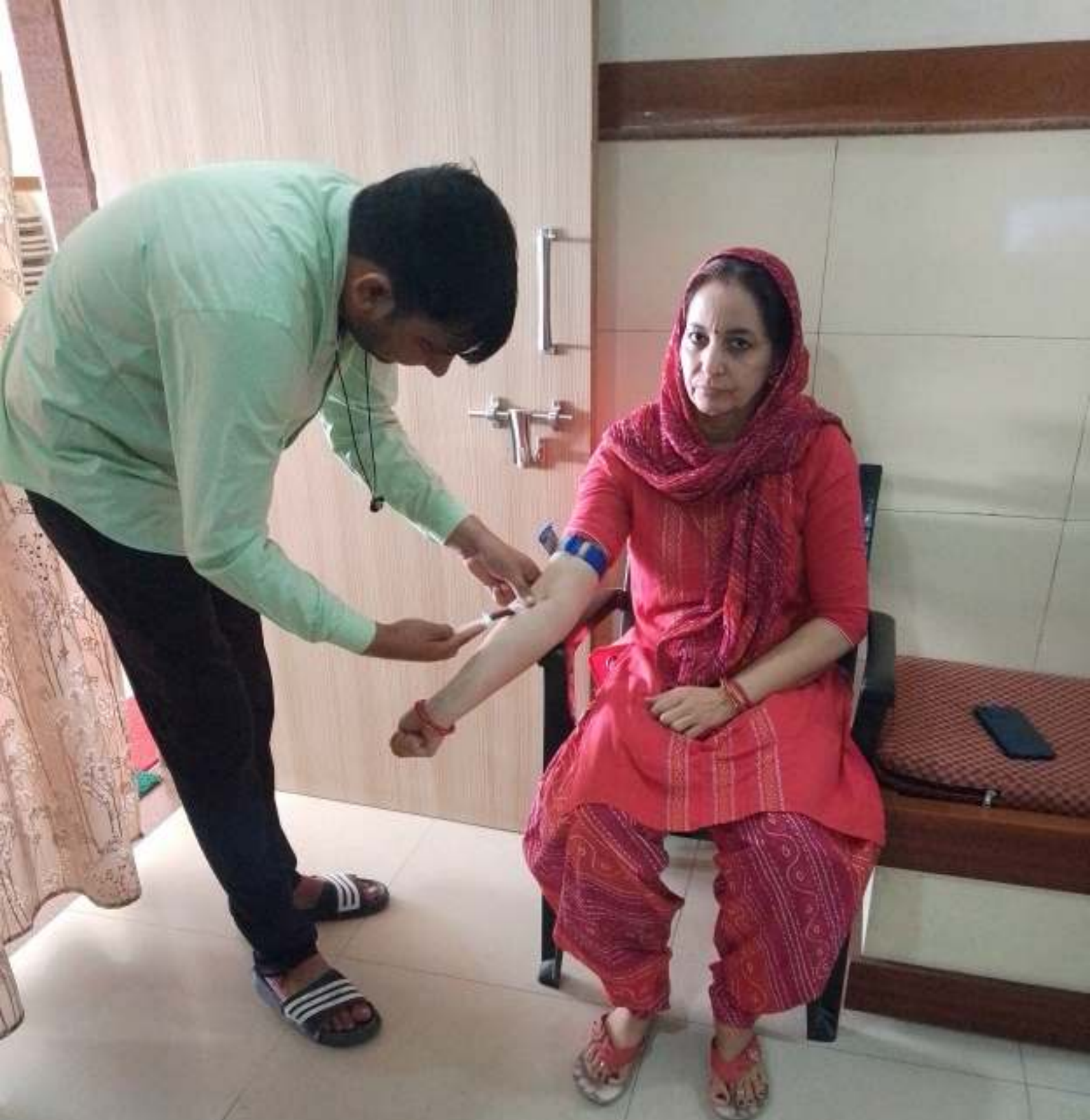Aadhaar - Aam Aadmi ka Adhikar




भारतीय विशिष्ट पहचान प्राधिकरण
UNIQUE IDENTIFICATION AUTHORITY OF INDIA

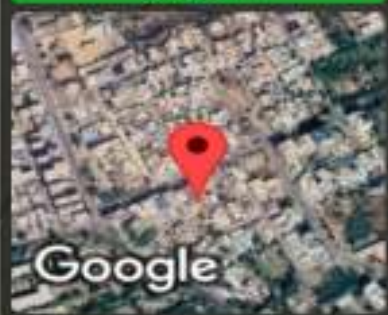Address:

**W/O: Ajay Kumar Punia Shyampura, Nua, Jhunjhunun
Rajasthan, 333041**



 GPS Map Camera

Check In



Jhunjhunu, Rajasthan, India
499p+88q, Subhash Marg, Pratap Nagar, Indra
Nagar, Jhunjhunu, Rajasthan 333001, India
Lat 28.118339° Long 75.385852°
23/11/24 09:03 AM GMT +05:30


भारत सरकार
 GOVERNMENT OF INDIA


 Babita Punia
 Yob: 1978
 Female


 3511 0031 0510

Aadhaar - Aam Aadmi ka Adhikar

Book

9468682172




भारतीय विशिष्ट पहचान प्राधिकरण
 UNIQUE IDENTIFICATION AUTHORITY OF INDIA

Address:
 W/O: Ajay Kumar Punia Shyampura, Nua, Jhunjhunun
 Rajasthan, 333041



23.11.2024 10:20:21

RAJASTHANI DIAGNOSTIC CENTRE
Jhunjhunu
Jhunjhunu

Female

Location:
Room:
Order Number:
Indication:
Medication 1:
Medication 2:
Medication 3:

Sinus bradycardia
Otherwise normal ECG

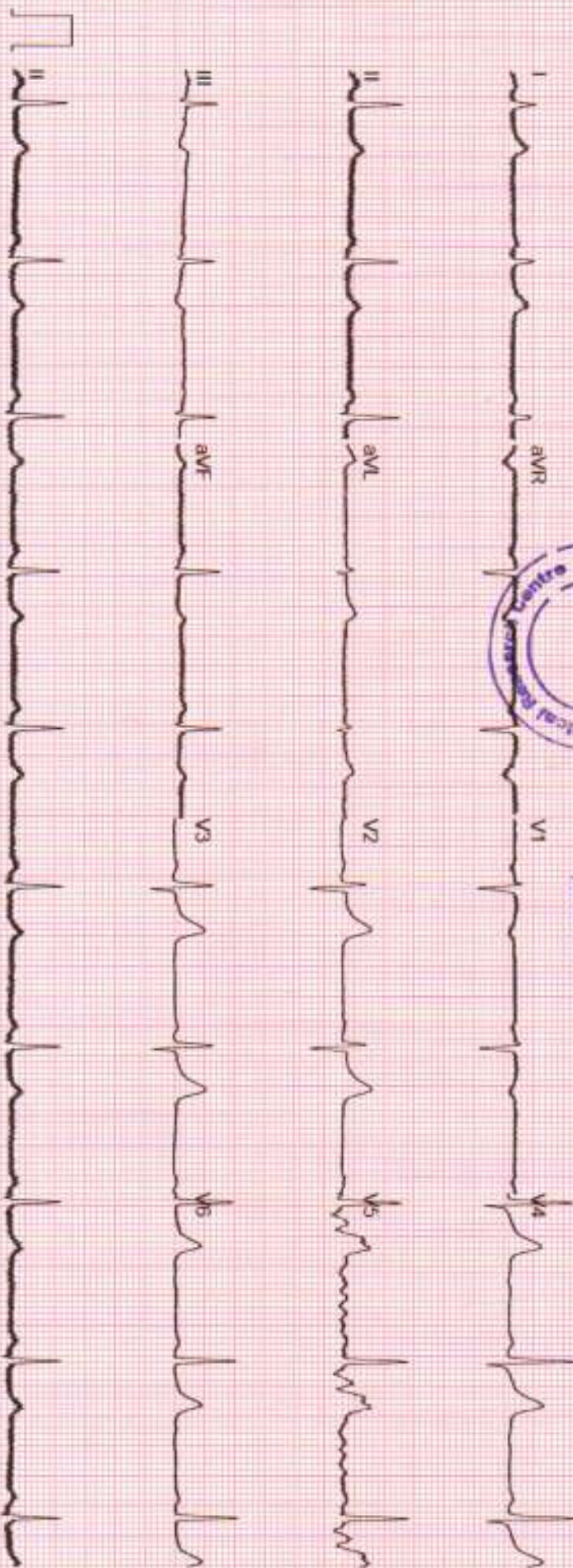
QRS 64 ms
QT / QTcBaz 414 / 402 ms
PR 138 ms
P 96 ms
RR / PP 1050 / 1052 ms
P / QRS / T 35 / 63 / 11 degrees

Technician
Ordering Ph:
Referring Ph:
Attending Ph:

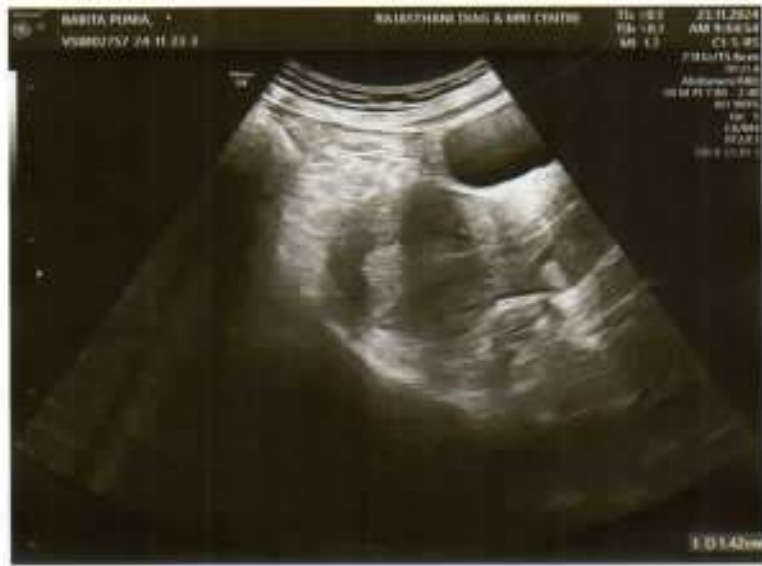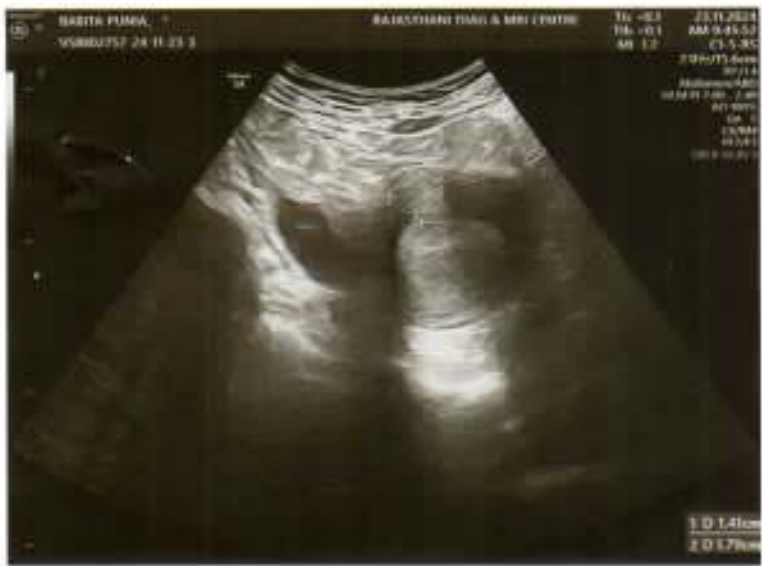57 bpm
- / - mmHg



Dr. Siddharth Chauhan
MBBS (RMC-50140)



Unconfirmed





RAJASTHANI DIAGNOSTIC & MRI CENTRE

FULLY COMPUTERISED PATHOLOGY LABORATORY

MRI CT SCAN TMT SONOGRAPHY X-RAY ECG MAMMOGRAPHY

NAME	BABITA PUNIA	AGE-	SEX: F
REF/BY:	BOB HEALTH CHECKUP	DATE	23-Nov-24

ULTRASONOGRAPHY WHOLE ABDOMEN

Liver: is normal in size, shape and echotexture. No IHBR dilatation is seen. No focal mass seen. Portal vein and hepatic veins are normal in diameter. Common bile duct is normal in diameter and lumen is clear.

Gall bladder: is normal in size shape, location with echo free lumen. Wall thickness is normal. No echogenic shadow suggestive of calculus is seen. No focal mass or lesion is seen.

Pancreas: is normal in size, shape and echotexture. No focal mass or lesion is detected. Pancreatic duct is not dilated.

Rt. Kidney: is normal in size, shape, position and echotexture. Corticomedullary differentiation is well maintained. No evidence of definite calculus/ hydronephrosis is seen.

Lt. Kidney: is normal in size, shape, position and echotexture. Corticomedullary differentiation is well maintained. No evidence of definite calculus/ hydronephrosis is seen.

Spleen: is normal in size, regular in shape and echo texture. No focal lesion is seen. Splenic vessels are normal.

Urinary Bladder: is well distended. Outline of bladder is regular. Wall thickness is normal. No focal mass is seen. No echogenic shadow suggestive of calculus is seen.

Uterus: is normal in size, regular in shape and outline. Uterus is anteverted and ante flexed. Endometrium is thickened-14 mm. Fibroid measuring approx 14x18 mm seen at anterior wall. Cervix is bulky (36mm) with nabothian cyst(6x7mm) in cervix s/o Chronic cervicitis.

Adenexa: Both adenexal regions are seen normal. No focal mass or lesion is seen. Bilateral ovaries are normal in appearance.

No evidence of ascites is seen. No significant Lymphadenopathy is seen. No obvious bowel pathology is seen. Retroperitoneum including aorta, IVC are unremarkable.

IMPRESSION:

- ❖ Thickened endometrium.
- ❖ Uterine fibroid.
- ❖ Chronic cervicitis.

Advised: clinicopathological correlation

DR. ANUSHA MAHALAWAT
MD RADIODIAGNOSIS

Dr. Anusha Mahalawat
MD-(Radiodiagnosis)
(RMC. 38742/25457)

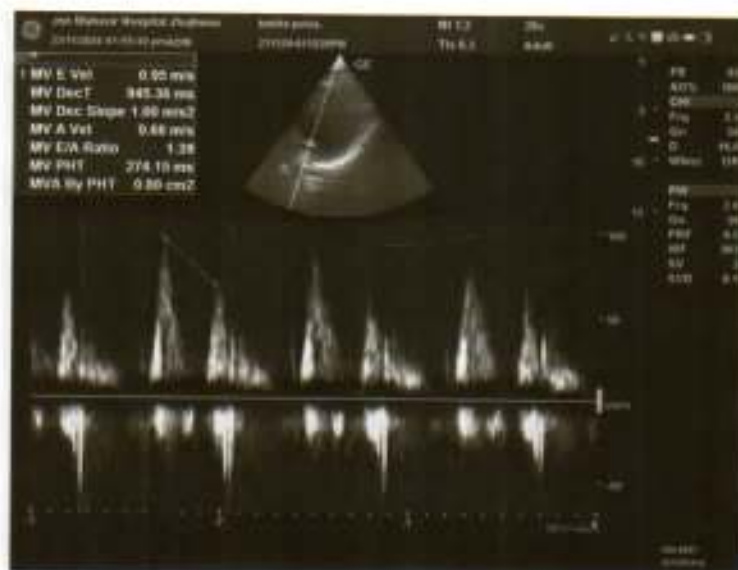
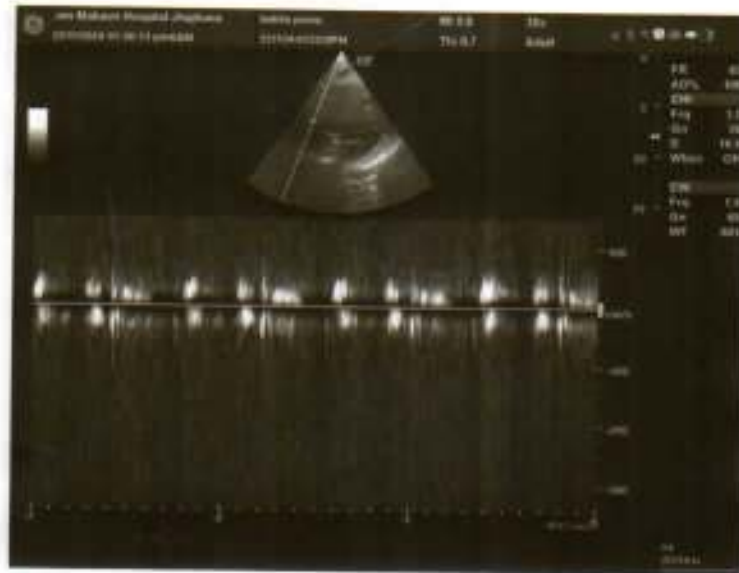
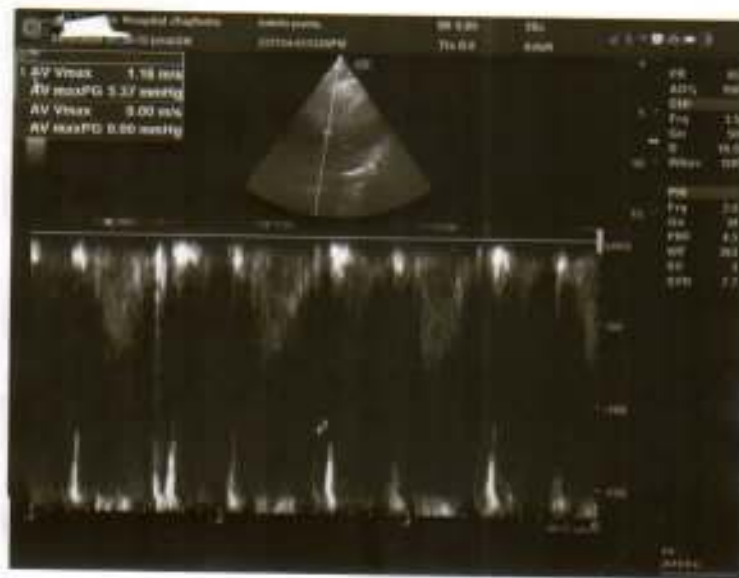

आपताकालीन सेवाएं

THIS REPORT IS NOT VALID FOR MEDICO LEGAL PURPOSE



B-110, Indra Nagar, Jhunjhunu (Raj.) Ph. No. 01592 294977





Name	:BABITA PUNIA	Father/Husband	:AJAY KUMAR PUNIA	IPD/OPD status	:OPD
Age/Sex	:46 Y/Female	Reg. No.	:OutSide	Category	:CASH
Consultant	:M. S. MEEL	Accession No.	:20241123021	Bed No.	:-
		BILL.NO	:2403246725	Date	:23/11/2024 11:58:27 AM

TRANSTHORACIC ECHO-DOPPLER TEST REPORT

MITRAL VALVE-

Morphology **AML**-Normal/Thickening/Calcification/Flutter/Restricted mobility/SAM/Doming.

PML-Normal/Thickening/Calcification/Prolapse/Fixed/Restricted Mobility/Flutter.

Doppler- Normal/Abnormal

Mitral E/A Velocity= 95/68 (cm/sec).

Mitral Regurgitation

Absent/Trace/Mild/Moderate/Severe.

Mitral Stenosis

Absent/Present.

TRICUSPID VALVE-

Morphology -Normal/Atresia/Thickening/Calcification/Prolapse/Doming.

Doppler- Normal/Abnormal

Tricuspid Regurgitation

Absent/Trace/Mild/Moderate/Severe.

Tricuspid Stenosis

Absent/Present.

PULMONARY VALVE-

Morphology -Normal/Atresia/Thickening/Doming/Vegetation.

Doppler- Normal/Abnormal

Pulmonary Velocity = 79 (cm/sec)

Pulmonary Regurgitation

Absent/Trace/Mild/Moderate/Severe.

Pulmonary Stenosis

Absent/Present.

AORTIC VALVE-

Morphology -Normal/Thickening/Calcification/Flutter/Sclerosis/Doming.

No of Cusps- 1/2/3.

Doppler- Normal/Abnormal

Aortic Velocity = 116 (cm/sec)

Aortic Regurgitation

Absent/Trace/Mild/Moderate/Severe.

Aortic Stenosis

Absent/Present.

Aorta = 2.6cm (2.0 - 3.7cm)

Left.Atrium = 4.5 cm (1.9 - 4.0 cm)

LV measurement

Diastole

Systole

IVS 1.3 cm (0.6-1.1cm) 1.5 cm

LVID 5.4 cm (3.7-5.6cm) 3.5 cm (2.2 - 4.0 cm)

LVPW 1.6 cm (0.6-1.1cm) 1.9 cm

LV Normal/Enlarged/Clear/Thrombus/**Hypertrophy.**

Contraction Normal/Reduced.

Regional wall motion abnormality : Present/**Absent.**

LA Normal/Enlarged/Clear/Thrombus.

RA Normal/Enlarged/Clear/Thrombus.

RV Normal/Enlarged/Clear/Thrombus.



This report is not valid for medico-legal purposes.

No Part of this report should be reproduced for any purpose

(कृपया अपनी पुरानी रिपोर्ट साथ लावें)

यह रिपोर्ट केवल चिकित्सा के लिए है। इसे कानून के लिए प्रमाण के रूप में उपयोग नहीं किया जाना चाहिए।

MAHAVIR HOSPITAL

Health & Hygiene

D-15, Indira Nagar, Subhash Marg, JHUNJHUNU (Raj.)



Tel. : 01592-232361
9680960962

MAHAVIR HOSPITAL

COMMENTS & SUMMARY-

ECHO window-Good/Fair/Poor.

No regional wall motion abnormality seen. LVEF=55%.

Mild left ventricular hypertrophy seen.


Mild MR, trace TR, no PAH.

Normal systolic function.

Normal diastolic function.

No I/C clot/vegetation.

Intact IAS/IVS & No CoA, no pericardial effusion.


Dr M S Meel
MD Medicine
Senior Physician

Dr. M.S. MEEL
MD (Medicine)
Reg. No. 7937/2635
Mahavir Hospital, Jhunjhunu

Dr. Pallavi Choudhary
MD Paediatrics
Consultant



This report is not valid for medico-legal purposes.
No Part of this report should be reproduced for any purpose

(कृपया अपनी पुरानी रिपोर्ट साथ लावें)

यह रिपोर्ट केवल चिकित्सा उद्देश्यों के लिए है।
इस रिपोर्ट को किसी भी प्रकार से प्रकाशित नहीं किया जा सकता है।



RAJASTHANI DIAGNOSTIC & MR CENTRE

FULLY COMPUTERISED PATHOLOGY LABORATORY

MRI

CT SCAN

TMT

SONOGRAPHY

X-RAY

ECG

MAMOGRAPHY

NAME : BABITA POONIA	AGE/SEX : F
REF.BY :SELF	DATE: 23-Nov-24

X-RAY CHEST (PA)

Both lung fields appear normal in under view

No e/o consolidation or cavitations is seen.

Both costo-phrenic angles appear clear.

Cardiac size is within normal limits.

Both domes of diaphragm appear normal.

Bony thoracic cage & soft tissue shadow appear normal.

IMPRESSION :- NORMAL X-RAY CHEST (PA)

[Signature]
 DR. ANUSHA MAHALAWAT
 MD (RADIODIAGNOSIS)
 RMC -38742/25457

Note - Please correlate the measurements on the typed report with the image and in case of any discrepancy/doubt, please contact us immediately. There is only a professional opinion and should be correlated clinically. No valid for medico-legal purpose.

MD (Radiodiagnosis)
 (RMC. 38742/25457)



THIS REPORT IS NOT VALID FOR MEDICO LEGAL PURPOSE



B-110, Indra Nagar, Jhunjhunu (Raj.) Ph. No. 01592-294977



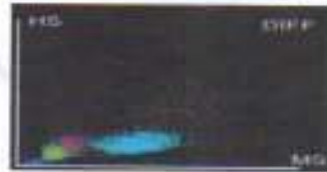
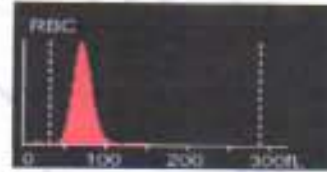Hematology Analysis Report

First Name: BABITA punia
Last Name:
Gender: Female
Age: 46 Year

Sample Type:
Department:
Med Rec. No.:

Sample ID: 4
Test Time: 23/11/2024 10:37
Diagnosis:

Parameter	Result	Ref. Range	Unit
1 WBC	5.11	4.00-10.00	10 ³ /uL
2 Neu%	57.7	50.0-70.0	%
3 Lym%	29.2	20.0-40.0	%
4 Mon%	7.5	3.0-12.0	%
5 Eos%	4.6	0.5-5.0	%
6 Bas%	1.0	0.0-1.0	%
7 Neu#	2.95	2.00-7.00	10 ³ /uL
8 Lym#	1.49	0.80-4.00	10 ³ /uL
9 Mon#	0.38	0.12-1.20	10 ³ /uL
10 Eos#	0.24	0.02-0.50	10 ³ /uL
11 Bas#	0.05	0.00-0.10	10 ³ /uL
12 RBC	3.81	3.50-5.50	10 ⁶ /uL
13 HGB	7.8 L	11.0-16.0	g/dL
14 HCT	29.0 L	37.0-54.0	%
15 MCV	76.2 L	80.0-100.0	fL
16 MCH	20.5 L	27.0-34.0	pg
17 MCHC	26.9 L	32.0-36.0	g/dL
18 RDW-CV	13.2	11.0-16.0	%
19 RDW-SD	41.7	35.0-56.0	fL
20 PLT	212	100-300	10 ³ /uL
21 MPV	10.9	6.5-12.0	fL
22 PDW	16.4	9.0-17.0	fL
23 PCT	0.231	0.108-0.282	%
24 P-LCR	45.9 H	11.0-45.0	%
25 P-LCC	97 H	30-90	10 ³ /uL



Mamta Khuteta
Dr. Mamta Khuteta
M.D. (Path.)
HMC No - 4720/16260

Submitter: Operator: admin Approver:
Draw Time: 23/11/2024 10:37 Received Time: 23/11/2024 10:37 Validated Time:
Report Time: 23/11/2024 16:13 Remarks:

*The Report is responsible for this sample only. If you have any questions, please contact us in 24 hours



THIS REPORT IS NOT VALID FOR MEDICO LEGAL PURPOSE





RAJASTHANI DIAGNOSTIC & MRI CENTRE




FULLY COMPUTERISED PATHOLOGY LABORATORY

MRI CT SCAN TMT SONOGRAPHY X-RAY ECG MAMOGRAPHY

NABL CERTIFICATE NO.
MC-5346

Patient Name: **BABITA PUNIA**
Sr. No. : 9
Patient ID No.: 12026
Age : 46 Gender : FEMALE
Ref. By Dr : MEDI-WHEEL HEALTH CHECKUP



Registered on : 23-11-2024 12:31 PM
Collected On : 23-11-2024 12:31 PM
Received On : 23-11-2024 12:31 PM
Reported On : 23-11-2024 04:16 PM
Bar Code 
LIS Number 8 0 4 3

LIPID PROFILE COMPLETE

Test Name	Observed Values	Units	Reference Intervals
Cholesterol (Method: CHOD-PAP)	H 245.00	mg/dL	Adults- Desirable: <200 Borderline: 200-239 High: >239 Children- Desirable: <170 Borderline: 170-199 High: >199
HDL Cholesterol	48.00	mg/dL	35-88
Triglycerides (Method: GPO)	104.00	mg/dL	Recommended triglycerides levels for adults: Normal: <161 High: 161-199 Hypertriglycerdemic: 200-499 Very high: >499
LDL Cholesterol	H 176.20	mg/dL	0-150
VLDL Cholesterol	20.80	mg/dL	0-35
TC/HDL Cholesterol Ratio	H 5.10	Ratio	2.5-5
LDL/HDL Ratio	H 3.67	Ratio	1.5-3.5

Ashish Sethi

Dr. Ashish Sethi
Consultant Biochemist



Manish Chaitik

Dr. Manish Chaitik
M.D. (P&C)
D.O. No. 1409/2023

PATHOLOGIST



This Report is Not Valid For Medico-Legal Purpose. Identification and name of person is not our responsibility. No part of this report should be reproduced. THIS REPORT IS NOT VALID FOR MEDICO-LEGAL PURPOSE. sex effect of drug and other relevant factor.



RAJSTHANI DIAGNOSTIC & MRI CENTRE




FULLY COMPUTERISED PATHOLOGY LABORATORY

MRI CT SCAN TMT SONOGRAPHY X-RAY ECG MAMOGRAPHY

NABL CERTIFICATE NO.
MC-5346

Patient Name: **BABITA PUNIA**
Sr. No. : 9
Patient ID No.: 12026
Age : 46 Gender : FEMALE
Ref. By Dr : MEDI-WHEEL HEALTH CHECKUP



Registered on : 23-11-2024 12:31 PM
Collected On : 23-11-2024 12:31 PM
Received On : 23-11-2024 12:31 PM
Reported On : 23-11-2024 04:16 PM
Bar Code 
LIS Number 3 0 4 3

HAEMATOLOGY

Test Name	Observed Values	Units	Reference Intervals
ESR (Erythrocyte Sedimentation Rate)	10	mm/hr	20
BLOOD GROUPING (ABO & Rh)	B+ Positive		



Ashish Sethi
Dr. Ashish Sethi
Consultant Biochemist



Navita Thakur
Dr. Navita Thakur
MBBS
DIPLOMA IN PATHOLOGY

PATHOLOGIST



This Report is Not Valid For Medico-Legal Purposes. *Identification and terms of report is not our responsibility.
No part of this report should be reproduced. THIS REPORT IS NOT VALID FOR MEDICO-LEGAL PURPOSE. sex effect of drug and other relevant factor



RAJASTHANI DIAGNOSTIC & MRI CENTRE



FULLY COMPUTERISED PATHOLOGY LABORATORY

MRI CT SCAN TMT SONOGRAPHY X-RAY ECG MAMOGRAPHY

NABL CERTIFICATE NO. MC-5346

Patient Name: BABITA PUNIA Sr. No. : 9 Patient ID No. : 12026 Age : 46 Gender : FEMALE Ref. By Dr : MEDI-WHEEL HEALTH CHECKUP		Registered on : 23-11-2024 12:31 PM Collected On : 23-11-2024 12:31 PM Received On : 23-11-2024 12:31 PM Reported On : 23-11-2024 04:16 PM Bar Code LIS Number 3 1 4 1
--	--	---

BIO-CHEMISTRY

Test Name	Observed Values	Units	Reference Intervals
Glucose Fasting <small>(Method: GOD-POD)</small>	76.00	mg/dL	Glucose Fasting Cord: 45-86 New born, 1d: 40-60 New born, >1d: 50-80 Child: 60-100 Adult: 74-100 >60 Y: 82-115 >69 Y: 75-121

KIDNEY FUNCTION TEST

Test Name	Observed Values	Units	Reference Intervals
Blood Urea <small>(Method: Ureaase-GUDH)</small>	26.00	mg/dL	Adults Women < 50 years : 13-40 Women > 50 years : 21-43 Men < 50 years : 19-45 Men > 50 years : 18-55 Children 1-3 years : 11-36 4-13 years : 15-36 13-19 years : 18-45
Creatinine <small>(Method: Enzymatic Creatinase)</small>	0.87	mg/dL	0.4-1.40
Calcium	9.52	mg/dL	8.5-11
Uric Acid <small>(Method: Uricase-POD)</small>	4.33	mg/dL	2.4-7.2

Ashish Sethi
Dr. Ashish Sethi
Consultant Biochemist

24/7
EMERGENCY SERVICE
LOGIST

Urvashi
Urvashi
Pathologist

PATHOLOGIST




This Report is Not Valid For Medical Legal Purposes. Identification and name of person is not our responsibility. No part of this report should be reproduced. THIS REPORT IS NOT VALID FOR MEDICO LEGAL PURPOSE. Sex effect of drug and other relevant factor.

B-110, Indra Nagar, Jhunjhunu (Raj.) Ph. No. 01592-294977



Patient Name: **BABITA PUNIA**
Sr. No. : 9
Patient ID No.: 12026
Age : 46 Gender : FEMALE
Ref. By Dr : MEDI-WHEEL HEALTH CHECKUP



Registered on : 23-11-2024 12:31 PM
Collected On : 23-11-2024 12:31 PM
Received On : 23-11-2024 12:31 PM
Reported On : 23-11-2024 04:16 PM
Bar Code 
LIS Number 8 0 4 3

BIO-CHEMISTRY Liver Function Test

Test Name	Observed Values	Units	Reference Intervals
SGOT/AST(Tech.: -UV Kinetic)	22.00	U/L	5-40
SGPT/ALT(Tech.: -UV Kinetic)	24.00	U/L	5-40
Bilirubin(Total) (Method: Glass)	0.75	mg/dL	Adults: 0-2, Cord < 2 Newborns, premature 0-1 day 1-8; 1-2 days : 6-12, 3-5 days : 10-14 Newborns, full term 0-1 day, 2-6, 1-2 days : 6-10, 3-5 days : 4-8
Bilirubin(Direct)	0.15	mg/dL	0-0.3
Bilirubin(Indirect)	0.60	mg/dL	0.1-1.0
Total Protein (Method: BIURET Method)	6.90	g/dL	Adults 6.4 - 8.3 Premature 3.6 - 6.0 Newborn : 4.6 - 7.0 1 Week : 4.4 - 7.6 7-12 months 5.1 - 7.3 1-2 Years : 5.6 - 7.5 > 2 Years : 6.0 - 8.0
Albumin(Tech.: -BCG) (Method: BCG)	3.89	gm/dL	0-4 days: 2.8-4.4 4d-14 yrs: 3.8-5.4 14y-18y : 3.2-4.5 Adults 20-60 yrs: 3.5-5.2 60-90 yrs: 3.2-4.6
Globulin(CALCULATION)	3.01	gm/dL	2.5-4.5
A/G Ratio(Tech.: -Calculated)	1.29		1.2 - 2.5
Alkaline Phosphatase(Tech.: -Pnp Amp Kinetic)	197.00	U/L	108-305

Ashish Sethi
Dr. Ashish Sethi
Consultant Biochemist



Urvashi Kulkarni
Urvashi Kulkarni
Pathologist

PATHOLOGIST



This Report is Not Valid For Medical Legal Purposes. * Identification and name of person and his responsibility. No part of this report should be reproduced. THIS REPORT IS NOT VALID FOR MEDICO LEGAL PURPOSE. sex effect of drug and other relevant factor



RAJASTHANI DIAGNOSTIC & MRI CENTRE



FULLY COMPUTERISED PATHOLOGY LABORATORY

MRI CT SCAN TMT SONOGRAPHY X-RAY ECC MAMOGRAPHY

NABL CERTIFICATE NO.
MC-5346

Patient Name: **BABITA PUNIA**

Sr. No. : 9

Patient ID No. : 12026

Age : 46 Gender : FEMALE

Ref. By Dr : MEDI-WHEEL HEALTH CHECKUP



Registered on : 23-11-2024 12:31 PM

Collected On : 23-11-2024 12:31 PM

Received On : 23-11-2024 12:31 PM

Reported On : 23-11-2024 04:16 PM

Bar Code



LIS Number

9 0 4 3

THYROID HORMONES T3,T4,TSH (THYROID PROFILE)

Test Name	Observed Values	Units	Reference Intervals
T3 (Total Triiodothyronine)	0.93	ng/mL	0.6 - 1.8 ng/mL
T4 (Total Thyroxine)	7.62	µg/dL	4.60-12.50 µg/dL
TSH (Thyroid Stimulating Hormone) H	7.20	µIU/mL	0.35-5.50

Sample Type : Serum

Test Performed by:-

Fully Automated Chemi Luminescent Immuno Assay (ARCHITECT- i1000 PLUS) Abbott USA

Remarks :

Primary malfunction of the Thyroid gland may result in excessive (hyper) or Low (hypo) release of T3 or T4. In addition, as TSH directly affect thyroid function, malfunction of the pituitary or the hypothalamus influences the thyroid gland activity.

Disease in any portion of the thyroid-pituitary-hypothalamus system may influence the level of T3 and T4 in the blood, in Primary Hypothyroidism, TSH levels are significantly elevated, while in secondary and tertiary hypothyroidism, TSH levels may be low. In addition, in Euthyroid sick syndrome, multiple alterations in serum thyroid function test findings have been recognized.

Ashish Sethi

Dr. Ashish Sethi
Consultant Biochemist

24/7
EMERGENCY SERVICE
LOGIST

Kavita Bhatia
Dr. Kavita Bhatia
MBBS, DGO, DNB
Gynaecologist

PATHOLOGIST



This Report is Not Valid For Medical Legal Purposes. * Identification and name of patient is not our responsibility. No part of this report should be reproduced. THIS REPORT IS NOT VALID FOR MEDICO LEGAL PURPOSE. sex effect of drug and other relevant factor.



RAJASTHANI DIAGNOSTIC & MRI CENTRE



FULLY COMPUTERISED PATHOLOGY LABORATORY

MRI CT SCAN TMT SONOGRAPHY X-RAY ECG MAMOGRAPHY

NABL CERTIFICATE NO.
MC-5346

Patient Name: **BABITA PUNIA**
Sr. No. : 9
Patient ID No. : 12026
Age : 46 Gender : FEMALE
Ref. By Dr : MEDI-WHEEL HEALTH CHECKUP



Registered on : 23-11-2024 12:31 PM
Collected On : 23-11-2024 12:31 PM
Received On : 23-11-2024 12:31 PM
Reported On : 23-11-2024 04:16 PM
Bar Code
LIS Number

URINE EXAMINATION URINE COMPLETE

Test Name	Observed Values	Units	Reference Intervals
PHYSICAL			
Quantity	20	ml	
Colour	Pale Yellow		
Appearance / Transparency	Clear		
Specific Gravity	1.020		
PH	6.0		4.5-6.5

CHEMICAL

Reaction	Acidic		
Albumin	trace		
Urine Sugar	Nil		

MICROSCOPIC

Red Blood Cells	Nil	/h.p.f.	
Pus Cells	2-3	/h.p.f.	
Epithelial Cells	1-2	/h.p.f.	
Crystals	Nil	/h.p.f.	
Casts	Nil	/h.p.f.	
Bacteria	Nil	/h.p.f.	
Others	Nil	/h.p.f.	

Test Name	Observed Values	Units	Reference Intervals
URINE SUGAR FASTING	Nil		

<<< END OF REPORT >>>

>>> Results relate only to the sample as received. Kindly correlate with clinical condition. <<<

Note: This report is not valid for medico legal purposes.

Ashish Sathi

Dr. Ashish Sathi
Consultant Biochemist



Wendy Bhatia
Sr. Health Officer
NABL (I) 12026
23-11-2024

PATHOLOGIST



This Reports is Not Valid For Medico Legal Purpose. Identification and responsibility. No part of this report should be reproduced. THIS REPORT IS NOT VALID FOR MEDICO LEGAL PURPOSE. sex effect of drug and other relevant factor

B-110, Indra Nagar, Jhunjhunu (Raj.) Ph. No. 01592-294977



RAJASTHANI DIAGNOSTIC & MR CENTRE

FULLY COMPUTERISED PATHOLOGY LABORATORY

MRI

CT SCAN

TMT

SONOGRAPHY

X-RAY

ECG

MAMMOGRAPHY

Patient ID		Patient Name	BABITA POONIA
Age	46 Yrs.	Date	23-Nov-24
Gender	FEMALE	Ref Doctor	SELF

MAMMOGRAPHY-BILATERAL BREASTS


FINDINGS:

1. BREAST COMPOSITION: Heterogeneous fibro glandular tissue present.
2. MASS: No definite mass lesions identified.
3. CALCIFICATIONS: None.
4. DILATED DUCTS: None.
5. INTRA-MAMMARY NODE: Nil.
6. ASYMMETRIC BREAST TISSUE: Nil.

IMPRESSION:

No significant abnormality.

Suggested USG and clinical correlation.


 DR. ANUSHA MAHALAWAT
 MD (RADIODIAGNOSIS)
 RMC -38742/25457



Note - Please correlate the measurements on the typed report with the image and in case of any discrepancy/doubt, please contact us immediately. There is only a professional opinion and should be correlated clinically. No valid for medico-legal purpose.



THIS REPORT IS NOT VALID FOR MEDICO LEGAL PURPOSE

B-110, Indra Nagar, Jhunjhunu (Raj.) Ph. No. 01592-294977