

Name: Santosh Korgaonkar Age: 51 Sex: M Date: 4/3/24
 H/O HTN } ↓ medical
 DM }

Rx

→ Teeth carious $\frac{843}{876} \mid \frac{8}{67}$

- Root pieces $\frac{8}{87} \mid \frac{8}{7}$

- Generalised plaque, calculus & stains ++

Rx required

→ Extrn $\frac{8}{87} \mid \frac{8}{7}$

→ RCT $\frac{6}{6} \mid \frac{6}{6}$

→ Restn $\frac{43}{43} \mid \frac{43}{43}$

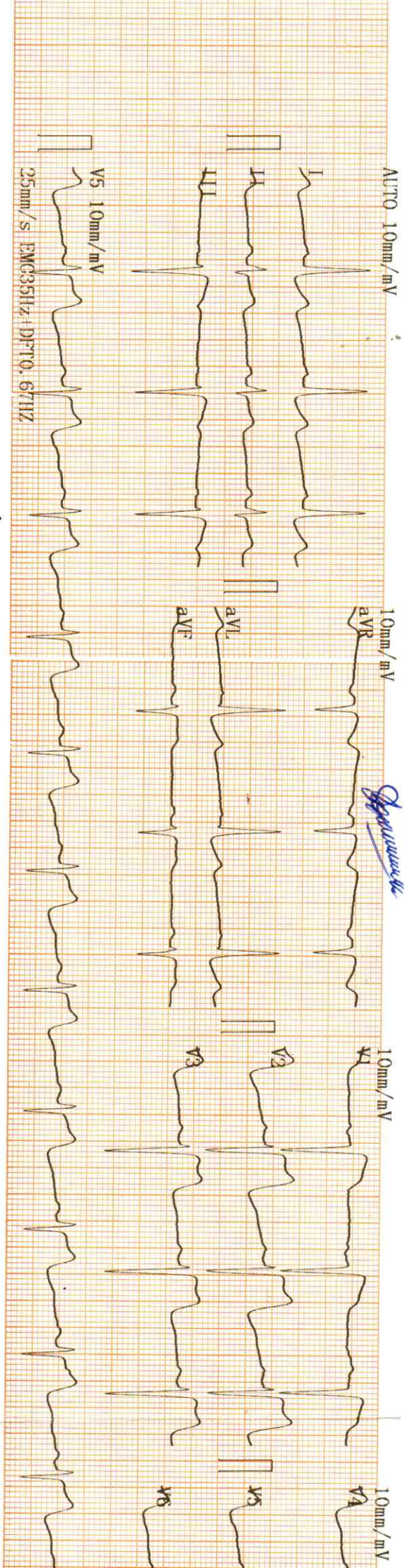
→ Oral prophylaxis

→ PD $\frac{7}{7} \mid \frac{7}{7}$

→ FC $\frac{6}{6} \mid \frac{6}{6}$



Dr. Madhika R. Madhika
Dr. Madhika R. Madhika
 B.D.S., M.D.S. (Co)
 Consulting Prosthodontist & Implantology
 Reg. No: A-758



AUTO 10mm/mV

10mm/mV

10mm/mV

10mm/mV

I

II

III

aVR

aVL

aVF

V1

V2

V3

V4

V5

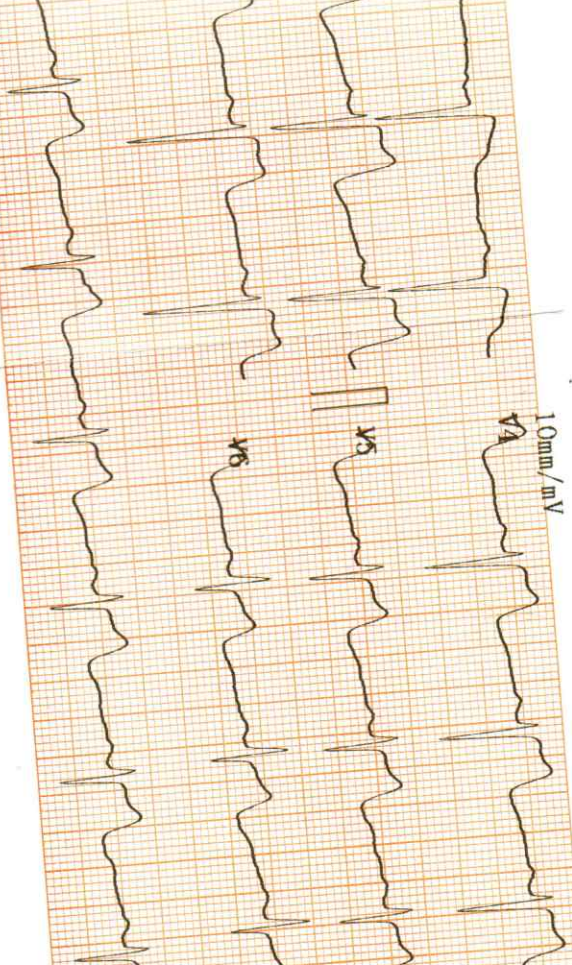
V6

V5 10mm/mV

25mm/s EMG35Hz+DF10.67Hz

Signature

2024-03-04 09:26



ID : santosh korgaonkar
 Name : Male
 Sex : Male
 Age : 51
 Height : cm
 Weight : kg
 SYS : mmHg
 DIA : mmHg
 HR : 71 bpm
 PR Interval : 176 ms
 P Duration : 120 ms
 QRS Duration : 85 ms
 T Duration : 172 ms
 QT/QTc : 356/386 ms
 P/QRS/T Axis : 46.4/-23.2/93.0 deg
 R (V5) / S (V1) : 0.34/1.10 mV
 R (V5) / S (V1) : 1.43 mV



Conclusions >>

Normal Sinus Rhythm,
 Middling left axis deviation,
 ST depression, high lateral myocardial ischemia.

DR. SUDHIR SHET
 M.D.
 CONSULTANT PHYSICIAN
 Reg. No.: GMC 3776
 Physician

DR. O. MORAES DE SOUZA

M.S (BOM.), D.O.M.S. (C.P.S)

Ex -Sr. Ophthalmic Surgeon - Hospicio Hospital
EYE SPECIALIST & MICRO - SURGEON

Clinic :

Ashirwad Bldg. II,
Above City Hospital,
Opp. Meenaxi Hotel,
MARGOA - GOA - 403601
Tel.: (C) 2713804 / 8237886021

Timings :

Morning : 10 a.m. to 1p.m.
Evening : 4.30 p.m to 7 p.m.
Except SATURDAY EVENINGS
& SUNDAYS

Date 4/3/24

Santosh. Kargantkar

No complaints.

VA 6/6 for distance

Near vision N/5

Colour vision: Normal

Fundus: Normal B/E


DR. O. MORAES DE SOUZA
M.S (Bom.), D.O.M.S. (C.P.S.)
Ex-Sr. Ophthalmic Surgeon - Hospicio Hospital
EYE SPECIALIST & MICRO - SURGEON
Reg. No. GMC 410

Please bring this prescription on your next visit.



सत्यमेव जयते

भारत सरकार

GOVERNMENT OF INDIA

Issue Date: 04/02/2012



Santosh Gokuldas Korgaonkar

जन्म तिथि / DOB: 20/06/1973

पुरुष / MALE

Mobile No.: 9730231759

5058 4107 4514

VID : 9102 4646 2630 9491

मेरा **आधार**, मेरी पहचान

CITY ULTRASOUND CLINIC

Dr Madkaiker's City hospital
"Ashirwad bldg" 1st floor,
Opp Meenaxi hotel
Isidor Baptista road,
Margao- Goa 403601

Name: MR SANTOSH KORGAONKER
Age: 51 years/M.

Ref: CITY HOSPITAL/Mediwheel
Date: 4/3/2024

ABDOMINAL SONOGRAPHY

LIVER Liver parenchyma shows bright echotexture
Size of liver WITHIN NORMAL LIMITS
No echogenic or echolucent mass lesion seen.
Intrahepatic branching of hepatic & portal radicles within
Normal limits.
No abscess formation noted. No cyst or hematoma.
Epigastria tenderness NIL

GALL-BLADDER: Well DISTENDED no evidence of biliary calculi.
No free fluid around gall bladder

SPLEEN : Normal in size 11x7.3cmss with no any focal lesion.
PANCREAS : Maintained in its size with normal echotexture. No per pancreatic fluid seen

RIGHT KIDNEY: Measures 9.4 x 5.3cms.
Pelvi -calyceal system appears normal.
No hydronephrosis.

LEFT KIDNEY : Measures 10. X 5.1 cms
Echotexture is normal.

PARA AORTIC REGION : Appears Normal.
No free fluid seen

URINARY BLADDER : Fully distended.
No free fluid in abdomen. Wall thickening present 4mm

Prostate: , Normal echotexture vol 37.22 CC

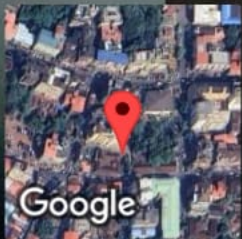
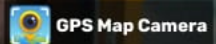
IMPRESSION: Fatty Liver
Prostatomegaly




SONOLOGIST
CITY HOSPITAL
Dr R MADKAIKER



Dr. Raj R. Madkaikar
M. B. B. S. D.G.O. D.M.A.S. F.I.C.S. A.F.I.H.
Consulting Obstetrician & Gynaecologist
Laparoscopist & Assisted Reproductive Medicine



Margao, Goa, India

Isidor Baptista road City hospital, Ashirwad building first floor,
opposite Meenaxi Hotel, Pajifond, Margao, Goa 403601, India
Lat 15.272167°

Long 73.961546°

04/03/24 09:08 AM GMT +05:30

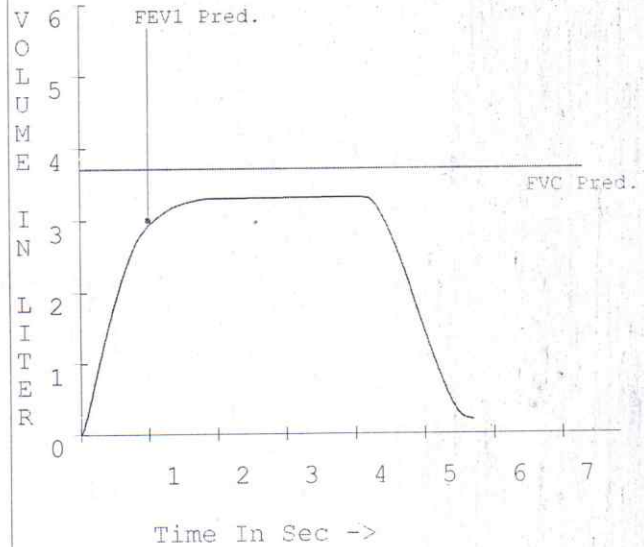
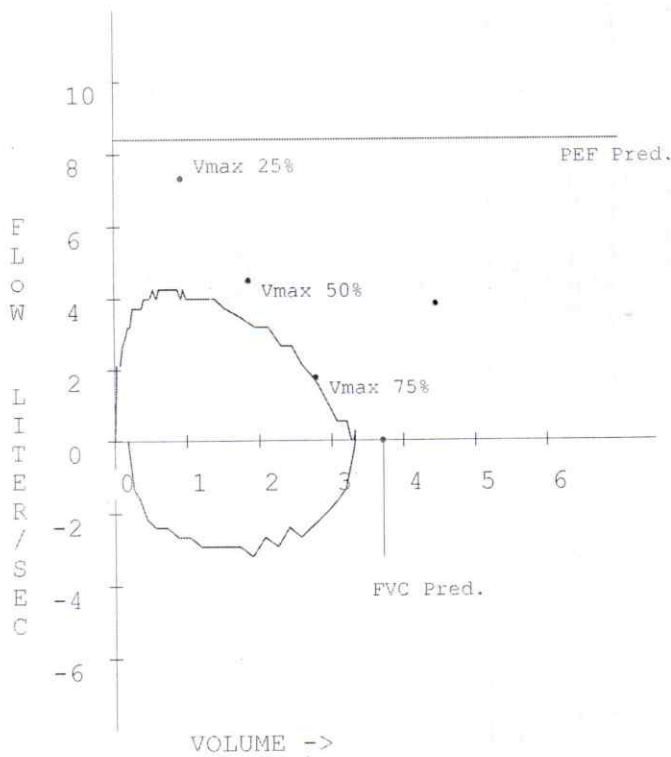
Dr.Madkaiker's CITY HOSPITAL
Margao Goa

Patient Information

Name : **Santosh Gokuldas Korgaonkar** DATE : 04/03/24 10:28:07

AGE : 51 /M ID : 237 Height : 170
REF.BY : Dr.Mediwheel Weight : 82
Indication: Smoker : Non Smoker

Pre _____
Post _____



Parameter	Predict Value	Observed		Pre.dif%
		Pre	%Pred	
FVC (L)	3.71	3.32	89.38	
FEV0.5 (L)		1.82		
FEV1 (L)	3.01	2.92	97.12	
FEV1/FVC %	80.97	87.98	108.65	
PEF (L/S)	8.40	4.39	52.27	
PIF (L/S)		3.19		
FEF25-75% (L/S)	3.81	3.37	88.58	
VMax25 %	7.33	4.39	59.84	
VMax50 %	4.51	3.59	79.58	
VMax75 %	1.77	2.39	135.16	
FET100 %		4.07		
FEF50 % (L/S)		3.59		
FIF50 % (L/S)		2.79		
FEF50/FIF50 %		1.29		

Diagnosis :

Normal Spirometry (FVC and FEV1/FVC > 80% of Predicted value)
Lung Age : 54

Dr. Raj R. Madkaiker
MBBS, DGO, DMAS, FMAS, AFIM
GMC Reg. No. 3474

Dr. _____

Dr. Madkaikar's
CITY HOSPITAL

4/3/24

Mr. Santosh Gokuldas Forgaonkar
Age : 51yrs

Patient Doesn't want to do TMT
because of the knee problem.



Handwritten signature/initials

Handwritten signature

CONS. / HOSP.:
ASHIRWAD BLDG., 1ST FLOOR, OPP. MINAXI HOTEL,
MARGAO - GOA. PH.: 0832-2714354 (HOSP.) Cell : 9784788585
