



## DEPARTMENT OF PATHOLOGY

Patient Name : Mr. VIKAS SHARMA  
 MR No : 30291  
 Age/Sex : 36 Years 1 Months 17 Days / Male  
 Type : OPD  
 TPA/Corporate : MEDIWHEEL  
 Bill Date : 08/03/2024  
 Reporting Date : 08/03/2024  
 Sample ID : 71048  
 Bill/Req. No. : 24093571  
 Ref Doctor : Dr.CONULTANT

Test	Result	Bio. Ref. Interval	Units
<b>URINE ROUTINE AND MICROSCOPY</b>			
<b>PHYSICAL CHARACTERSTICS</b>			
QUANTITY	30.0 ML	5 - 100	ML
COLOUR	Pale Yellow		
TURBIDITY	Clear	clear	
SPECIFIC GRAVITY	1.005	1.003 - 1.030	
PH	6.5	Acidic	
<b>CHEMICAL EXAMINATION-1</b>			
URINE PROTEIN	NIL	NIL	
GLUCOSE	NIL	NIL	
<b>MICRO.EXAMINATION</b>			
PUS CELL	0 - 1/HPF		CELLS/HPF
RED BLOOD CELLS	Nil	0-2	CELLS/HPF
EPITHELIAL CELLS	1-2/HPF	0-5	CELLS/HPF
CASTS	NIL	NIL	CELLS/HPF
CRYSTALS	NIL	NIL	CELLS/HPF
OTHER	NIL		

\*\*\*\*\* END OF THE REPORT \*\*\*\*\*



Sample no.

Dr. VAISHAL YADAV    Dr.REETU JADHAV    Dr. PARDIP KUMAR    S.C.GAUR  
 CONS.PATHOLOGIST    CONS.PATHOLOGIST    MICROBIOLOGIST & ICO    LAB INCHARGE    USER NM    PRIYANKA

(This is only professional opinion and not the diagnosis, Please correlate clinically)

J-Block, Sector-10, Near Court, Faridabad - 121004, Haryana

Tel.: 0129-4200000 E-mail : parkfaridabad@gmail.com





**DEPARTMENT OF PATHOLOGY**

Patient Name : Mr. VIKAS SHARMA	Bill Date : 08/03/2024
MR No : 30291	Reporting Date : 09/03/2024
Age/Sex : 36 Years 1 Months 17 Days / Male	Sample ID : 71048
Type : OPD	Bill/Req. No. : 24093571
TPA/Corporate : MEDIWHEEL	Ref Doctor : Dr. CONSULTANT

Test	Result	Bio. Ref. Interval	Units
<b>PSA - TOTAL (PROSTATIC SPECIFIC ANTIGEN) - CANCER MARKER</b>			
PROSTATE SPECIFIC ANTIGEN(PSA)	0.55	0.0 - 4.0	ng/ml

**Note :** Decrease in total PSA level is seen 24 to 48 hours after ejaculation. Decrease in total PSA level occurs after prostate ctomy and orchidectomy. successful radiation therapy and therapy with anti-androgen drugs result in decline in PSA levels, over a period of time.  
 \*Results of these tests should always be interpreted in conjunction with patients medical history, clinical presentation and other findings.  
 \*The test has been performed in Park Hospital Sector-47, Gurgaon.

OUT SOURCE  
PARK HOSPITAL  
GGN

\*\*\*\*\* END OF THE REPORT \*\*\*\*\*



Sample no.

Dr. VAISHALI YADAV    Dr. REETU JADHAV    Dr. PARDIP KUMAR    S.C. GAUR  
 CONS. PATHOLOGIST    CONS. PATHOLOGIST    MICROBIOLOGIST & ICO    LAB INCHARGE    USER NM    SUNIL

(This is only professional opinion and not the diagnosis, Please correlate clinically)

J-Block, Sector-10, Near Court, Faridabad - 121004, Haryana  
 Tel.: 0129-4200000 E-mail : parkfaridabad@gmail.com





**DEPARTMENT OF PATHOLOGY**

Patient Name : Mr. VIKAS SHARMA	Bill Date : 08/03/2024
MR No : 30291	Reporting Date : 09/03/2024
Age/Sex : 36 Years 1 Months 17 Days / Male	Sample ID : 71048
Type : OPD	Bill/Req. No. : 24093571
TPA/Corporate : MEDIWHEEL	Ref Doctor : Dr.CONSULTANT

Test	Result	Bio. Ref. Interval	Units
<b>THYROID PROFILE</b>			
TRI-IODOTHYRONINE (T3)	1.35	0.60 - 1.81	ng/ml
THYROXINE (T4)	8.7	5.01 - 12.45	µg/dL
THYROID STIMULATING HORMONE	3.57	0.5-5.50	µIU/ml

\*\*\*\*\* END OF THE REPORT \*\*\*\*\*

OUT SOURCE  
PARK HOSPITAL  
GGN



Sample no.

Dr. VAISHALI YADAV    Dr. REETU JADHAV    Dr. PARDIP KUMAR    S.C. GAUR  
CONS.PATHOLOGIST    CONS.PATHOLOGIST    MICROBIOLOGIST & ICO    LAB INCHARGE    USER NM    SUNIL

(This is only professional opinion and not the diagnosis, Please correlate clinically)

J-Block, Sector-10, Near Court, Faridabad - 121004, Haryana

Tel.: 0129-4200000 E-mail : parkfaridabad@gmail.com





## DEPARTMENT OF PATHOLOGY

**Patient Name** : Mr. VIKAS SHARMA  
**MR No** : 30291  
**Age/Sex** : 36 Years 1 Months 17 Days / Male  
**Type** : OPD  
**TPA/Corporate** : MEDIWHEEL  
**Bill Date** : 08/03/2024  
**Reporting Date** : 08/03/2024  
**Sample ID** : 71048  
**Bill/Req. No.** : 24093571  
**Ref Doctor** : Dr.CONULTANT

Test	Result	Bio. Ref. Interval	Units
<b>CBC</b>			
*HAEMOGLOBIN	14.1	12 - 16	gm/dL
PACKED CELL VOLUME	44.4	35.0 - 50.0	%
RED BLOOD CELL COUNT	4.66	3.5 - 5.5	millions/ $\mu$ L
MEAN CORPUSCULAR VOLUME	95.2	83 - 101	fL
MEAN CORPUSCULAR HAEMOGLOBIN	30.3	27 - 31	pg
MEAN CORPUSCULAR HB CONC	<b>31.8 L</b>	33 - 37	g/dl
RDW	13.6	11.6 - 14.5	%
TOTAL LEUCOCYTE COUNT	8040	4000-11000	/ $\mu$ L
<b>DIFFERENTIAL COUNT</b>			
NEUTROPHILS	60	40.0 - 80.0	%
LYMPHOCYTES	30	20 - 40	%
MONOCYTES	06	2.0 - 10.0	%
EOSINOPHILS	04	0.0 - 5.0	%
BASOPHILS	00	0.0 - 2.0	%
* PLATELET COUNT	<b>1.15 BY SLIDE LL</b>	1.50 - 4.50	lac/cumm

\*\*\*\*\* END OF THE REPORT \*\*\*\*\*



Sample no.

Dr. VAISHALI YADAV    Dr. REETU JADHAV    Dr. PARDIP KUMAR    S.C. GAUR  
 CONS. PATHOLOGIST    CONS. PATHOLOGIST    MICROBIOLOGIST & ICO    LAB INCHARGE    USER NM    PRIYANKA

(This is only professional opinion and not the diagnosis, Please correlate clinically)

J-Block, Sector-10, Near Court, Faridabad - 121004, Haryana

Tel.: 0129-4200000 E-mail : parkfaridabad@gmail.com





**DEPARTMENT OF PATHOLOGY**

Patient Name : Mr. VIKAS SHARMA

MR No : 30291

Age/Sex : 36 Years 1 Months 17 Days / Male

Type : OPD

TPA/Corporate : MEDIWHEEL

Bill Date : 08/03/2024

Reporting Date : 08/03/2024

Sample ID : 71048

Bill/Req. No. : 24093571


Ref Doctor : Dr. CONSULTANT

Test	Result	Bio. Ref. Interval	Units
------	--------	--------------------	-------

**BLOOD GROUPING AND rh FACTOR**

BLOOD GROUP	" O " Rh POSITIVE		
-------------	-------------------	--	--

\*\*\*\*\* END OF THE REPORT \*\*\*\*\*



Sample no.

Dr. VAISHALI YADAV    Dr. REETU JADHAV    Dr. PARDIP KUMAR    S.C. GAUR  
CONS. PATHOLOGIST    CONS. PATHOLOGIST    MICROBIOLOGIST & ICO LAB INCHARGE    USER NM PRIYANKA

(This is only professional opinion and not the diagnosis, Please correlate clinically)

J-Block, Sector-10, Near Court, Faridabad - 121004, Haryana

Tel.: 0129-4200000 E-mail : parkfaridabad@gmail.com





**DEPARTMENT OF PATHOLOGY**

Patient Name : Mr. VIKAS SHARMA  
MR No : 30291  
Age/Sex : 36 Years 1 Months 17 Days / Male  
Type : OPD  
TPA/Corporate : MEDIWHEEL  
Bill Date : 08/03/2024  
Reporting Date : 08/03/2024  
Sample ID : 71048  
Bill/Req. No. : 24093571  
Ref Doctor : Dr. CONSULTANT

Test	Result	Bio. Ref. Interval	Units
<b>BLOOD SUGAR 2 HR. PP</b>			
BLOOD SUGAR P.P.	131.12	80 - 150	mg/dl

\*\*\*\*\* END OF THE REPORT \*\*\*\*\*



Sample no.

Dr. VAISHALI YADAV    Dr. REETU JADHAV    Dr. PARDIP KUMAR    S.C. GAUR  
CONS. PATHOLOGIST    CONS. PATHOLOGIST    MICROBIOLOGIST & ICO    LAB INCHARGE    USER NM    PRIYANKA

(This is only professional opinion and not the diagnosis, Please correlate clinically)

J-Block, Sector-10, Near Court, Faridabad - 121004, Haryana  
Tel.: 0129-4200000 E-mail : parkfaridabad@gmail.com






## DEPARTMENT OF PATHOLOGY

Patient Name : Mr. VIKAS SHARMA  
 MR No : 30291  
 Age/Sex : 36 Years 1 Months 17 Days / Male  
 Type : OPD  
 TPA/Corporate : MEDIWHEEL

Bill Date : 08/03/2024  
 Reporting Date : 08/03/2024  
 Sample ID : 71048  
 Bill/Req. No. : 24093571  
 Ref Doctor : Dr. CONSULTANT

Test	Result	Bio. Ref. Interval	Units
<b>LFT (LIVER FUNCTION TEST)</b>			
<b>LFT</b>			
TOTAL BILIRUBIN	1.0	0 - 1.2	mg/dL
DIRECT BILIRUBIN	0.3	0 - 0.4	mg/dL
INDIRECT BILIRUBIN	<b>0.7 H</b> H	0.10 - 0.6	mg/dL
SGOT (AST)	<b>86 H</b> H	0 - 45	U/L
SGPT (ALT)	<b>160 H</b> H	0 - 45	U/L
ALKALINE PHOSPHATASE	<b>183.9 H</b> H	30 - 170	IU/L
TOTAL PROTEIN	6.8	6.4 - 8.0	g/dL
ALBUMIN	4.1	3.3 - 5.5	g/dL
GLOBULIN	2.7	2.3 - 4.5	g/dL
A/G RATIO	1.52	1.1 - 2.2	g/dL

\*\*\*\*\* END OF THE REPORT \*\*\*\*\*



Sample no.

Dr. VAISHALI YADAV    Dr. REETU JADHAV    Dr. PARDIP KUMAR    S.C. GAUR  
 CONS. PATHOLOGIST    CONS. PATHOLOGIST    MICROBIOLOGIST & ICO    LAB INCHARGE    USER NM    PRIYANKA

(This is only professional opinion and not the diagnosis, Please correlate clinically)

J-Block, Sector-10, Near Court, Faridabad - 121004, Haryana  
 Tel.: 0129-4200000 E-mail : parkfaridabad@gmail.com





**DEPARTMENT OF PATHOLOGY**

Patient Name : Mr. VIKAS SHARMA  
MR No : 30291  
Age/Sex : 36 Years 1 Months 17 Days / Male  
Type : OPD  
TPA/Corporate : MEDIWHEEL

Bill Date : 08/03/2024  
Reporting Date : 08/03/2024  
Sample ID : 71048  
Bill/Req. No. : 24093571  
Ref Doctor : Dr. CONSULTANT

Test	Result	Bio. Ref. Interval	Units
<b>KFT (RENAL PROFILE)</b>			
<b>KFT</b>			
SERUM UREA	22	10 - 45	mg/dL
SERUM CREATININE	1.0	0.4 - 1.4	mg/dL
SERUM URIC ACID	<b>7.1 H</b> <i>H</i>	2.5 - 7.0	mg/dL
SERUM SODIUM	136	136 - 148	mmol/L
SERUM POTASSIUM	3.6	3.5 - 5.5	mmol/L
CHLORIDE	96.0	96 - 106	mmol/L

\*\*\*\*\* END OF THE REPORT \*\*\*\*\*



Sample no.

Dr. VAISHALI YADAV    Dr. REETU JADHAV    Dr. PARDIP KUMAR    S.C. GAUR  
CONS. PATHOLOGIST    CONS. PATHOLOGIST    MICROBIOLOGIST & ICO    LAB INCHARGE    USER NM    PRIYANKA

(This is only professional opinion and not the diagnosis, Please correlate clinically)

J-Block, Sector-10, Near Court, Faridabad - 121004, Haryana

Tel.: 0129-4200000 E-mail : parkfaridabad@gmail.com





**DEPARTMENT OF PATHOLOGY**

Patient Name : Mr. VIKAS SHARMA  
MR No : 30291  
Age/Sex : 36 Years 1 Months 17 Days / Male  
Type : OPD  
TPA/Corporate : MEDIWHEEL  
Bill Date : 08/03/2024  
Reporting Date : 08/03/2024  
Sample ID : 71048  
Bill/Req. No. : 24093571  
Ref Doctor : Dr.CONULTANT

Test	Result	Bio. Ref. Interval	Units
<b>BLOOD SUGAR FASTING</b>			
PLASMA GLUCOSE FASTING	91.10	60 - 110	mg/dl

\*\*\*\*\* END OF THE REPORT \*\*\*\*\*



Sample no.

Dr. VAISHALI YADAV    Dr. REETU JADHAV    Dr. PARDIP KUMAR    S.C. GAUR  
CONS. PATHOLOGIST    CONS. PATHOLOGIST    MICROBIOLOGIST & ICO    LAB INCHARGE    USER NM    PRIYANKA

(This is only professional opinion and not the diagnosis, Please correlate clinically)

J-Block, Sector-10, Near Court, Faridabad - 121004, Haryana  
Tel.: 0129-4200000 E-mail : parkfaridabad@gmail.com





**DEPARTMENT OF PATHOLOGY**

Patient Name : Mr. VIKAS SHARMA  
 MR No : 30291  
 Age/Sex : 36 Years 1 Months 17 Days / Male  
 Type : OPD  
 TPA/Corporate : MEDIWHEEL

Bill Date : 08/03/2024  
 Reporting Date : 08/03/2024  
 Sample ID : 71048  
 Bill/Req. No. : 24093571  
 Ref Doctor : Dr.CONULTANT

Test	Result	Bio. Ref. Interval	Units
<b>LIPID PROFILE</b>			
<b>LIPID PROFILE</b>			
TOTAL CHOLESTEROL	<b>242.21 H</b>	120.0 - 200.0	mg/dL
SERUM TRIGLYCERIDES	<b>174.56 H</b>	40.0 - 160.0	mg/dl
HDL-CHOLESTEROL	58.17	30 - 70	mg/dl
VLDL CHOLESTEROL	<b>34.91 H</b>	6 - 32	mg/dL
LDL	<b>149.13 H</b>	50 - 135	mg/dl
LDL CHOLESTEROL/HDL RATIO	2.56	1.0 - 3.0	mg/dL
TOTAL CHOLESTEROL/HDL RATIO	4.16	2.0 - 5.0	mg/dl

\*\*\*\*\* END OF THE REPORT \*\*\*\*\*



Sample no.

Dr. VAISHALI YADAV    Dr. REETU JADHAV    Dr. PARDIP KUMAR    S.C. GAUR  
 CONS. PATHOLOGIST    CONS. PATHOLOGIST    MICROBIOLOGIST & ICO    LAB INCHARGE    USER NM    PRIYANKA

(This is only professional opinion and not the diagnosis, Please correlate clinically)

J-Block, Sector-10, Near Court, Faridabad - 121004, Haryana

Tel.: 0129-4200000 E-mail : parkfaridabad@gmail.com





**DEPARTMENT OF PATHOLOGY**

Patient Name : Mr. VIKAS SHARMA  
MR No : 30291  
Age/Sex : 36 Years 1 Months 17 Days / Male  
Type : OPD  
TPA/Corporate : MEDIWHEEL

Bill Date : 08/03/2024  
Reporting Date : 08/03/2024  
Sample ID : 71048  
Bill/Req. No. : 24093571  
Ref Doctor : Dr. CONSULTANT

Test	Result	Bio. Ref. Interval	Units
------	--------	--------------------	-------

**HB A1C GLYCOSYLATED HAEMOGLOBIN**

HBA1C	5.7		%
-------	-----	--	---

Note : Non-Diabetics 4.0 - 6.0 %

In Diabetics  
Good Control 6.1 - 6.8 %  
Fair Control 6.9 - 7.6 %  
Poor Control > 7.6 %

\*\*\*\*\* END OF THE REPORT \*\*\*\*\*

OUT SOURCE  
PARK HOSPITAL  
GGN



Sample no.

Dr. VAISHALI YADAV    Dr. REETU JADHAV    Dr. PARDIP KUMAR    S.C. GAUR  
CONS. PATHOLOGIST    CONS. PATHOLOGIST    MICROBIOLOGIST & ICO    LAB INCHARGE    USER NM    SEHDEV

(This is only professional opinion and not the diagnosis, Please correlate clinically)

J-Block, Sector-10, Near Court, Faridabad - 121004, Haryana  
Tel.: 0129-4200000 E-mail : parkfaridabad@gmail.com





**DEPARTMENT OF RADIOLOGY**

Patient Name	Mr VIKAS SHARMA	Billed Date	: 08/03/2024	9.26 AM
Reg No	30291	Reported Date	: 08/03/2024	
Age/Sex	36 Years 1 Months 17Days / Male	Req. No.	: 24093571	
Type	OPD	Consultant Doctor	: Dr. CONSULTANT	

**X-RAY CHEST AP/PA**

Bilateral lungs appears normal.

Both hila are normal in size, have equal density and bear normal relationship.

The heart and trachea are central in position and no mediastinal abnormality is visible.

The cardiac size is normal for patient age and view.

The domes of the diaphragms are normal in position and show smooth outline.

**To be correlated clinically**

DR BINO KR CHAUDHARY  
MBBS, MD  
CONSULTANT RADIOLOGIST

(This is only professional opinion and not the diagnosis, Please correlate clinically)

J-Block, Sector-10, Near Court, Faridabad - 121004, Haryana

Tel.: 0129-4200000 E-mail : parkfaridabad@gmail.com





## DEPARTMENT OF RADIOLOGY

Patient Name	Mr VIKAS SHARMA	Billed Date	: 08/03/2024	9.26 AM
Reg No	30291	Reported Date	: 08/03/2024	
Age/Sex	36 Years 1 Months 17Days / Male	Req. No.	: 24093571	
Type	OPD	Consultant Doctor	: Dr. CONSULTANT	

### USG WHOLE ABDOMEN

**LIVER** : The liver is normal in size, shape and **shows increased echotexture**. No evidence of any focal lesion. IHBR is NOT dilated. Portal vein is normal.

**GALL BLADDER** :The gall bladder is well distended. No evidence any calculus or mass seen. GB wall thickness with in normal limits. No evidence of pericholecystic fluid is seen. The common bile duct is normal.

**SPLEEN** :The spleen is normal in size and shape. Its echotexture is homogeneous. No evidence of focal lesion is noted. Splenic vein is normal.

**PANCREAS** :The pancreas is normal in size, shape, contours and echotexture.

**BILATERAL KIDNEYS** : The bilateral kidneys are normal in size and echotexture. Cortico-medullary differentiation is maintained. There is no evidence of obvious calculus or hydronephrosis seen.

**URINARY BLADDER** :The urinary bladder is well distended. Wall thickness within normal limits. No evidence of calculus is seen. No evidence of mass or diverticulum is noted.


**PROSTATE** : Prostate appears normal in size, shape and echotexture.

No free fluid is seen in peritoneal cavity.

No evidence of obvious retroperitoneal or mesenteric lymphadenopathy is seen.

**IMPRESSION:- USG WHOLE ABDOMEN REVEALS Grade II fatty liver.**

**TO BE CORRELATED CLINICALLY.**

  
DR BINOD KR CHAUDHARY  
MBBS,MD  
CONSULTANT RADIOLOGIST





# ECHO REPORT

Name of the patient: MR. VIKAS SHARMA Age: 36 Sex:  Male  Female

UHID No: 30291 Bill No: 24093571 Date: 8-3-24

Refer By Doctor: DR. RAKESH ALOLA

LVEF% 66%

**2D ECHO**

> Mitral Value Normal Pulmonary Value N Pulm  
 > Artery N  
 > Aortic aive N Tricuspid valve N

**2D RWMA**

> NO RWMA (Regional wall motion abnormality) at rest

**COLD DOPPLER**

> NO Significant Vavular stenosis / Regurgiation

**COMMENTS AND SUMMARY**

> All cardiac chambers of N size and shape NO dilatation or hypertrophy.

> NO RWMA (Regional wall motion abnormality) at rest

> NO Cloth / Vegetation/ pericardial effusion

> LV 66% Systolic function

> NO Significant Vavular stenosis / Regurgiation

**Final Impression**

> EF at Rest 66%

COMMENTS 2D ECHO & Color Doppler study wnl

**Consultant Cardiology**

Doctor Name : Dr.  
Date :

*Rakesh Kumar Arola*  
Dr. Rakesh Kumar Arola  
MBBS, MD (Cardiology)  
Signature : Cardiology  
Time : Park Hospital, Faridabad

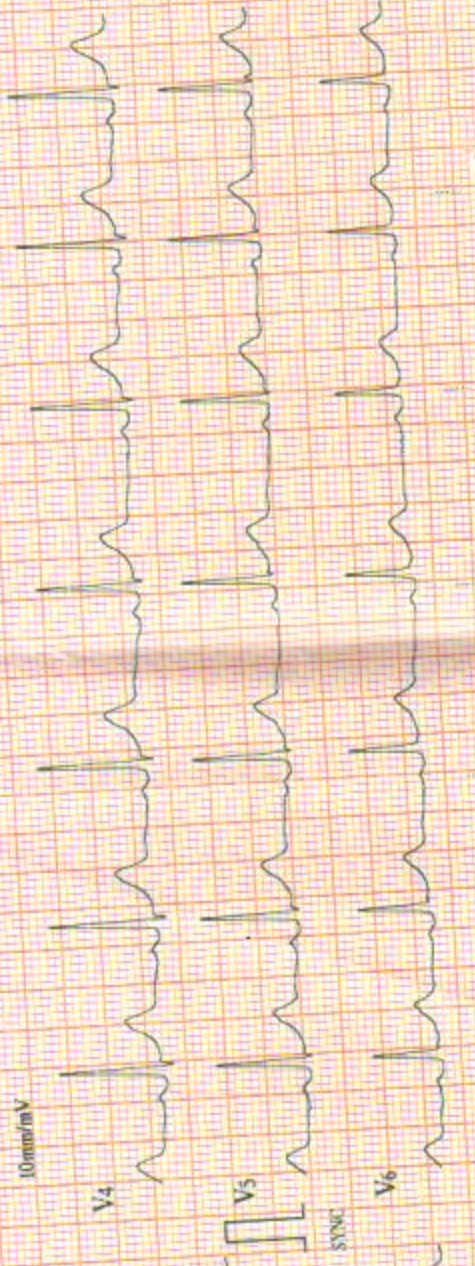






ID : 4271  
Name: Vikas Sharma  
Sex : Male  
Age :  
HR : 70  
PR : 185  
P : 120  
QT/QTc : 374/403  
P/QTc/T : 6.50/37  
RV5/SVI : 1.210/0.810 mV  
RV5+SVI : 2.020 mV

----- Sinus Arrhythmia



Unconfirmed report Verified by:

ECG CARDIOPRINT