


 An Aadhaar card for Neeru. It features a small portrait on the left, a QR code on the right, and the number 2229 7660 7661 at the bottom. The text is in Hindi and English.

नाम  
 Neeru  
 जन्म तिथि/ DOB: 18/06/1988  
 पुरुष / MALE

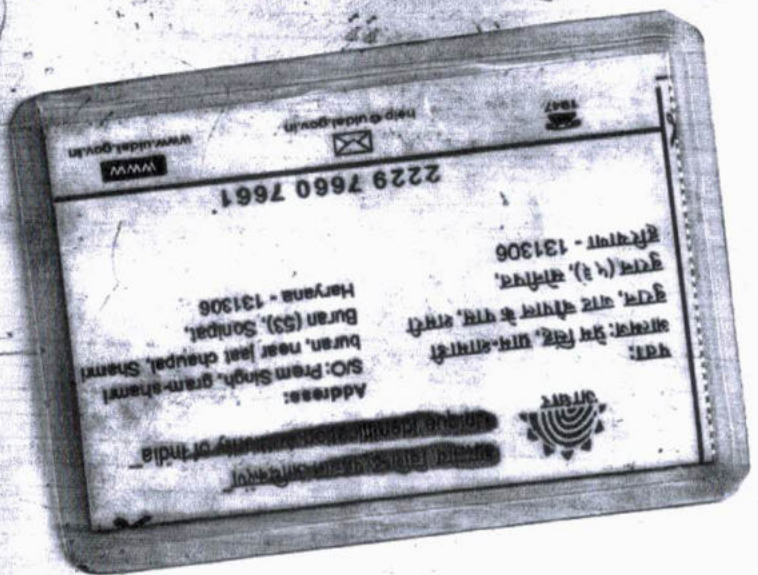
2229 7660 7661

मेरा आधार, मेरी पहचान

*For one plus Lab only*

ONEPLUS ULTRASOUND LAB  
 47, Harsh Vihar, Pitam Pura,  
 Delhi 110034  
 Ph: 011-42480101, 9599913051  
 E-mail: oneplusul@gmail.com

  
 Dr. NITIN AGARWAL  
 MBBS, MD  
 Regn. No. DMC-R-1436



 An Aadhaar card for Prem Singh. It is oriented upside down. It features a small portrait on the left, a QR code on the right, and the number 2229 7660 7661 at the bottom. The text is in Hindi and English.

Address:  
 S/O: Prem Singh, gram-shanti  
 buran, near jati chaura, Shamri  
 Haryana - 131306

2229 7660 7661

  
Dr. NITIN AGARWAL  
MBBS, MD  
Regn. No. DMC-R-1435

ONEPLUS ULTRASOUND LAB  
47, Harsh Vihar, Pitam Pura,  
Delhi-110034  
Ph. 011-42489101, 9599913051  
E-mail: [oneplusul@gmail.com](mailto:oneplusul@gmail.com)







# OnePLUS Ultrasound Lab

QUALITY FIRST... ALWAYS!

**Dr. Nitin Agarwal**  
Pathologist & Director  
Ex. Sr. Res. MAMC  
& Lok Nayak Hospital  
Ex. Chief of Lab Dr. Lal Path Labs.

**Dr. Pooja (Garg) Agarwal**  
Radiologist & Director  
MAMC & Lok Nayak Hospital



NAME	:Mr. NEERU	Barcode No	:10133897
AGE/GENDER	:32 YRS/Male	SPECIMEN DATE	:18/Dec/2022 08:06AM
PATIENT ID	:106429	SPECIMEN RECEIVED	:18/Dec/2022 08:23AM
REFERRED BY	:Dr. MEDIWHEEL	REPORT DATE	:18/Dec/2022 01:47PM
CENTRE NAME	:ONEPLUS ULTRASOUND LAB	LAB NO.	:012212180001

Test Name	Result	Unit	Ref. Range
-----------	--------	------	------------

## HAEMATOLOGY

### Health checkup 2 Male

<b>Glycosylated Hemoglobin (HbA1c)</b>	5.4	%	Non Diabetic adults <5.7 Prediabetic (at risk) 5.7-6.4 Diabetes >6.4
<b>Estimated average blood glucose (eag)</b>	108		

Reference range (mg/dl):

90 - 120:Excellent control, 121 - 150:Good Control, 151 - 180:Average Control, 181 - 210:Action Suggested

>211:Panic value

<b>BLOOD GROUP (ABO)</b>	B
<b>Rh typing</b>	POSITIVE

### NOTE :

- \* Apart from major A,B,H antigens which are used for ABO grouping and Rh typing, many minor blood group antigens exist. Agglutination may also vary according to titre of antigen and antibody.
- \* So before transfusion, reconfirmation of blood group as well as cross-matching is needed.
- \* Presence of maternal antibodies in newborns, may interfere with blood grouping.
- \* Auto agglutination (due to cold antibody, falciparum malaria, sepsis, internal malignancy etc.) may also cause erroneous result.

## CBC

Haemoglobin	14.4	g/dl	13.0-17.0
Total Leucocyte Count	8200	/cumm	4000-10000
<b>Differential leucocyte count</b>			
Neutrophils	54	%	40-80
Lymphocyte	<b>40.70</b>	%	20-40
Monocytes	3.30	%	2-10
Eosinophils	01	%	1-6
Basophils	01	%	0-2
RBC Count	5.10	million/cumm	4.5 - 5.5

Checked By.

**DR. NITIN AGARWAL**  
MBBS, MD  
Regn. No. DMC-R-1436  
MBBS, MD (PATHOLOGIST)

47, Harsh Vihar, Pitampura, New Delhi-110034 | Ph.: 011-42480101, 9599913051

E-mail: [oneplusul@gmail.com](mailto:oneplusul@gmail.com) | Web.: [www.oneplusul.in](http://www.oneplusul.in)

Page 1 of 6



# OnePLUS Ultrasound Lab

QUALITY FIRST... ALWAYS!

**Dr. Nitin Agarwal**

Pathologist & Director  
Ex. Sr. Res. MAMC  
& Lok Nayak Hospital  
Ex. Chief of Lab Dr. Lal Path Labs.

**Dr. Pooja (Garg) Agarwal**

Radiologist & Director  
MAMC & Lok Nayak Hospital



NAME	:Mr. NEERU	Barcode No	:10133897
AGE/GENDER	:32 YRS/Male	SPECIMEN DATE	:18/Dec/2022 08:06AM
PATIENT ID	:106429	SPECIMEN RECEIVED	:18/Dec/2022 08:23AM
REFERRED BY	:Dr. MEDIWHEEL	REPORT DATE	:18/Dec/2022 01:47PM
CENTRE NAME	:ONEPLUS ULTRASOUND LAB	LAB NO.	:012212180001

Test Name	Result	Unit	Ref. Range
PCV(Hematocrit)	45	%	40-50
MCV	88.3	fL	83-101
MCH	28.3	Pg	27-32
MCHC	32	G/dL	32-35
Platelet count	275000	/cumm	150000-450000
RDW-CV	13.4	%	11.4-14.0
ESR(WESTEGRENs METHOD)	12	mm in 1st hr	0-20

### BIOCHEMISTRY

<u>Blood sugar fasting</u>	81	mg/dL	70-110
<u>Blood sugar pp</u>	106	mg/dL	70.0-140.0
<u>Bun (blood urea nitrogen )</u>	11.20	mg/dl	8.9-21.6
<u>Uric acid, serum</u>	4.2	mg/dl	3.5-7.2
<u>Creatinine, serum</u>	0.62	mg/dl	0.60-1.2


### LFT(LIVER FUNCTION TEST)

Bilirubin Total	0.54	mg/dl	0.1-1.2
Bilirubin Conjugated	0.22	mg/dl	0-0.4
Bilirubin Unconjugated	0.32	mg/dl	up to 0.7
SGOT (AST)	20	U/L	0-46
SGPT (ALT)	26	U/L	0-49
Alkaline phosphatase	98	U/L	40-129
Gamma glutamyl transpeptidase	28	U/L	10-45
Total Protein	7.6	gm/dl	6.60 - 8.70
Albumin serum	4.2	g/dL	3.0-5.2
Globulin	3.40	gm/dl	1.8-3.4
Albumin/Globulin Ratio	1.24		1.10 - 2.50

### LIPID PROFILE

Cholesterol	229	mg/dl	50-200
Triglycerides	158	mg/dL	25-150

Checked By.

  
DR. NITIN AGARWAL  
MBBS,MD(PATHOLOGIST)  
MBBS, MD  
Regn. No. DMC-R-1436

47, Harsh Vihar, Pitampura, New Delhi-110034 | Ph.: 011-42480101, 9599913051

E-mail: [oneplusul@gmail.com](mailto:oneplusul@gmail.com) | Web.: [www.oneplusul.in](http://www.oneplusul.in)

Page 2 of 6

Clinical correlation is essential for final diagnosis. • If test results are unsatisfactory please contact personally or on phone. • This report is for perusal of doctors only.  
• All disputes Subject to Delhi Jurisdiction only. • Not for medicolegal purposes. • All congenital anomalies in a foetus may not be diagnosed in routine obstetric ultrasound.



# OnePLUS Ultrasound Lab

— QUALITY FIRST... ALWAYS! —

**Dr. Nitin Agarwal**  
Pathologist & Director  
Ex. Sr. Res. MAMC  
& Lok Nayak Hospital  
Ex. Chief of Lab Dr. Lal Path Labs.

**Dr. Pooja (Garg) Agarwal**  
Radiologist & Director  
MAMC & Lok Nayak Hospital



NAME	:Mr. NEERU	Barcode No	:10133897
AGE/GENDER	:32 YRS/Male	SPECIMEN DATE	:18/Dec/2022 08:06AM
PATIENT ID	:106429	SPECIMEN RECEIVED	:18/Dec/2022 08:23AM
REFERRED BY	:Dr. MEDIWHEEL	REPORT DATE	:18/Dec/2022 01:47PM
CENTRE NAME	:ONEPLUS ULTRASOUND LAB	LAB NO.	:012212180001

Test Name	Result	Unit	Ref. Range
HDL Cholesterol	55	mg/dL	40 - 60
LDL cholesterol	<b>142</b>	mg/dL	<130
VLDL cholesterol	31.6	mg/dL	5-40
Cholesterol/HDL Ratio	4.2		Low Risk 3.3-4.97 Average Risk 4.4-7.1 Moderate Risk 7.1-11.0 High Risk >11.0
LDL/HDL Ratio	2.6		0 - 3.55

According to ATP III and NCEP guidelines

Parameter	Normal	Desirable	Borderline	High
Total cholesterol	<200		200-239	240
Triglycerides	<150	150-199	200-499	500
LDL	Optimal <100 Near Optimal 100-129	130-159	160-180	190
HDL	<40 : LOW 60 : HIGH			

## ENDOCRINOLOGY

### PSA TOTAL

Prostatic specific antigen, Total 1.00 ng/ml <4.0

< 40 years	0.21 to 1.72 ng/ml
40 - 49	0.27 to 2.19 ng/ml
50 - 59	0.27 to 3.42 ng/ml
60 - 69	0.22 to 6.16 ng/ml
> 69	0.21 to 6.77 ng/ml

### Notes:

Checked By.

Dr. NITIN AGARWAL  
MBBS, MD  
MBBS, MD (PATHOLOGIST) Regn. No. DMC-R-1436

47, Harsh Vihar, Pitampura, New Delhi-110034 | Ph.: 011-42480101, 9599913051

E-mail: [oneplusul@gmail.com](mailto:oneplusul@gmail.com) | Web.: [www.oneplusul.in](http://www.oneplusul.in)

Page 3 of 6

Clinical correlation is essential for final diagnosis. • If test results are unsatisfactory please contact personally or on phone. • This report is for perusal of doctors only. • All disputes Subject to Delhi Jurisdiction only. • Not for medicolegal purposes. • All congenital anomalies in a foetus may not be diagnosed in routine obstetric ultrasound.



# OnePLUS Ultrasound Lab

QUALITY FIRST... ALWAYS!

**Dr. Nitin Agarwal**  
Pathologist & Director  
Ex. Sr. Res. MAMC  
& Lok Nayak Hospital  
Ex. Chief of Lab Dr. Lal Path Labs.

**Dr. Pooja (Garg) Agarwal**  
Radiologist & Director  
MAMC & Lok Nayak Hospital



NAME	:Mr. NEERU	Barcode No	:10133897
AGE/GENDER	:32 YRS/Male	SPECIMEN DATE	:18/Dec/2022 08:06AM
PATIENT ID	:106429	SPECIMEN RECEIVED	:18/Dec/2022 08:23AM
REFERRED BY	:Dr. MEDIWHEEL	REPORT DATE	:18/Dec/2022 01:47PM
CENTRE NAME	:ONEPLUS ULTRASOUND LAB	LAB NO.	:012212180001

Test Name	Result	Unit	Ref. Range
PSA is principally produced by the glandular epithelium of the prostate, and is secreted in the seminal fluid. PSA is also present in urine and blood. PSA acts on seminal fluid to fluidify and increase sperm mobility. PSA levels rise in prostatic pathologies such as benign prostatic hyperplasia (BPH) or prostate cancer.			

### THYROID PROFILE(T3,T4,TSH)

Triiodothyronine total [t3]	0.68	ng/dl	0.52-1.9
Thyroxine total [t4]	9.50	µg/dl	4.4 - 10.8
TSH (Thyroid Stimulating Hormone)	2.50	µIU/ml	0.25-5.0

### AGE WISE VARIATION IN TSH

AGE	TSH(µIU/ml)	AGE	TSH(µIU/ml)
1-4 weeks	1.00 - 19.0	16-20 yrs	0.25 - 5.0
1-12 mths	1.70 - 9.1	21 - 80 yrs	0.25 - 5.0
1-5 yrs	0.80 - 8.2	I <sup>st</sup> trimester	0.25 - 5.0
6-10 yrs	0.25 - 5.0	II <sup>nd</sup> trimester	0.50 - 5.0
11-15 yrs	0.25 - 5.0	II <sup>rd</sup> trimester	0.4 - 6.0

### Reference ranges - Interpretation of Diagnostic tests - (Jacques Wallach)

1. Primary hypothyroidism is accompanied by depressed serum T3 and T4 values and elevated serum TSH level.
2. Primary hyperthyroidism is accompanied by elevated serum T3 and T4 levels along with depressed TSH values.
3. Slightly elevated T3 levels may be found in pregnancy and estrogen therapy, while depressed levels may be encountered in severe illness, renal failure and during therapy with drugs like propranolol and propyl thiouracil.
4. Although elevated TSH levels are nearly always indicative of primary hypothyroidism, and may be seen in secondary thyrotoxicosis

### CLINICAL PATHOLOGY

#### URINE ROUTINE

#### Physical examination

Quantity	20	ML
Colour	PALE YELLOW	
Transparency	SLIGHTLY TURBID	CLEAR
Sp.gravity	1.015	1.010-1.030
pH	6.00	

Checked By.

DR. NITIN AGARWAL  
MBBS,MD(PATHOLOGIST)  
Regn. No. DMC-R-1436

47, Harsh Vihar, Pitampura, New Delhi-110034 | Ph.: 011-42480101, 9599913051  
E-mail: oneplusul@gmail.com | Web.: www.oneplusul.in

Page 4 of 6



# OnePLUS Ultrasound Lab

— QUALITY FIRST... ALWAYS! —

**Dr. Nitin Agarwal**  
Pathologist & Director  
Ex. Sr. Res. MAMC  
& Lok Nayak Hospital  
Ex. Chief of Lab Dr. Lal Path Labs.

**Dr. Pooja (Garg) Agarwal**  
Radiologist & Director  
MAMC & Lok Nayak Hospital



NAME	:Mr. NEERU	Barcode No	:10133897
AGE/GENDER	:32 YRS/Male	SPECIMEN DATE	:18/Dec/2022 08:06AM
PATIENT ID	:106429	SPECIMEN RECEIVED	:18/Dec/2022 08:23AM
REFERRED BY	:Dr. MEDIWHEEL	REPORT DATE	:18/Dec/2022 01:47PM
CENTRE NAME	:ONEPLUS ULTRASOUND LAB	LAB NO.	:012212180001

Test Name	Result	Unit	Ref. Range
Reaction	ACIDIC		ACIDIC
<b><u>Chemical examination</u></b>			
Urine protein	NIL		NIL
Urine sugar	NIL		NIL
Bilirubin, urine	NEGATIVE		NEGATIVE
Urobilinogen	NORMAL		NORMAL
Ketones	NEGATIVE		NEGATIVE
<b><u>Microscopic examination</u></b>			
<b>Pus cells.</b>			
Epithelial cells	2-3	/HPF	0-2
R.B.C.	1-2	/HPF	NIL
Casts	NIL	/HPF	NIL
Crystals	NIL	/HPF	NIL
Bacteria	NIL	/HPF	NIL
Others.	NIL	NIL	NIL
<b>STOOL ROUTINE</b>			
<b><u>Physical examination</u></b>			
Colour	BROWNISH		
Consistency	SEMI LOOSE		Semi Formed
Blood	ABSENT		Absent
Mucus	ABSENT		Absent
<b><u>Chemical examination, stool</u></b>			
pH	6.00		
<b><u>Microscopic examination</u></b>			
Pus cells	0-1	/HPF	
R.B.C.	NIL	/HPF	NIL
Ova	NIL		NIL
Cysts	NIL		NIL
Bacteria	PRESENT	/HPF	NIL

Checked By.

**Dr. NITIN AGARWAL**  
MBBS, MD  
Regn. No. DMC-R-1436  
MBBS, MD(PATHOLOGIST)

47, Harsh Vihar, Pitampura, New Delhi-110034 | Ph.: 011-42480101, 9599913051

E-mail: [oneplusul@gmail.com](mailto:oneplusul@gmail.com) | Web.: [www.oneplusul.in](http://www.oneplusul.in)

Page 5 of 6

Clinical correlation is essential for final diagnosis. • If test results are unsatisfactory please contact personally or on phone. • This report is for perusal of doctors only. • All disputes Subject to Delhi Jurisdiction only. • Not for medicolegal purposes. • All congenital anomalies in a foetus may not be diagnosed in routine obstetric ultrasound.





# OnePLUS Ultrasound Lab

— QUALITY FIRST... ALWAYS! —

**Dr. Nitin Agarwal**  
Pathologist & Director  
Ex. Sr. Res. MAMC  
& Lok Nayak Hospital  
Ex. Chief of Lab Dr. Lal Path Labs.

**Dr. Pooja (Garg) Agarwal**  
Radiologist & Director  
MAMC & Lok Nayak Hospital




NAME	:Mr. NEERU	Barcode No	:10133897
AGE/GENDER	:32 YRS/Male	SPECIMEN DATE	:18/Dec/2022 08:06AM
PATIENT ID	:106429	SPECIMEN RECEIVED	:18/Dec/2022 08:23AM
REFERRED BY	:Dr. MEDIWHEEL	REPORT DATE	:18/Dec/2022 01:47PM
CENTRE NAME	:ONEPLUS ULTRASOUND LAB	LAB NO.	:012212180001

Test Name	Result	Unit	Ref. Range
Others	NIL		

\*\*\* End Of Report \*\*\*

Checked By.

Dr. NITIN AGARWAL  
MBBS, MD

Regd. No. DMC-R-1436  
  
DR. NITIN AGARWAL  
MBBS, MD(PATHOLOGIST)

47, Harsh Vihar, Pitampura, New Delhi-110034 | Ph.: 011-42480101, 9599913051  
E-mail: oneplusul@gmail.com | Web.: www.oneplusul.in

Page 6 of 6

Clinical correlation is essential for final diagnosis. • If test results are unsatisfactory please contact personally or on phone. • This report is for perusal of doctors only.  
• All disputes Subject to Delhi Jurisdiction only. • Not for medicolegal purposes. • All congenital anomalies in a foetus may not be diagnosed in routine obstetric ultrasound.



**OnePLUS**  
Ultrasound Lab

— QUALITY FIRST... ALWAYS! —

**Dr. Nitin Agarwal**

Pathologist & Director  
Ex. Sr. Res. MAMC  
& Lok Nayak Hospital  
Ex. Chief of Lab Dr. Lal Path Labs.

**Dr. Pooja (Garg) Agarwal**

Radiologist & Director  
MAMC & Lok Nayak Hospital

<b>Name</b>	: Mr. NEERU	<b>Age/Sex</b>	: 32 YRS/Male
<b>Ref. By</b>	: Dr. MEDIWHEEL	<b>Lab No</b>	: 012212180001
<b>Date</b>	: 18-Dec-2022	<b>Patient ID</b>	: LSHHI106429

### ULTRASOUND EXAMINATION----WHOLE ABDOMEN

**Liver** is enlarged in size (17.5 cm) and normal in outline with altered echopattern. Diffuse increase in echogenicity of liver parenchyma is noted, suggestive of fatty infiltration (grade II). Intrahepatic biliary radicles are not dilated. No abscess or mass lesion seen. Hepatic veins, portal vein, IVC and aorta are normal. CBD is normal in caliber.

**Gall bladder** is well distended with anechoic lumen. Wall thickness is normal.

**Both kidneys** are normal in size, shape, position, outline and echopattern. Corticomedullary differentiation is maintained. No pelvicalyceal dilation or mass lesion is seen.

**Spleen** is normal in size (11.0 cm) and echotexture. No mass lesion seen.

**Pancreas** is normal in size, outline and echotexture.

**Urinary bladder** is normal in shape and position. No evidence of intravesical stone or mass seen.

**Prostate** is normal in size, shape and echopattern.

**Prostate measures** 3.6 x 4.1 x 2.8 cm. **Weight of prostate is 21.6 grams.**

No abnormal bowel wall thickening seen in right iliac fossa.  
No free fluid seen anywhere in abdomen.

#### IMPRESSION:

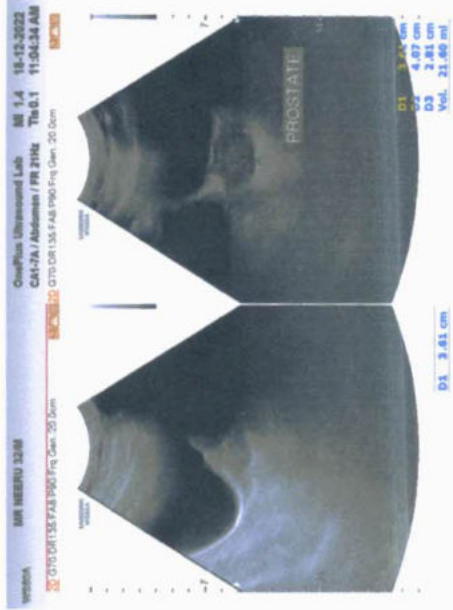
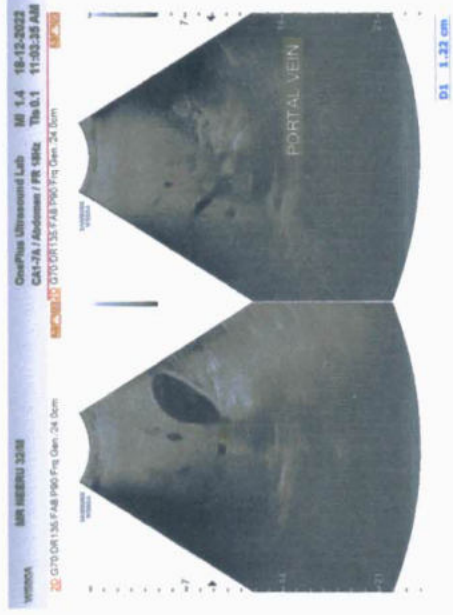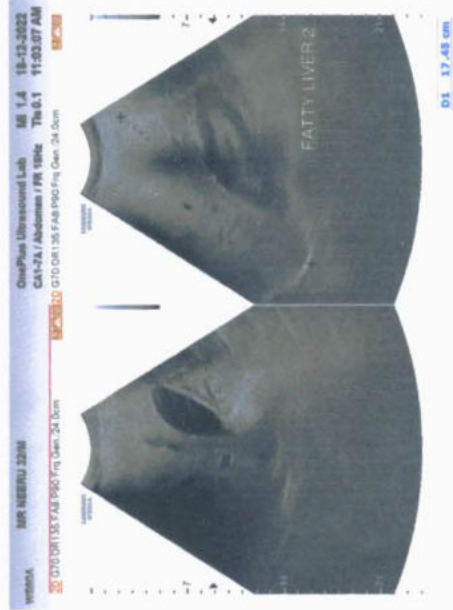
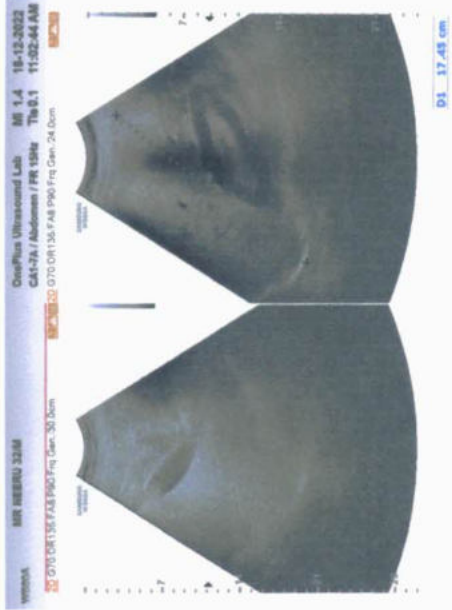
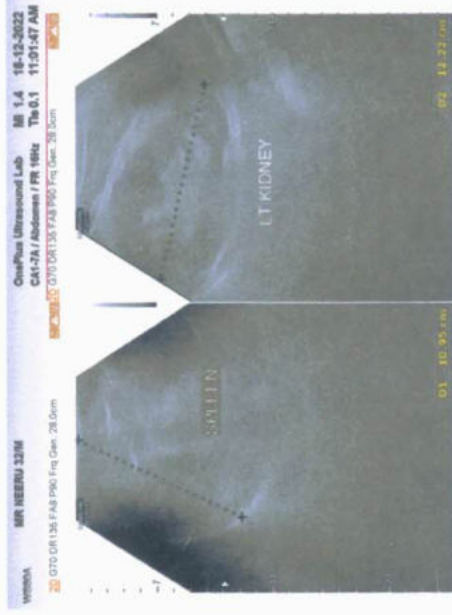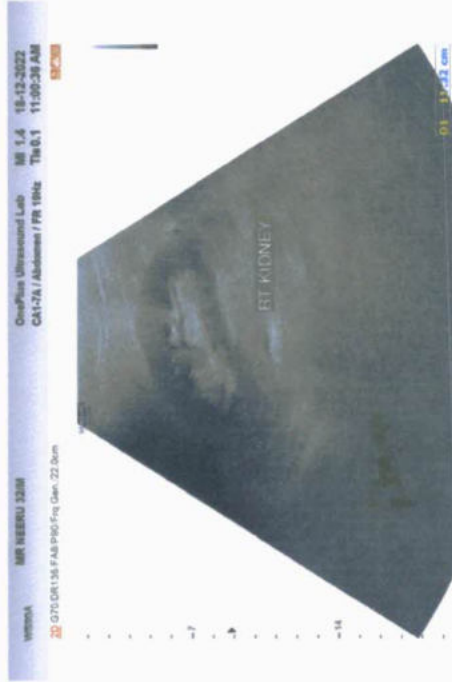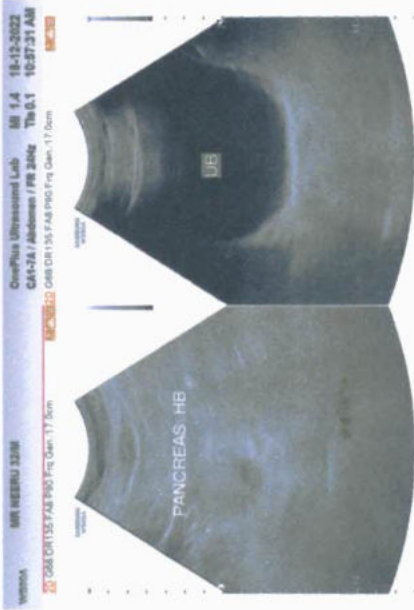
- Fatty infiltration of liver (grade II) with hepatomegaly.

**DR. APEKSHA ASHOK SHENOY**  
**RADIOLOGIST**

**RegNo:DMC/R/80169**

DR. APEKSHA ASHOK SHENOY  
MBBS, MD  
Reg. No. DMC/R/80169  
Radiologist

47, Harsh Vihar, Pitampura, New Delhi-110034 | Ph.: 011-42480101, 9599913051  
E-mail: oneplusul@gmail.com | Web.: www.oneplusul.in





# ONEPLUS ULTRASOUND LAB

47, HARSH VIHAR, PITAMPURA, DELHI- 110034

Mr. NEERU  
 Age : 32/M  
 Ref. by : MEDIWHEEL  
 Indication1 :  
 Indication2 :  
 Indication3 :  
 COMMENTS : Normal ECG.

ID : 2052  
 Ht/Wt : 168/80  
 Recorded : 18-12-2022 8:42  
 Medication1 :  
 Medication2 :  
 Medication3 :

BPM : 86  
 BP : 124/74  
 P Axis : 38 deg  
 QRS Axis : 48 deg  
 T Axis : 56 deg

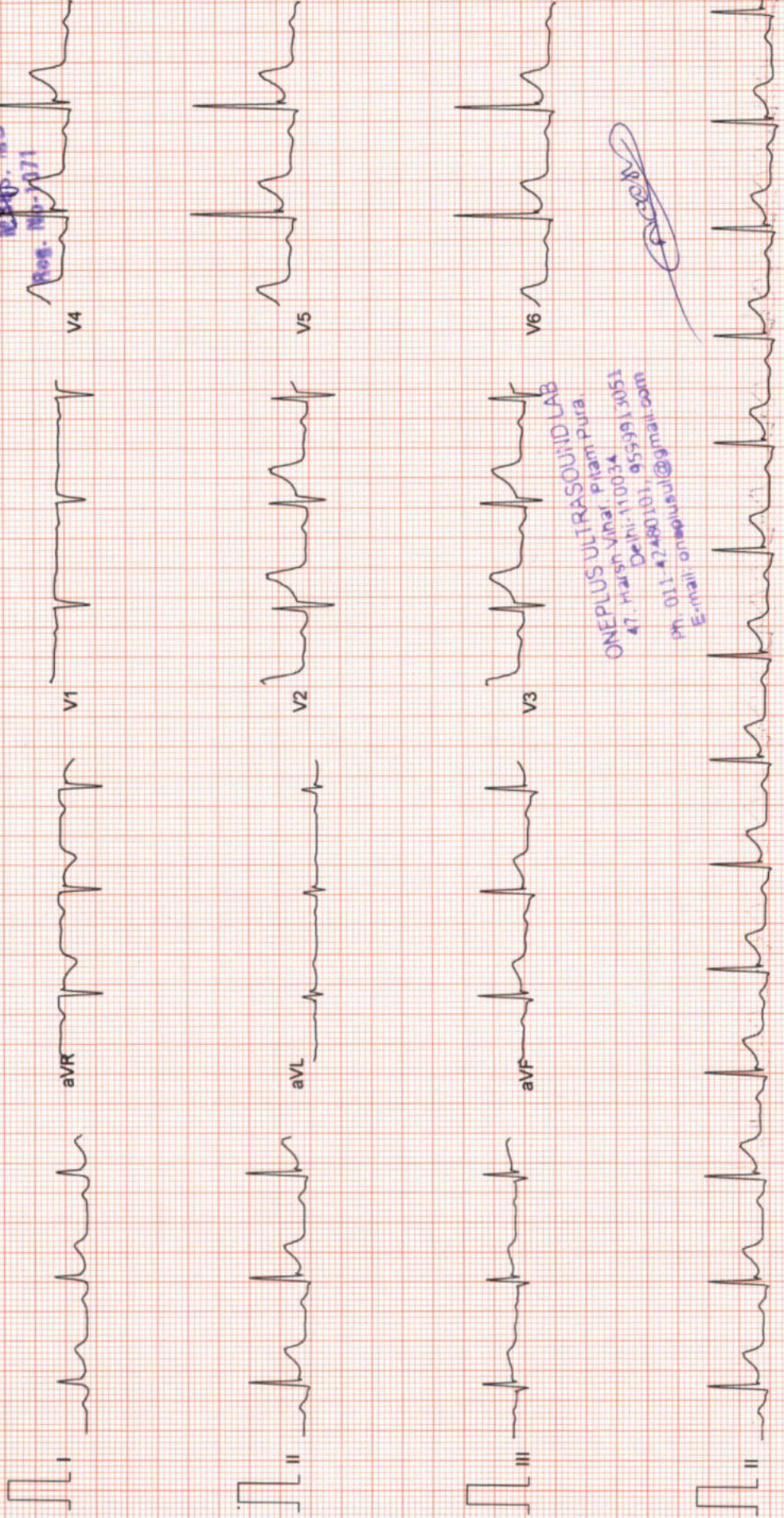
P duration : 93 msec  
 PR duration : 173 msec  
 QRS duration : 100 msec  
 QT interval : 303 msec  
 QTc interval : 348 msec

Raw E.C.G.(Seq)

Unconfirmed Report Reviewed By:

Cardiologist

*Dr. P. S. Gupta*  
 Dr. P. S. Gupta  
 Reg. No. 3071



ONEPLUS ULTRASOUND LAB  
 47, Harsh Vihar, Pitampura  
 Delhi-110034  
 Ph. 011-42480101, 9559912051  
 E-mail: onepplusul@gnmail.com



# ONEPLUS ULTRASOUND LAB

47, HARSH VIHAR PITAMPURA DELHI 110034

Mr. NEERU  
Age/Sex : 32/M  
Ref. by : MEDIWHEEL  
Indication1 :  
Indication2 :  
Indication3 :

ID : 998  
Ht/Wt : 168/80  
Recorded : 18-12-2022 8:47

TREADMILL TEST SUMMARY REPORT  
Protocol: BRUCE  
History:  
Medication1 :  
Medication2 :  
Medication3 :

PHASE	PHASE TIME	STAGE TIME	SPEED (Km./Hr.)	GRADE (%)	H.R. (BPM)	B.P. (mmHg)	RPP X100	II	ST LEVEL (mm) V2	V5	METS
STANDING SUPINE					83	124/74	102	1.5	2.8	2.2	
					83	124/74	102	1.5	2.8	2.2	
STAGE 1	2:59	2:59	2.70	10.00	97	136/78	131	1.4	2.8	2.3	4.80
STAGE 2	5:59	2:59	4.00	12.00	107	146/80	156	1.3	2.4	2.0	7.10
STAGE 3	8:59	2:59	5.40	14.00	129	158/84	203	0.8	1.9	1.4	10.00
STAGE 4	9:44	0:44	6.70	16.00	157	158/84	248	0.4	1.2	0.9	10.98
PEAK EXER	9:57	0:57			166	170/86	282	0.6	1.3	1.0	11.27
RECOVERY	2:59	2:59	0.00	0.00	98	130/76	127	1.0	1.3	0.9	

### RESULTS

Exercise Duration : 9:57 Minutes  
Max Heart Rate : 166 bpm 88 % of target heart rate 188 bpm  
Max Blood Pressure : 170/86 mmHg  
Max Work Load : 11.27 METS  
Reason of Termination :

*Negative for ischemia*

### IMPRESSIONS

Dr. P.K. GUPTA  
MBBS MD  
Reg. No. 10031

Cardiologist



ONEPLUS ULTRASOUND LAB  
47, Harsh Vihar Pitam Pura,  
Delhi-110034  
Ph. 011-42480101, 9599913051  
E-mail: oneplusul@gmail.com

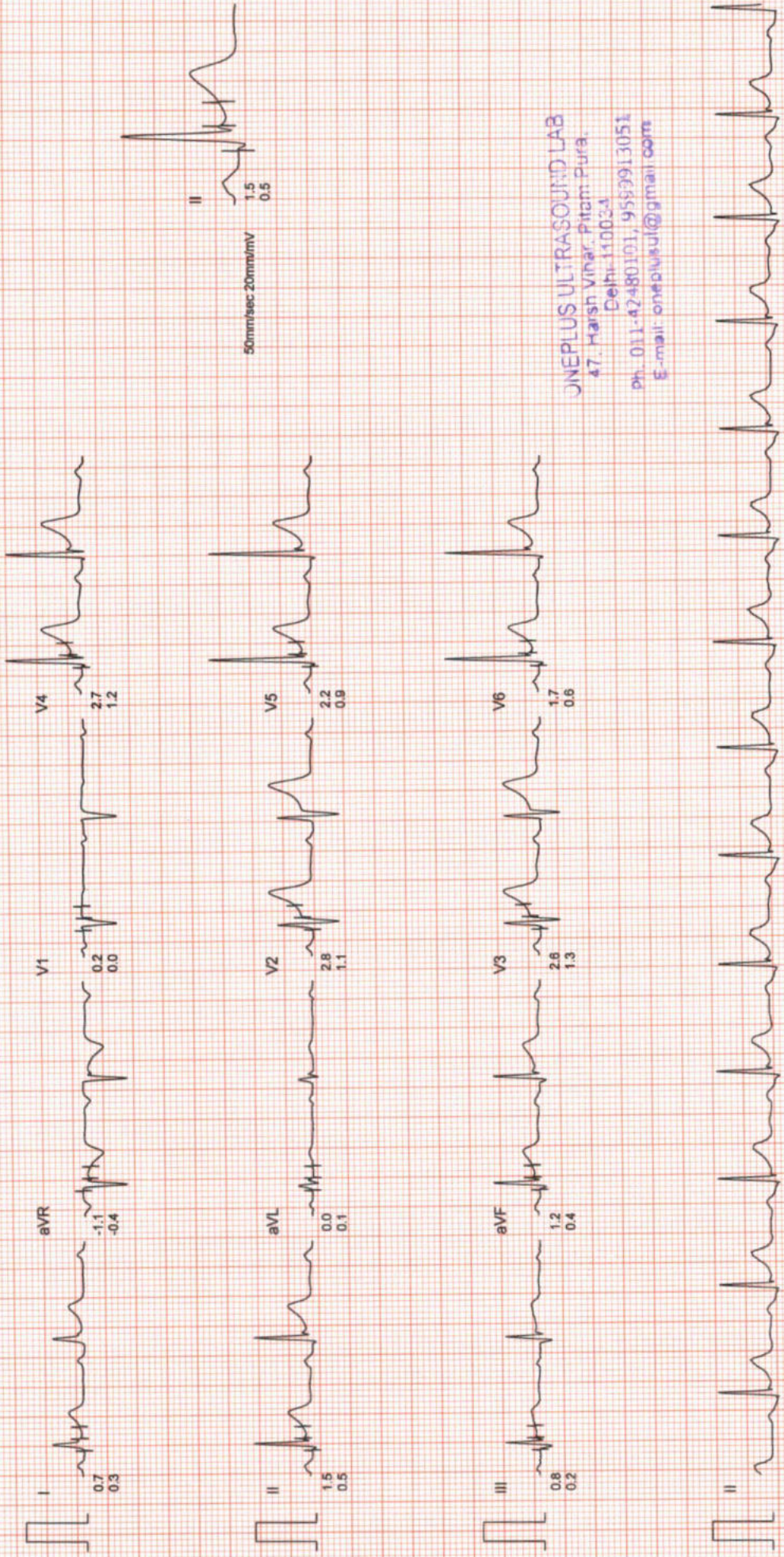
# ONEPLUS ULTRASOUND LAB

ST @ 10mm/mV  
80ms PostJ

STANDING  
PRETEST

Mr. NEERU  
I.D. : 998  
AGE/SEX : 32/M  
RECORDED : 18-12-2022 8:47  
RATE : 83 BPM  
B.P. : 124/74 mmHg

LINKED MEDIAN



ONEPLUS ULTRASOUND LAB  
47, Harish Vihar, Pitam Pura,  
Delhi-110034  
Ph. 011-42480101, 9559913051  
E-mail: oneplusul@gmail.com



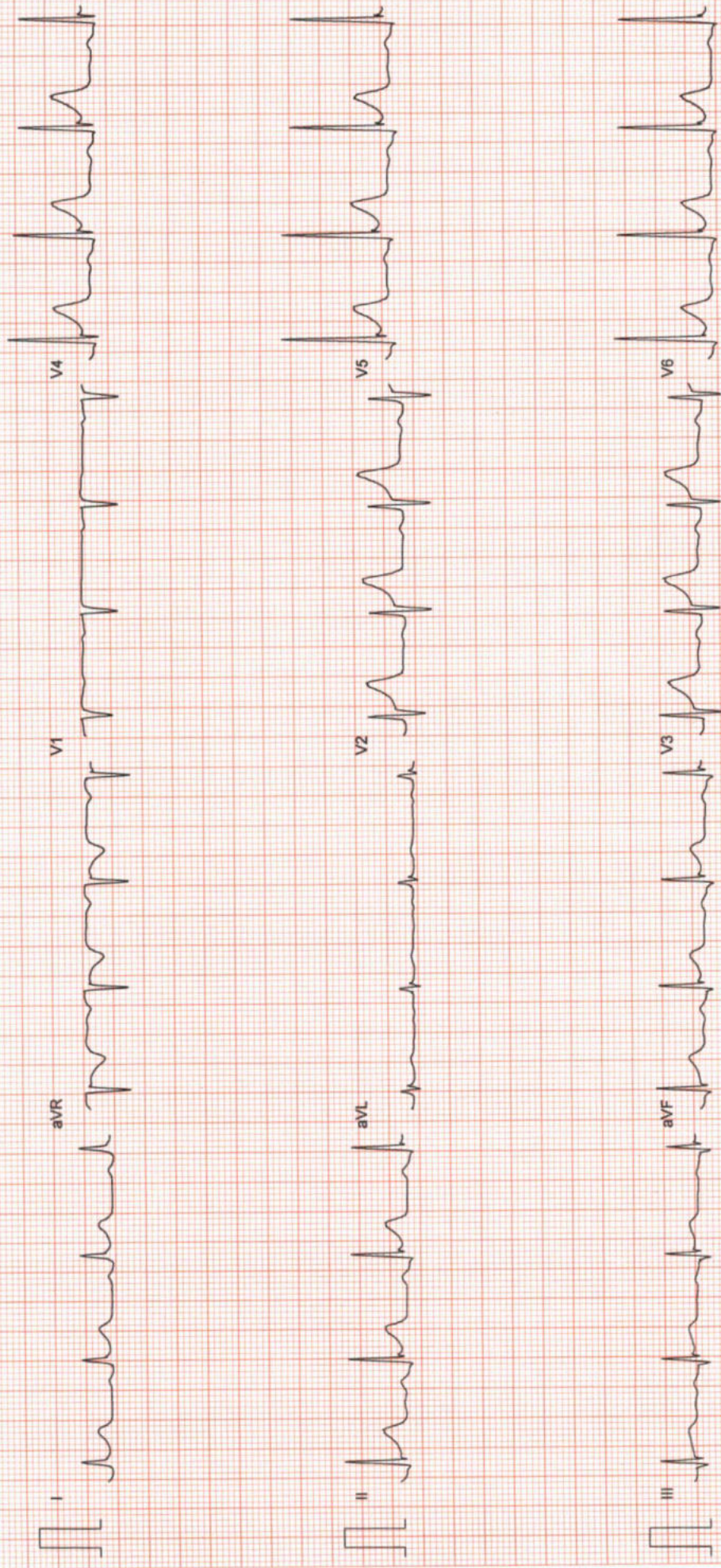
# ONEPLUS ULTRASOUND LAB

ST @ 10mm/mV  
80ms PostJ

SUPINE  
PRETEST

Mr. NEERU  
I.D. : 998  
AGE/SEX : 32/M  
RECORDED : 18-12-2022 8:47  
RATE : 83 BPM  
B.P. : 124/74 mmHg

RAW E.C.G.



ONEPLUS ULTRASOUND LAB  
47, Harish Vihar, Pitam Pura,  
Delhi-110034  
Ph. 011-42480101, 9599913051  
E-mail: oneplusul@gmail.com

# ONEPLUS ULTRASOUND LAB

Mr. NEERU  
I.D. : 998  
AGE/SEX : 32/M

RECORDED : 18-12-2022 8:47

RATE : 97 BPM

B.P. : 136/78 mmHg

BRUCE

EXERCISE 1

PHASE TIME : 2:59

STAGE TIME : 2:59

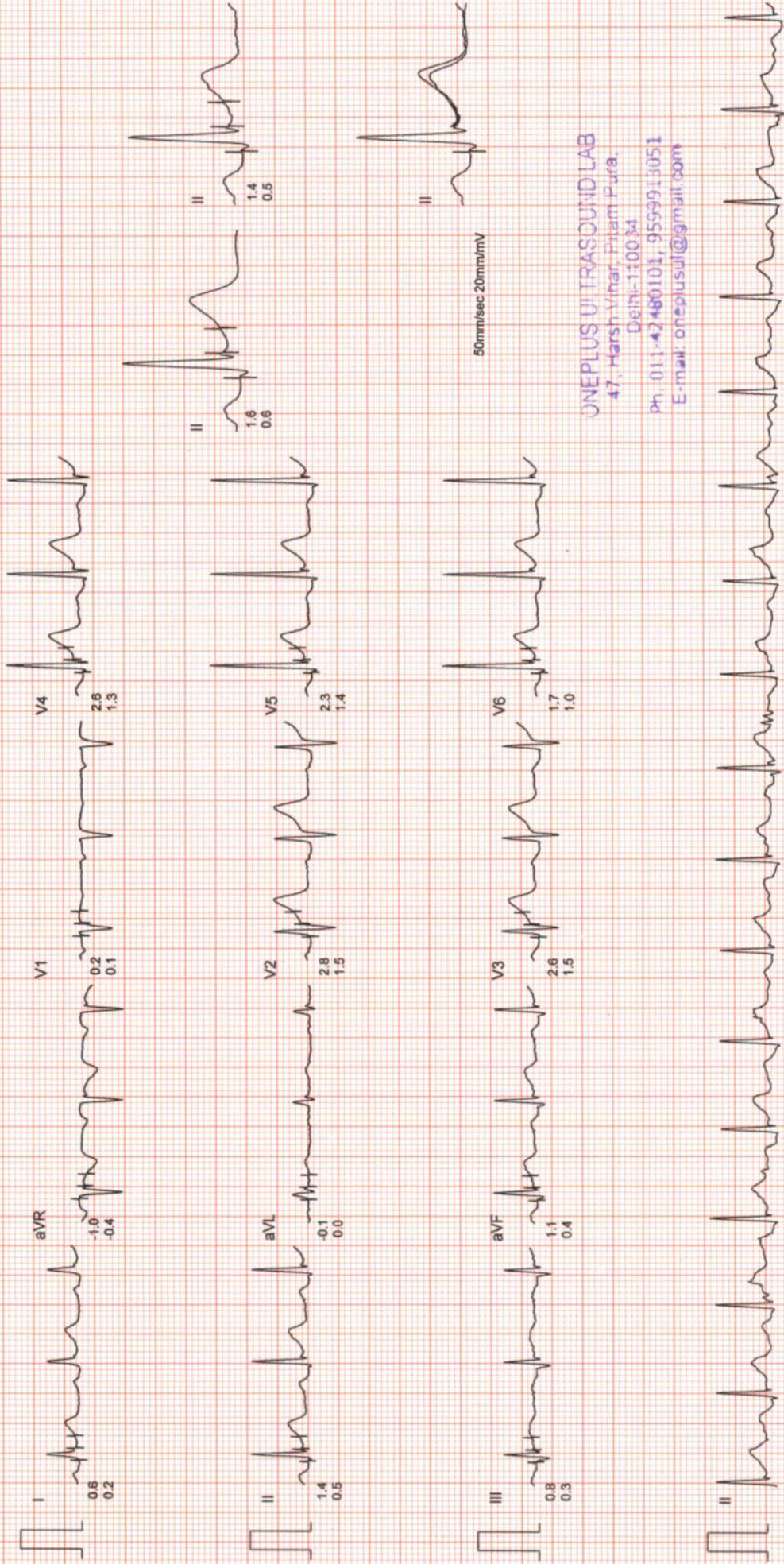
ST @ 10mm/mV

80ms PostJ

SPEED : 2.7 Km./Hr.

GRADE : 10.0 %

LINKED MEDIAN



ONEPLUS ULTRASOUND LAB

47, Harsh Vihar, Pitam Pura,  
Delhi-110034

Ph. 011-42480101, 9599913051

E-mail: oneplusul@gmail.com



# ONEPLUS ULTRASOUND LAB

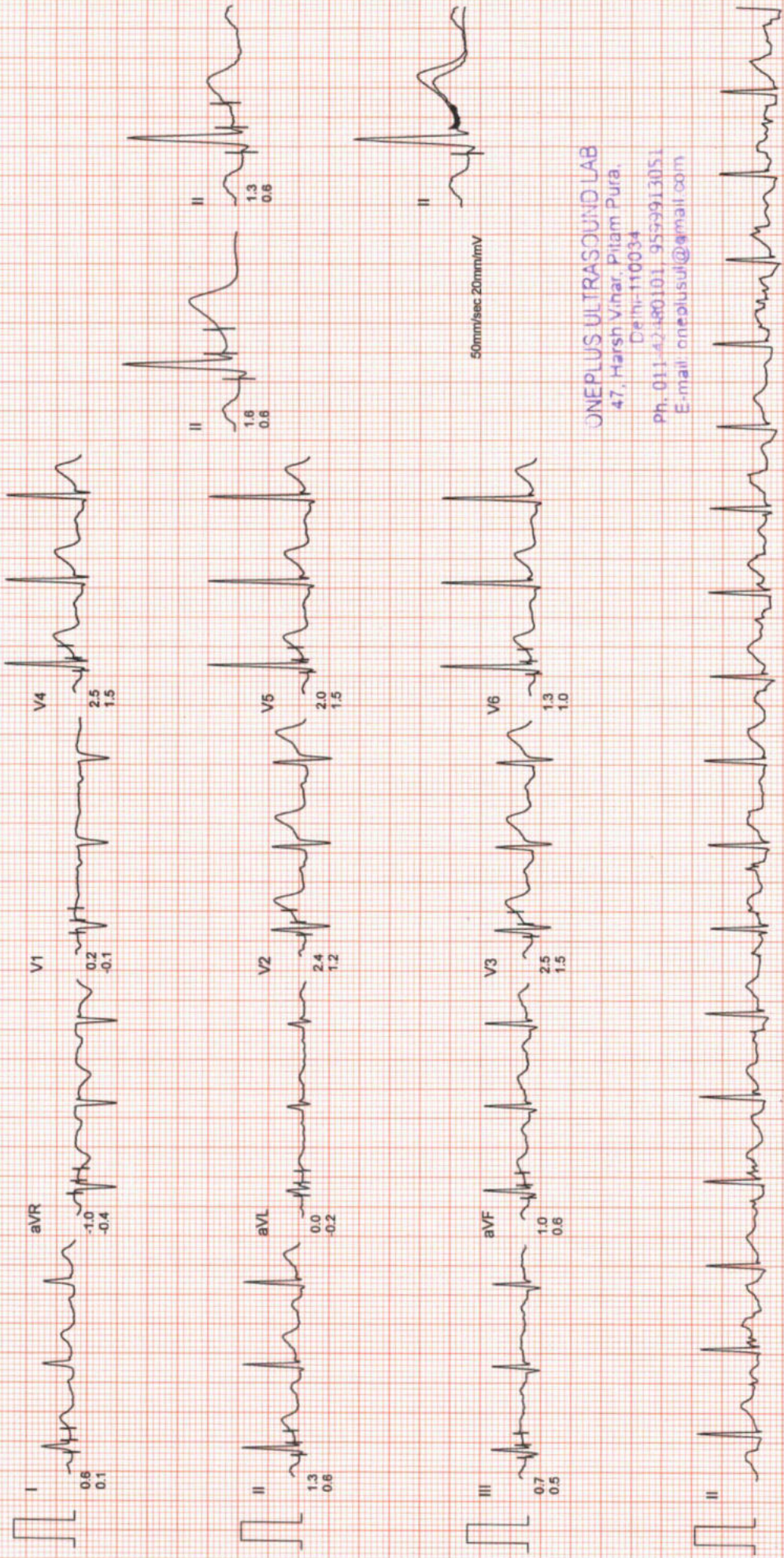
Mr. NEERU  
I.D. : 998  
AGE/SEX : 32/M

RECORDED : 18-12-2022 8:47  
RATE : 107 BPM  
B.P. : 146/80 mmHg

BRUCE  
EXERCISE 2  
PHASE TIME : 5:59  
STAGE TIME : 2:59

ST @ 10mm/mV  
80ms PostJ  
SPEED : 4.0 Km./Hr.  
GRADE : 12.0 %

LINKED MEDIAN



ONEPLUS ULTRASOUND LAB  
47, Harsh Vihar, Pitam Pura,  
Delhi-110034  
Ph. 011-42480101, 9559913051  
E-mail: oneplusul@gmail.com



# ONEPLUS ULTRASOUND LAB

Mr. NEERU  
I.D. : 998

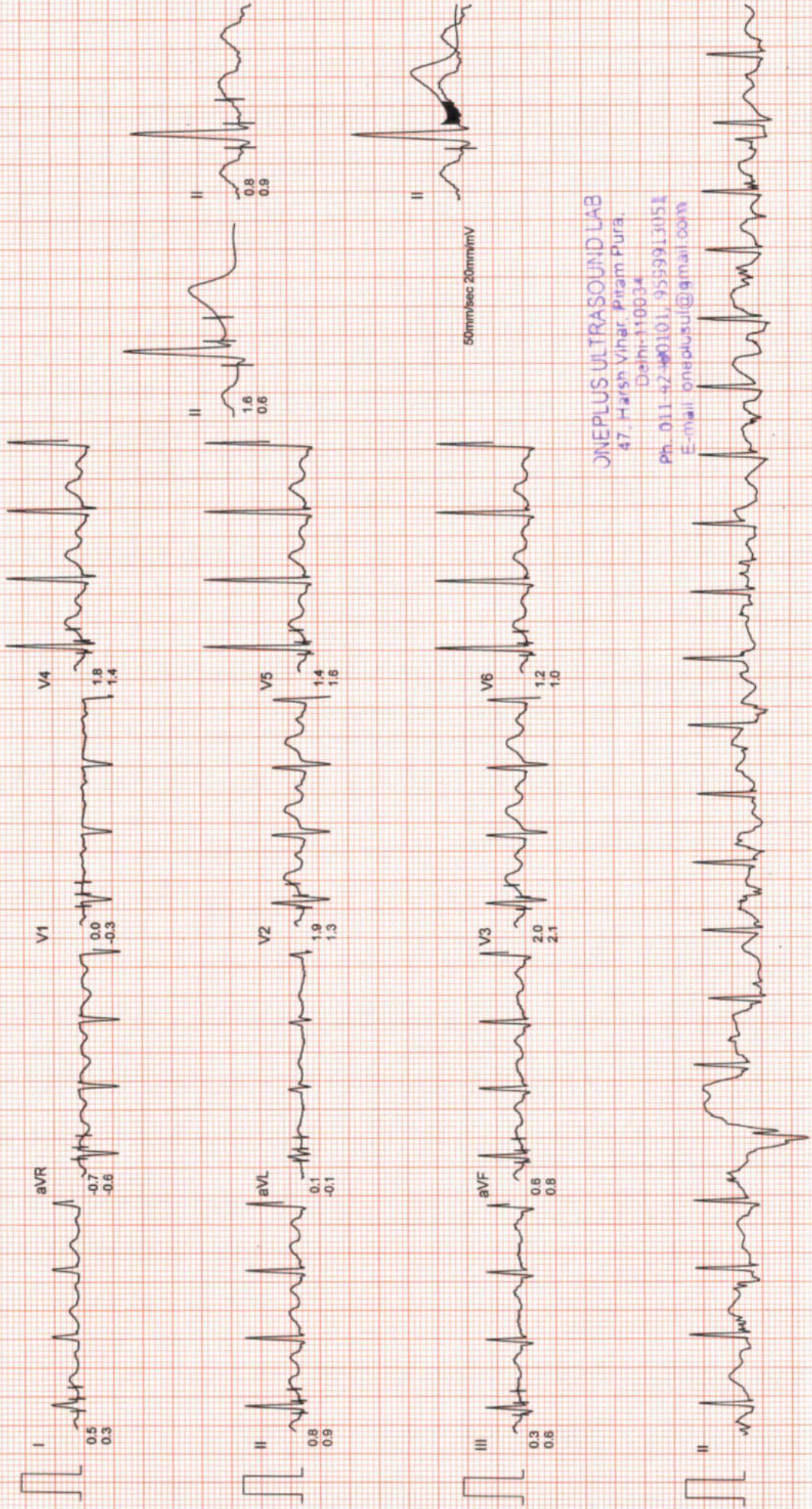
AGE/SEX : 32/M  
RECORDED : 18-12-2022 8:47

RATE : 129 BPM  
B.P. : 158/84 mmHg

BRUCE  
EXERCISE 3  
PHASE TIME : 8:59  
STAGE TIME : 2:59

ST @ 10mm/mV  
80ms PostJ  
SPEED : 5.4 Km./Hr.  
GRADE : 14.0 %

LINKED MEDIAN



ONEPLUS ULTRASOUND LAB  
47, Harsh Vihar, Pitam Pura,  
Delhi-110034  
Ph. 011-42-400101, 9559913051  
E-mail: onepplusul@gmail.com

# ONEPLUS ULTRASOUND LAB

Mr. NEERU  
I.D. : 998

BRUCE  
EXERCISE 4

ST @ 10mm/mV  
80ms PostJ

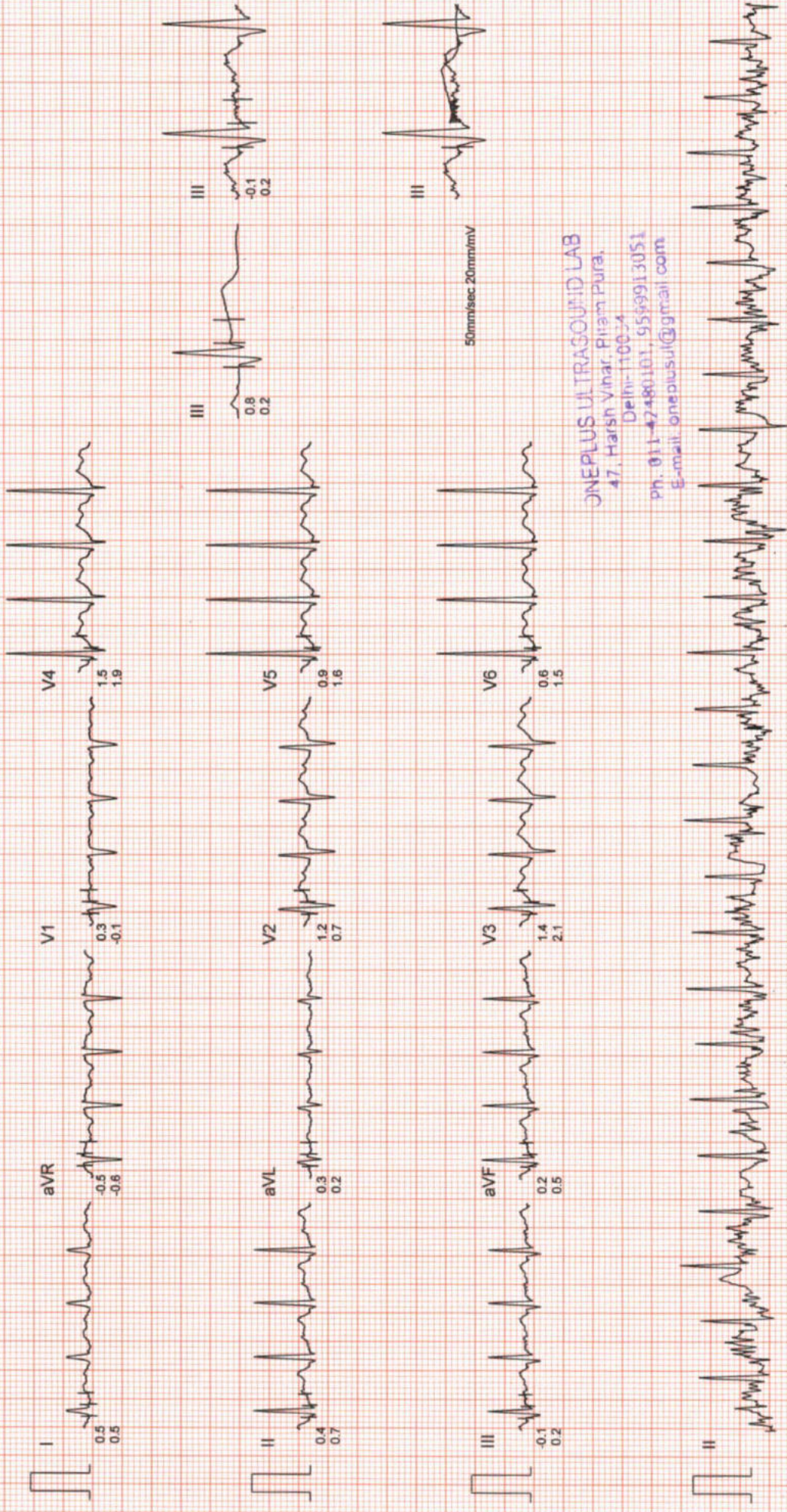
RECORDED : 18-12-2022 8:47

RATE : 157 BPM  
B.P. : 158/84 mmHg

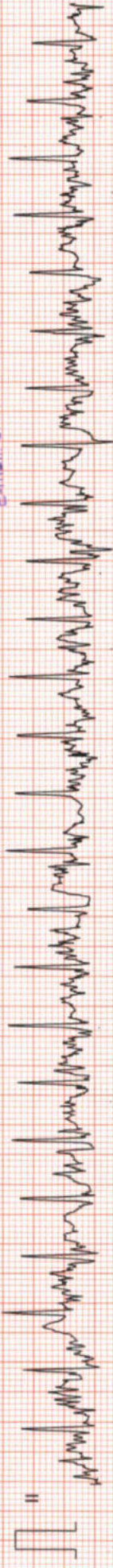
PHASE TIME : 9:44  
STAGE TIME : 0:44

SPEED : 6.7 Km./Hr.  
GRADE : 16.0 %

LINKED MEDIAN



ONEPLUS ULTRASOUND LAB  
47, Harsh Vihar, Pitam Pura,  
Delhi-110034  
Ph. 011-42481101, 9549913051  
E-mail: oneplusul@gmail.com







# ONEPLUS ULTRASOUND LAB

Mr. NEERU  
I.D. : 998

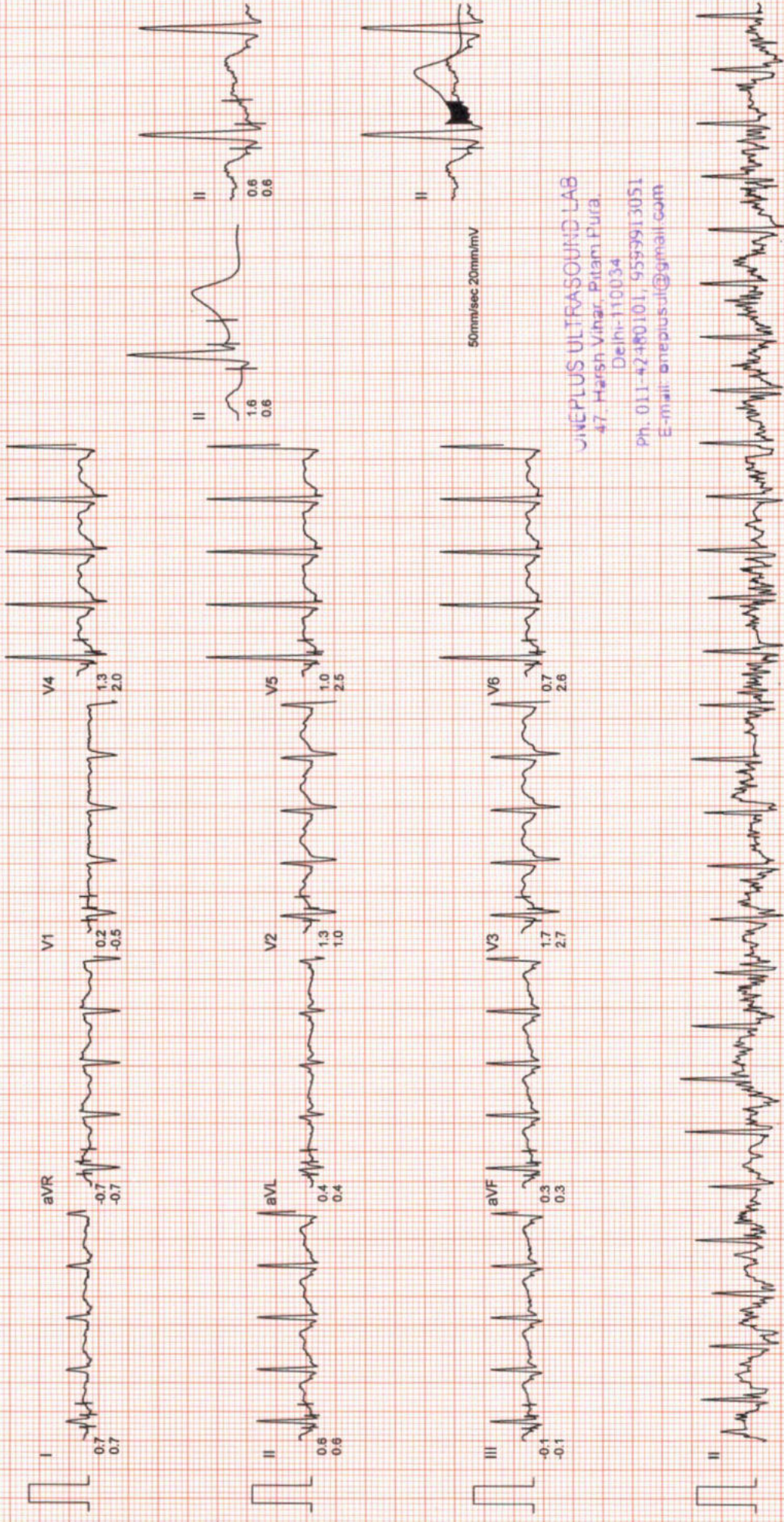
AGE/SEX : 32/M  
RECORDED : 18-12-2022 8:47

RATE : 166 BPM  
B.P. : 170/86 mmHg

BRUCE  
PEAK EXER  
PHASE TIME : 9:57  
STAGE TIME : 0:57

ST @ 10mm/mV  
80ms PostJ  
SPEED : 6.7 Km./Hr.  
GRADE : 16.0 %

LINKED MEDIAN



ONEPLUS ULTRASOUND LAB  
47, Harsh Vihar, Pitam Pura  
Delhi-110034  
Ph. 011-42480101, 5559913051  
E-mail: oneplusul@ gmail.com

# ONEPLUS ULTRASOUND LAB

Mr. NEERU  
I.D. : 998

AGE/SEX : 32/M

RECORDED : 18-12-2022 8:47

RATE : 98 BPM

B.P. : 130/76 mmHg

ST @ 10mm/mV

80ms PostJ

SPEED : 0.0 Km./Hr.

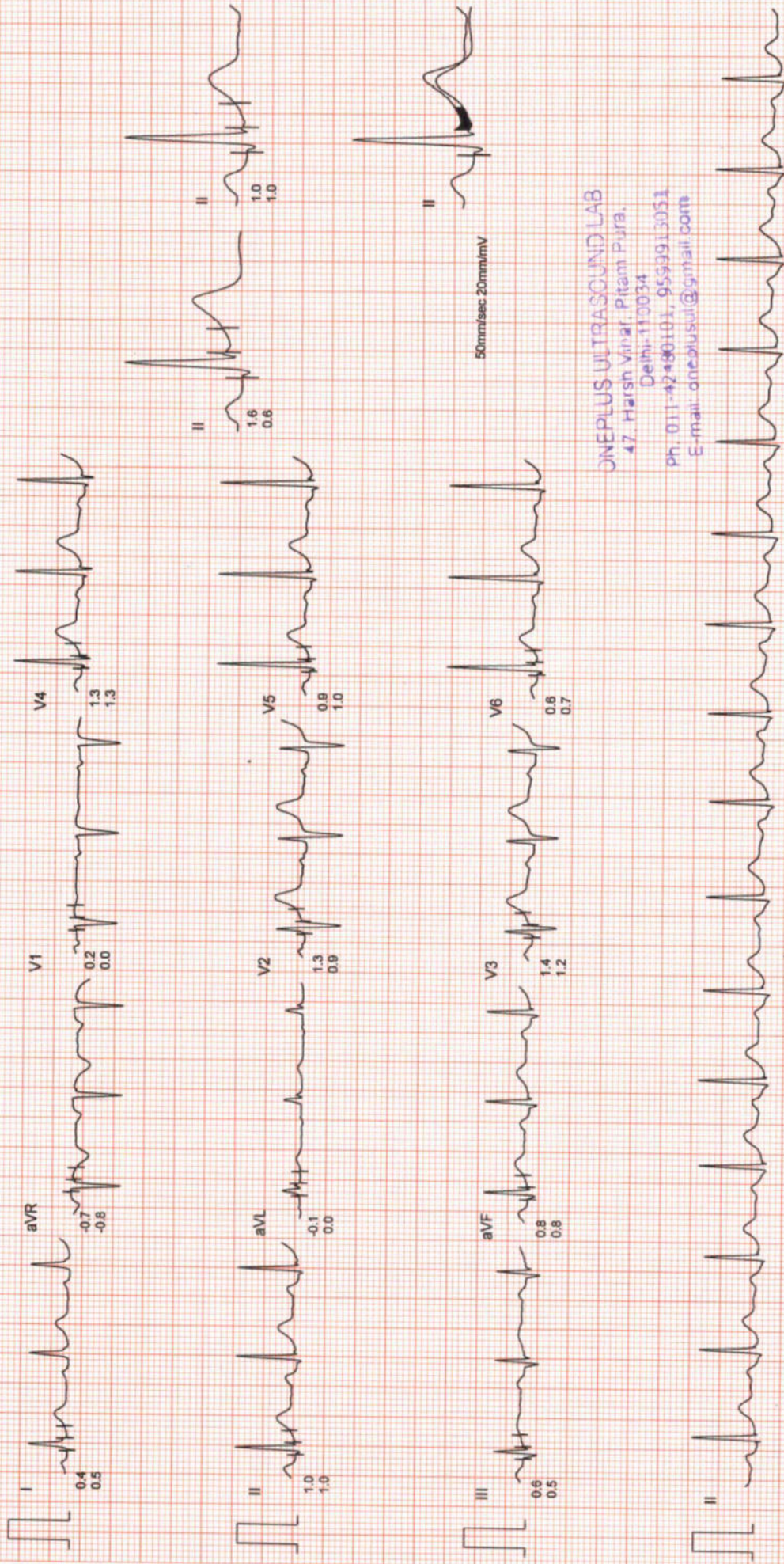
GRADE : 0.0 %

LINKED MEDIAN

BRUCE

RECOVERY

PHASE TIME : 2:59



ONEPLUS ULTRASOUND LAB

47, Harsin Vihar, Pitam Pura,

Delhi-110034

PH: 011-42480101, 9559913051

E-mail: oneplusul@gmail.com

# ONEPLUS ULTRASOUND LAB

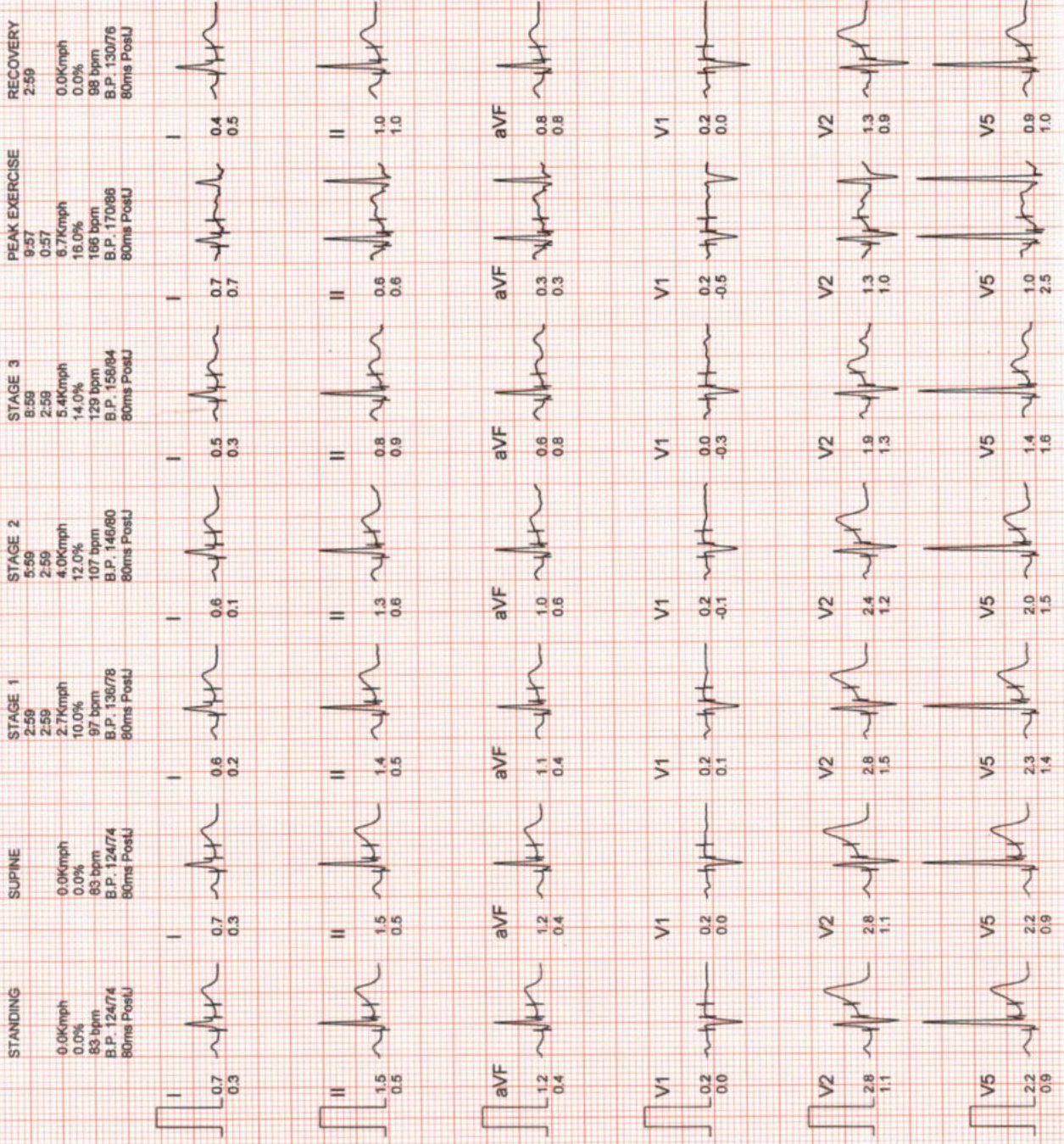
Mr. NEERU

I.D. : 998

AGE/SEX : 32/M

RECORDED : 18-12-2022 8:47

AVG E.C.G.



ONEPLUS ULTRASOUND LAB  
 47, Harsh Vihar, Pitam Pura,  
 Delhi-110034  
 Ph. 011-42441101, 9599913051  
 E-mail: oneplusul@gmail.com

# ONEPLUS ULTRASOUND LAB

AGE/SEX : 32/M

RECORDED : 18-12-2022 8:47

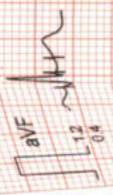
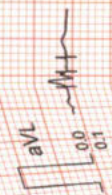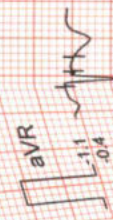

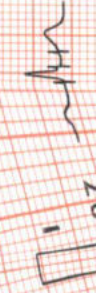I.D. : 998

Mr. **NEERU**

## COMPARISON REPORT

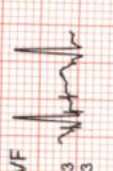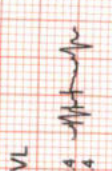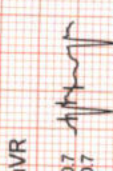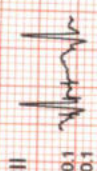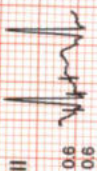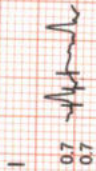### SUPINE

0.0 Km/h  
0.0%  
83 bpm  
B.P. 124/74  
80ms PostU



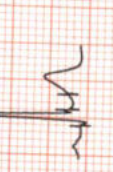
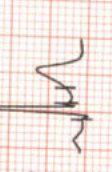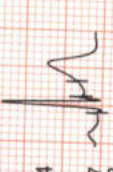
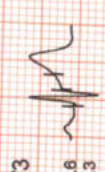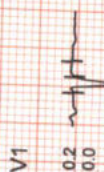
### PEAK EXERCISE

9:57  
0:57  
6.7 Km/h  
16.0%  
166 bpm  
B.P. 170/86  
80ms PostU



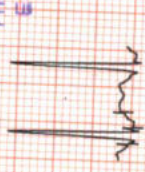
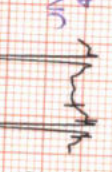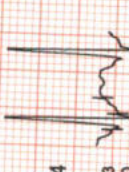
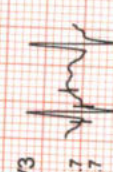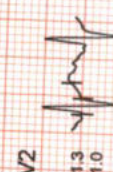
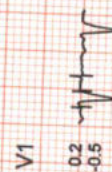### SUPINE

0.0 Km/h  
0.0%  
83 bpm  
B.P. 124/74  
80ms PostU



### PEAK EXERCISE

9:57  
0:57  
6.7 Km/h  
16.0%  
166 bpm  
B.P. 170/86  
80ms PostU



ONEPLUS ULTRASOUND LAB

47, Harsh Vihar, Pitam Pura,  
Delhi-110034

Ph. 011-42480101, 9599913051

E-mail: onetplusul@gmail.com





**OnePLUS**  
Ultrasound Lab

— QUALITY FIRST... ALWAYS! —

**Dr. Nitin Agarwal**

Pathologist & Director  
Ex. Sr. Res. MAMC  
& Lok Nayak Hospital  
Ex. Chief of Lab Dr. Lal Path Labs.

**Dr. Pooja (Garg) Agarwal**

Radiologist & Director  
MAMC & Lok Nayak Hospital

<b>Name</b>	: Mr. NEERU	<b>Age/Sex</b>	: 32 YRS/Male
<b>Ref. By</b>	: Dr. MEDIWHEEL	<b>Lab No</b>	: 012212180001
<b>Date</b>	: 18-Dec-2022	<b>Patient ID</b>	: LSHHI106429

## X-ray-Chest PA view

Bony cage and soft tissues are normal.  
Cardiothoracic ratio is normal.  
Mediastinum is normal.  
Both hila are normal.  
Both costophrenic angles are clear.  
Both domes of diaphragm are normal.  
Lung fields are clear. No parenchymal lesion seen.

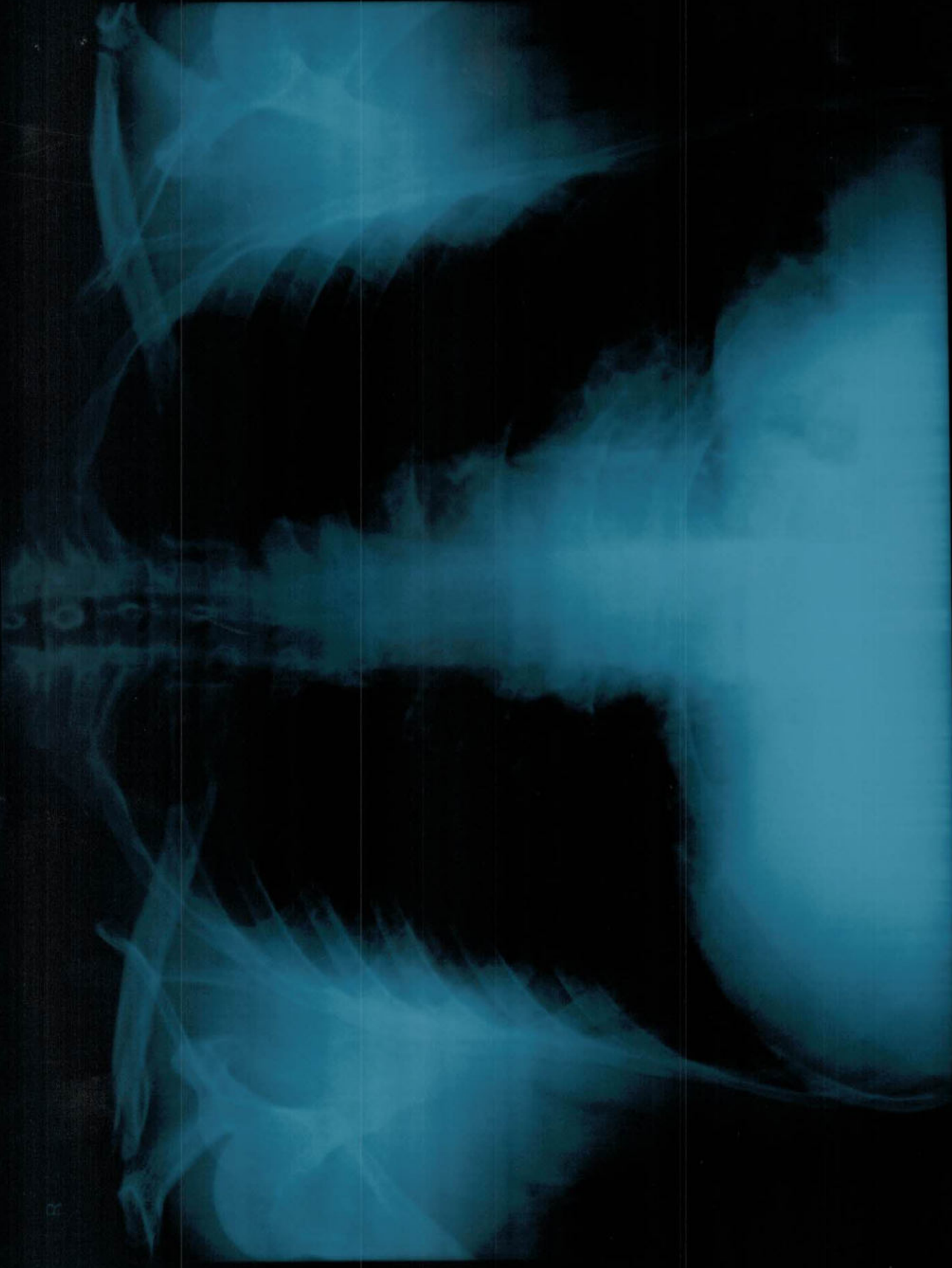
**IMPRESSION: Normal Study.**

**DR. APEKSHA ASHOK SHENOY**  
**RADIOLOGIST**  
**RegNo:DMC/R/80169**

Dr. APEKSHA ASHOK SHENOY  
MBBS, MD  
No. DMC/R/80169  
radiologist

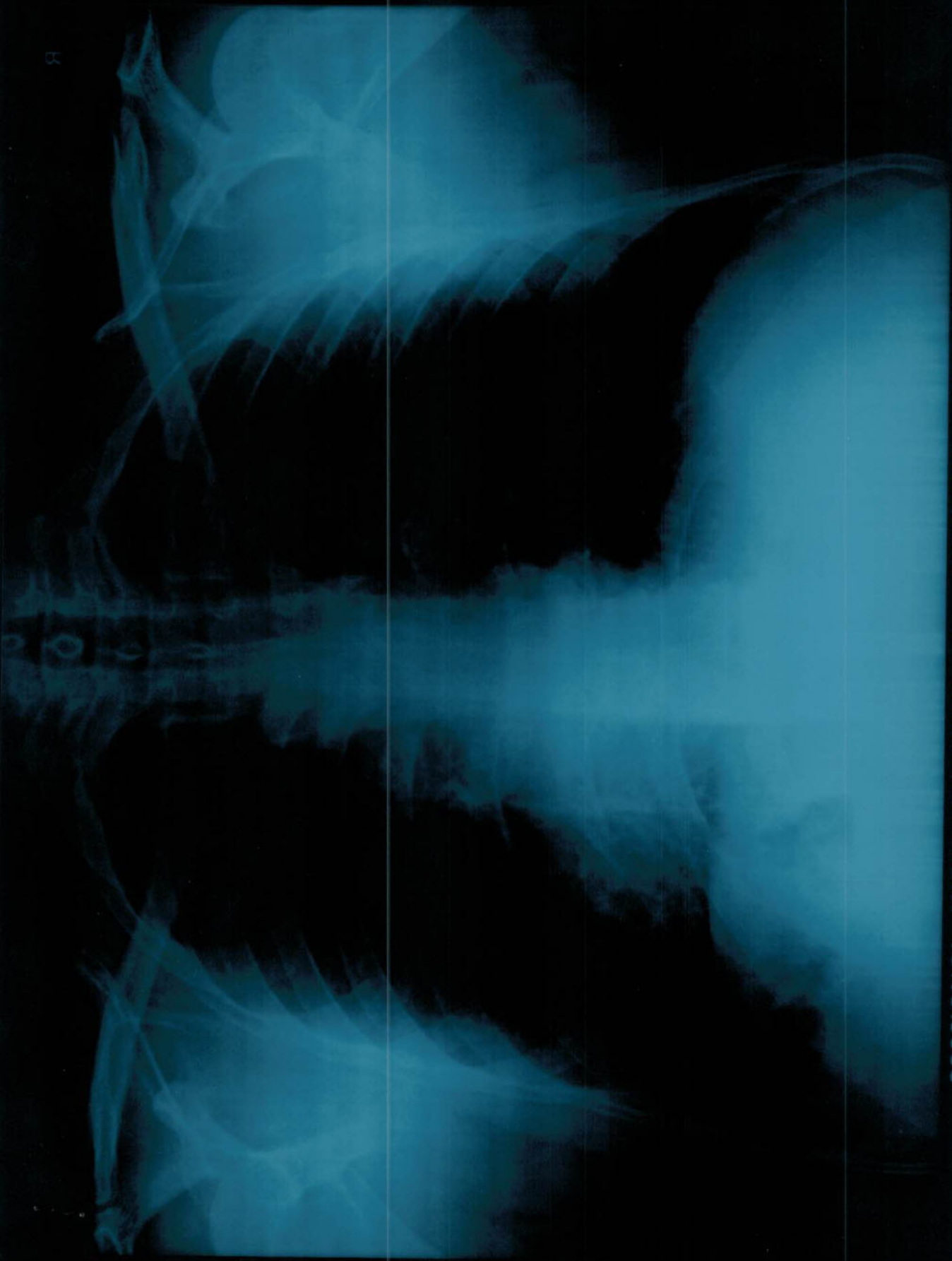
47, Harsh Vihar, Pitampura, New Delhi-110034 | Ph.: 011-42480101, 9599913051  
E-mail: oneplusul@gmail.com | Web.: www.oneplusul.in

Clinical correlation is essential for final diagnosis. • If test results are unsatisfactory please contact personally or on phone. • This report is for perusal of doctors only.  
• All disputes Subject to Delhi Jurisdiction only. • Not for medicolegal purposes. • All congenital anomalies in a foetus may not be diagnosed in routine obstetric ultrasound.



MR. NEERU 32 YRS 18/12/2022 M CHEST PA VIEW 12/18/2022  
ONEPLUS ULTRASOUND LAB, 47-HARSH VIHAR, PITAMPURA

ONEPLUS ULTRASOUND LAB, 41-HARSH VIHAR, PITAMPURA  
MR. NEERU 35 YRS 18/11/2005 M CHEST PA VIEW 15/11/2005



R