

Age **33** 1 23  
years months days

Gender **Female**

Heart Rate **76 bpm**

**Patient Vitals**

BP: NA

Weight: NA

Height: NA

Pulse: NA

Spo2: NA

Resp: NA

Others: \_\_\_\_\_

**Measurements**

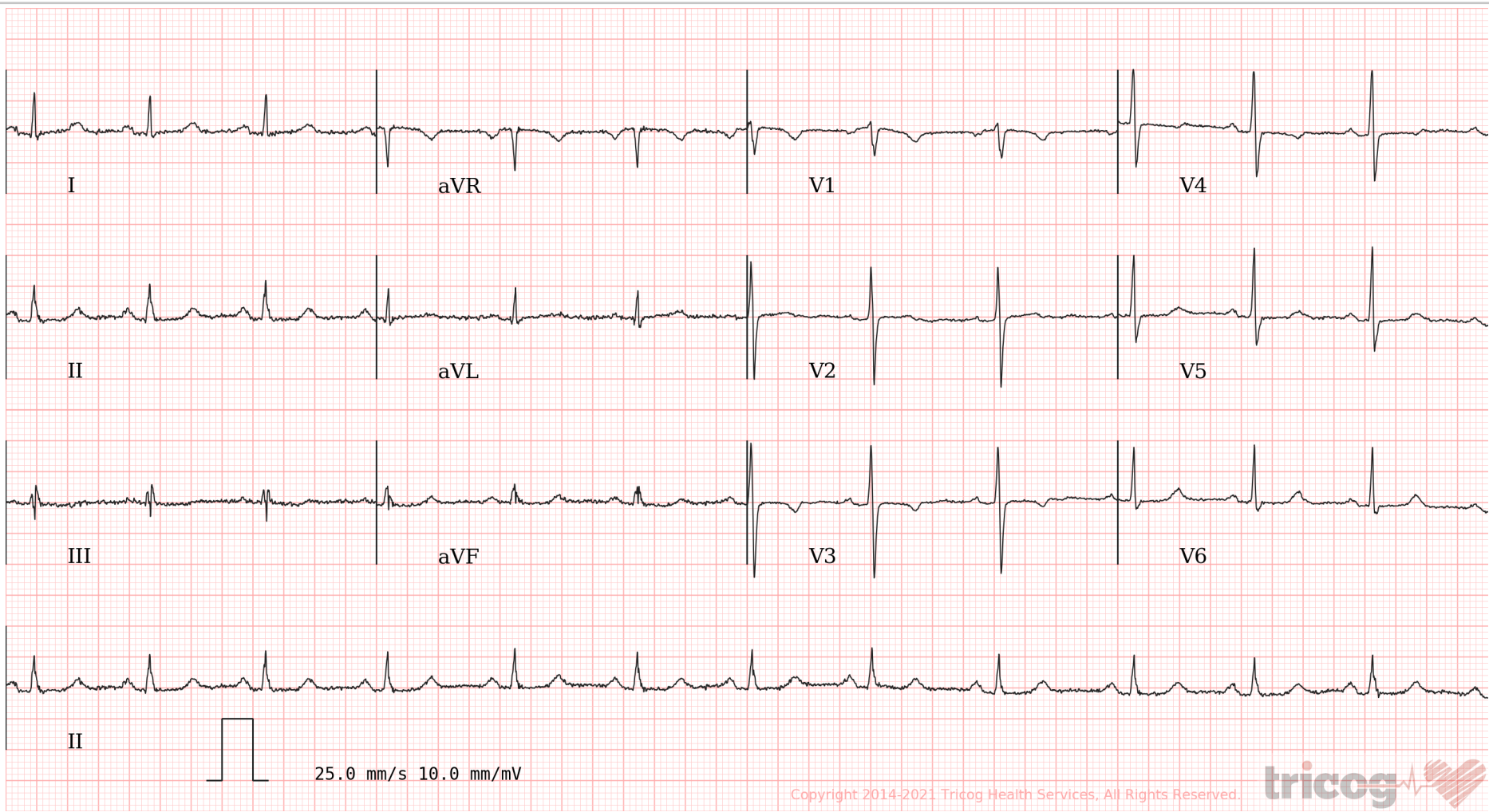
QSRD: 76 ms

QT: 400 ms

QTc: 450 ms

PR: 160 ms

P-R-T: 46° 28° 29°



Copyright 2014-2021 Tricog Health Services, All Rights Reserved.



Sinus Rhythm, Normal Axis. T wave changes seen in Anterior wall chest leads may be a normal variant in females, however, please rule out ischemia and kindly correlate clinically. Please correlate clinically.

REPORTED BY

*Anand N Motwani*

Dr. Anand N Motwani  
M.D (General Medicine)  
Reg No 39329 M.M.C