



To,

The Coordinator,  
Mediwheel (Arcofemi Healthcare Limited)  
Helpline number: 011- 41195959

Dear Sir / Madam,

**Sub: Annual Health Checkup for the employees of Bank of Baroda**

This is to inform you that the following spouse of our employee wishes to avail the facility of Cashless Annual Health Checkup provided by you in terms of our agreement.

PARTICULARS OF HEALTH CHECK UP BENEFICIARY	
NAME	SONALI MANDAL
DATE OF BIRTH	13-10-1985
PROPOSED DATE OF HEALTH CHECKUP FOR EMPLOYEE SPOUSE	28-08-2021
BOOKING REFERENCE NO.	21S100028100003084S
SPOUSE DETAILS	
EMPLOYEE NAME	MR. MANDAL INDRAJIT
EMPLOYEE EC NO.	100028
EMPLOYEE DESIGNATION	SINGLE WINDOW OPERATOR A
EMPLOYEE PLACE OF WORK	RANAGHAT
EMPLOYEE BIRTHDATE	07-09-1975

This letter of approval / recommendation is valid if submitted along with copy of the Bank of Baroda employee id card. This approval is valid from **27-08-2021** till **31-03-2022**. The list of medical tests to be conducted is provided in the annexure to this letter. Please note that the said health checkup is a **cashless facility** as per our tie up arrangement. We request you to attend to the health checkup requirement of our employee's spouse and accord your top priority and best resources in this regard. The EC Number and the booking reference number as given in the above table shall be mentioned in the invoice, invariably.

We solicit your co-operation in this regard.

Yours faithfully,

Sd/-

**Chief General Manager**  
**HRM Department**  
**Bank of Baroda**

(Note: This is a computer generated letter. No Signature required. For any clarification, please contact Mediwheel (Arcofemi Healthcare Limited))

Patho Treat Diagnostic Centre  
& Poly Clinic  
75 Dum Dum Road, Kol-700074  
Phone No. - (033) 2569 3341

**SUGGESTIVE LIST OF MEDICAL TESTS**

FOR MALE	FOR FEMALE
CBC	CBC
ESR	ESR
Blood Group & RH Factor	Blood Group & RH Factor
Blood and Urine Sugar Fasting	Blood and Urine Sugar Fasting
Blood and Urine Sugar PP	Blood and Urine Sugar PP
Stool Routine	Stool Routine
<b>Lipid Profile</b>	<b>Lipid Profile</b>
Total Cholesterol	Total Cholesterol
HDL	HDL
LDL	LDL
VLDL	VLDL
Triglycerides	Triglycerides
HDL / LDL ratio	HDL / LDL ratio
<b>Liver Profile</b>	<b>Liver Profile</b>
AST	AST
ALT	ALT
GGT	GGT
Bilirubin (total, direct, indirect)	Bilirubin (total, direct, indirect)
ALP	ALP
Proteins (T, Albumin, Globulin)	Proteins (T, Albumin, Globulin)
<b>Kidney Profile</b>	<b>Kidney Profile</b>
Serum creatinine	Serum creatinine
Blood Urea Nitrogen	Blood Urea Nitrogen
Uric Acid	Uric Acid
HBA1C	HBA1C
Routine urine analysis	Routine urine analysis
USG Whole Abdomen	USG Whole Abdomen
<b>General Tests</b>	<b>General Tests</b>
X Ray Chest	X Ray Chest
ECG	ECG
2D/3D ECHO / TMT	2D/3D ECHO / TMT
Stress Test	Thyroid Profile (T3, T4, TSH)
PSA Male (above 40 years)	Mammography (above 40 years) and Pap Smear (above 30 years).
Thyroid Profile (T3, T4, TSH)	Dental Check-up consultation
Dental Check-up consultation	Physician Consultation
Physician Consultation	Eye Check-up consultation
Eye Check-up consultation	Skin/ENT consultation
Skin/ENT consultation	Gynaec Consultation





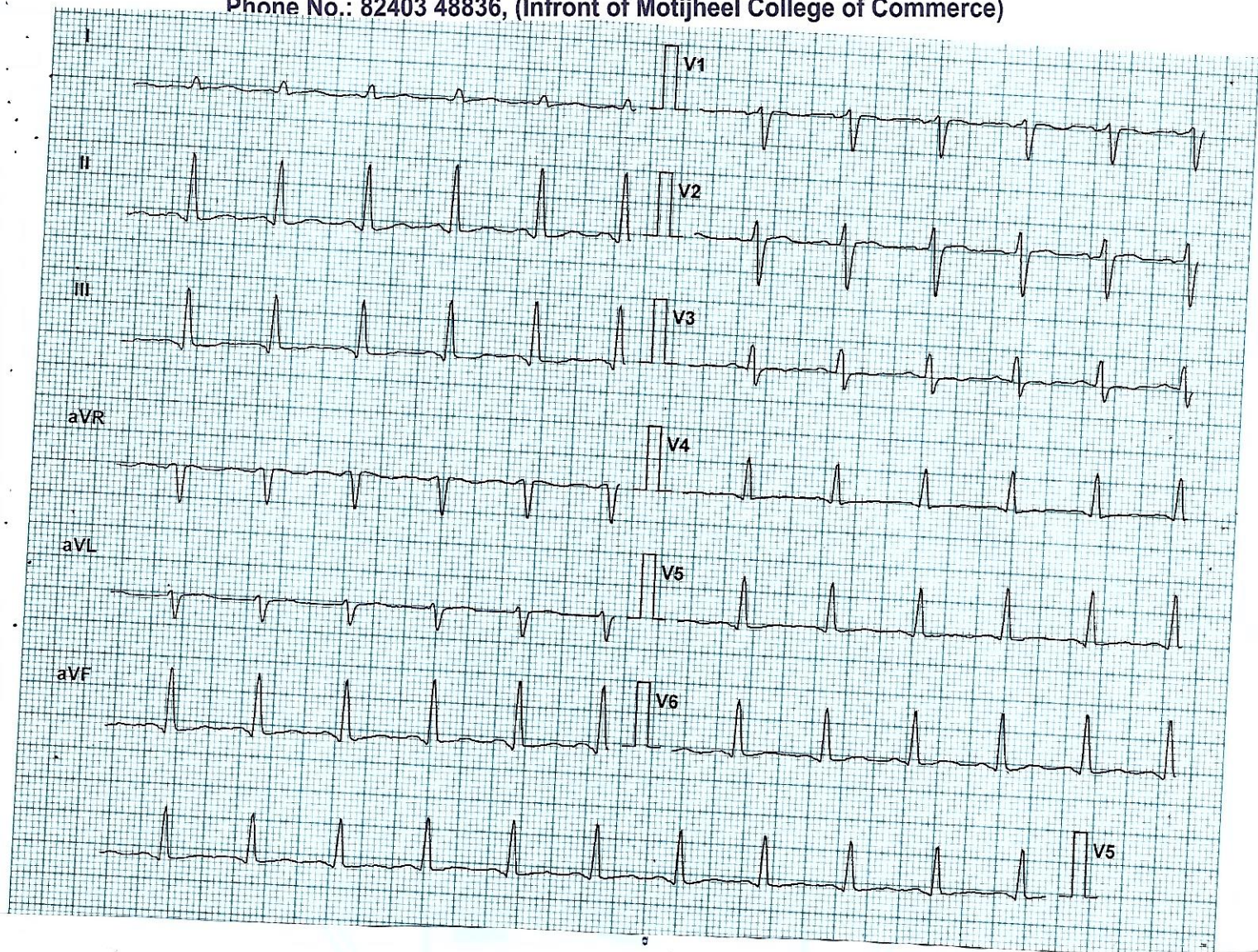
# Patho Treat

TEST REPORT

DIAGNOSTIC CENTRE & POLYCLINIC

Regd. Off : 75, Dum Dum Road, Kolkata - 700 074

Phone No.: 82403 48836, (Infront of Motijheel College of Commerce)



Sonal Mondal  
35 Year Female  
ref B.O.B.  
7/09/2021

H/R - 109 bpm  
Rhythm Sinus Tachycardia  
So  
normal ECG

Dr. Uday Sankar Das  
MBBS (Genl.), MD (Med),  
DM (Cardio), DNB (Cardio)  
No. - 4909 (WBMC)





# Patho Treat

DIAGNOSTIC CENTRE & POLYCLINIC

TEST REPORT

Regd. Off : 75, Dum Dum Road, Kolkata - 700 074  
Phone No.: 82403 48836, (Infront of Motijheel College of Commerce)

Sonali Mandal .

35 Yrs (Female.)

all reports are normal, no abnormalities found. She is Physically fit & fine & good health.

Dr. Debasish Banerjee  
M.B.B.S., MD (Medicine)  
Reg. No. - 42951



आयकर विभाग

INCOME TAX DEPARTMENT

SONALI MANDAL

SUSIL MANDAL

30/10/1985

Permanent Account Number

CMLPM8467L


*Sonal Mandal*

Signature




भारत सरकार

GOVT. OF INDIA







# Patho Treat

DIAGNOSTIC CENTRE & POLYCLINIC

TEST REPORT

Regd. Off : 75, Dum Dum Road, Kolkata - 700 074  
Phone No.: 82403 48836, (Infront of Motijheel College of Commerce)

ID NO: B/09/06  
PT.NAME= MRS SONALI MANDAL  
SEX: F AGE: 35 YRS


DATE OF RECEIPT: 07.09.2021

DATE OF REPORT: 07.09.2021

Reference By: BANK OF BARODA

## HEMATOLOGY

<u>TEST</u>		<u>RESULT</u>
"ABO" GROUPING	:	" B "
Rh (D) FACTOR	:	POSITIVE

  
DR. SUMANA MAJUMDAR  
M.B.B.S., MD  
(PATHOLOGIST)



# Patho Treat

DIAGNOSTIC CENTRE & POLYCLINIC

TEST REPORT

Regd. Off : 75, Dum Dum Road, Kolkata - 700 074  
Phone No.: 82403 48836, (Infront of Motijheel College of Commerce)


ID NO: B/09/06  
PT.NAME= MRS SONALI MANDAL  
SEX: F AGE: 35 YRS


DATE OF RECEIPT: 07.09.2021

DATE OF REPORT: 07.09.2021

Reference By: BANK OF BARODA

<u>INVESTIGATION</u>	<u>RESULT / UNIT</u>	<u>REFERENCE VALUE</u>
TOTAL TRI-IODOTHYRONIN (T3)	120ng/dl	( 60 – 181 )
TOTAL THYROXINE (T4)	7.02ng/dl	( 4.5 – 10.9 )
THYROID STIMULATING HORMONE	3.5 nl/ml	( 0.35 – 5.5 )

  
DR. SUMANA MAJUMDAR  
M.B.B.S., MD  
(PATHOLOGIST)



# Patho Treat

DIAGNOSTIC CENTRE & POLYCLINIC

TEST REPORT

Regd. Off : 75, Dum Dum Road, Kolkata - 700 074  
Phone No.: 82403 48836, (Infront of Motijheel College of Commerce)

ID NO: B/09/06  
PT.NAME= MRS SONALI MANDAL  
SEX: F AGE: 35 YRS

DATE OF RECEIPT: 07.09.2021

DATE OF REPORT: 07.09.2021

Reference By: BANK OF BARODA

## REPORT ON EXAMINATION OF BLOOD

### INVESTIGATION


### RESULT & UNIT

GLYCOSYLATED HB%  
(HBAIC)


6.14%

### REFERENCE RANGE : -

Below 6.0 % ----- Normal Value  
6.0 % - 7.0 % ----- Good Control  
7.0 % - 8.0 % ----- Fair Control  
8.0 % - 10.0 % ----- Unsatisfactory Control  
Above 10.0 % ----- Poor Control

  
DR. SUMANA MAJUMDAR  
M.B.B.S., MD  
(PATHOLOGIST)





# Patho Treat

DIAGNOSTIC CENTRE & POLYCLINIC

TEST REPORT

Regd. Off : 75, Dum Dum Road, Kolkata - 700 074  
Phone No.: 82403 48836, (Infront of Motijheel College of Commerce)

ID NO: B/09/06  
PT.NAME= MRS SONALI MANDAL  
SEX: F AGE: 35 YRS

DATE OF RECEIPT: 07.09.2021

DATE OF REPORT: 07.09.2021


Reference By: BANK OF BARODA

## DIGITAL X-RAY CHEST PA VIEW

- No focal lesion seen bilateral lung fields.
- Domes of diaphragms are smooth and regular.
- Costophrenic angles are clear.
- Cardiac shadow is normal.
- Mediastinum is central.
- Both hila are normal in position and density.
- Bony thorax shows no abnormality.

## IMPRESSION

Normal Study.

  
DR WIMLESH JI VIMAL  
M.B.B.S.,MD,  
DMRD (Radiologist)





# Patho Treat

DIAGNOSTIC CENTRE & POLYCLINIC

TEST REPORT

Regd. Off : 75, Dum Dum Road, Kolkata - 700 074  
Phone No.: 82403 48836, (Infront of Motijheel College of Commerce)

ID NO: B/09/06  
PT.NAME= MRS SONALI MANDAL  
SEX: F AGE: 35 YRS

DATE OF RECEIPT: 07.09.2021


DATE OF REPORT: 07.09.2021

Reference By: BANK OF BARODA

<u>TEST</u>	<u>RESULT</u>	<u>VALUE RANGE</u>
COTININE TEST	NEGATIVE	(<200 ng / ml)

*METHOD : - Qualitative Immunochromatographic Assay*

*SAMPLE : - URINE*

  
DR.SIMANA MAJUMDAR  
M.B.B.S.,MD  
(PATHOLOGIST)





# Patho Treat

DIAGNOSTIC CENTRE & POLYCLINIC

TEST REPORT

Regd. Off : 75, Dum Dum Road, Kolkata - 700 074  
Phone No.: 82403 48836, (Infront of Motijheel College of Commerce)

ID NO: B/09/06  
PT.NAME= MRS SONALI MANDAL  
SEX: F AGE: 35 YRS

DATE OF RECEIPT: 07.09.2021

DATE OF REPORT: 07.09.2021

Reference By: BANK OF BARODA

## REPORT ON THE EXAMINATION OF STOOL

### Physical Examination

Colour : Brownish

Consistency : Semi Liquid

Blood : Not Found

Mucus : Present

Parasite : Not Found

### Chemical Examination

Reaction : Acidic

Occult Blood : Acidic

PH : \*\*

Reducing Substance : \*\*

### Microscopical Examination

Vegetable Cell : Present Few .

Starch : Not Found .

Epithelial Cell : Not Found .

Pus Cells : 1-2/ H.P.F .

R . B . C : Not Found .

Helminthic Ova : Not Found .

Protozoal Cysts : Not Found .

Trophozoite : Not Found .

Larva : Not Found .

Fat Droplets : Not Found .

Macrophage Cells : Not Found .

Crystal : Not Found .

Micro Organisms : ( + ) .

Others : Not Found .

  
DR. SUMANA MAJUMDAR  
M.B.B.S., MD(PATHOLOGIST)





# Patho Treat

DIAGNOSTIC CENTRE & POLYCLINIC

TEST REPORT

Regd. Off : 75, Dum Dum Road, Kolkata - 700 074  
Phone No.: 82403 48836, (Infront of Motijheel College of Commerce)

ID NO: B/09/06  
PT.NAME= MRS SONALI MANDAL  
SEX: F AGE: 35 YRS

DATE OF RECEIPT: 07.09.2021

DATE OF REPORT: 07.09.2021

Reference By: BANK OF BARODA

## REPORT ON THE BIO-CHEMICAL EXAMINATION

<u>TEST</u>	<u>RESULT</u>	<u>UNIT</u>	<u>NORMAL VALUE</u>
TRIGLYCERIDES	145.00	mg / dL	( 65.00 – 170.00 )
HDL - CHOLESTEROL	45.00	mg / dL	( 30 . 00 – 55 . 00 )
LDL - CHOLESTEROL ( By Enzyaatic Mathod at 370C )	90.00	mg / dL	( Upto 150.00 )
VLDL	29.0	mg / dL	( 16 . 00 - 40 . 00 )
CHOLESTEROL - TOTAL	164.00	mg / dL	( 150 . 00 – 250 . 00 )
LDL/HDL	2.0:1		
CHOLESTEROL TOTAL/HDL	3.6:1		

  
DR.SUMANA MAJUMDAR  
M.B.B.S.,MD(PATHOLOGIST)





# Patho Treat

DIAGNOSTIC CENTRE & POLYCLINIC

TEST REPORT

Regd. Off : 75, Dum Dum Road, Kolkata - 700 074  
Phone No.: 82403 48836, (Infront of Motijheel College of Commerce)

ID NO: B/09/06  
PT.NAME= MRS SONALI MANDAL  
SEX: F AGE: 35 YRS

DATE OF RECEIPT: 07.09.2021


DATE OF REPORT: 07.09.2021


Reference By: BANK OF BARODA

## REPORT ON THE BIO – CHEMICAL EXAMINATION

-----

<u>TEST</u>	<u>RESULT</u>	<u>UNIT</u>	<u>NORMAL VALUE</u>
SUGAR (F)	133	mg / dl	(70 – 110)
SUGAR (PP)	231	mg / dl	(110 – 140)
CREATININE	0.76	mg /dL	(0.70 - 1.20)
URIC – ACID	3.9	mg/dL	(Male -3.4 – 7.0 Female - 2.4 – 5.7)
BUN	11.4	mg/dL	(5 – 23)
BUN/CREATININE	15/1		

  
DR.SUMANA MAJUMDAR  
M.B.B.S.,MD  
(PATHOLOGIST)



# Patho Treat

DIAGNOSTIC CENTRE & POLYCLINIC

TEST REPORT

Regd. Off : 75, Dum Dum Road, Kolkata - 700 074  
Phone No.: 82403 48836, (Infront of Motijheel College of Commerce)

ID NO: B/09/06  
PT.NAME= MRS SONALI MANDAL  
SEX: F AGE: 35 YRS

DATE OF RECEIPT: 07.09.2021

DATE OF REPORT: 07.09.2021

Reference By: BANK OF BARODA

## PHYSICAL EXAMINATION


Quantity	40 ml
Colour	watery
Appearance	clear
Deposit	Nil
Sp. Gravity	1.015

## MICROSCOPIC EXAMINATION

R.B.C.	Not Found
Epithelial Cells	(3 - 4 / H.P.F)
Pus Cells	(2 - 3 / H.P.F)
Casts	Not Found
Crystal	Not Found
Micro Organisms	Present a few.
Parasites	Not Found
Yeast Cells	Not Found
Others	Not Found

## CHEMICAL EXAMINATION

Reaction	Acidic
Albumin	Negative
Proteins	Negative
Sugar	Negative
Acetone	Negative
Bile Salt	Absent
Bile Pigment	Absent
Phosphates	Negative
Chyle	Negative
Occult Blood	Negative
Urobilinogen	Normal
Others	Negative

  
DR. SUMANA MAJUMDAR  
M.B.B.S., MD  
(PATHOLOGIST)





# Patho Treat

DIAGNOSTIC CENTRE & POLYCLINIC

TEST REPORT

Regd. Off : 75, Dum Dum Road, Kolkata - 700 074  
Phone No.: 82403 48836, (Infront of Motijheel College of Commerce)

DATE OF RECEIPT: 07.09.2021

ID NO: B/09/06

PT.NAME= MRS SONALI MANDAL

SEX: F AGE: 35 YRS

DATE OF REPORT: 07.09.2021

Reference By: BANK OF BARODA

TEST	RESULT & UNIT	NORMAL RANGE
HAEMOGLOBIN (Cyanmethmaglobin Method)	13.9 gm %	Male :- ( 13 - 18 ) Female :- ( 11.5 - 16.5 )
Total R.B.C	3.94 Million / cmm	3.5 - 6.5 Million / cmm
Total W.B.C	6900 / cmm	( 4000 - 11000 ) / cmm
Platelets Count	2.13 lac / cmm	( 1.5 - 4.0 ) lac / cmm

### Differential Count W.B.C

TEST	RESULT & UNIT	NORMAL RANGE
Neutrophils	67%	( 40 - 80 ) %
Lymphocytes	30%	( 20 - 40 ) %
Eosinophils	02 %	( 2 - 10 ) %
Monocytes	01 %	( 1 - 6 ) %
Basophils	00 %	( 0 - 2 ) %


### Haemogram

TEST	RESULT & UNIT	NORMAL RANGE
PCV	41.7%	( 38 - 54 ) %
MCV	85 Um <sup>3</sup>	( 77 - 93 ) Um <sup>3</sup>
MCH	31 g %	( 26 - 32 ) g %
MCHC	29 %	( 27 - 35 ) %

Morphology of RBC : Normocytic, Normochromic.

ESR(Westergern Method): 1<sup>st</sup> Hour-18/mm ( MALE : 0 - 14 FEMALE : 0-20)

DR.SUMANA MAJUMDAR  
M.B.B.S.,MD  
(PATHOLOGIST)



# Patho Treat

DIAGNOSTIC CENTRE & POLYCLINIC

TEST REPORT

Regd. Off : 75, Dum Dum Road, Kolkata - 700 074  
Phone No.: 82403 48836, (Infront of Motijheel College of Commerce)

ID NO: B/09/06  
PT.NAME= MRS SONALI MANDAL  
SEX: F AGE: 35 YRS


DATE OF RECEIPT: 07.09.2021

DATE OF REPORT: 07.09.2021

Reference By: BANK OF BARODA

## REPORT ON THE BIO - CHEMICAL EXAMINATION

<u>TEST</u>	<u>RESULT</u>	<u>UNIT</u>	<u>NORMAL VALUE</u>
BILIRUBIN TOTAL	0.78	mg /dL	( Upto 1.00 )
Bilirubin Conjugated	0.21	mg /dL	( Upto 0.25 )
Bilirubin Unconjugated	0.57	mg /dL	( Upto 0.75 )
SGOT/AST	25.00	U/L	( Male : 10 -35 Female : 10 - 31)
SGPT/ALT	34.00	U/L	( 9.00 - 43.00 )
TOTAL PROTEIN	7.68	g/dL	( 6.00 - 8.50 )
ALBUMIN	4.50	gm/dL	( 3.5 - 5.2 )
GLOBULIN :	3.18	gm/dL	( 2.3 - 3.6 )
A G Ratio :	1.4:1		
GAMA GT (G . G . T)	35.0	IU/L	( 7.00 - 52.00 )
ALKALINE PHOSPHATSE	98.0	IU/L	<i>Upto 5Yrs. F: 48-406, M: 75-389 5-10 Yrs.F: 96-332, M: 93-362 11- 15 Yrs. F: 52-162, M:74-390 16- 19 Yrs.F: 47-119, M:52-171 Adult - F: 35-141, M: 40-129</i>
AST/ALT RATIO	1.36:1		

  
DR.SUMANA MAJUMDAR  
M.B.B.S.,MD (PATHOLOGIST)



**Regd. Off : 75, Dum Dum Road, Kolkata - 700 074****Phone No.: (033) 2560 3641 / 3642, (033) 6526 0026, (Infront of Motijheel College of Commerce)**

Associate Code :	D1	Received On :	07/09/2021
Patient's Name :	MR INDRAJIT MANDAL	Reported On :	08/09/2021
ID Number :	10470/I-833	Age/Sex :	46Y/MALE
Referred By :	SELF	Sample Source :	

ClinicPro/debjan

Page 1 of 1

## ULTRASONOGRAPHY OF WHOLE ABDOMEN

### LIVER

It is enlarged (19.3 cm) in size. Parenchymal echotexture is raised. No focal parenchymal lesion is seen. Intrahepatic biliary radicles not dilated.

### PORTA

PV : Normal in diameter with echofree lumen. PV measures 0.9 cm.

CD : Normal in caliber. No calculus is seen upto tracable part. CD measures 0.3 cm.

### GALL BLADDER

Gall bladder is normally distended with normal wall thickness. No intraluminal calculus is noted.

### PANCREAS

Normal in size, shape & outline. No focal S.O.L. or calcification noted. Main pancreatic duct – not dilated.

### SPLEEN

Spleen is normal in size (8.9 cm). Parenchymal echotexture is normal. Splenic vein at its hilum is not dilated.

### KIDNEY

Both kidneys are normal in size, shape and outline. Cortical echogenicity appears normal on both sides. Central echocomplexes are normal. Corticomedullary differentiation is maintained. No evidence of stone, hydronephrosis or any mass lesion seen on either side.

**DR. S. PAL**  
M.B.B.S.(KOL),  
APUSC-CBET(WBUHS)  
CONSULTANT SONOLOGIST

  
**DR. V. J. VIMAL**  
MD,DMRD  
CONSULTANT RADIOLOGIST

Checked by.....

Regd. Off : 75, Dum Dum Road, Kolkata - 700 074

Phone No.: (033) 2560 3641 / 3642, (033) 6526 0026, (Infront of Motijheel College of Commerce)

## URETERS

Not visualized hence not dilated.

## URINARY BLADDER

Urinary bladder is well distended and normal in wall thickness. No intraluminal pathology or intramural mass lesion seen.

## PROSTATE

It is mildly enlarged in size and homogenous echotexture. Capsule is intact. No sizeable mass lesion is seen. Both seminal vesicles appear normal. Prostate measures 3.4 x 3.9 x 3.5 cm. Weight 25 gm.

No appreciable retroperitoneal lymphadenopathy noted at present.

No detectable ascites seen in peritoneal cavity.

**IMPRESSION 1. Moderate hepatomegaly with fatty liver.**

**2. Mild prostatomegaly**

**DR. S. PAL**  
M.B.B.S.(KOL),  
APUSC-CBET(WBUHS)  
CONSULTANT SONOLOGIST

**DR. V. J. VIMAL**  
MD,DMRD  
CONSULTANT RADIOLOGIST

Checked by.....