



**LABORATORY REPORT : BIOCHEMISTRY**

<b>Name</b>	: Ms. PRACHI PRATIK YEOTIKAR	<b>Age /Sex</b>	: 32Y Y(s)/FEMALE
<b>Bill Date</b>	: 09-Nov-2024 09:55 AM	<b>UMR No.</b>	: 702411000718
<b>Rec. Dt</b>	: 09-Nov-2024 10:28 AM	<b>Bill No.</b>	: MCB70241102753
<b>Rept. Dt</b>	: 09-Nov-2024 11:39 AM	<b>Result No</b>	: RUR241109964
<b>Ref By</b>	: Dr. Ananddeep Agarwal	<b>Sample ID</b>	: MCHAU4047304
<b>Sample Type</b>	: SERUM		

**BUN(BLOOD UREA NITROGEN)**

**Parameters**  
**BLOOD UREA**  
*Urease kinetic*

**Result**  
23.3

**Reference Range**  
16.6 - 48.5

**Units**  
mg/dL

\*\*\* End Of Report \*\*\*



DR. URMILA AJAY ROTTE  
CONSULTANT PATHOLOGIST, MBBS,  
DIPLOMA IN PATHOLOGY



**LABORATORY REPORT : BIOCHEMISTRY**

<b>Name</b>	: Ms. PRACHI PRATIK YEOTIKAR	<b>Age /Sex</b>	: 32Y Y(s)/FEMALE
<b>Bill Date</b>	: 09-Nov-2024 09:55 AM	<b>UMR No.</b>	: 702411000718
<b>Rec. Dt</b>	: 09-Nov-2024 10:28 AM	<b>Bill No.</b>	: MCB70241102753
<b>Rept. Dt</b>	: 09-Nov-2024 11:54 AM	<b>Result No</b>	: RUR241109965
<b>Ref By</b>	: Dr. Ananddeep Agarwal	<b>Sample ID</b>	: MCHAU4047305
<b>Sample Type</b>	: SERUM		

**HBA1C (GLYCOSYLATED HAEMOGLOBIN)**

**Parameters**  
**HBA1C**  
HPLC

**Result**  
5.6

**Reference Range**  
" Normal : < 5.7%  
Pre diabetic : 5.7 % - 6.5 %  
Diabetic : > 6.5 %

**Units**

\*\*\* End Of Report \*\*\*

DR. Suwarna Rahul Jawale  
CONSULTANT PATHOLOGIST, MBBS,  
DNB



**LABORATORY REPORT : BIOCHEMISTRY**

<b>Name</b>	: Ms. PRACHI PRATIK YEOTIKAR	<b>Age /Sex</b>	: 32Y Y(s)/FEMALE
<b>Bill Date</b>	: 09-Nov-2024 09:55 AM	<b>UMR No.</b>	: 702411000718
<b>Rec. Dt</b>	: 09-Nov-2024 10:28 AM	<b>Bill No.</b>	: MCB70241102753
<b>Rept. Dt</b>	: 09-Nov-2024 11:39 AM	<b>Result No</b>	: RUR241109966
<b>Ref By</b>	: Dr. Anandeep Agarwal	<b>Sample ID</b>	: MCHAU4047304
<b>Sample Type</b>	: SERUM		

**LIPID PROFILE**

<u>Parameters</u>	<u>Result</u>	<u>Reference Range</u>	<u>Units</u>
<b>TOTAL CHOLESTEROL</b> <i>Enzymatic colorimetric</i>	<b>222.7 *</b>	Desirable : : < 200 mg/dL Borderline High : : 200 - 239 mg/dL High risk : > 240 mg/dL	mg/dL
<b>HDL CHOLESTEROL</b> <i>Homogeneous enzymatic colorimetric</i>	30.0	Low : : < 40 mg/dL High : : > 60 mg/dL	mg/dL
<b>LDL CHOLESTEROL</b> <i>Direct-Enzymatic colorimetric</i>	149 *	Very High : - > 190 mg/dL Optimal : - < 100 mg/dL Near Optimal : 100 - 129 mg/dL High : 160 - 189 mg/dL Borderline High:130-159 mg/dl	mg/dL
<b>VLDL</b> <i>Calculation</i>	43.46 *	2 - 30 mg/dL	mg/dL
<b>SERUM TRYGLYCERIDES</b> <i>Enzymatic colorimetric</i>	<b>217.3 *</b>	< 150 mg/dL Borderline High : 150 - 199 mg/dL High : 200 - 499 mg/dL	mg/dL
<b>CHO/HDL RATIO</b> <i>Calculation</i>	7.42 *	Normal : - < 3.5 High Risk : - > 5.0	
<b>LDL/HDL RATIO</b>	4.97		

\*\*\* End Of Report \*\*\*

*UAR*

DR. URMILA AJAY ROTTE  
CONSULTANT PATHOLOGIST, MBBS,  
DIPLOMA IN PATHOLOGY



**LABORATORY REPORT : BIOCHEMISTRY**

<b>Name</b>	: Ms. PRACHI PRATIK YEOTIKAR	<b>Age /Sex</b>	: 32Y Y(s)/FEMALE
<b>Bill Date</b>	: 09-Nov-2024 09:55 AM	<b>UMR No.</b>	: 702411000718
<b>Rec. Dt</b>	: 09-Nov-2024 10:28 AM	<b>Bill No.</b>	: MCB70241102753
<b>Rept. Dt</b>	: 09-Nov-2024 11:39 AM	<b>Result No</b>	: RUR241109967
<b>Ref By</b>	: Dr. Ananddeep Agarwal	<b>Sample ID</b>	: MCHAU4047306
<b>Sample Type</b>	: PLASMA		

**FBS (FASTING BLOOD GLUCOSE WITH URINE GLUCOSE)**

<b><u>Parameters</u></b>	<b><u>Result</u></b>	<b><u>Reference Range</u></b>	<b><u>Units</u></b>
<b>FASTING BLOOD GLUCOSE</b> <i>Hexokinase</i>	97	Normal Range : 70 - 99 Impaired Glucose tolerance : 100 -125 Diabetes Mellitus : >=126	mg/dL

\*\*\* End Of Report \*\*\*



DR. URMILA AJAY ROTTE  
CONSULTANT PATHOLOGIST, MBBS,  
DIPLOMA IN PATHOLOGY



**LABORATORY REPORT : BIOCHEMISTRY**

<b>Name</b>	: Ms. PRACHI PRATIK YEOTIKAR	<b>Age /Sex</b>	: 32Y Y(s)/FEMALE
<b>Bill Date</b>	: 09-Nov-2024 09:55 AM	<b>UMR No.</b>	: 702411000718
<b>Rec. Dt</b>	: 09-Nov-2024 10:28 AM	<b>Bill No.</b>	: MCB70241102753
<b>Rept. Dt</b>	: 09-Nov-2024 11:39 AM	<b>Result No</b>	: RUR241109968
<b>Ref By</b>	: Dr. Ananddeep Agarwal	<b>Sample ID</b>	: MCHAU4047304
<b>Sample Type</b>	: SERUM		

**SERUM CREATININE**

**Parameters**  
**CREATININE**  
*Jaffe*

**Result**  
0.68

**Reference Range**  
0.5 - 1.2

**Units**  
mg/dL

\*\*\* End Of Report \*\*\*

*UAR*

DR. URMILA AJAY ROTTE  
CONSULTANT PATHOLOGIST, MBBS,  
DIPLOMA IN PATHOLOGY



**LABORATORY REPORT : BIOCHEMISTRY**

<b>Name</b>	: Ms. PRACHI PRATIK YEOTIKAR	<b>Age /Sex</b>	: 32Y Y(s)/FEMALE
<b>Bill Date</b>	: 09-Nov-2024 09:55 AM	<b>UMR No.</b>	: 702411000718
<b>Rec. Dt</b>	: 09-Nov-2024 10:28 AM	<b>Bill No.</b>	: MCB70241102753
<b>Rept. Dt</b>	: 09-Nov-2024 11:39 AM	<b>Result No</b>	: RUR241109970
<b>Ref By</b>	: Dr. Ananddeep Agarwal	<b>Sample ID</b>	: MCHAU4047304
<b>Sample Type</b>	: SERUM		

**T3,T4 AND TSH**

<b><u>Parameters</u></b>	<b><u>Result</u></b>	<b><u>Reference Range</u></b>	<b><u>Units</u></b>
<b>T3</b> ECLIA	1.11	0.8 - 2.0	ng/mL
<b>T4</b> ECLIA	8.17	5.1 - 14.1	ug/dL
<b>TSH(THYROID STIMULATING HORMONE)</b> ECLIA	2.07	0.270 - 4.20	uIU/mL

\*\*\* End Of Report \*\*\*



DR. URMILA AJAY ROTTE  
CONSULTANT PATHOLOGIST, MBBS,  
DIPLOMA IN PATHOLOGY



**LABORATORY REPORT : BIOCHEMISTRY**

<b>Name</b>	: Ms. PRACHI PRATIK YEOTIKAR	<b>Age /Sex</b>	: 32Y Y(s)/FEMALE
<b>Bill Date</b>	: 09-Nov-2024 09:55 AM	<b>UMR No.</b>	: 702411000718
<b>Rec. Dt</b>	: 09-Nov-2024 10:28 AM	<b>Bill No.</b>	: MCB70241102753
<b>Rept. Dt</b>	: 09-Nov-2024 11:39 AM	<b>Result No</b>	: RUR241109971
<b>Ref By</b>	: Dr. Ananddeep Agarwal	<b>Sample ID</b>	: MCHAU4047304
<b>Sample Type</b>	: SERUM		

**LFT(LIVER FUNCTION TEST)**

<u>Parameters</u>	<u>Result</u>	<u>Reference Range</u>	<u>Units</u>
<b>TOTAL BILIRUBIN</b> <i>DIAZO</i>	0.24	<1.2	mg/dL
<b>DIRECT BILIRUBIN</b> <i>DIAZO</i>	0.08	<=0.20	mg/dL
<b>INDIRECT BILIRUBIN</b> <i>Calculated</i>	0.16	<=1.0	mg/dL
<b>SGPT (ALT)</b> <i>UV without P5P</i>	36.7 *	<=33	U/L
<b>SGOT (AST)</b> <i>UV without P5P</i>	19.3	<= 32	U/L
<b>ALKALINE PHOSPHATASE (ALP)</b> <i>PNPP, AMP Buffer - IFCC Ref.</i>	74.0	35 - 105	U/L
<b>TOTAL PROTEINS</b> <i>Biuret method</i>	7.34	6.0 - 8.0 g/dL	g/dL
<b>SERUM ALBUMIN</b> <i>Bromcresol Green (BCG)</i>	4.21	3.5 - 5.2 g/dL	g/dL
<b>GLOBULINS</b> <i>Calculated</i>	3.13	2.5 - 3.5 g/dL	g/dL
<b>A/G RATIO</b> <i>Calculation</i>	1.35	1.2 - 2.5	

\*\*\* End Of Report \*\*\*

*UAR*

DR. URMILA AJAY ROTTE  
CONSULTANT PATHOLOGIST, MBBS,  
DIPLOMA IN PATHOLOGY



**LABORATORY REPORT : BIOCHEMISTRY**

<b>Name</b>	: Ms. PRACHI PRATIK YEOTIKAR	<b>Age /Sex</b>	: 32Y Y(s)/FEMALE
<b>Bill Date</b>	: 09-Nov-2024 09:55 AM	<b>UMR No.</b>	: 702411000718
<b>Rec. Dt</b>	: 09-Nov-2024 10:28 AM	<b>Bill No.</b>	: MCB70241102753
<b>Rept. Dt</b>	: 09-Nov-2024 11:39 AM	<b>Result No</b>	: RUR241109972
<b>Ref By</b>	: Dr. Ananddeep Agarwal	<b>Sample ID</b>	: MCHAU4047304
<b>Sample Type</b>	: SERUM		

**SERUM URIC ACID**

<b><u>Parameters</u></b>	<b><u>Result</u></b>	<b><u>Reference Range</u></b>	<b><u>Units</u></b>
<b>SERUM URIC ACID</b> <i>uricase</i>	5.1	2.4-5.7	mg/dL

\*\*\* End Of Report \*\*\*

*UAR*

DR. URMILA AJAY ROTTE  
CONSULTANT PATHOLOGIST, MBBS,  
DIPLOMA IN PATHOLOGY





**LABORATORY REPORT : BIOCHEMISTRY**

<b>Name</b>	: Ms. PRACHI PRATIK YEOTIKAR	<b>Age /Sex</b>	: 32Y Y(s)/FEMALE
<b>Bill Date</b>	: 09-Nov-2024 09:55 AM	<b>UMR No.</b>	: 702411000718
<b>Rec. Dt</b>	: 09-Nov-2024 01:17 PM	<b>Bill No.</b>	: MCB70241102753
<b>Rept. Dt</b>	: 09-Nov-2024 02:45 PM	<b>Result No</b>	: RUR241110329
<b>Ref By</b>	: Dr. Ananddeep Agarwal	<b>Sample ID</b>	: MCHAU4047430
<b>Sample Type</b>	:		

**PLBS (POST LUNCH BLOOD SUGAR WITH URINE SUGAR)**

<b><u>Parameters</u></b>	<b><u>Result</u></b>	<b><u>Reference Range</u></b>	<b><u>Units</u></b>
<b>PLBS (POST LUNCH BLOOD GLUCOSE )</b> <i>Hexokinase</i>	80	Norma Range : < 140 mg/dL mpaired Glucose Tolerance : 140-199 mg/dL Diabetes Mellitus : > 200 mg/dL	mg/dL

\*\*\* End Of Report \*\*\*



DR. URMILA AJAY ROTTE  
CONSULTANT PATHOLOGIST, MBBS,  
DIPLOMA IN PATHOLOGY



**LABORATORY REPORT : BLOOD BANK**

<b>Name</b>	: Ms. PRACHI PRATIK YEOTIKAR	<b>Age /Sex</b>	: 32Y Y(s)/FEMALE
<b>Bill Date</b>	: 09-Nov-2024 09:55 AM	<b>UMR No.</b>	: 702411000718
<b>Rec. Dt</b>	: 09-Nov-2024 10:28 AM	<b>Bill No.</b>	: MCB70241102753
<b>Rept. Dt</b>	: 09-Nov-2024 12:48 PM	<b>Result No</b>	: RUR241109974
<b>Ref By</b>	: Dr. Ananddeep Agarwal	<b>Sample ID</b>	: MCHAU4047308
<b>Sample Type</b>	: WHOLE BLOOD		

**BLOOD GROUPING AND RH**

<u>Parameters</u>	<u>Result</u>	<u>Reference Range</u>	<u>Units</u>
<b>BLOOD GROUP</b> <i>Automated microcolumn gel method</i>	A		
<b>RH TYPE</b>	POSITIVE		

**INTERPRETATION**

1. If Rh is Du positive it is best considered as Rh negative as recipient and Rh positive as donor. Proper Cross matching is recommended before transfusion.
2. In case of forward and reverse grouping discrepancy, clinical correlation and repeat sample analysis is recommended.
3. For Infants below 6 months only forward grouping is performed.
4. A sub-grouping is recommended after the age of 6 months.

\*\*\* End Of Report \*\*\*



DR. Suwarna Rahul Jawale  
CONSULTANT PATHOLOGIST, MBBS,  
DNB



**LABORATORY REPORT : CLINICAL PATHOLOGY**

<b>Name</b>	: Ms. PRACHI PRATIK YEOTIKAR	<b>Age /Sex</b>	: 32Y Y(s)/FEMALE
<b>Bill Date</b>	: 09-Nov-2024 09:55 AM	<b>UMR No.</b>	: 702411000718
<b>Rec. Dt</b>	: 09-Nov-2024 10:28 AM	<b>Bill No.</b>	: MCB70241102753
<b>Rept. Dt</b>	: 09-Nov-2024 11:31 AM	<b>Result No</b>	: RUR241109973
<b>Ref By</b>	: Dr. Ananddeep Agarwal	<b>Sample ID</b>	: MCHAU4047307
<b>Sample Type</b>	: URINE		

**CUE(COMPLETE URINE EXAMINATION)**

<u>Parameters</u>	<u>Result</u>	<u>Reference Range</u>	<u>Units</u>
<b><u>PHYSICAL EXAMINATION</u></b>			
<b>QUANTITY</b>	20		ML
<b>COLOUR</b>	PALE YELLOW	PALE YELLOW	
<b>APPEARANCE</b>	CLEAR	CLEAR	
<b>PROTEIN</b> <i>Tetra-bromophenol blue/Heat coagulation test</i>	NIL	NIL	
<b>GLUCOSE</b> <i>Glucose oxidase Peroxidase/Benedict's test</i>	NIL	NIL	
<b><u>MICROSCOPIC EXAMINATION</u></b>			
<b>PUS CELLS</b>	2-3	0 - 5 /hpf	
<b>EPITHELIAL CELLS</b>	3-5	0 - 5	hpf
<b>RBC</b>	NIL	0 - 5 /hpf	
<b>CRYSTALS</b>	NIL	NIL	

*UAR*

**DR. URMILA AJAY ROTTE**  
CONSULTANT PATHOLOGIST, MBBS,  
DIPLOMA IN PATHOLOGY



**LABORATORY REPORT : CLINICAL PATHOLOGY**

<b>Name</b>	: Ms. PRACHI PRATIK YEOTIKAR	<b>Age /Sex</b>	: 32Y Y(s)/FEMALE
<b>Bill Date</b>	: 09-Nov-2024 09:55 AM	<b>UMR No.</b>	: 702411000718
<b>Rec. Dt</b>	: 09-Nov-2024 10:28 AM	<b>Bill No.</b>	: MCB70241102753
<b>Rept. Dt</b>	: 09-Nov-2024 11:31 AM	<b>Result No</b>	: RUR241109973
<b>Ref By</b>	: Dr. Ananddeep Agarwal	<b>Sample ID</b>	: MCHAU4047307
<b>Sample Type</b>	: URINE		

CASTS

NIL

NIL

\*\*\* End Of Report \*\*\*



DR. URMILA AJAY ROTTE  
CONSULTANT PATHOLOGIST, MBBS,  
DIPLOMA IN PATHOLOGY



**LABORATORY REPORT : HAEMATOLOGY**

<b>Name</b>	: Ms. PRACHI PRATIK YEOTIKAR	<b>Age /Sex</b>	: 32Y Y(s)/FEMALE
<b>Bill Date</b>	: 09-Nov-2024 09:55 AM	<b>UMR No.</b>	: 702411000718
<b>Rec. Dt</b>	: 09-Nov-2024 10:28 AM	<b>Bill No.</b>	: MCB70241102753
<b>Rept. Dt</b>	: 09-Nov-2024 11:39 AM	<b>Result No</b>	: RUR241109963
<b>Ref By</b>	: Dr. Ananddeep Agarwal	<b>Sample ID</b>	: MCHAU4047303
<b>Sample Type</b>	: WHOLE BLOOD		

**CBP(COMPLETE BLOOD PICTURE)**

<u>Parameters</u>	<u>Result</u>	<u>Reference Range</u>	<u>Units</u>
<b>HEMOGLOBIN</b> <i>Photometric</i>	11.0 *	12.0 - 15.0	gms/dL
<b>R B C COUNT</b> <i>Electrical Impedance</i>	4.93 *	3.8 - 4.8 10 <sup>12</sup> /L	10 <sup>12</sup> /L
<b>PCV/HCT</b> <i>Calculated</i>	35.2 *	36 - 46	%
<b>MCV</b> <i>Calculated</i>	71 *	83 - 101	fl
<b>MCH</b> <i>Calculated</i>	22.3 *	27 - 32	pg
<b>MCHC</b> <i>Calculated</i>	31.3	31 - 37	g/dL
<b>TLC (TOTAL LEUCOCYTE COUNT)</b> <i>Impedance</i>	6.9	4.0 - 10.0	10 <sup>3</sup> /μl
<b>DIFFERENTIAL COUNT</b>			
<b>NEUTROPHILS</b> <i>DHSS/Microscopy</i>	47.0	40 - 80 %	
<b>LYMPHOCYTES</b> <i>DHSS/Microscopy</i>	42.8 *	20 - 40 %	
<b>MONOCYTES</b> <i>DHSS/Microscopy</i>	6.4	02 - 10 %	

*UAR*

DR. URMILA AJAY ROTTE  
CONSULTANT PATHOLOGIST, MBBS,  
DIPLOMA IN PATHOLOGY



**LABORATORY REPORT : HAEMATOLOGY**

<b>Name</b>	: Ms. PRACHI PRATIK YEOTIKAR	<b>Age /Sex</b>	: 32Y Y(s)/FEMALE
<b>Bill Date</b>	: 09-Nov-2024 09:55 AM	<b>UMR No.</b>	: 702411000718
<b>Rec. Dt</b>	: 09-Nov-2024 10:28 AM	<b>Bill No.</b>	: MCB70241102753
<b>Rept. Dt</b>	: 09-Nov-2024 11:39 AM	<b>Result No</b>	: RUR241109963
<b>Ref By</b>	: Dr. Ananddeep Agarwal	<b>Sample ID</b>	: MCHAU4047303
<b>Sample Type</b>	: WHOLE BLOOD		

**EOSINOPHILS**

*DHSS/Microscopy*

3.7

00 - 06 %

**BASOPHILS**

*DHSS/Microscopy*

0.1

00 - 01 %

**PLATELET COUNT**

*Electrical Impedance*

404 \*

150 - 400 10<sup>3</sup>/μL

10<sup>3</sup>/μL

\*\*\* End Of Report \*\*\*



DR. URMILA AJAY ROTTE  
CONSULTANT PATHOLOGIST, MBBS,  
DIPLOMA IN PATHOLOGY



**LABORATORY REPORT : HAEMATOLOGY**

<b>Name</b>	: Ms. PRACHI PRATIK YEOTIKAR	<b>Age /Sex</b>	: 32Y Y(s)/FEMALE
<b>Bill Date</b>	: 09-Nov-2024 09:55 AM	<b>UMR No.</b>	: 702411000718
<b>Rec. Dt</b>	: 09-Nov-2024 10:28 AM	<b>Bill No.</b>	: MCB70241102753
<b>Rept. Dt</b>	: 09-Nov-2024 11:54 AM	<b>Result No</b>	: RUR241109975
<b>Ref By</b>	: Dr. Anandeeep Agarwal	<b>Sample ID</b>	: MCHAU4047309
<b>Sample Type</b>	: WHOLE BLOOD		

<u>Parameters</u>	<u>Result</u>	<u>ESR</u> <u>Reference Range</u>	<u>Units</u>
<b>ESR</b> MODIFIED WESTERGRENS METHOD	12	0 - 20	mm/1st hour

\*\*\* End Of Report \*\*\*



DR. Suwarna Rahul Jawale  
CONSULTANT PATHOLOGIST, MBBS,  
DNB

# MEDICOVER HOSPITAL

Near Chistiya Colony , Police Chowki, N-6 Cidco ,  
Chhatrapati Sambhajnagar - 431001  
Email\_ID: info@medicoverhospitals.in

Name: Mrs. PRACHI YEOTIKAR  
Age: 32 Y  
Sex: F  
Date: 09-Nov-2024

Ref By: Dr. ANANDEEP AGRAWAL  
Study: 2D ECHO  
Examined By: Dr. ANKUSH KOLHE  
Hospital ID: UMR0718

## ECHOCARDIOGRAPHY REPORT

### MEASUREMENTS

Aorta	27mm	LA	30mm
IVSed	07mm	PWed	08mm
LV ed	39mm	LVes	21mm
LVEF	60 %	IVC	12 mm, collapsing

IVS Motion - NORMAL

### CHAMBERS

LV            NORMAL CHAMBER DIMENSIONS  
                  RWMA- ABSENT  
                  DIASTOLIC DYSFUNCTION - ABSENT  
LA            NORMAL  
RA            NORMAL  
RV            NORMAL

### MITRAL VALVE

Morphology            NORMAL  
Mitral Stenosis -        ABSENT  
Mitral Regurgitation - ABSENT

### TRICUSPID VALVE

Morphology            NORMAL  
Doppler                TRIVIAL TR, RVSP- 26mm of Hg

### PULMONARY VALVE

Morphology            NORMAL  
Doppler                NORMAL

### AORTIC VALVE

Morphology            NORMAL  
Doppler                NORMAL

AORTA-Normal / No-CoA/ dissection

IAS/ IVS - Intact

NO CLOT/VEGETATION/PERICARDIAL EFFUSION

### FINAL IMPRESSION-

- NORMAL CHAMBER DIMENSIONS
- NO RESTING RWMA, LVEF - 60%
- NO LV DIASTOLIC DYSFUNCTION
- NO PULMONARY HYPERTENSION

  
DR ANKUSH KOLHE  
MBBS/FCPS/DIP. PRE.MED/DIP CARD(PGDCC)  
REG-2007-07-3028

DR. KULDEEP R TOTAWAR  
MD,DM CARDIOLOGIST  
REG. NO.-MMC 2014-06-2848

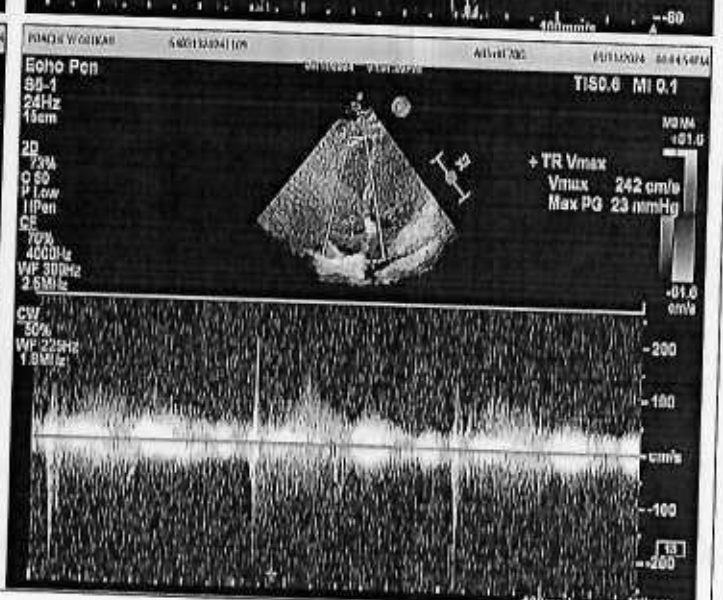
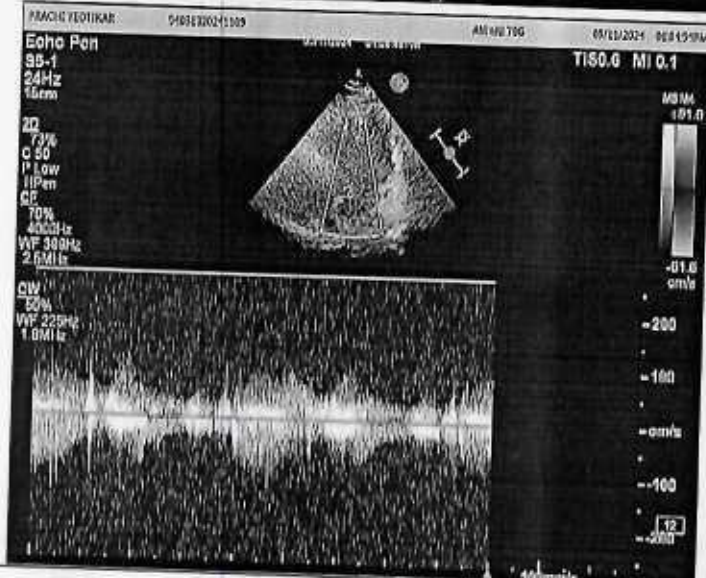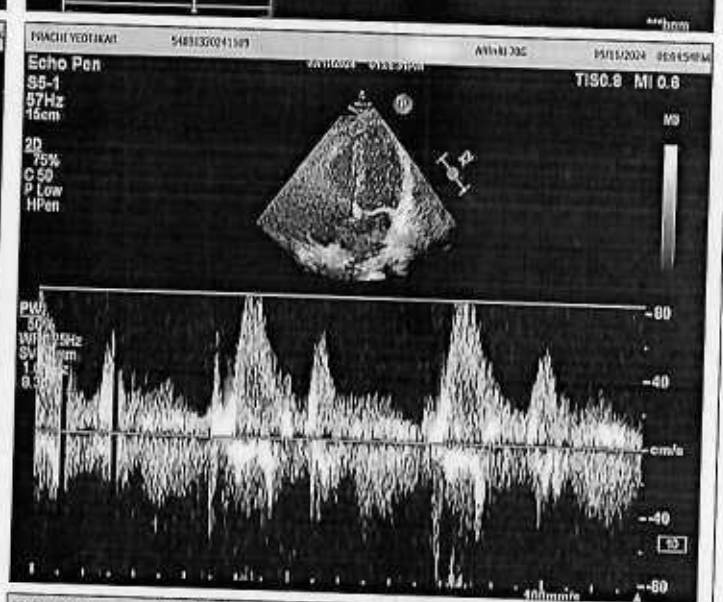
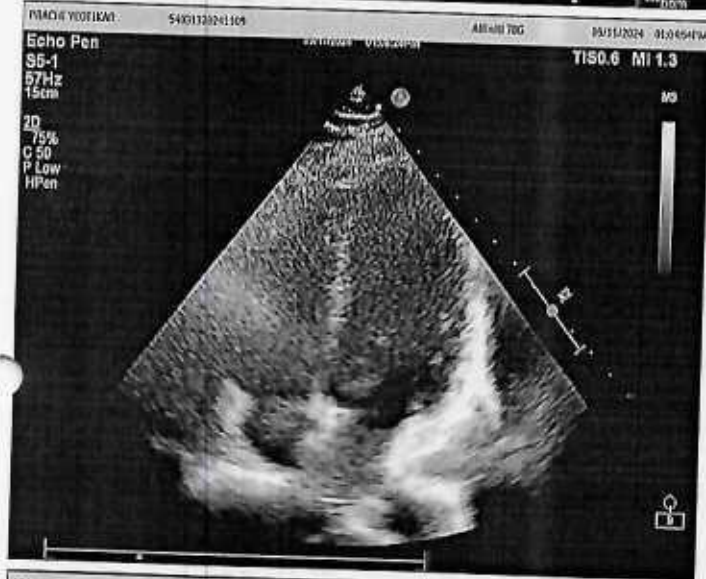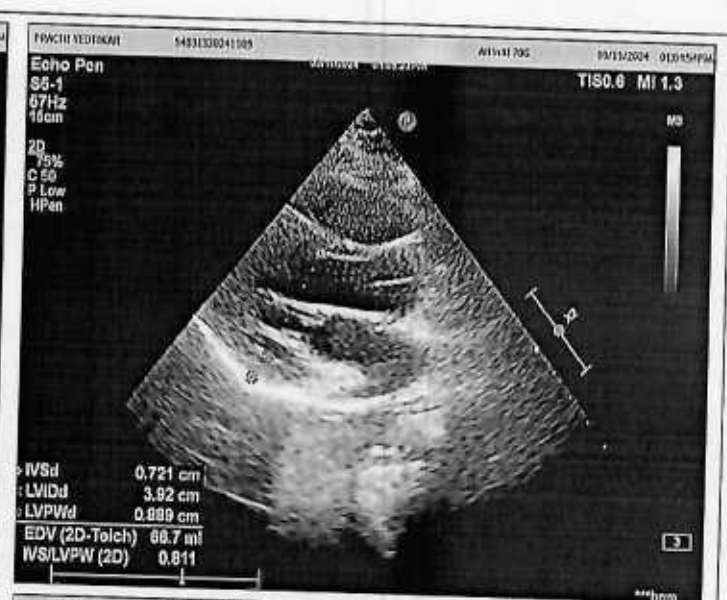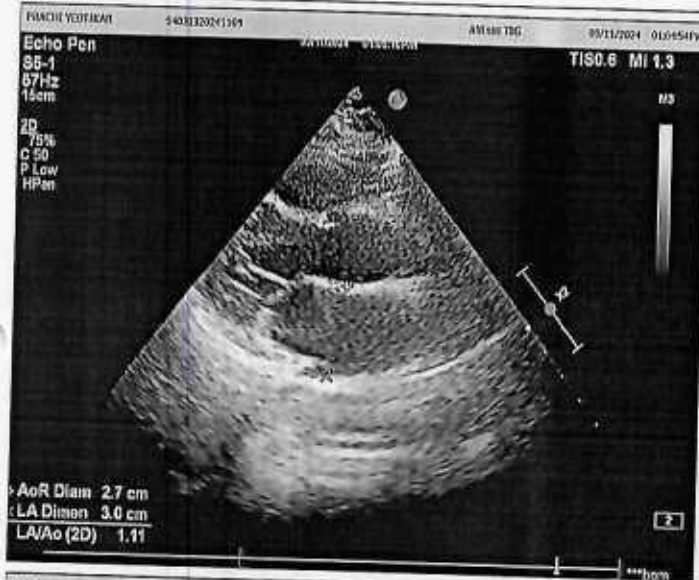


# MEDICOVER HOSPITAL

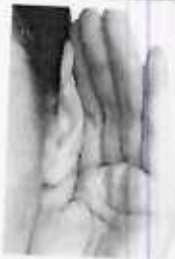Near Chistiya Colony, Police Chowki, N-6 Cidco,  
Chhatrapati Sambhajnagar - 431001  
Email\_ID: info@medicoverhospitals.in

Name: Mrs. PRACHI YEOTIKAR  
Age: 32 Y  
Sex: F  
Date: 09-Nov-2024

Ref By: Dr. ANANDEEP AGRAWAL  
Study: 2D ECHO  
Examined By: Dr. ANKUSH KOLHE  
Hospital ID: UMR0718



# AADHAR SPEECH THERAPY & HEARING CLIN



All type of Hearing Aid Machine Available Hear.

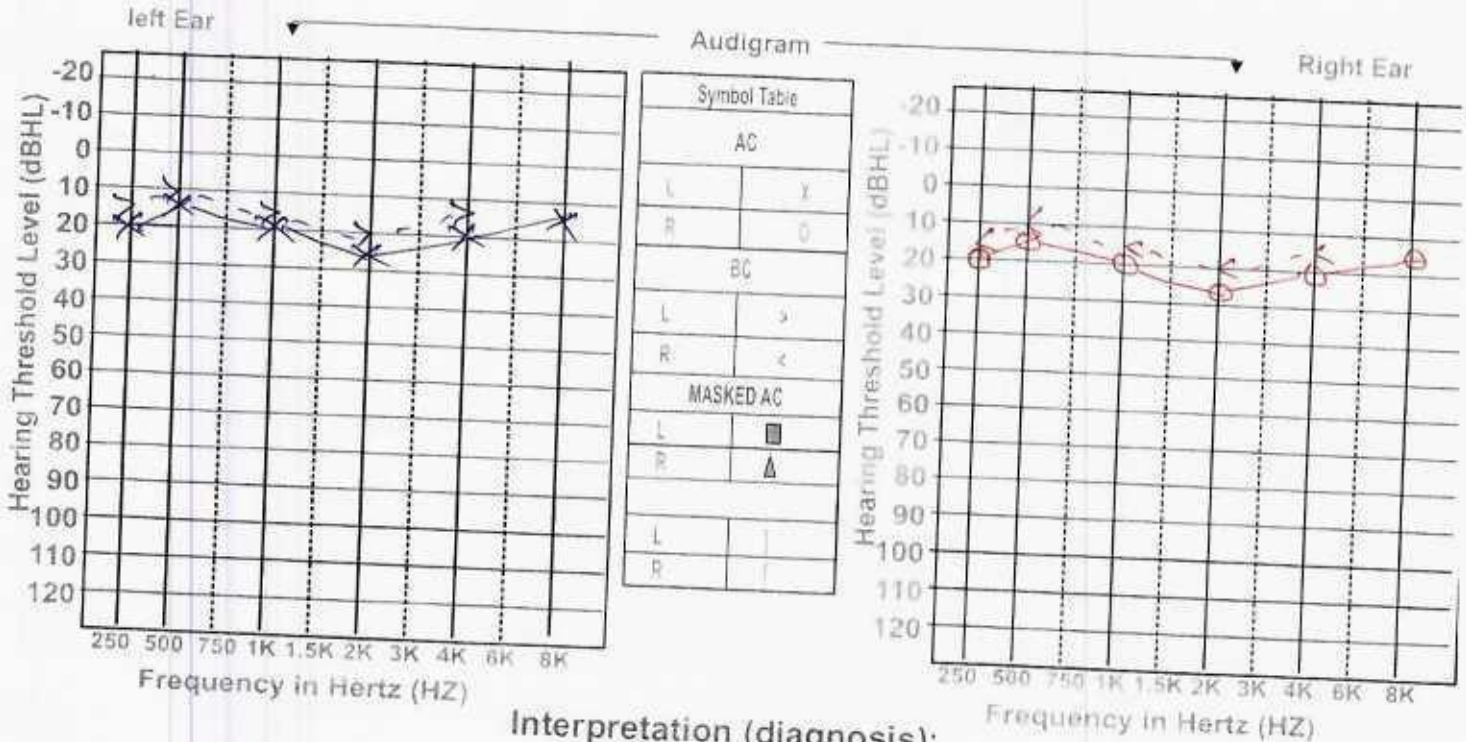
Mo : 8380840048 / 8380847568



## Audiological Evaluation Sheet

Name : prachi yeotikar. Age 32 Gender F  
 Date : 09/11/24 Tested By PTA. E Code         

Brief Case History / Complaint :



Interpretation (diagnosis):


Right ear : bilateral - Normal hearing sensitivity.  
 Left ear :         

Otосcopy Findings : Right Ear  Left Ear   
 Responses : Reliable  Fairly Reliable  Not Reliable   
 Test Condition : Satisfactory  Not Satisfactory   
 Procedure : Standard  Play

Audiometer: Mycen - 5000A!

### Speech Audiometry

Test →	PTA	SAT	SRT	WRS	MCL	UCL
Ear ↓	dBHL	DBHL	dBHL	%	dBHL	dBHL
Right						
Left						

  
 Audiologist / Speech Therapist  
 RCI-No B53593  
 E-mail ID : arunrathod0048@gmail.com

**Arun Rathod**

**Add : Near Aamdar Amruttulya, Opp.SBI Bank Sevalal Chowk Hanuman Nagar, N-4 Cidco Aurangabad.**



4-2022-0871  
June 10, 2022 - June 10, 2028

Patient ID:	UMR702411000718	Patient Name:	PRACHI YEOTIKAR
Age:	32 Years	Sex:	F
Referring Physician:	DR.A.AGARWAL	Modality:	CR
Study Date:	09-Nov-2024	Study:	Chest

### X-RAY CHEST PA VIEW

Both lung fields appears normal  
Both C.P.angles appears normal.  
Both hilar shadows normal.  
Mediastinal silhouette appears normal.  
Both domes of diaphragm, bony cage and soft tissue appears normal

**Imp : No significant abnormality detected.**

**DR. ABHISHEK BUJADE**  
**MD RADIOLOGY**  
**(CONSULTANT RADIOLOGIST)**

For Appointment Please Contact - 040 - 6833 4455

📍 Near Chistiya Police Chowk, N-6, Cidco,  
Chhatrapati Sambhajnagar - 431003.

🌐 [www.medicoverhospitals.in](http://www.medicoverhospitals.in)  
@ [info@medicoverhospitals.in](mailto:info@medicoverhospitals.in)

**For Reports Only**

**Dr. Jankidevi Swaroop Borade**  
MBBS, MS, OBGY (Mumbai)  
DIP. Reproductive Medicine (Germany)  
Obsterics & Gynaecology  
Infertility Specialist  
Reg.No. 2010/05/1864  
Mob. : +91 7028796546



**MEDICOVER**  
HOSPITALS

A UNIT OF SAHRUDAYA HEALTHCARE PVT LTD

Prachi Vaidya

9/11/24

- 3yr 10m1 health check up
- on complaint
- hb: 25/10/24.

Abh  
Kapoor

For Appointment Please Contact - 0240 - 6661111

A UNIT OF SAHRUDAYA HEALTHCARE PVT LTD.

Medicover Hospital, Near Chistiya Police Chowki, N-6, Cidco, Chhatrapati Sambhajanagar - 431003.

24x7 HELPLINE- 040 6833 4455



H-2022-0977  
June 16, 2022 - June 15, 2026



**MEDICOVER**  
HOSPITALS

A Unit of Sahrudaya Health Care Private Limited

<b>NAME:</b>	PRACHI YEOTIKAR	<b>SEX:</b>	32YRS /F
<b>REF BY:</b>	DR. A. AGARWAL	<b>DATE:</b>	09/11/2024
<b>UMR NO :</b>	702411000718		

June 16, 2022 - June 15, 2026

### USG ABDOMEN AND PELVIS

**Liver:** Size is normal. Shows bright echotexture s/o grade – I fatty changes. No focal lesion seen.

Intrahepatic portal and biliary radicals appear normal. Portal vein and CBD normal.

**Gall Bladder :** Physiologically distended. Wall thickness normal. No calculus seen.

**Pancreas:** Visualized head and body appears normal.

**Spleen :** Size is normal. Shape and parenchymal echotexture normal. S.V. normal.

**RT. Kidney:** Size 9.6 x 4.1 cms, normal.

Parenchymal echotexture, corticomedullary differentiation normal.

Pelvicalyceal system appears normal. No calculus seen.

**LT. Kidney:** Size 9.6 x 4.0 cms, normal.

Parenchymal echotexture, corticomedullary differentiation normal.

Pelvicalyceal system appears normal. No calculus seen.

**Urinary Bladder:** Distended, wall thickness normal. No calculus seen.

**Uterus :** Anteverted measuring normal.

Normal in myometrial echotexture. No focal lesion seen.

**Endometrium:** Central, measuring 7.0 mm. No focal lesion.

**Ovaries:** Both ovaries normal. No adenexal mass seen.

No e/o free fluid in POUCH OF DOUGLUS.

**Bowel loops:** Normal. Peristalsis normal. No e/o free fluid in abdomen / pelvis.

No e/o Pre/Para aortic lymphadenopathy. Aorta and IVC appear grossly normal.

### IMPRESSION :

- Grade – I fatty changes in liver.
- No other significant abnormality detected.

**DR. ABHISHEK BUJADE**  
**MD RADIOLOGY**

**(CONSULTANT RADIOLOGIST)**

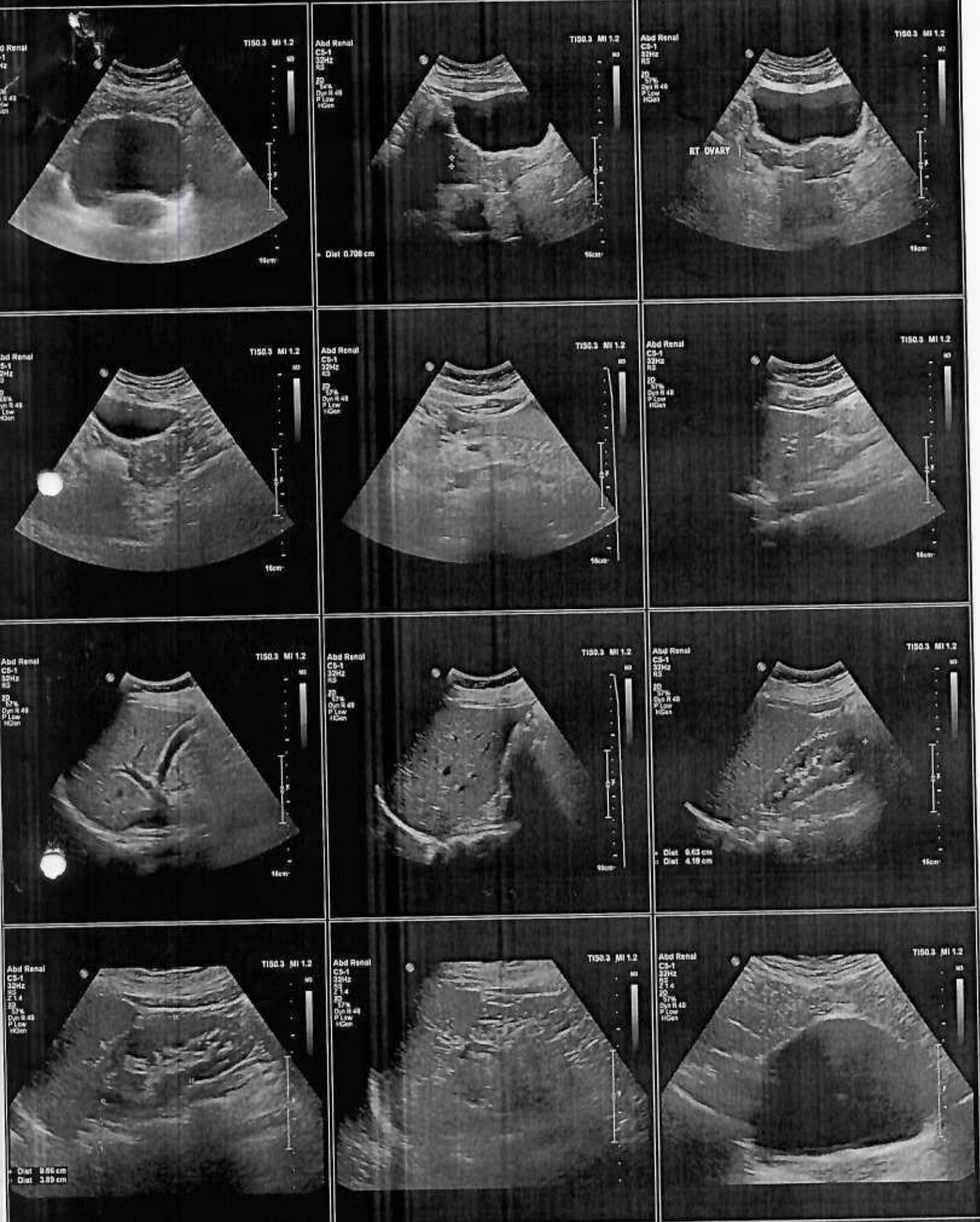For Appointment Please Contact - 040 - 6833 4455

📍 Near Chistiya Police Chowk, N-6, Cidco,  
Chhatrapati Sambhajanagar - 431003.

🌐 [www.medicoverhospital](http://www.medicoverhospital)

@ [Info@medicoverhospital.in](mailto:Info@medicoverhospital.in)

For Reports Only





H-2022-0977  
June 16, 2022 - June 15, 2026



**MEDICOVER**  
HOSPITALS  
A Unit of Sahrudaya Health Care Private Limited

Ms. Prachi Pratik Yeotikar

Age. 32 Y / F.

Vn { 6/60 P  
6/60 P

RE

LE

Dist - 5.575 - 2.00 x 180. - 6.75 - 2.00 x 180.

Near. { NG  
NG

colom - Normal

For Appointment Please Contact - 040 - 6833 4455  
Near Chistiya Police Chowk, N-6, Cidco,  
Chhatrapati Sambhajnagar - 431003.

For Reports Only

www.medicoverhospital  
@ Info@medicoverhospital.in

ID: 0718  
Name: PRACHI YEOTIKAR  
Age: Female  
Gender: Female

09-11-2024 10:51:30 AM

Rate 76 bpm  
PR Interval 148 ms  
QRS Duration 80 ms  
QT/QTc Interval 372/400 ms  
P/QRS/T Axes 61/95/18 deg  
QTc Hedges

Sinus rhythm  
--- Interpretation made without knowing patient's age ---  
Possible anterior infarct - age undetermined  
Abnormal ECG

Unconfirmed Diagnosis:

