



दिवाकर डायग्नोस्टिक सेंटर

E-7/636, पंजाब नेशनल बैंक के पास, मैन रोड, अरेरा कॉलोनी भोपाल (म.प्र.)

फोन: 0755-2465288, 0755-3520545 मो: 9826340190


Pt.Name :-	Mrs. Adya Goswami
Age :-	33y/F
Refd. By :-	BOB
Lab.pNo.:-	290
Date :-	30/07/2022

EXAMINATION OF BLOOD

TEST	RESULT	NORMAL VALUE
Haemoglobin	11.4mgs%	Female 12-16gms%, Male 14-18gms%
Red Cell count	4.7	4.5-5.6 million /cumm
Platelet Count	2.65	1.5-5.6 Lac/cumm
Leucocytes per.cu.mm	7600/cumm	5000-11000/cumm
Neutrophils	55%	50-70%
Lymphocytes	39%	20-40%
Eosinophils	04%	0-7%
Monocytes	02%	2-8%
PCV	36.2	37-47
MCV	75.6	76-96
MCH	23.7	27-32
MCHC	31.4	31-35
ESR	12	Male 0-9, Female 0-20mm/FHR
Blood Group	"O" Positive	
S.Bilirubin(Total)	0.74	0.2-1.0mg/dl
Direct	0.32	0.0-0.25mg/dl
Indirect	0.42	
SGOT	18.9	5-35U/L
SGPT	22.0	8-40U/L
Alk Phosphatase	7.3	3-13 KA units
S. Protein(Total)	6.7	6.0-8.0mg%
Albumin	3.8	3.7-5.3mg%
Globulin	3.2	1.5 to 3.5 mg%
AG Ratio	1.20	1-2.0
Blood Urea Nitrogen (BUN)	11.1	7-20 mg/dl
S.Creatine	0.68	0.5-1.4mg/dl
Uric Acid	5.4	4.8 to 7.5 mg/dl
Calcium	8.2	8.5-10.5 gm/dl
GGTP	28.0	5-35 UL/dl
Fasting Blood Sugar	72.8	70 to 110mg/dl
Post Prandial Blood Sugar	128.2	Up to 150mg/dl
Total Serum Cholesterol	162.1	100-250 mg%
Serum Triglyceride	182.0	Up to 160 mg%
Serum Cholesterol HDL	40.1	Up to 65 mg%
Serum Cholesterol LDL	85.6	Up to 125 mg%
VLDL	36.4	Up to 30 mg%
TC/HDL Ratio	3.35	Bellow 5
Glycosylated Hemoglobin HBA1c	5.3	Below - 6.0 % -Non Diabetic control 6-7 % -Excellent control Above- 8 % -Poor control

Pathologist

All test have technical limitation. Collaborative clinic pathological interpretation is mandatory. In case of disparity test may be repeated immediately. Typographical mistakes should be get correct instantly. This report is not valid for medical legal purpose.



Dr. B. M. Agarwal
MBBS, DCP
Consultant Pathologist



दिवाकर डायग्नोस्टिक सेंटर

E-7/636, पंजाब नेशनल बैंक के पास, मैन रोड, अरेा कॉलोनी भोपाल (म.प्र.)

फोन: 0755-2465288, 0755-3520545 मो: 9826340190

Pt.Name :-	Mrs. Adya Goswami
Age :-	33y/F
Refd. By :-	BOB
Lab.pNo.:-	290
Date :-	30/07/2022

URINE ANALYSIS

<u>A. PHYSICALEXAMINATION</u>		<u>C. MICROSCOPIEXAMINATION</u>	
1. Colour	Yellow	Pus Cells	3-4/HPF
2. Appearance	Clear	R.B.C.	Nil
3. Specific Gravity	Q.N.S.	Epithelial Cell	occ/HPF
<u>B. CHEMICAL EXAMINATION</u>		Cast	Nil
1.Reaction	Acidic	Crystals(Cal.Oxa)	Nil
2.Albumin	Absent	Bacteria	Nil
3.Sugar	Nil	Amorphous	Nil
4.Bile Salts	Absent	T. Vaginitis	Nil

URINE COTININE	Negative	By Card method
----------------	----------	----------------



Dr. B. M. Agarwal
MBBS, DCP
Consultant Pathologist

All test have technical limitation. Collaborative clinic pathological interpretation is mandatory. In case of disparity test may be repeated immediately. Typographic mistakes should be get correct instantly. This report is not valid for medico legal purpose



दिवाकर डायग्नोस्टिक सेंटर

E-7/636, पंजाब नेशनल बैंक के पास, मैन रोड, अरेा कॉलोनी भोपाल (म.प्र.)

फोन: 0755-2465288, 0755-3520545 मो: 9826340190

Pt.Name :-	Mrs. Adya Goswami
Age :-	33y/F
Refd. By :-	BOB
Lab.pNo.:-	290
Date :-	30/07/2022

EXAMINATION OF BLOOD

Thyroid profile


<u>TEST</u>	<u>RESULT</u>	<u>NORMAL VALUE</u>
T3 - TOTAL	116.8	82-213 ng/dL
T4 - TOTAL	8.39	6.09-12.23 ug/dL
THYROID STIMULATING HORMONE (TSH)	3.88	0.45-4.25 ul/mL

Interpretation:

TSH Levels will be elevated in primary hypothyroidism, TSH levels will be low in Hyperthyroidism there is decreased production of thyroid hormones by the thyroid hence the person may experience symptoms such as weight gain, constipation, cold intolerance and fatigue. Iodine deficiency and Hashimoto

thyroiditis is the most common cause of hypothyroidism It makes Thyroid stimulating hormone. If TSH levels are abnormally high it could mean you have an underactive thyroid or hypothyroidism.




Dr. B. M. Agarwal
MBBS, DCP
Consultant Pathologist

All test have technical limitation. Collaborative clinic pathological interpretation is mandatory. In case of disparity test may be repeated immediately. Typographic mistakes should be get correct instantly. This report is not valid for medico legal purpose



द्विवाकर डायग्नोस्टिक सेंटर

E-7/636, पंजाब नेशनल बैंक के पास, मैन रोड, अरेरा कॉलोनी भोपाल (म.प्र.)

फोन: 0755-2465288, 0755-3520545 मो: 9826340190

Pt.Name :-	Mrs. Adya Goswami
Age :-	33y/F
Refd. By :-	BOB
Lab.pNo.:-	290
Date :-	30/07/2022
Skigram	X Ray Chest PA View
Radiologist	Dr. B.M.Agarwal MD (Radiology)

REPORT

Tricia Central

Thoracic cage normal

Both Lungs Field Clear.

Both hilers normal

Cardiac border normal

Both cp angles clear

Both domes and diaphragm normal

IMPRESSION

-NO CARDIO PULMONARY PATHOLOGY

-COORELATE WITH CLINICAL FINDINGS.


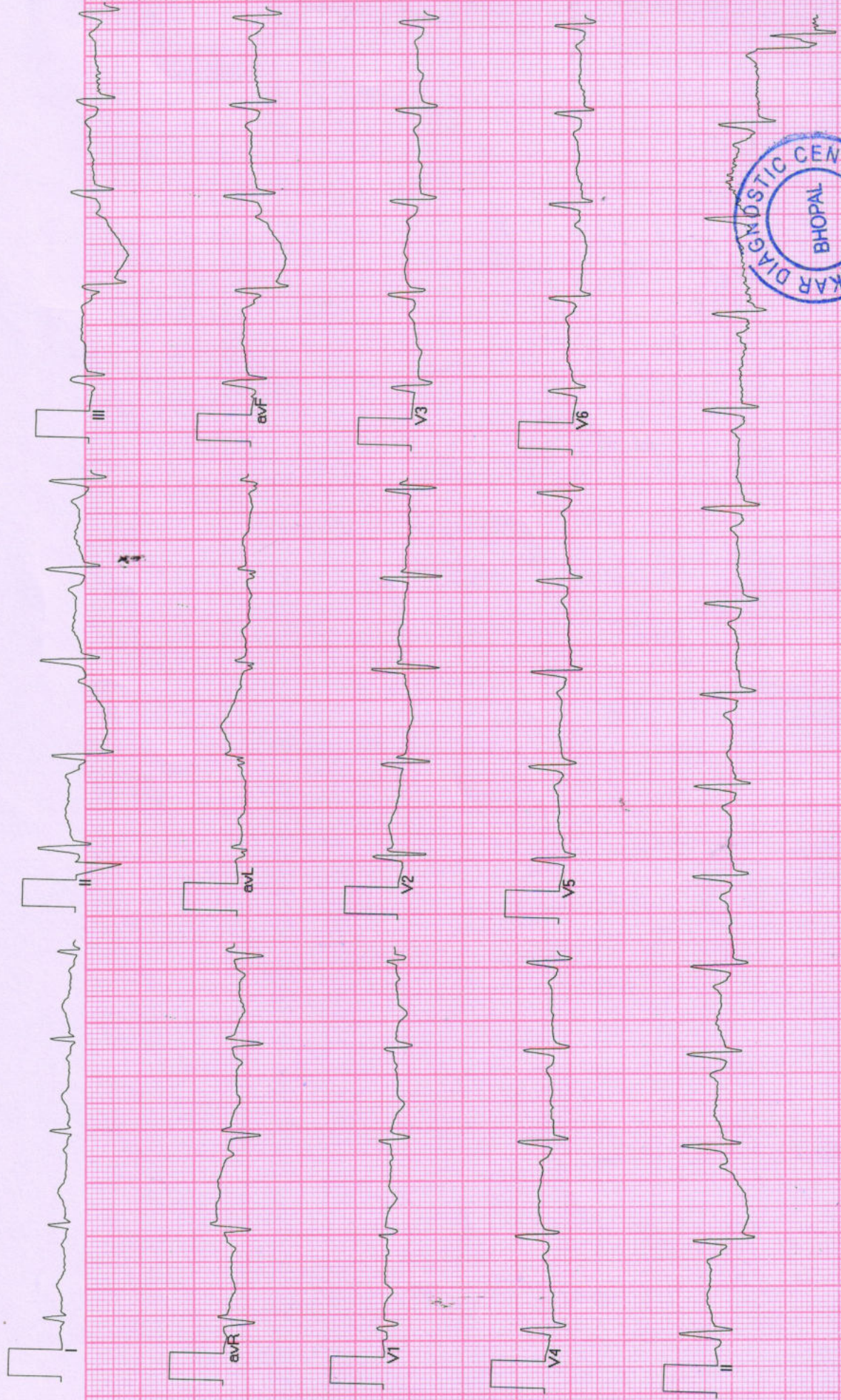


Dr. B. M. Agarwal
MD, Radiology
Consultant Radiologist
Radiologist

Allengers Global Healthcare Pvt Ltd.

145 / MRS. ADYA GOSWAMI / 33 Yrs / F / 165Cms. / 85Kgs.
Heart Rate : 86 bpm / Tested On : 30-Jul-22 09:34:05 / HF 0.05 Hz - LF 100 Hz / Notch 50 Hz / Sn 1.00 Cm/mV / Sw 25 mm/s
/ Refd By.: BOB

ECG



Allengers ECG (Piscas)(PIS213180317)

[Handwritten signature]



डॉ. सविता क्लिनिक

34, भूतल, मोहिनी अदिति आर्केड, शाहपुरा मस्जिद के पास
भरत नगर रोड, ई-7/194, अरेरा कॉलोनी, भोपाल - 462038

Mob. : 8989649694, 9516333619

Clinic Registration : CL/5392/Jun/2017

PNDT Registration : MPPCPNDT/BPL/2017/206



Name : Mrs. ADYA Age 33 YRS./F

R/B Health check up Date 20/7/22

WHOLE ABDOMES ULTRASOUND REPORT

Indication:

Liver appears normal in size and shape with normal outline. Normal/
increased perenchymal echogenicity is noted. No E/O focal lesion/ IHBR
dilatation is sen. Hepatic veins and portal veins appear normal.

No E/O subdiaphragmatic Collection.

Gall Blader is physiologically well distended. No. E/O echogenic foci in GB
lumen. GB wall is normal / thickened. No E/O pericholecystic collection.
Common duct reveals normal course and caliber.

Pancreas appear normal in size, shape and echo texture with smooth
contour. No peripancreatic pathology seen. (~~Not seen due to gases~~)

Spleen is normal in size and echo texture.

IVC and aorta appear to be normal.

No evidence of lymphadenopathy is noted.

No evidence of free fluid is noted.

Right Kidney is normal in size. size, shape and position. Corticomedullary
defferentiation (CMD) is well maintained. Normal cortical thickness is
noted. No E/O hydronephrosis or calculus is noted.

PTO

Dr. P. Savita, MD

MBBS, MD (O&G) Reg. No. 9971

स्त्री रोग विशेषज्ञ

Dr. Jayant Yadav

MBBS, MD (Radiology)

रेडियोलॉजिस्ट

Left Kidney is normal in size, shape and position. CMD is well maintained. Normal cortical thickness is noted. No E/O hydronephrosis or calculus is noted.

Urinary Bladder is well distended (physiological). its contents are echo free. No E/O bladder wall thickening is noted. ~~Post-void residue is insignificant.~~

Prostate is normal in size. Shape and echo texture with smooth outline. No E/O focal lesion is noted.

Uterus is ante/ ~~retro~~ verted and normal in size, shape and echotexture with smooth outline. No E/O focal lesion is noted. Endometrial echo appear normal. Cervical and vaginal shadows appear normal.

Right Ovary appears ~~enlarged~~ / Normal in size, shape and echo texture.

Left Ovary appears ~~enlarged~~ / Normal in size, shape and echo texture.

Impression : Normal study.

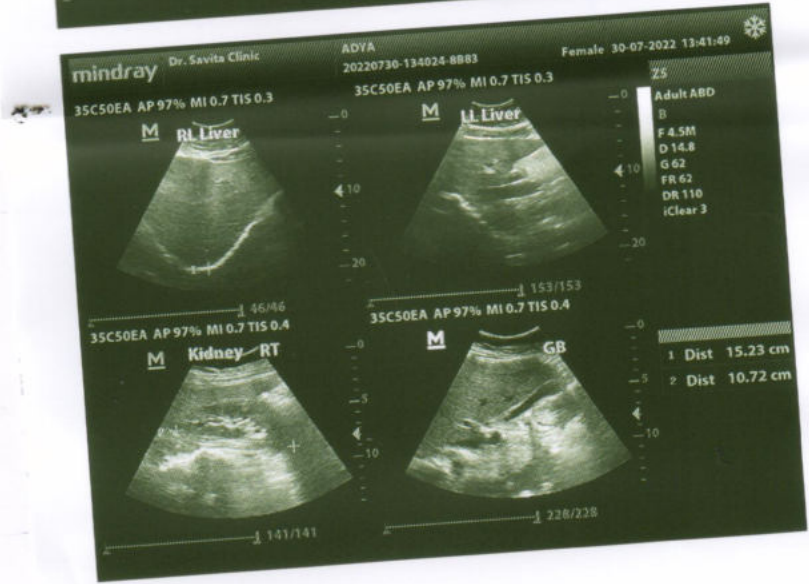
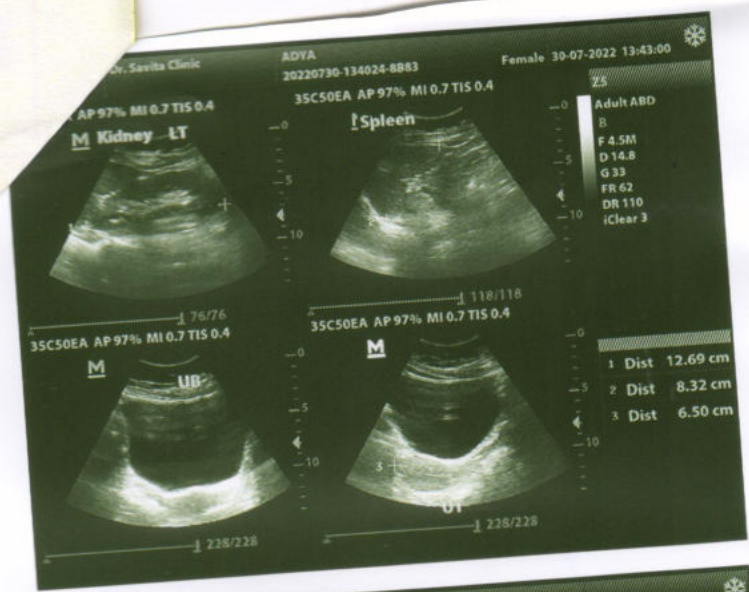
Advised clinical Correlation.

Jayant

Dr. P. Savita, MD
MBBS, MD (O&G) Reg. No. 9971
स्त्री रोग विशेषज्ञ

Dr. Jayant Yadav, MD
MBBS, MD (Radiologist) Reg. No. 4166
रेडियोलॉजिस्ट

phrosis or calculus is
ID is well maintained.




सत्यमेव जयते

भारत निर्वाचन आयोग
पहचान पत्र
ELECTION COMMISSION OF INDIA
IDENTITY CARD

NMU1278241



निर्वाचक का नाम : आद्या गोस्वामी
ELECTOR'S NAME : ADYA GOSVAMI
पिता का नाम : एम एम गोस्वामी
FATHER'S NAME : M M GOSVAMI
लिंग / SEX : महिला / FEMALE
जन्म की तारीख / DATE OF BIRTH : 07/05/1989

Adya



Dr. B. M. Agarwal
MBBS, DCP
Consultant Pathologist

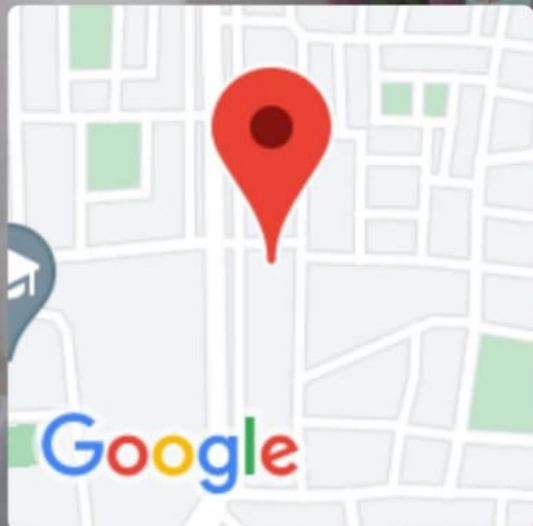


Diwakar Diagnostic Centre

पेथोलोजी | एक्स-रे | ई.सी.जी. | एको कार्डियो ग्राफी | सोनोग्राफी



GPS Map Camera



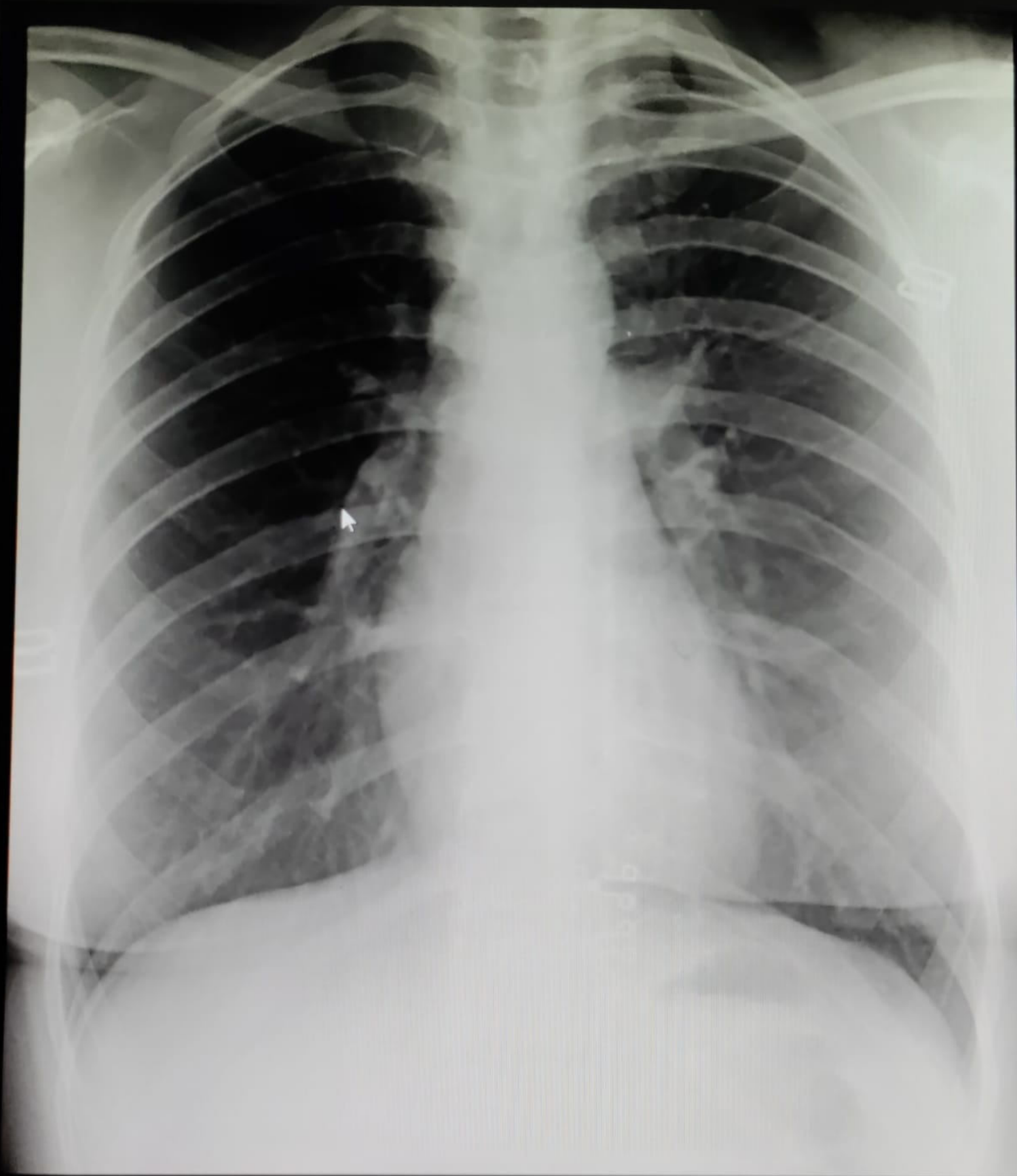
Bhopal, Madhya Pradesh, India

6C4J+8PP, E-7, Arera Colony, Bhopal, Madhya Pradesh
462016, India

Lat 23.205766°

Long 77.431745°

30/07/22 10:19 AM



**MRS ADTA GOSVAMI 1223 CHEST,FRN P->A 30-JULY-22
DIWAKAR DIAGNOSTIC CENTRE , ARERA COLONY ,BHOPAL**



Report :

TEST OBJECTIVE : ROUTINE CHECK UP
RISK FACTOR : FEMALE
ACTIVITY : MODERATE ACTIVE
OTHER INVESTIGATION : ROUTINE BLOOD INVESTIGATION, USG, XRAY
REASON FOR TERMINATION : FATIGUE, HEART RATE ACHIEVED
EXERCISE TOLERANCE : AVERAGE
EXERCISE INDUCED ARRHYTHMIAS : NO
HAEMODYNAMIC RESPONSE : NORMAL
CHRONOTROPIC RESPONSE : NORMAL
FINAL IMPRESSION : STRESS TEST IS NEGATIVE FOR EXERCISE INDUCED ISCHAEMIC HEART DISEASE



Doctor : Cardiologist



Stage	Time	Duration	Belt Speed (mph)	Elevation	METS	Rate	% THR Achieved	BP	RPP	PVC	Comments
Supine	00:09	0:01	00.0	00.0	01.0	86	46 %	120/80	103	00	
Standing	00:14	0:01	00.0	00.0	01.0	86	46 %	120/80	103	00	
HV	00:25	0:01	00.0	00.0	01.0	106	57 %	120/80	127	00	
Warm Up	00:29	0:01	01.0	00.0	01.0	109	58 %	120/80	130	00	
ExStart	00:34	0:06	01.7	10.0	01.1	103	55 %	120/80	123	00	
BRUCE Stage 1	03:34	3:00	01.7	10.0	04.7	141	75 %	130/80	183	00	
BRUCE Stage 2	06:34	3:00	02.5	12.0	07.1	165	88 %	140/90	231	00	
PeakEx	06:53	0:19	03.4	14.0	07.4	169	90 %	140/90	236	00	
Recovery	07:52	1:00	00.0	00.0	01.2	128	68 %	136/86	174	00	
Recovery	08:52	2:00	00.0	00.0	01.0	099	53 %	130/80	128	00	
Recovery	08:58	2:05	00.0	00.0	01.0	099	53 %	130/80	128	00	

Findings :

- Exercise Time : 06:20
- Max HR Attained : 169 bpm 90% of Target 187
- Max BP Attained : (Sys) 140/90
- Max Workload Attained : 7.4 Fair response to induced stress
- Test End Reasons : Fatigue, Heart Rate Acheived

Doctor : Cardiologist

689 / MRS. ADYA GOSWAMI / 33 YRS / F / 165 Cms / 85 Kg / HR : 86

Date: 30-Jul-2022 09:35:11 AM

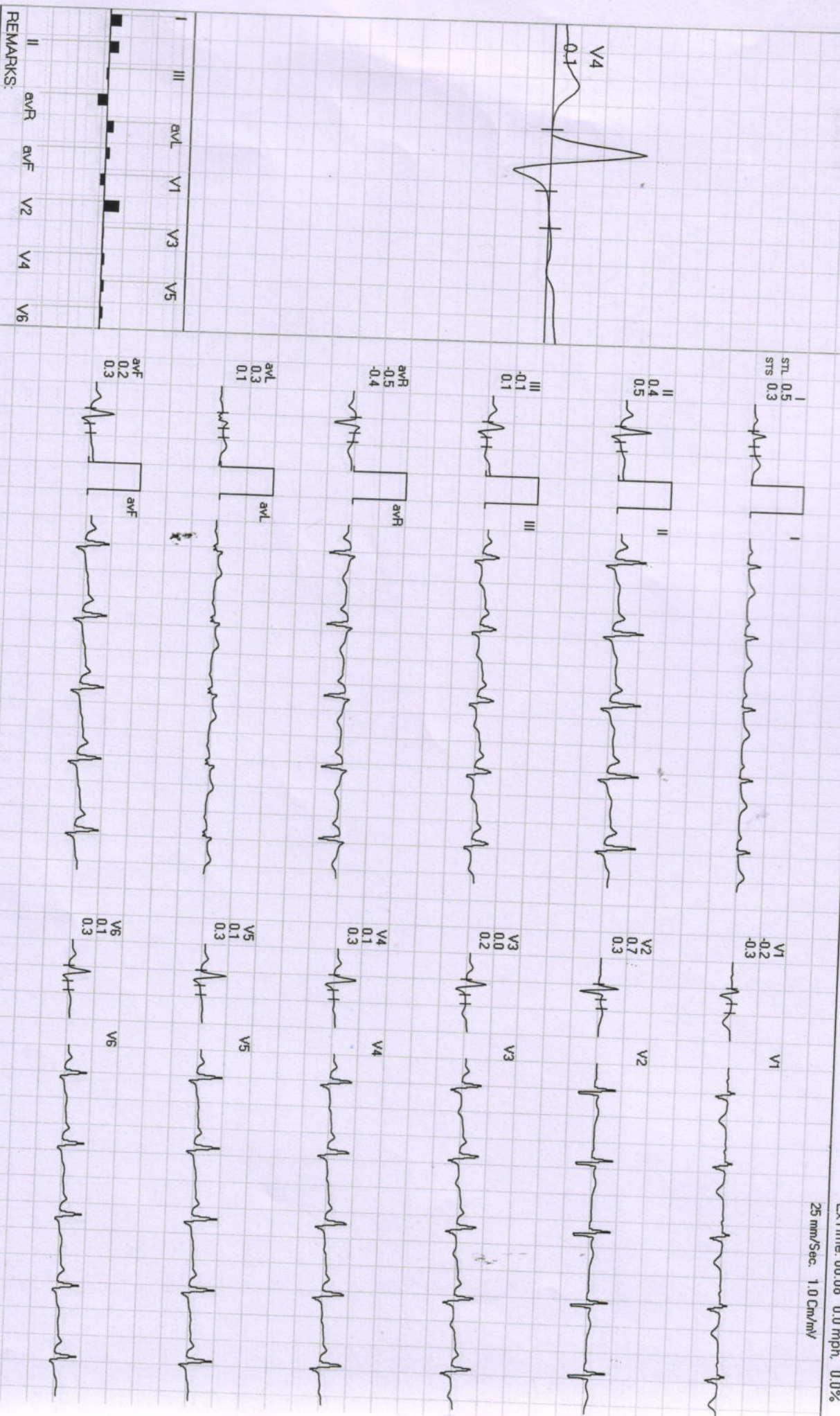

METS: 1.0/ 86 bpm 45% of THR BP: 120/80 mmHg Raw ECG/ BLC On/ Natch On/ HF 0.05 Hz/LF 20 Hz

SUPINE



4X 80 ms Post J

ExTime: 00:08 0.0 mph, 0.0%
25 mm/Sec. 1.0 Cm/mV



REMARKS:

689 / MRS. ADYA GOSWAMI / 33 Yrs / F / 165 Cms / 85 Kg / HR : 86

STANDING

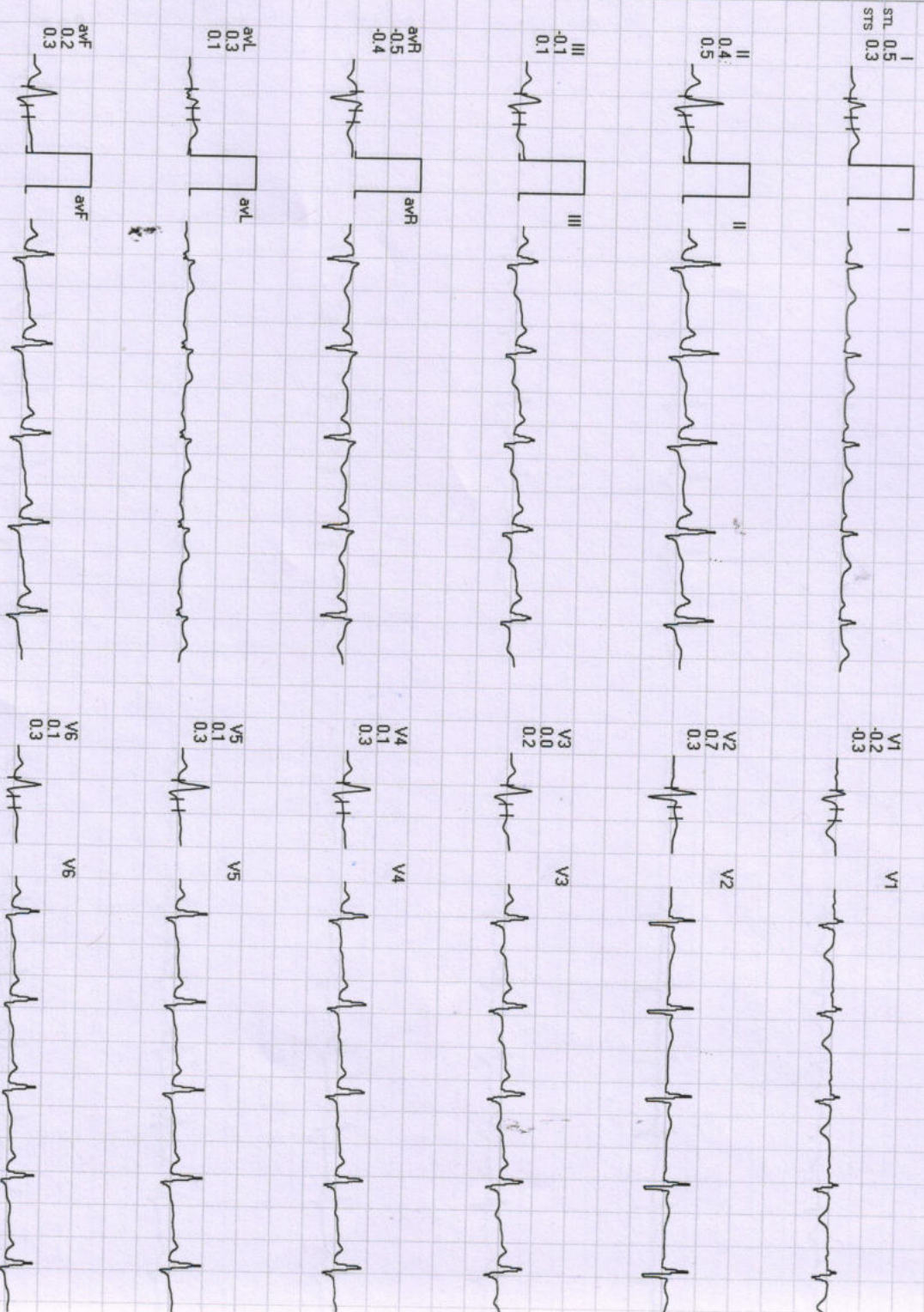
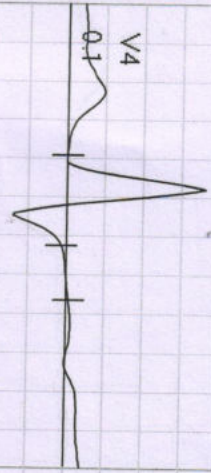


Date: 30-Jul-2022 09:35:11 AM METS: 1.0/ 86 bpm 45% of THR BP: 120/80 mmHg Raw ECG/ BLC On/ Notch On/ HF 0.05 Hz/ LF 20 Hz

ExTime: 00:13 0.0 mph, 0.0%

25 mm/Sec. 1.0 Cm/mV

4X 80 mS Post J

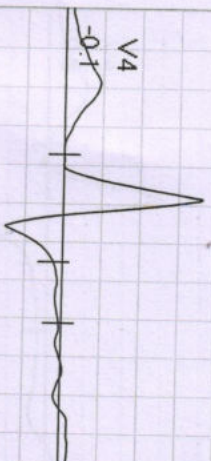


REMARKS:


4X

80 ms Post J

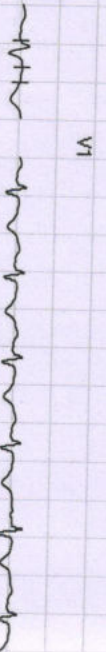ExTime: 00:24 0.0 mph, 0.0%
25 mm/Sec. 1.0 Cm/mV




I
STL 0.3
STS 0.1




V1
0.0
-0.3




II
0.3
0.3




V2
0.6
0.2



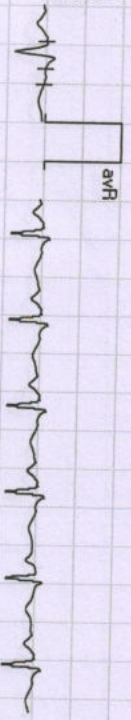
III
0.0
0.2




V3
0.1
0.5



aVR
-0.3
-0.2



V4
-0.1
0.2



aVL
0.1
-0.1




V5
0.1
0.5



aVF
0.1
0.3



V6
0.4
0.4



I	III	aVL	V1	V3	V5
II	aVR	aVF	V2	V4	V6

REMARKS:



689 / MRS. ADYA GOSWAMI / 33 Yrs / F / 165 Cms / 85 Kg / HR : 109

Date: 30-Jul-2022 09:35:11 AM

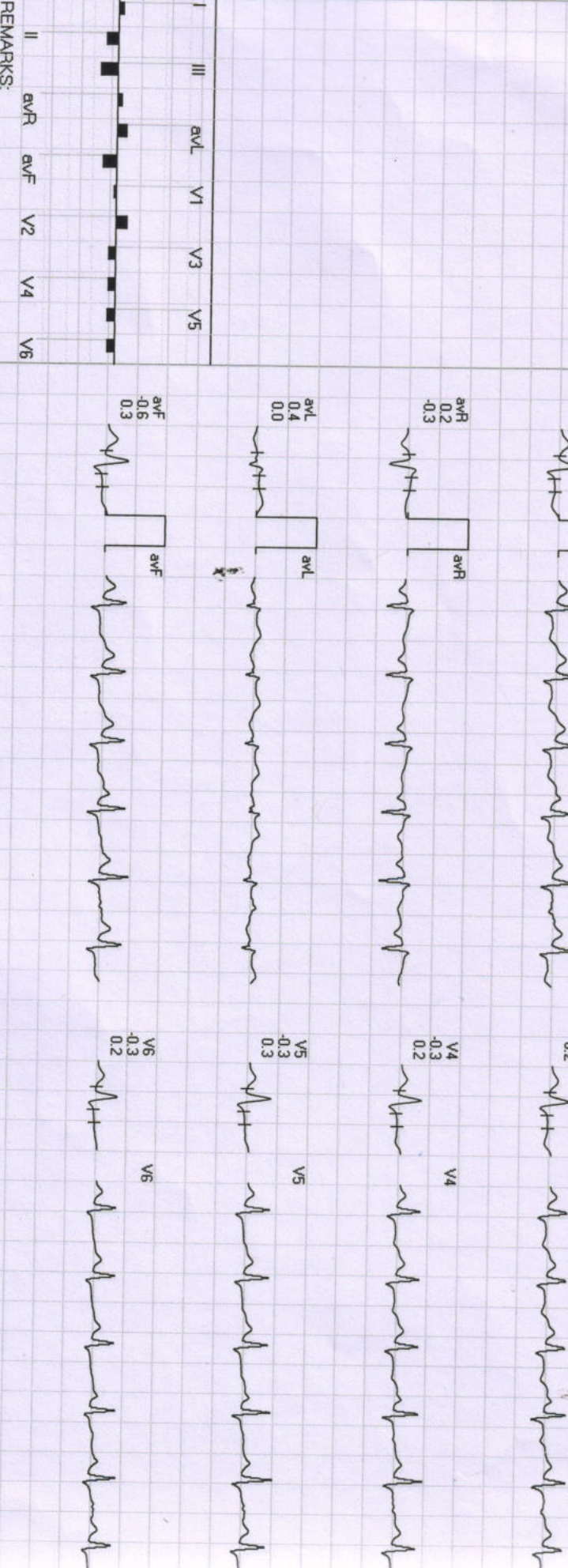
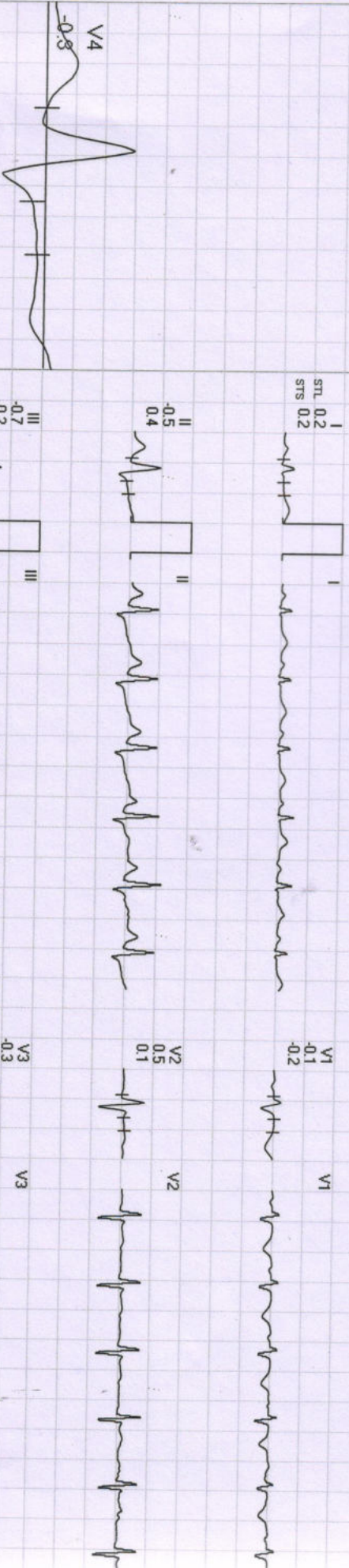
METS: 1.0 / 1.09 bpm 58% of THR BP: 120/80 mmHg Raw ECG/ BLC On/ Notch On/ HF 0.05 Hz/LF 20 Hz

EXTime: 00:28 1.0 mph, 0.0%

4X

80 mS Post J

25 mm/Sec. 1.0 Cm/mV



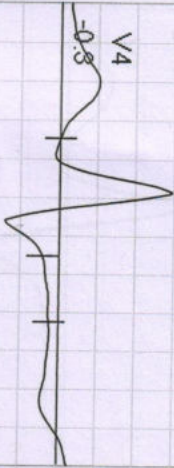
REMARKS:

4X


80 ms Post J

ExTime: 00:00 0.0 mph 0.0%

25 mm/Sec. 1.0 Cm/mV



I
STL 0.2
STS 0.2



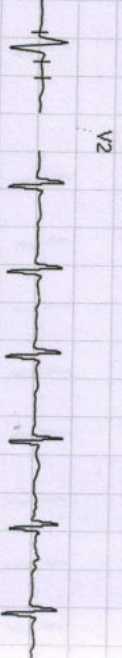
V1
-0.1
-0.2



II
-0.5
0.4




V2
0.5
0.1




III
-0.7
0.2




V3
-0.3
0.2




aVR
0.2
-0.3




V4
-0.3
0.2




aVL
0.4
0.0




V5
-0.3
0.3



aVF
-0.6
0.3



V6
-0.3
0.2



I	III	aVL	V1	V3	V5
II	aVR	aVF	V2	V4	V6

REMARKS:



Date: 30-Jul-2022 09:35:11 AM

METS: 4.7/141 bpm 75% of THR BP: 130/80 mmHg

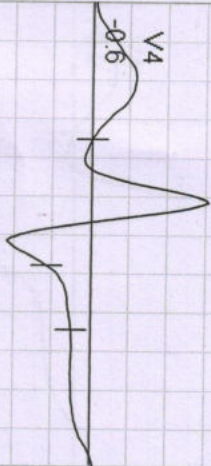
Raw ECG/BLC On/Notch On/HF 0.05 Hz/LF 20 Hz

EXTime: 03:00 1.7 mph, 10.0%

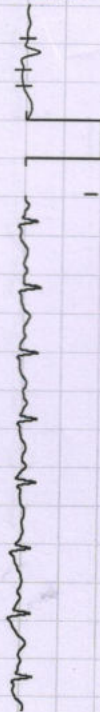
25 mm/Sec 1.0 Cm/mV

4X


60 mS Post J




I
STL -0.4
STS 0.2



V1
0.2
0.0



II
-1.2
1.4



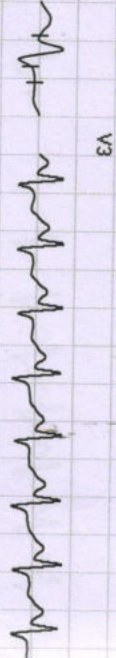V2
0.1
0.1



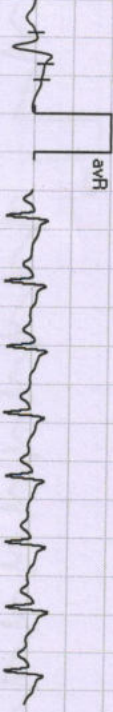
III
-0.7
1.2




V3
-0.6
0.9



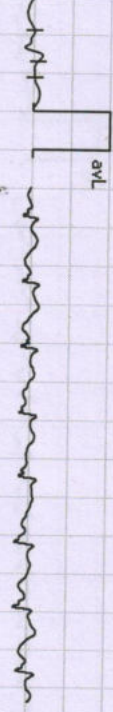
aVR
0.8
-0.8




V4
-0.6
1.2




aVL
0.1
-0.6



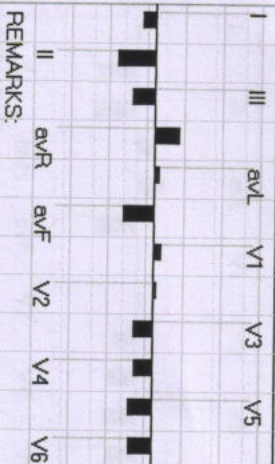

V5
-0.8
0.9



aVF
-1.0
1.3



V6
-0.8
0.7



REMARKS:



689 / MRS. ADYA GOSWAMI / 33 Yrs / F / 165 Cms / 85 Kg / HR : 166

Date: 30-Jul-2022 09:35:11 AM


METS: 7.1 / 166 bpm 88% of THR BP: 140/90 mmHg Raw ECG/ BLC On/ Notch On/ HF 0.05 Hz/LF 20 Hz

EXTime: 06:00 2.5 mph, 12.0%


4X

80 ms Post J

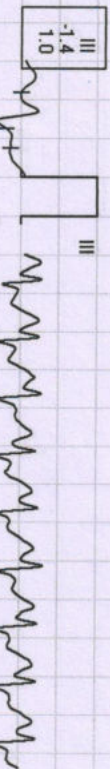

25 mm/Sec. 1.0 Cm/mV




I
STL 0.2
STS 0.7



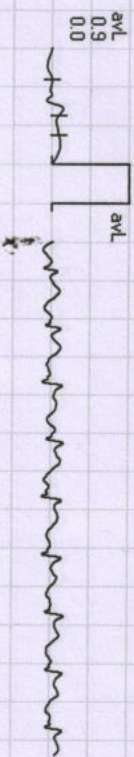

II
-1.2
1.7




III
-1.4
1.0



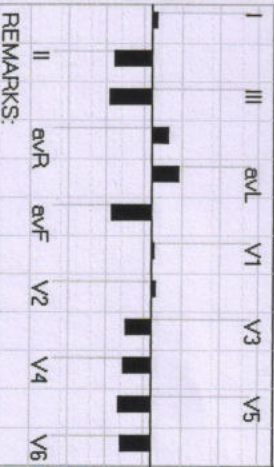

aVR
0.5
-1.2



aVL
0.9
0.0



aVF
-1.3
1.4



REMARKS:

689 / MRS. ADYA GOSWAMI / 33 Yrs / F / 165 Cms / 85 Kg / HR : 169

Date: 30-Jul-2022 09:35:11 AM

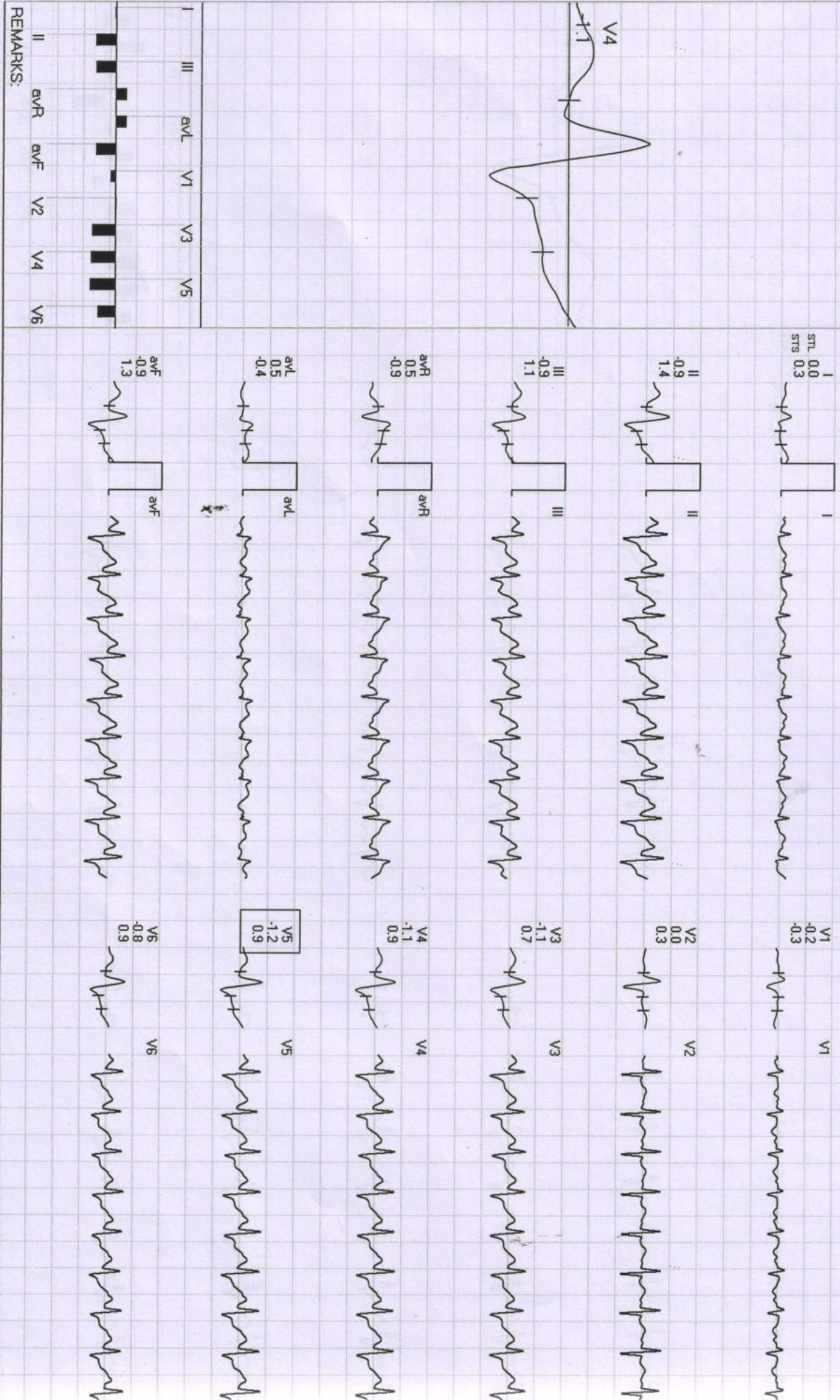
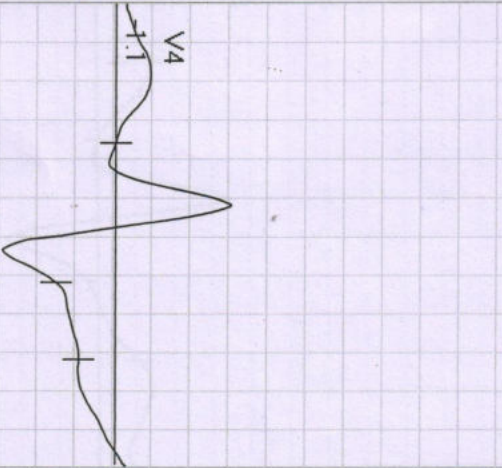
METS: 7.4 / 169 bpm 90% of THR BP: 140/90 mmHg

Raw ECG/ BLC On/ Notch On/ HF 0.05 Hz/LF 20 Hz

EXTime: 06:19 3.4 mph, 14.0%

4X 60 ms Post J

25 mm/Sec. 1.0 Cm/mV



REMARKS:



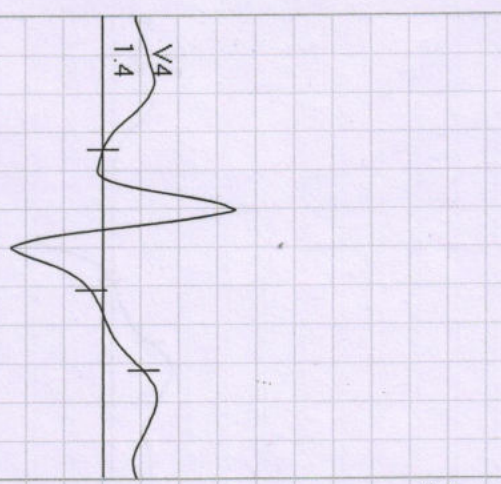
689 / MRS. ADYA GOSWAMI / 33 Yrs / F / 165 Cms / 85 Kg / HR : 128

Date: 30-Jul-2022 09:35:11 AM METS: 1.1/128 bpm 68% of THR BP: 136/86 mmHg Raw ECG/BLC On/Notch On/HF 0.05 Hz/LE 20 Hz


ExTime: 06:19 0.0 mph, 0.0%

4X 80 ms Post J


25 mm/Sec. 1.0 Cm/mV



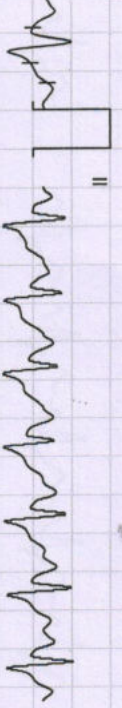I
STL 1.1
STS 1.5



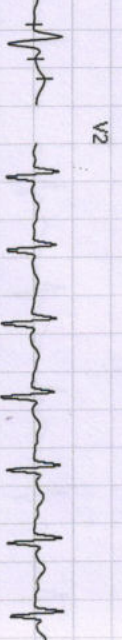
V1
-0.5
-1.0



II
1.9
2.7



V2
1.4
1.4



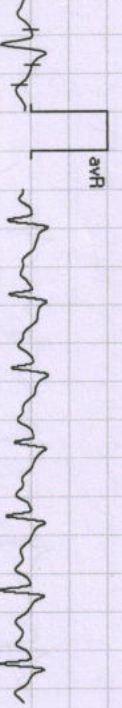
III
0.7
1.2



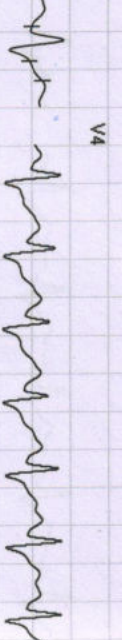V3
1.2
1.7




avR
-1.5
-2.1



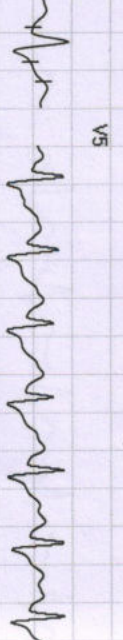
V4
1.4
2.1



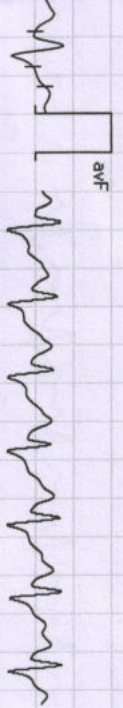
avL
0.2
0.2



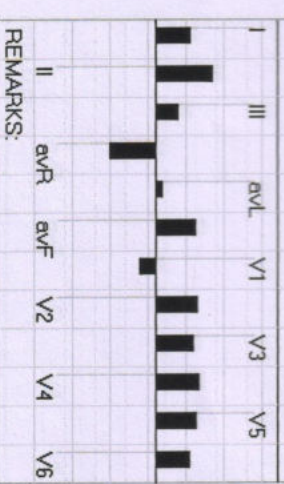
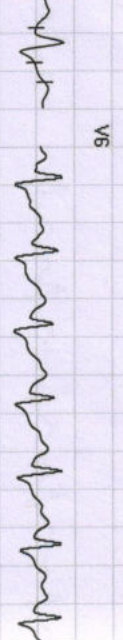
V5
1.3
2.1



avF
1.3
2.0



V6
1.1
1.7



REMARKS:



689 / MRS. ADYA GOSWAMI / 33 Yrs / F / 166 Cms / 85 Kg / HR : 99

Date: 30-Jul-2022 09:35:11 AM

METS: 1.0 / 99 bpm 52% of THR

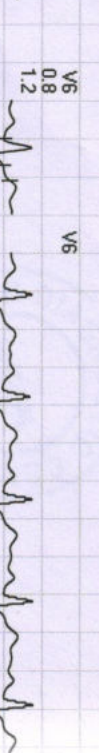
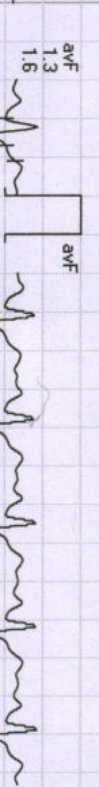
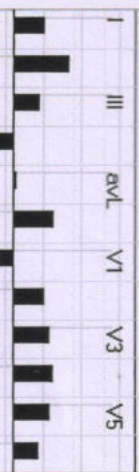






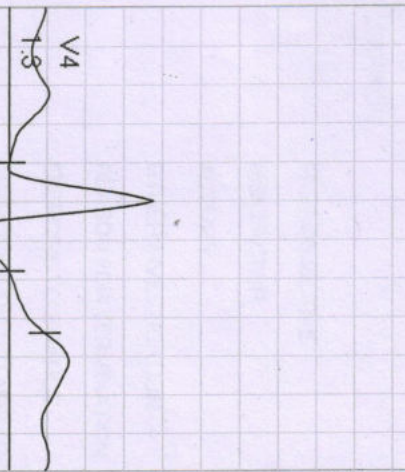
BP: 130/80 mmHg

Raw ECG/ BLC On/ Natch On/ HF 0.05 Hz/LF 20 Hz

4X 80 mS Post J

EXTime: 06:19 0.0 mph, 0.0%

25 mm/Sec. 1.0 Cm/mV



REMARKS: