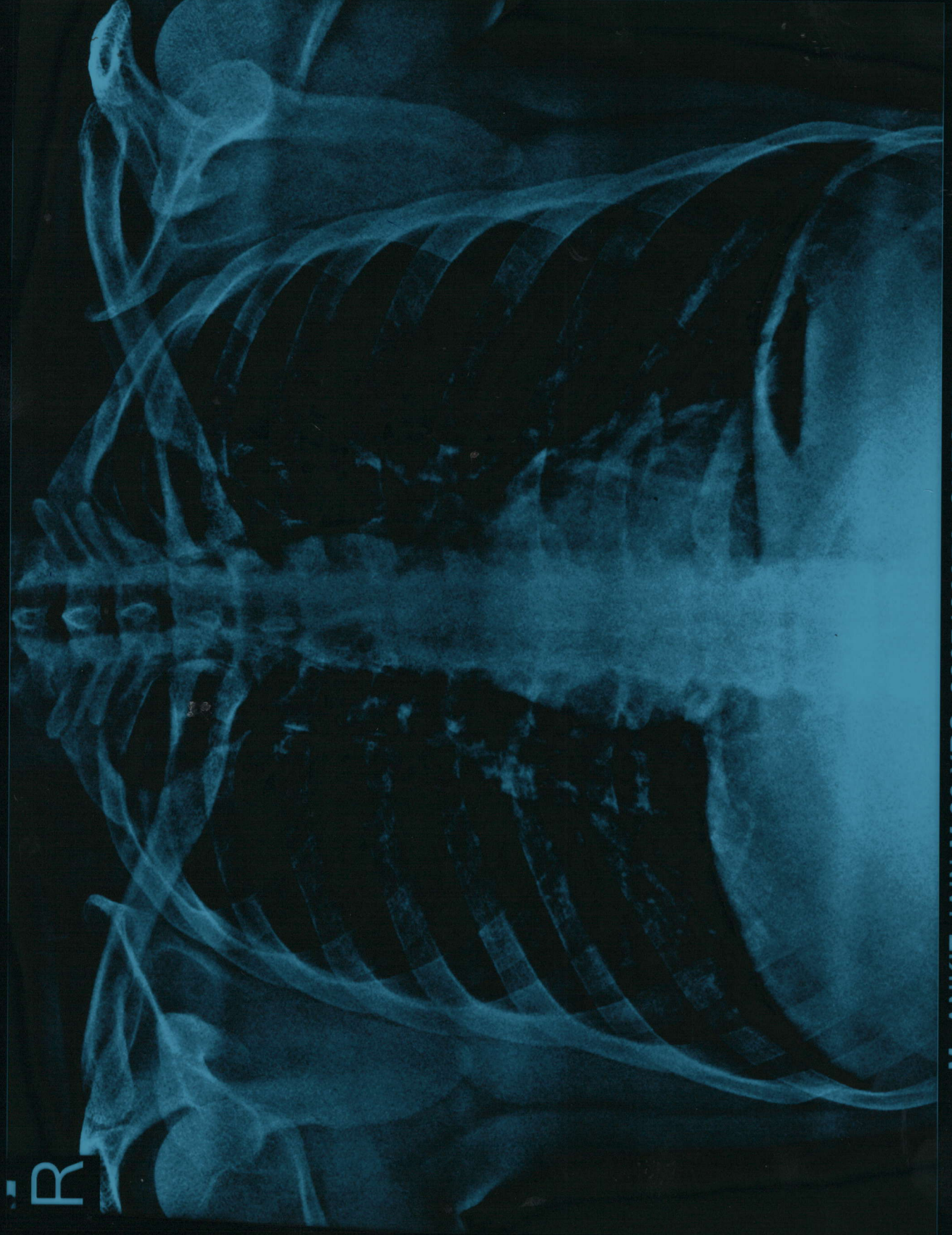

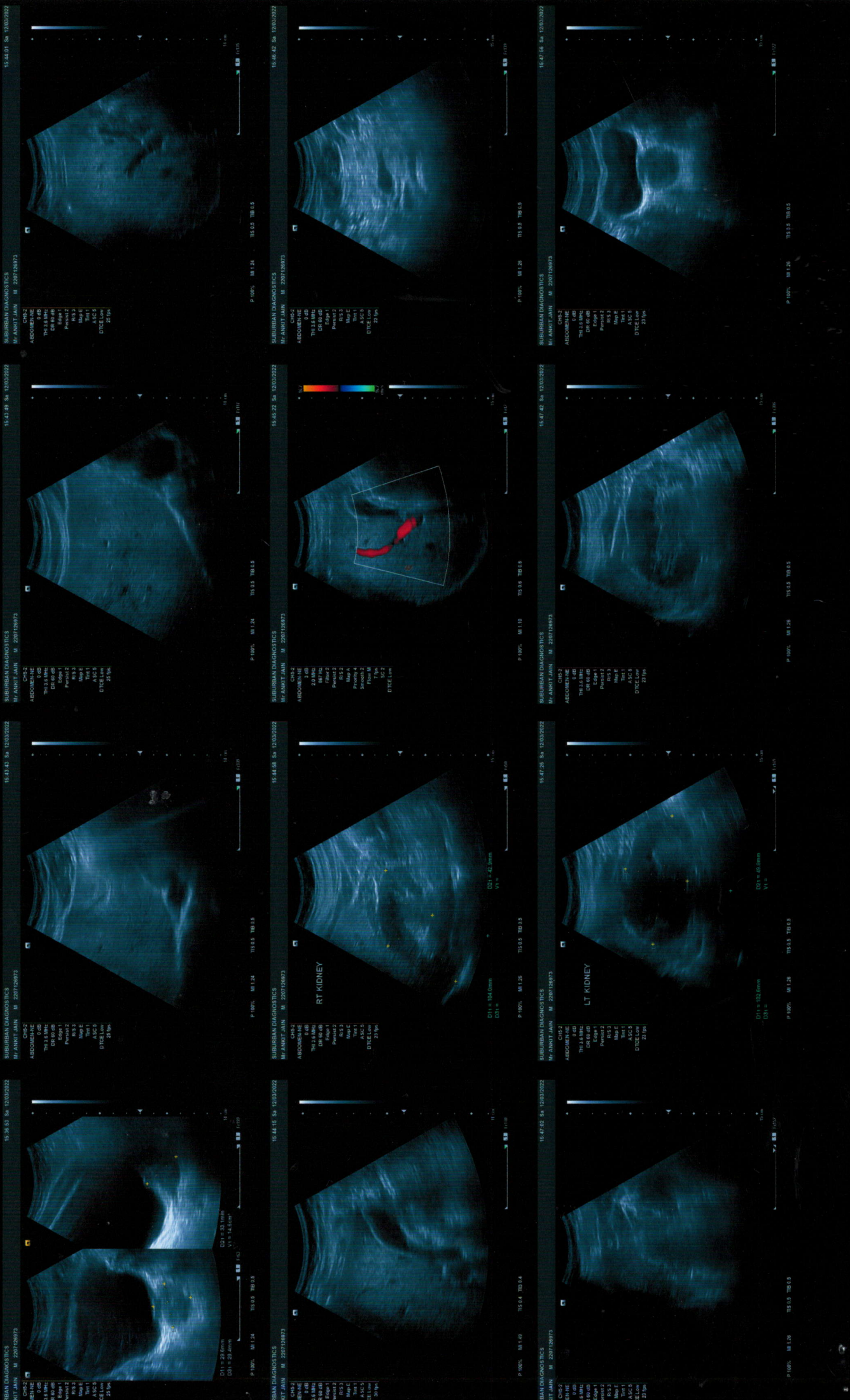
R

Mr ANKIT JAIN M 33 YRS 2207126973 CHEST PA 3/12/2022

# SUBURBAN DIAGNOSTIC CENTRE

name : Mr ANKIT JAIN 33 / M

12 Mar 2022 Study : Abd





Ankit Jain  
33/M

~~FMT~~

~~FMT~~ 2D ECHO  
12/13/22

R  
E  
P  
O  
R  
T

PHY2.

**History and Complaints:**

N/A

**EXAMINATION FINDINGS:**

Height (cms):	170	Weight (kg):	77	BMI
Temp (0c):	Afebrile	Skin:	Normal	N/A
Blood Pressure (mm/hg):	110/70	Nails:	Healthy	
Pulse:	82	Lymph Node:	Not Palpable	

**Systems**

Cardiovascular: S1,S2 Normal No Murmurs  
Respiratory: Air Entry Bilaterally Equal  
Genitourinary: Normal  
GI System: Soft non tender No Organomegaly  
CNS: Normal

**IMPRESSION:**

FBT  
Grade I Fatty liver on USG.  
↑ non HDL, LDL chol.

**ADVICE:**

Diet + Exercise.

**CHIEF COMPLAINTS:**


1)	Hypertension:	N/A
2)	IHD:	
3)	Arrhythmia:	
4)	Diabetes Mellitus :	
5)	Tuberculosis :	
6)	Asthama:	

**7) Pulmonary Disease :**

PUNE LAB ADDRESS: Seraph Centre, Opp. BSNL Exchange, Shahu College Road, Off Pune-Satara Road, Behind Panchami Hotel, Pune - 411009

CENTRAL PROCESSING LAB: 2<sup>nd</sup> Floor, Aston, Sundervan Complex, Above Mercedes Showroom, Andheri West, Mumbai - 400053

8)	Thyroid/ Endocrine disorders :	
9)	Nervous disorders :	
10)	GI system :	
11)	Genital urinary disorder :	
12)	Rheumatic joint diseases or symptoms :	
13)	Blood disease or disorder :	NIL
14)	Cancer/lump growth/cyst :	
15)	Congenital disease :	
16)	Surgeries :	
<b>PERSONAL HISTORY:</b>		
1)	Alcohol	Non 14 months x 2y
2)	Smoking	no.
3)	Diet	Veg
4)	Medication	NIL



Dr. KRUTIKA INGLE

MBBS, D.DM, PG in Diabetology (USA)  
MMC Regd - 2012 103018

Preventive Health Check-up | Pathology | Digital X-Ray | Sonography | Colour Doppler | Mammography | BMD (DXA Scan) | OOB | Stress Test/TMT | 2D Echo | Spirometry | Eye Examination | Dental Examination | Diet Consultation | Audiometry | OT Sterility | Water Sterility | Clinical Res

R  
E  
P  
O  
R  
T

Date:- 12-3-22  
Name:- Ankit Jain

CID:  
Sex / Age: / M

**EYE CHECK UP**

Chief complaints:  
Systemic Diseases: *DM*  
Past history:  
Unaided Vision: *—*  
Aided Vision: *3 m*  
Refraction: *3 m*

	(Right Eye)				(Left Eye)			
	Sph	Cyl	Axis	Vn	Sph	Cyl	Axis	Vn
Distance	<i>—</i>	<i>—</i>	<i>—</i>	<i>(N)</i>	<i>—</i>	<i>—</i>	<i>—</i>	<i>(N)</i>
Near	<i>—</i>	<i>—</i>	<i>—</i>	<i>(N)</i>	<i>—</i>	<i>—</i>	<i>—</i>	<i>(N)</i>

Colour Vision: Normal / ~~Abnormal~~

Remark: *DM*

*Krutika Ingle*

Dr. KRUTIKA INGLE  
MBBS, D.DM, PG in Diabetology (USA)  
MMC Regd - 2012 103018

Pat Name:

HR 75/min

.. Ankit Jain

Age: 33 yrs

170 cm / 77 kg

110 / 70 mmHg

H10211

10 mm/mV

10 mm/mV

Normal Axis, Sinus Rhythm

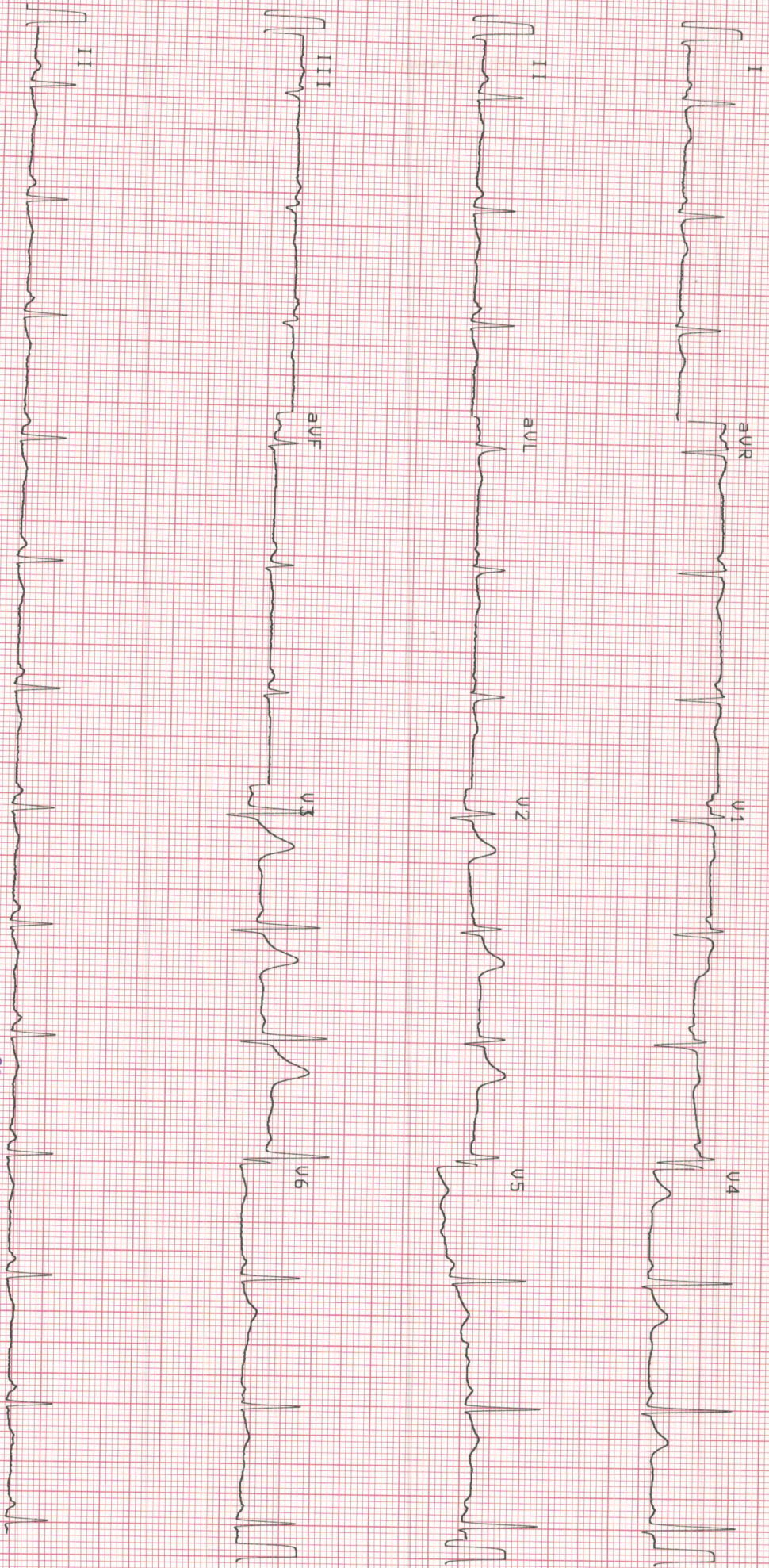
MSD

NSR

DR. KRUTIKA INGHTE

MBBS, D.D.M, PG in Diabetology (USA)  
MMC Regd - 2012 103018

*[Signature]*



25 mm/s

SCHILLER

0.05-25 Hz F50

5a 12-MAR-22 12:08:31

**SUBURBAN DIAGNOSTIC (I) PVT. LTD.**  
"Fortuna" Ground Floor, Near Shivar  
Garden Chowk, Next to Radha Krishna  
Hotel, Pimple Saudagar, Pune-411 027.

PT-2 K.03

Part No 2 157017M

CE 0123

K 88

**2D ECHO / COLOUR DOPPLER**

**NAME :Mr ANKIT JAIN**  
**REF BY: ARCOFEMI HEALTHCARE**  
**CID NO : 2207128625**

**Age: 33Y/MALE**  
**DATE :12.03.2022**  
**REG LOC: PIMPLE SAUDAGAR PUNE**

**M - Mode values**

**Doppler Values**

AORTIC ROOT (mm)	26	PULMONARY VEL (m/sec)	0.6
LEFT ATRIUM (mm)	32	PG (mmHg)	1.5
RV (mm)	28	AORTIC VEL (m/sec)	0.4
IVS - D (mm)	11	PG (mmHg)	0.3
LVID - D (mm)	48	MITRAL E VEL (m/sec)	0.8
LVID - S (mm)	24	A VEL (m/ sec)	0.4
LVPW - D (mm)	11	TRICUSPID VEL. (m/sec)	1.6
EJECTION FRACTION (%)	60	PG (mmHg)	11

Mild mitral valve prolapse.  
Rest other cardiac valves are structurally normal.  
All four cardiac chambers normal in dimensions.  
Normal left ventricle size with Good ventricle systolic function .(LVEF-65%)  
No Regional wall motion abnormality.  
Left atrium, Right atrium & Right ventricle are normal in size.  
No pulmonary artery hypertension. RVSP = 20 mmHg.  
Interatrial septum & Interventricular septum are intact.  
No clot/vegetation /pericardial effusion.  
Doppler study revealed mild mitral regurgitation , mild tricuspid regurgitation.  
IVC 1.5 cm, more than 50% pulsatile.  
Left sided aortic arch, No coarctation of aorta.  
No diastolic dysfunction.

**CONCLUSION:**

**Normal left ventricle size with Good ventricle systolic function .(LVEF-65%)**  
**No pulmonary artery hypertension. RVSP = 20 mmHg.**  
**Mild mitral valve prolapse.**



**Dr. Sonam Shah**  
**MBBS MD DM Cardiology**  
**Interventional Cardiologist**  
**MMC 2010 / 06 / 2218**

**DR SONAM SHAH**  
**MD DM CARDIOLOGY**  
**INTERVENTIONAL CARDIOLOGY**





CID : 2207126973  
Name : Mr ANKIT JAIN

Age / Sex : 33 Years/Male

Ref. Dr :

Reg. Location : Pimple Saudagar, Pune Main Centre

Reg. Date : 12-Mar-2022 / 15:42

Reported : 12-Mar-2022 / 15:44

## USG WHOLE ABDOMEN

**Liver-** Normal in size, shape with **slightly raised parenchymal echo pattern s/o grade I fatty liver**. No focal lesion. Intrahepatic biliary and portal radicals appear normal. Visualised portion of CBD appears normal in calibre. Portal vein appears normal.

**Gall bladder-** partially distended with normal wall thickness. No calculus or mass lesion is visualized. No pericholecystic collection.

**Pancreas-** Head and body are visualized and appear normal in size, shape and echo pattern. No focal lesion seen. No peripancreatic collection noted.

**Spleen** - Appears normal in size, shape & echo pattern. No focal lesion seen.

**Kidneys-** Right kidney -10.4 X 4.2 cm, Left kidney -10.2 X 4.9 cm, both kidneys appear normal in size, shape, position & echo pattern with maintained cortico-medullary differentiation. Tiny papillary concretions are noted in both the kidneys. No hydronephrosis, hydroureter or calculus noted.

**Urinary bladder-** Is distended & shows normal wall thickness. No calculus or mass lesion is noted.

**Prostate** - appears normal in size(vol-14.6.cc), shape and echo-pattern for age. No focal lesion .

No free fluid in abdomen and pelvis.

Visualized bowel loops are gaseously distended appear grossly normal and show normal peristalsis. No evidence of enlarged lymph nodes.

### IMPRESSION:

**Grade I fatty liver.**

*Advice - clinical correlation and further evaluation if clinically indicated.*

**Dr. SATYAJEET S. GHODAKE**  
MBBS, MD, DNB, MNAMS.  
Regd. No. 2013/05/1417  
Consultant Radiologist

-----End of Report-----

**This report is prepared and physically checked by DR SATYAJEET before dispatch.**

*Investigations have their own limitations. Solitary radiological investigation never leads to a final diagnosis. They should be always correlated with clinical and pathological examinations.*

Click here to view images <http://202.143.96.162/Suburban/Viewer?ViewerType=3&AccessionNo=2022031210020815>

PUNE LAB ADDRESS: Seraph Centre, Opp. BSNL Exchange, Shahu College Road, Off Pune-Satara Road, Behind Panchami Hotel, Pune - 411009

CENTRAL PROCESSING LAB: 2<sup>nd</sup> Floor, Aston, Sundervan Complex, Above Mercedes Showroom, Andheri West, Mumbai - 400053

HEALTHLINE - MUMBAI: 022-6170-0000 | OTHER CITIES: 1800-266-4343 | For Feedback - customerservice@suburbandiagnosics.com | www.suburbandiagnosics.com



**CID** : 2207126973  
**Name** : Mr ANKIT JAIN  
**Age / Sex** : 33 Years/Male  
**Ref. Dr** :  
**Reg. Location** : Pimple Saudagar, Pune Main Centre

**Reg. Date** : 12-Mar-2022 / 12:59  
**Reported** : 12-Mar-2022 / 17:10

### X-RAY CHEST PA VIEW

Patient is minimally rotated.  
Trachea is central.  
Slightly prominent bronchovascular markings are noted bilaterally.  
Visualized bilateral lung fields otherwise appear grossly normal.  
Both hila appear normal.  
Cardio-aortic silhouette has grossly normal appearance for age.  
Diaphragmatic domes have normal contours and positions.  
Bilateral costophrenic and cardiophrenic angles appear normal.  
Visualized bony thorax and soft-tissues are grossly normal for age.

### **IMPRESSION :**

No other significant abnormality detected.

*Advice – Clinical correlation and further evaluation if clinically indicated.*

*Ghoda*


**Dr. SATYAJEET S. GHODAKE**  
MBBS, MD, DNB, MNAMS.  
Regd. No. 2013/05/1417  
Consultant Radiologist

*Investigations have their own limitations. Solitary radiological investigation never leads to a final diagnosis. They should be always correlated with clinical and pathological examinations.*

**This report is prepared and physically checked by DR SATYAJEET before dispatch.**

**Click here to view images** <http://202.143.96.162/Suburban/Viewer?ViewerType=3&AccessionNo=2022031210020822>

Download Date: 12/06/2021



भारत सरकार  
Government of India

Ankit Jain  
Ankit Jain  
जन्म तिथि/DOB: 08/04/1988  
पुंलिंग/ MALE

Issue Date: 02/06/2018

4653 3065 4722  
VID : 9108 1202 3286 9327

भारत आहार, जैसी पहचान

SUBURBAN DIAGNOSTIC (I) PVT. LTD.  
"Fortuna" Ground Floor, Near Shivar  
Garden Chowk, Next to Radha Krishna  
Hotel, Pimple Saudagar, Pune-411 027.

*Ankit Jain*  
12/03/22