

❖ This medical fitness is only on the basis of clinical examination. No COVID -19 and other investigation has been done to reveal the fitness

MEDICAL EXAMINATION REPORT

Name Raman Sharma Age & Sex 54y/M Date of MER 09/11/24
 Identification Mark Male near Rt. eye ID Proof VIA CARD
 Ht 179 wt 105 Chest Exp/Insp. 120/125 Abd 116 PR 79 BP 140/90

Any Operation

No

Any Medicine Taken

K/O - HTN since 1 year on Rx Tab. Amlong 25mg

Any Accident

No

Alcohol/Tabacco/Drugs No

Consumption..... Duration.....

Qty.....

Whether the person is suffering from any of the following diseases, give details

DISEASE	Yes/NO	DETAIL
Diabetes	No	
Hypertension	YES	HTN since 1 year Rx Tab. Amlong 25mg
Renal Complications	No	
Heart Disease	No	
Cancer	No	
Any Other	No	

Examination of systems

SYSTEMS(any evidence of past/present disease)	YES	NO	DETAILS
Brain or nervous system		<input checked="" type="checkbox"/>	
Lungs or other parts of respiratory system		<input checked="" type="checkbox"/>	
GI Tract		<input checked="" type="checkbox"/>	
Ears, Eyes, Nose, Throat, Neck		<input checked="" type="checkbox"/>	
Cardiovascular System		<input checked="" type="checkbox"/>	

Signature of client.....

Signature of Doctor.....

Seal of Centre.....

Dr. R.S. Maheshwari
 M.B.B.S. M.D. (Paed) P.C.M.S. (Ex.) M.I.A.P.
 Consultant Physician & Child Specialist
LIFE LINE HOSPITAL
 GILL ROAD, LUDHIANA-141003
 Registration No. 34970



सत्यमेव जयते
ਅਖਰ ਵਾਕਾ



आधार

ਭਾਰਤ ਸਰਕਾਰ ਪਾਠਾਏ ਅਧਾਰਟੀ

ਭਾਰਤ ਸਰਕਾਰ
Unique Identification Authority of India
Government of India

ਦਾਖਲੇ ਦਾ ਪਛਾਣ / Enrollment No. : 1055/90677/02924

21/08/2013

To
Raman Sharma
ਰਮਨ ਸ਼ਰਮਾ
S/O: Rajinder Kumar Sharma
644-E
B R S NAGAR
Rajguru Nagar
Rajguru Nagar, Ludhiana
Punjab - 141012
7355095673



KL358682102FT

35868210



ਤੁਹਾਡਾ ਅਧਾਰ ਨੰਬਰ / Your Aadhaar No. :

9603 5512 8351

ਆਧਾਰ - ਆਮ ਆਦਮੀ ਦਾ ਅਧਿਕਾਰ



ਭਾਰਤ ਸਰਕਾਰ
Government of India

ਰਮਨ ਸ਼ਰਮਾ

Raman Sharma

Dr. R. S. Maheshwari
M.B.B.S. M.D. (Ped) D.C.M.S. (Ex) M.I.A.P.
Consultant Physician & Child Specialist
LIFE LINE HOSPITAL
GILL ROAD, LUDHIANA-141001
Registration No. 34970



9603 5512 8351



ਆਧਾਰ - ਆਮ ਆਦਮੀ ਦਾ ਅਧਿਕਾਰ

for

- Apollo Insurance Co. Ltd.
 - Aviva Life Insurance Co. Ltd.
 - Star Health and Allied Insurance Co. Ltd.
 - Star
 - Sah
 - Rel
 - Ma
 - Edt
 - Shr
 - Ch
 - TA
 - In
 - Ex
 - IC
 - IC
 - C
 - R
 - L

LIFELINE HOSPITAL

LIFELINE HOSPITAL

LIFELINE HOSPITAL

LIFELINE HOSPITAL

LIFELINE HOSPITAL

LIFELINE HOSPITAL

LIFELINE HOSPITAL

LIFELINE HOSPITAL

LIFELINE HOSPITAL

LIFELINE HOSPITAL

LIFELINE HOSPITAL


Important

1. Please Bring Card for Any Pre-Insurance
2. Center Will Not Charge for Lab Test With Insurance
3. Please Come Fast As Per The Instructions By Your Corporation
4. Please Keep Silence And Switch Off Mobile
5. Please Fill The Form And Do Not Hesitate Faced Any Problem

YOU ARE UNDER SURVEILLANCE

Dr. R.S. Makshwari
 M.B.B.S. M.D. (Paed) P.C.M.S. (Ex) M.I.A.P.
 Consultant Physician & Child Specialist
LIFE LINE HOSPITAL
 GILL ROAD, LUDHIANA-141003
 Registration No. 34970

Ludhiana, Punjab, India
 241/1, Dasmesh Nagar, New Kartar Nagar, Ludhiana, Punjab 141003, India
 Lat 30.88376° Long 75.85819°
 09/11/24 09:46 AM GMT +05:30



© 2024 Mapbox

Lifeline Hospital

Multi Speciality & Super Speciality Hospital

NABH Accredited



NAME Roman Sharma

EMP.CODE _____

AGE / SEX 51y/m

DATE 09/11/2024

REF. BY BoB

	RIGHT EYE				LEFT EYE			
	SPH	CYL	AXIS	VIA	SPH	CYL	AXIS	VIA
DISTANCE	<u>-0.25</u>	<u>—</u>	<u>—</u>	<u>6/6</u>	<u>-0.50</u>	<u>—</u>	<u>—</u>	<u>6/6</u>
FOR NEAR ADD			<u>—</u>				<u>—</u>	

COLOR VISION (ISHIHARA'S CHART)

COLOR VISION : Normal

OTHER OPINION: _____

EYE CARE DEPARTMENT
LIFELINE HOSPITAL
GILL ROAD, LUDHIANA-141003.

DOCTOR SIGNATURE



NAME: RAMAN SHARMA

AGE/SEX: 51 Y/M

HEIGHT: 179 cms

WEIGHT: 105kgs

B.P: 140/90mmHg

PULSE: 60 BPM

- CVS - N.A.D.
- CNS - N.A.D.
- P/A - N.A.D.
- R/S - N.A.D.
- ENT - N.A.D.
- Skin Examination - N.A.D.
- Hearing Examination - N.A.D.
- Dental Examination - Good Oral Hygiene.

Dr. R.S. Maheshwari
DR. R.S. Maheshwari M.B.B.S., M.D. (Ped) P.G.M.S. (Ex.) M.I.A.P.
M.B.B.S., M.D. Consultant Physician & Child Specialist
LIFE LINE HOSPITAL
GILL ROAD, LUDHIANA-141003
Registration No. 34970

QRS 86 ms
QT / QTc/Baz 366 / 411 ms
PR 172 ms
P 88 ms
RR / PP 792 / 789 ms
P / QRS / T 65 / -1 / 43 degrees

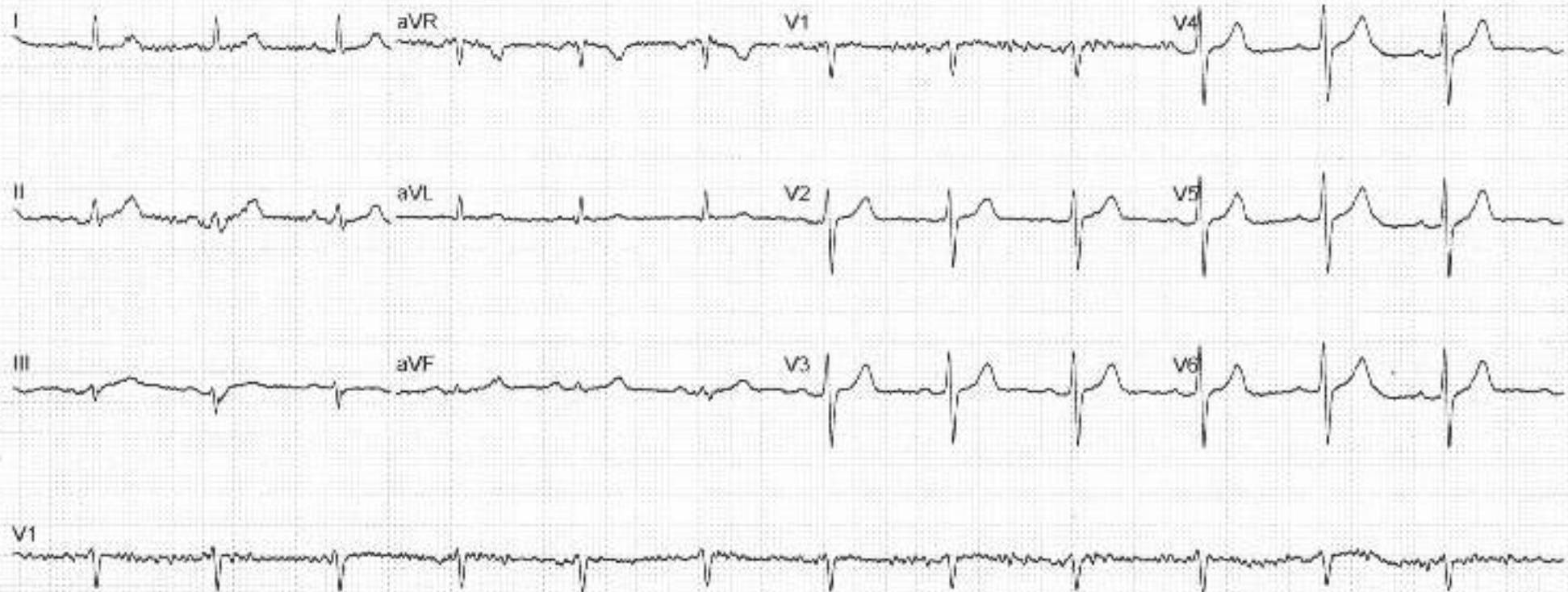
Normal sinus rhythm
Normal ECG

hnl

Technician:
Ordering Ph:
Referring Ph:
Attending Ph:

Dr. R.S. Aneshwari
M.B.B.S. MD
Medical Director
Reg. 34970

[Handwritten mark]



To,
Lifeline Hospital
Gill Road,
LDH

I referred to my stool sample.



Dr. R.S. Maheshwari
M.B.B.S. MD (Paed) P.C.M.S. (Ex.) M.I.A.P.
Consultant Physician & Child Specialist
LIFE LINE HOSPITAL
GILL ROAD, LUDHIANA-141003
Registration No. 34970

Dr. Sanjeev Kumar Mittal

M.D, DNB, DM (Cardiology)
Fellowship American College of Cardiology (FACC)
Fellowship European Society of Cardiology (FESC)
Fellowship of Society of Cardiovascular
Angiography & Interventions, USA (FSCAI)
Senior Interventional Cardiologist

Dr. Reena Mittal

Anaesthesiologist
Pain Management Specialist



Dr. SANJEEV
HEART CENTRE

Let's go for healthy heart

47-A (B-XX-894/2) Maya Nagar, Civil Lines, Ludhiana, Punjab (INDIA), Ph: 0161-2443344, E-mail: dr_sanjeev@yahoo.com.

NAME	RAMAN SHARMA	AGE/SEX	51/MALE
REF .BY	LIFE LINE HOSPITAL	DATE	09/11/2024
DIAGNOSIS	CARDIAC EVALUATION		

ECHOCARDIOGRAPHY REPORT

MEASUREMENTS:

		NORMAL VALUES
Left Atrial dimension:	3.3	(1.9-4.0cm)
Aortic root dimension:	3.2	(2.0-3.7cm)
Aortic valve opening	1.9	
Left Ventricular end diastolic dimension	3.9	(3.8-5.6cm)
Left Ventricular end systolic dimension:	2.0	(2.0-4.0cm)
Interventricular septum thickness (end diastolic):	1.1	(0.6-1.2cm)
(end systolic):	1.7	
Left Ventricular posterior wall thickness (end diastolic)	1.0	(0.5-1.0cm)
(end systolic):	1.7	
Right ventricular dimension:	2.1	(0.7-2.6cm)
Right ventricular thickness:	Normal	(0.3-0.5cm)

INDICES OF LEFT VENTRICULAR FUNCTION

LV Ejection Fraction:	60	(55-70%)
-----------------------	----	----------

For all Investigations & in all emergencies.
Please Contact: 97797-12871

- Coronary Angiography
- PTCA / Stenting
- Renal and Peripheral Angiography
- Pacemaker Implantation
- Natural Bypass Therapy (ECP Therapy)

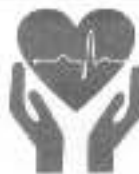- ECG
- ECHO
- TMT
- Holter
- Stress ECHO
- Advanced ECHO
- Strain rate Imaging
- Carotid Doppler

Dr. Sanjeev Kumar Mittal

MD, DNB, DM (Cardiology)
 Fellowship American College of Cardiology (FACC)
 Fellowship European Society of Cardiology (FESC)
 Fellowship of Society of Cardiovascular
 Angiography & Interventions, USA (FSCAI)
 Senior Interventional Cardiologist

Dr. Reena Mittal

Anesthesiologist
 Pain Management Specialist

**Dr. SANJEEV
HEART CENTRE***Let's go for healthy heart*

47-A, (B-XX-894/2) Maya Nagar, Civil Lines, Ludhiana, Punjab (INDIA), Ph: 0161-2443344, E-mail: dr_smittal@yahoo.com.

IMAGING:

2-D imaging in PLAX, SAX and Apical views revealed normal LV size and normal LV contractility. RA/RV are normal in size. Mitral valve opening is normal. No evidence of Mitral valve prolapse is seen. Aortic valve has three cusps and its opening is not restricted. Pulmonary and tricuspid valves are structurally normal. Interatrial and interventricular septums are intact. No intracardiac mass or thrombus is seen. No pericardial pathology is observed. LV ejection fraction is approximately 60%.

DOPPLER: PULSE WAVE, CONTINUOUS WAVE & COLOR FLOW MAPPING

MITRAL VALVE	:	E=0.53 m/sec	A= 0.63 m/s	A>E	Trace MR
AORTIC VALVE	:	1.13 m/sec			No AR
TRICUSPID VALVE	:	E= 0.59 m/sec	A=0.52 m/s		No TR
PULMONARY VALVE	:	0.95 m/sec			No PR
TISSUE DOPPLER IMAGING:		E' = 0.10 m/s		E/E' = 5.38	

IMPRESSION: Normal Cardiac Chamber dimensions
 Normal LV systolic function (LVEF 60%)
 Type 1 diastolic dysfunction.
 Trace MR. No TR. No PR. No AS/A&.
 No clot/ veg./Pericardial effusion.

Dr. Sanjeev Kumar Mittal
Dr. Sanjeev Kumar Mittal
 DM Cardiology, FACC, FSCAI, FESC
 Cardiologist Mittal Clinic, Ludhiana
 Reg. No. 30318

For all Investigations & in all emergencies,
 Please Contact: 97797-12871

- Coronary Angiography
- PTCA / Stenting
- Renal and Peripheral Angiography
- Pacemaker Implantation
- Natural Bypass Therapy (ECP Therapy)
- ECG
- ECHO
- TMT
- Holter
- Stress ECHO
- Advanced ECHO
- Strain rate Imaging
- Carotid Doppler

SANJEEV HEART CENTRE

Name raman sharma

Date 09/11/2024

Image 1

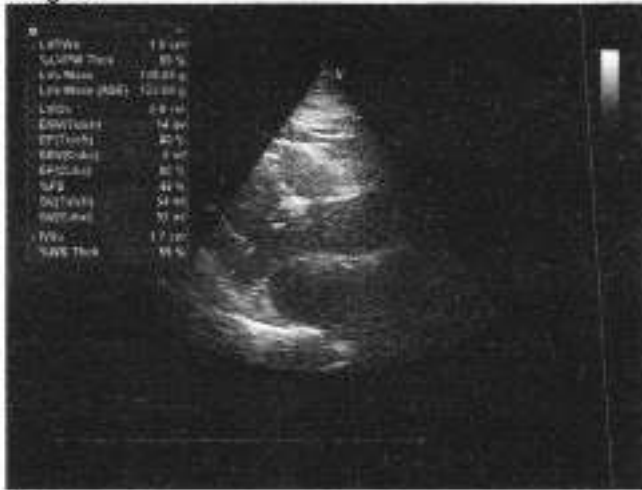

Image 2

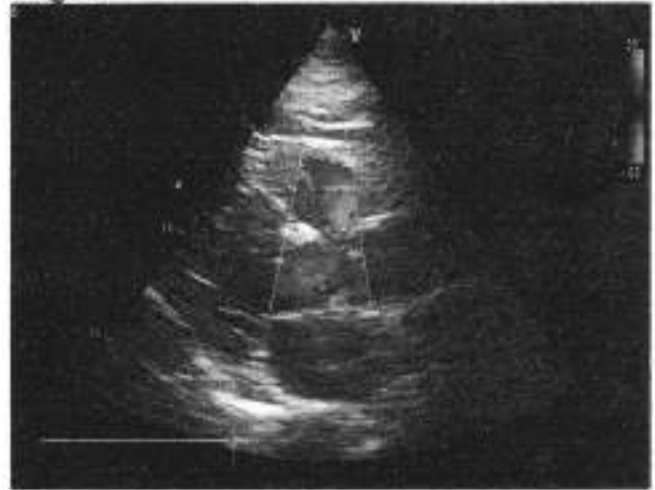


Image 3

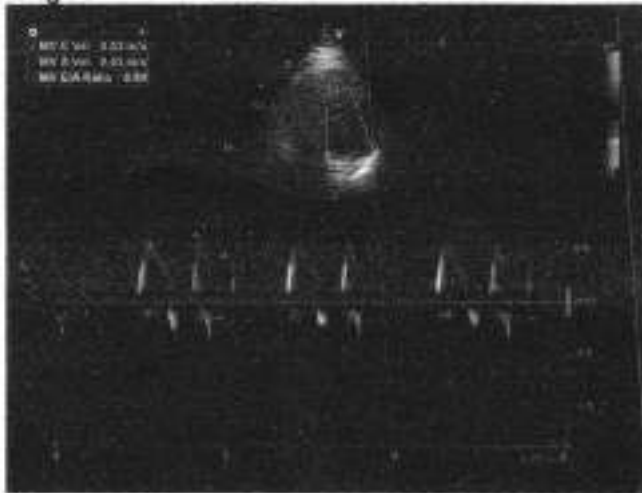


Image 4

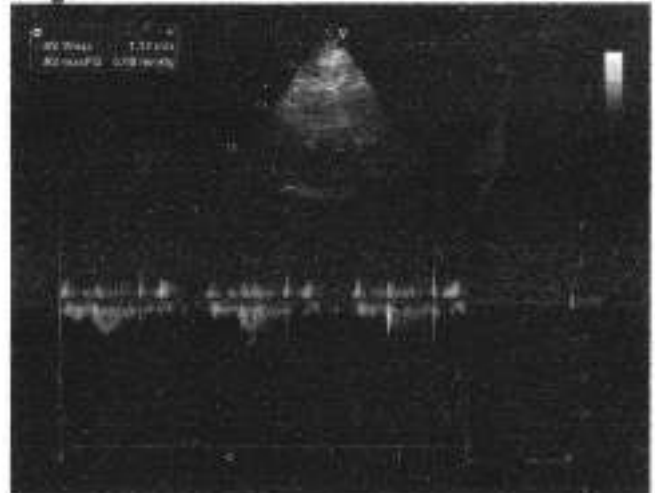


Image 5

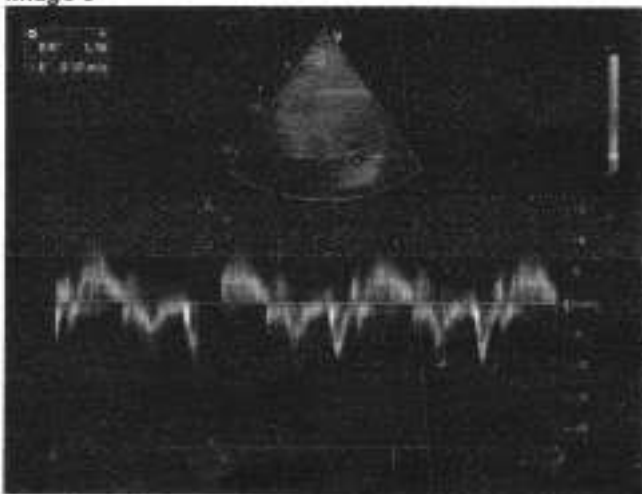
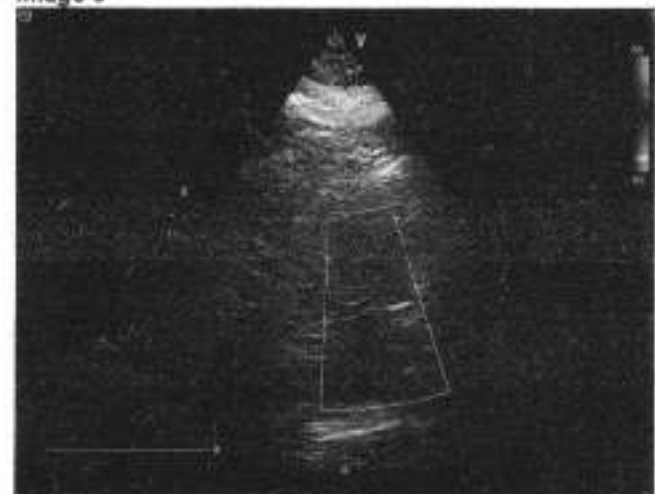


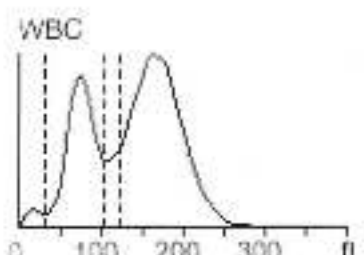
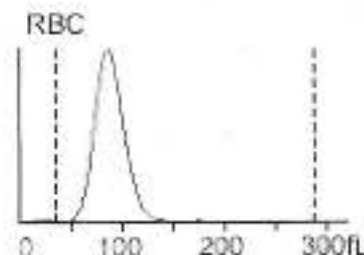
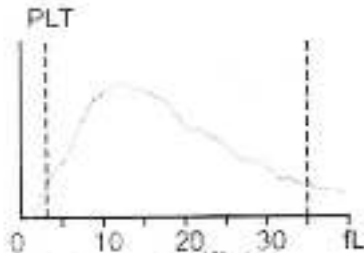
Image 6



Lab ID. :	10	Date :	09/11/2024
Name :	RAMAN SHARMA	Age/Sex :	51 Years/Male
Ref. By :	BANK OF BARODA	Mac. No. :	4692

Complete Blood Count

Test Performed on ERBA H360 Fully Automated Analyser

Parameters	Result	Units	Reference Range	Graphs
LEUKOCYTES				
Total WBC Count	10.02	$10^3/uL$	4.0 - 11.0	
Lymphocytes%	30.4	%	20.0 - 50.0	
Mixed%	5.5	%	3.0 - 10.0	
Neutrophils%	64.1	%	50.0 - 70.0	
Lymphocytes#	3.05	$10^3/uL$	0.6 - 4.1	
Mixed#	0.55	$10^3/uL$	0.1 - 1.8	
Neutrophils#	6.42	$10^3/uL$	2.0 - 7.8	
ERYTHROCYTES				
Hemoglobin	14.0	g/dl	12.0 - 17.0	
R.B.C Count	4.81	$10^6/uL$	3.50 - 5.50	
Haematocrit(PCV)	42.9	%	36.0 - 47.0	
MCV	89.2	fl	80.0 - 99.0	
MCH	29.2	pg	27.0 - 32.0	
MCHC	32.7	g/dl	32.0 - 36.0	
RDW-SD	49.6	fl	35.0 - 56.0	
RDW-CV	14.4	%	11.5 - 14.5	
THROMBOCYTES				
Platelets Count	168	$10^3/uL$	150 - 450	
MPV	10.2	fl	7.4 - 10.4	
PDW	16.4	fl	10.0 - 17.0	
PDW-CV	16.2	%	10.0 - 17.0	
PCT	0.211	%	0.108 - 0.280	
P-LCR	40.5	%	13.0 - 43.0	
P-LCC	79.0	$10^3/uL$	30 - 90	
ESR	10	mm 1st hr	0 - 20	
Blood Group	"B" POSITIVE			

Dr. SUNIL GOYAL
M.B.B.S M.D (PEDIATRICS)
CONSULTANT PEDIATRICIEN
401115

K. Kaur
9/11/24

NAME : RAMAN SHARMA
AGE/SEX : 51Y/M
REF BY : BANK OF BARODA
DATE : 09.11.2024


BLOOD EXAMINATION REPORT

DETERMINATION	NORMAL	RESULT
FBS	70-110mg/dl	89mg/dl
PPBS	70-140mg/dl	141mg/dl
BILLIRUBIN TOTAL	<1.2mg/dl.	0.74mg/dl
BILLIRUBIN DIRECT	<0.3mg/dl	0.18mg/dl
BILIRUBIN INDIRECT	<0.9mg/dl	0.56mg/dl
S.G.O.T.	5-50Units/L	35Units/L
S.G.P.T.	5-50 Units/L	40Units/L
GAMMA GT	9-52 Units/L	25Units/L
SGOT/SGPT RATIO		0.87 RATIO
TOTAL PROTEIN	6.0-8.0mg/dl	7.3mg/dl
ALBUMIN	3.5-5.3mg/dl	4.2mg/dl
S.GLOBULIN	2.0-4.0gm/dl	3.1gm/dl
A/G RATIO	1.25:1-1.75:1 mg/dl	1.35:1gm/dl
ALK. PHOSPHATASE	108-305 Units/L.	189Units/L.
UREA(BUN)	15-45mg/dl	23mg/dl
CREATININE	0.7-1.5mg/dl	0.78mg/dl
URIC ACID	3.0-7.2mg/dl	6.10mg/dl
BUN/SR.CREATININE RATIO	9:1-23:1 RATIO	29.4:0 RATIO
CHOLESTEROL	140-200mg/dl	253mg/dl
TRIGLYCRIDE	60-160mg/dl	154mg/dl
CHOLESTEROL HDL	35-60 mg/dl	49mg/dl
CHOLESTEROL LDL	60-150 mg/dl	174mg/dl
VLDL	20-40 mg/dl	30mg/dl
LDL/HDL Ratio	1.71-2.5mg/dl	3.5mg/dl
CHOLESTEROL/HDL Ratio	4.0:1-4.16:1 mg/dl	5.1:1mg/dl

Recommendation:

1. This report is not valid for medico legal purposes.


REPORT CHECKED BY
KULWINDER KAUR
MSC (MLT)
REG.NO-388-FHPxpar(mg)2018


DR.SURBHI GOYAL
M.B.B.S MD (Pathology)
CONSULTANT PATHOLOGIST

NAME : RAMAN SHARMA
 AGE/SEX : 51Y/M
 REF BY : BANK OF BARODA
 DATE : 09.11.2024

HbA1C

Test name	results	units
HbA1c{GLYCOSYLATED HEMOGLOBIN}BLOOD	5.50	%

Interpretation

As per American Diabetes association {ADA}	
Reference Group	HbA1c in %
Non diabetic adults >=18 years	4.0 - 6.0
At risk	> = 6.0 to < = 6.5
Diagnosing diabetes	>6.5
Therapeutic goals for glycemic Control	Adults Goal of therapy : < 7.0 Action suggested : >8.0

Note : 1. Since HbA1c reflects long term fluctuations in the blood glucose concentration, a diabetic patient who is recently under good control may still have a high concentration of HbA1c. Converse is true for a diabetic previously under good control but now poorly controlled.

2. target goals of < 7.0 % may be beneficial in patients with short duration of diabetes , long life expectancy and no significant cardiovascular disease. In patient with significant complications of diabetes , limited life expectancy or extensive co-morbid conditions, targeting a goal of < 7.0 % may not be appropriate.

Comments

HbA1c provides an index of average blood glucose level over the past 8-12 weeks & is a much better indicator of long term glycaemic as compared to blood & urinary glucose determinations.

ADA criteria for correlation between HbA1c & Mean plasma glucose levels

HbA1c %	Mean plasma glucose {mg/dl }	HbA1c %	Mean plasma glucose {mg/dl }
5	98	9	212
6	126	10	240
7	154	11	269
8	183	12	298

Recommendation:-

1. This report is not valid for medico legal purposes.
2. The test can be repeated free of cost in case of any discrepancy.
3. Test to be clinically correlated.
4. All card tests require confirmation by serology
5. False negative or false positive results may occur in some cases.

Kaur
09/11/24

REPORT CHECKED BY
 KULWINDER KAUR
 MSC (MLT)
 REG.NO-388-FHPxpar(mg)2018

Surbhi
 DR.SURBHI GOYAL
 M.B.B.S MD (Pathology)
 CONSULTANT PATHOLOGIST
 Dr. SURBHI GOYAL
 M.B.B.S. M.D.
 CONSULTANT PATHOLOGIST
 - No 40195


NAME : RAMAN SHARMA
AGE/SEX : 51Y/M
REF BY : BANK OF BARODA
DATE : 09.11.2024


BLOOD EXAMINATION REPORT

DETERMINATION	NORMAL	RESULT
CALCIUM	8.5-10.4mg/dl	9.2mg/dl

Recommendation:-

1. This report is not valid for medico legal purposes.
2. The test can be repeated free of cost in case of any discrepancy.
3. Test to be clinically correlated.
4. All card tests require confirmation by serology
5. False negative or false positive results may occur in some cases


REPORT CHECKED BY
KULWINDER KAUR
MSC (MLT)
REG.NO-388-FIHPxpar(mg)2018

DR.SURBHI GOAL
M.B.B.S MD (Pathology)
CONSULTANT PATHOLOGIST

Dr. SURBHI GOAL
M.B.B.S M.D (PATHOLOGY)
CONSULTANT PATHOLOGIST

NAME : RAMAN SHARMA
AGE/SEX : 51Y/M
REF BY : BANK OF BARODA
DATE : 09.11.2024


TEST ASKED : -T3,T4,TSH

<u>TEST NAME</u>	<u>RESULT</u>	<u>NORMAL RANGE</u>
T3	1.00 ng/ml	0.70-2.04 ng/ml
T4	7.12µg/dl	4.6-10.5 µg/dl
TSH	1.226µIU/ml	0.40-4.20µIU/ml

Recommendation:-

1. This report is not valid for medico legal purposes.
2. The test can be repeated free of cost in case of any discrepancy.
3. Test to be clinically correlated.
4. All card tests require confirmation by serology
5. False negative or false positive results may occur in some cases


REPORT CHECKED BY
KULWINDER KAUR
MSC (MLT)
REG.NO-388-FHIPxpar(mg)2018


DR.SURBHI GOYAL
M.B.B.S MD (Pathology)
CONSULTANT PATHOLOGIST

NAME : RAMAN SHARMA
AGE/SEX : 51Y/M
REF BY : BANK OF BARODA
DATE : 09.11.2024

<u>TEST NAME</u>	VALUE	UNITS
PROSTATE SPECIFIC ANTIGEN (PSA)	0.49	ng/ml

Technology : C.L.I.A

REFERENCE RANGE:

NORMAL: 0 to 4 ng/ml

Border Line: 4.01 to 10.00 ng/ml

Recommendation:-

1. This report is not valid for medico legal purposes.
2. The test can be repeated free of cost in case of any discrepancy.
3. Test to be clinically correlated.
4. All card tests require confirmation by serology
5. False negative or false positive results may occur in some cases.

Kaur
9/11/24

REPORT CHECKED BY
KULWINDER KAUR
MSC (MLT)
REG.NO-388-FIIPxpar(mg)2018

DR. SURBHI KUMAR
M.B.B. (Pathology)
CONSULTANT PATHOLOGIST
CONSULTANT PATHOLOGIST
No. 10


NAME : RAMAN SHARMA
AGE/SEX : 51Y/M
REF BY : BANK OF BARODA
DATE : 09.11.2024


URINE EXAMINATION REPORT

A. PHYSICAL EXAMINATION	
QUANTITY	30ml
COLOUR	P. YELLOW
DEPOSIT	ABSENT
REACTION	ACIDIC
SECIFIC GRAVITY	1.020
B. CHEMICAL EXAMINATION	
UROBILINOGEN	NIL
BLOOD	NIL
PROTEIN	NIL
SUGAR	NIL
KETONE BODIES	NIL
BILIRUBIN	NIL
NITRITE	NIL
LEUKOCYTES	NIL
C. MICROSCOPIC EXAMINATION	
EPITHELIAL CELLS	0-1/hpf
PUS CELLS	1-2/hpf
R.B.C.	NIL
CRYSTALS	NIL
CAST	NIL

Recommendation:-

1. This report is not valid for medico legal purposes.
2. The test can be repeated free of cost in case of any discrepancy.
3. Test to be clinically correlated.
4. All card tests require confirmation by serology
5. False negative or false positive results may occur in some cases


REPORT CHECKED BY
KULWINDER KAUR
MSC (MLT)
REG.NO-388-FHPxpar(mg)2018


DR. SURBHI GOYAL
M.B.B.S M.D. Pathology
CONSULTANT PATHOLOGIST


NAME : RAMAN SHARMA
AGE/SEX : 51Y/M
REF BY : BANK OF BARODA
DATE : 09.11.2024

URINE EXAMINATION REPORT

DETERMINATION	NORMAL	RESULT
POST URINE SUGAR	NIL	NIL

*Recommendation:-

1. This report is not valid for medico legal purposes.
2. The test can be repeated free of cost in case of any discrepancy
3. Test to be clinically correlated.
4. All card tests require confirmation by serology
5. False negative or false positive results may occur in some cases


REPORT CHECKED BY
KULWINDER KAUR
MSC (MLT)
REG.NO-388-FHPxpar(mg)2018


DR.SURBHEER GOYAL
M.B.B.S MD (Pathology)
CONSULTANT PATHOLOGIST

Name : RAMAN SHARMA
Age/Sex : 51YRS/M
Date : 9/11/2024

X-ray Chest PA View

The cardiac size and shape is **enlarged**.

Both hilla are normal.

The lungs on either side show equal translucency

The peripheral vasculature is normal

The domes of the diaphragm is normal

The pleural spaces are normal.

Cardiomegaly

Dr. R.S. Maheshwari

M.B.B.S. M.D. (Paed) P.C.M.S. (Ex.) M.I.A.P.

Senior Physician & Child Specialist

DR. R. S. MAHESHWARI

M.B.B.S. M.D.

Reg No. 34970

Patient's Name : RAMAN SHARMA

DATE : 09/11/2024

Age/Sex : 51 Yrs/M

ULTRASONOGRAPHY OF ABDOMEN

LIVER : Liver is normal in size & shape and shows fatty infiltration. Hepatic biliary radicals are normally outlined. Portal vein is normal in caliber. No evidence of liver abscess. Movements of diaphragm are not restricted. No evidence of secondaries. CBD is of normal calibre.

GALL BLADDER : Gall Bladder is distended. Walls are normal. Lumen shows normal echo.

PANCREAS : Pancreas is normal in size, shape and echotexture. No evidence of any collection in lesser sac.

SPLEEN : Spleen is normal in size, shape and echotexture. Calibre splenic vein at hilum is WNL.

RIGHT KIDNEY : : Right kidney is normal in size & shape. Cortical thickness is WNL. Pelvi-calyceal system is normal. There is no evidence of a calculus. No backpressure changes or S.O.L. Corticomedullary differentiation is well maintained.

LEFT KIDNEY : Left kidney is normal in size & shape. Cortical thickness is WNL. Pelvi-calyceal system is normal. There is no evidence of a calculus. No backpressure changes or S.O.L. Corticomedullary differentiation is well maintained.

URETERS: Both ureter are normal and not dilated

URINARY BLADDER : UB is seen filled stage. lumen is echo free walls are normal.

PROSTATE : Prostate medium lobe is enlarged in size. No focal lesion seen.

IMPRESSION:- GRADE - I FATTY LIVER // MILD PROSTATOMEGALY.

Adv... PSA.

Dr. R. S. Maheshwari
M.B.B.S., M.D (Paed)

DR.R.S. MAHESHWARI

MBBS, MD [PAED]

Registration No. : - 34970

Reg. No. DAA/LDH/21/346

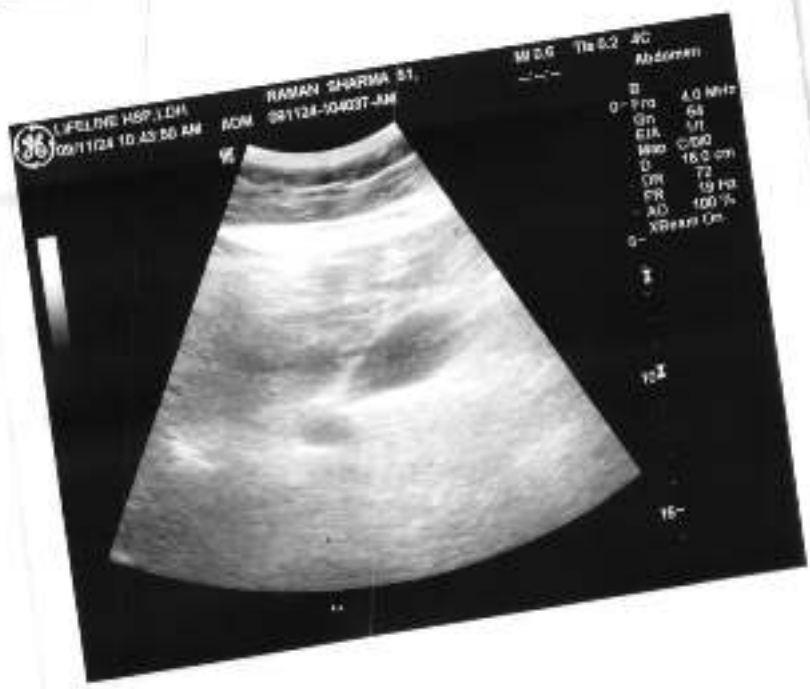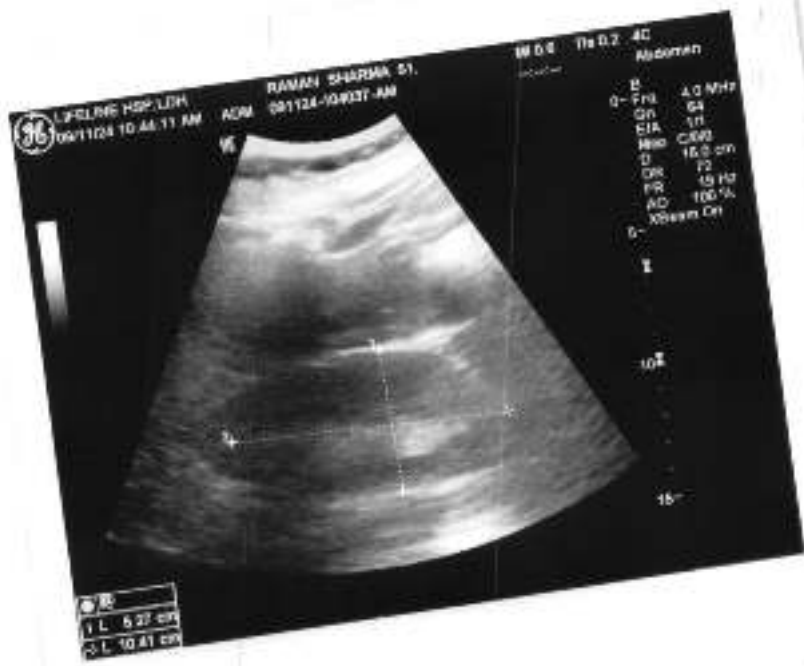ULTRASONOLOGIST :-

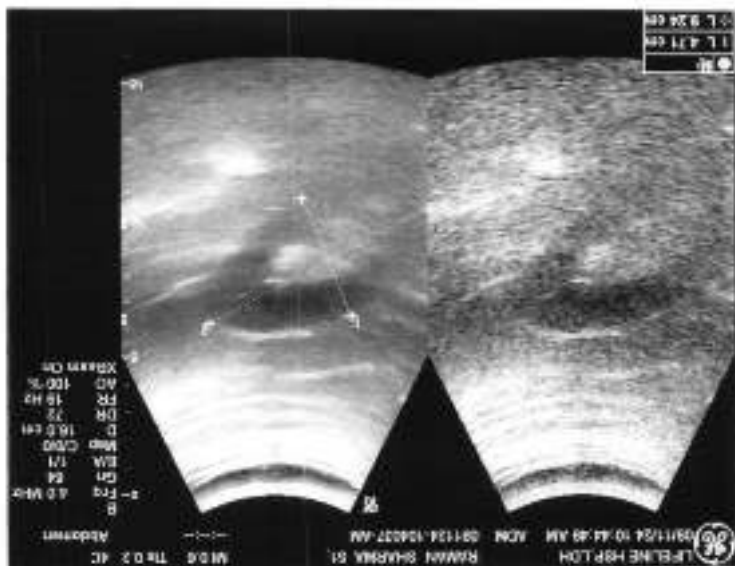
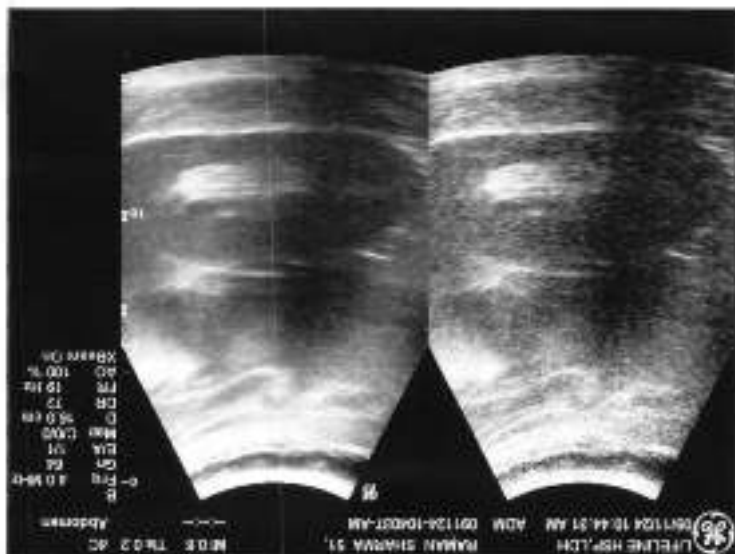correlated clinically.

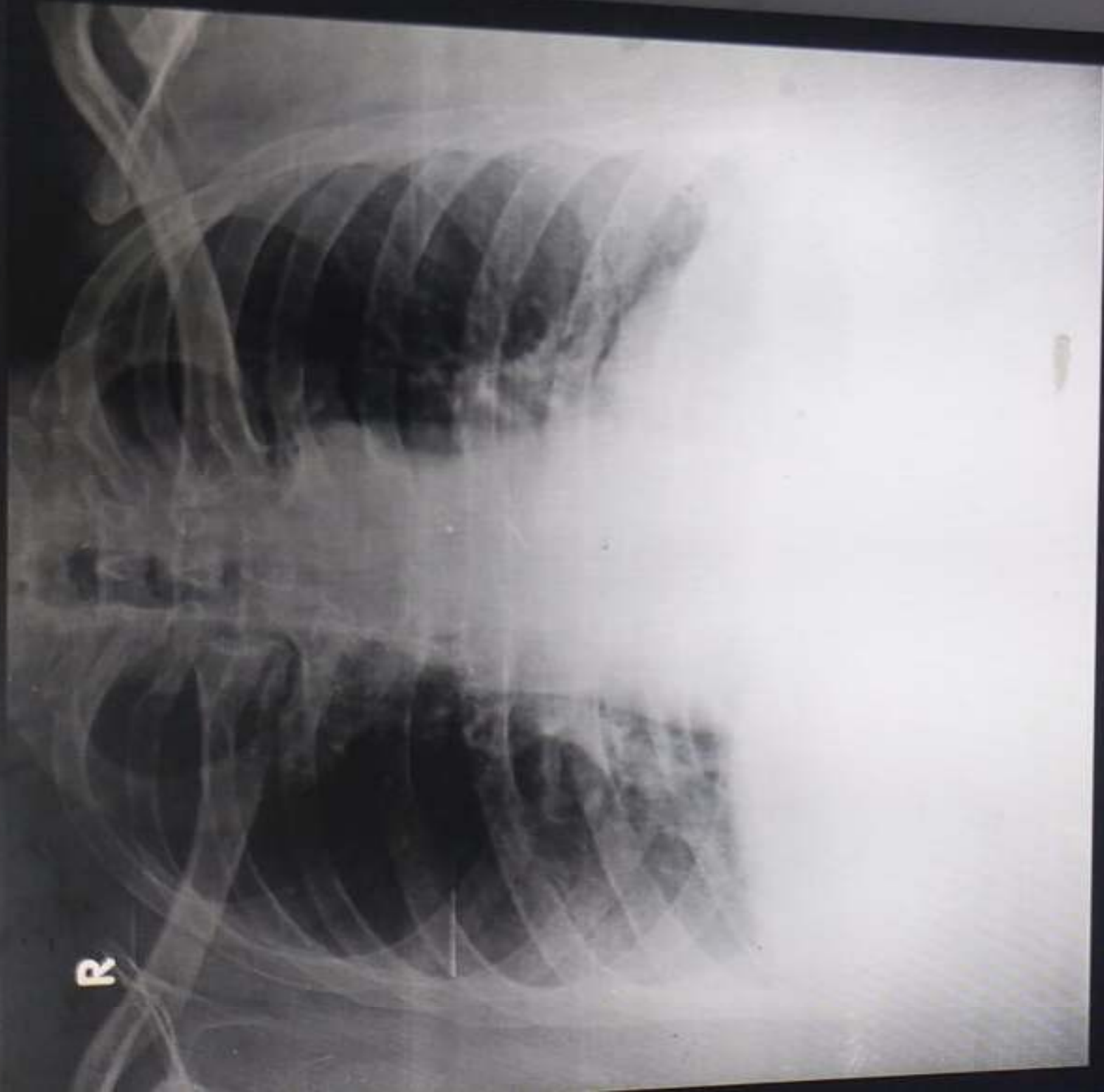
LIFE LINE HOSPITAL

GILL ROAD, LUDHIANA-141003

Reg. No. DAA/LDH/21/346







RAMAN SHARMA 51 8002 M CHEST,FRN P->A 09-11-2024 11:42 AM
LIFELINE HOSPITAL, GILL ROAD ,LUDHIANA