

Stool sample not done



Seshan

Chandan Diagnostic Center  
99, Shivaji Nagar, Mahmooorganj  
Varanasi-221010 (U.P.)  
Phone No.: 0542-2223232






This report is not for medico legal purpose. If clinical correlation is not established, kindly repeat the test at no additional cost within seven days.  
Facilities: Pathology, Bedside Sample Collection, Health Check-ups, Digital X-Ray, ECG (Bedside also), Allergy Testing, Test And Health Check-ups, Ultrasonography, Sonomammography, Bone Mineral Density (BMD), Doppler Studies, 2D Echo, CT Scan, MRI, Blood Bank, TMT, EEG, PFT, OPG, Endoscopy, Digital Mammography, Electromyography (EMG), Nerve Conduction Velocity (NCV), Audiometry, Brainstem Evoked Response Audiometry (BERA), Colonoscopy, Ambulance Services, Online Booking Facilities for Diagnostics, Online Report Viewing \*  
\*Facilities Available at Select Location



Dr. Ravesh Chandra Roy (MD-Radio)



Results to Follow:  
COMPLETE BLOOD COUNT (CBC), Blood Group (ABO & Rh typing), URINE EXAMINATION, ROUTINE, STOOL, ROUTINE EXAMINATION, GLUCOSE FASTING, GLUCOSE PP, SUGAR, FASTING STAGE, SUGAR, PP STAGE, GLYCOSYLATED HAEMOGLOBIN (HBA1C), THYROID PROFILE - TOTAL, LIPID PROFILE (MINI), Uric Acid, BUN (Blood Urea Nitrogen), CREATININE SERUM, L.F.T.(WITH GAMMA GT), ECG/EKG, X-RAY DIGITAL CHEST PA, PSA (Prostate Specific Antigen), Total, TREADMILL TEST

\*\*\* End Of Report \*\*\*

Please correlate clinically

- Fatty infiltration liver.
- Rest of the abdominal organs are normal.

IMPRESSION :

- The liver measures 14.3 cm in mid clavicular line. Mild diffuse increase in liver echogenicity seen. No focal lesion is seen. No intra hepatic biliary radicle dilatation seen.
- Gall bladder is well distended and is normal.
- Portal vein measures 9.5 mm in caliber. CBD measures 3.4 mm in caliber.
- Pancreas is normal in size, shape and echogenicity.
- Spleen is normal in size ( 7.2 cm in its long axis), shape and echogenicity.
- Right kidney is normal in size, shape and echogenicity. No focal lesion or calculus seen. Right pelvicalyceal system is not dilated. Right kidney measures : 8.9 x 3.6 cm.
- Left kidney is normal in size, shape and echogenicity. No focal lesion or calculus seen. Left pelvicalyceal system is not dilated. Left kidney measures : 9.2 x 4.5 cm.
- Urinary bladder is partially filled. Prevoid urine volume 15 cc.
- The prostate is normal in size ( 37 x 32 x 27 mm / 18gms), shape and echopattern.
- No free fluid is seen in the abdomen/pelvis.

ULTRASOUND WHOLE ABDOMEN (UPPER & LOWER) \*

DEPARTMENT OF ULTRASOUND  
MEDIWHEEL BANK OF BARODA MALE ABOVE 40 YRS

Ref Doctor	: Dr.Mediwheel - Arcofemi Health Care Ltd.	Status	: Status
Visit ID	: CVAR0052042122	Reported	: 17/Aug/2021 10:19:35
UHD/MR NO	: CVAR.000021171	Received	: N/A
Age/Gender	: 52 Y 0 M 0 D /M	Collected	: N/A
Patient Name	: Mr.KRISHNA GOPAL KESHARI - PKG10000	Registered On	: 17/Aug/2021 09:43:34
			: Final Report


CHANDAN DIAGNOSTIC CENTRE

Add: 99, Shivaji Nagar Mahmoorganj, Varamasi  
Ph: 9235447795, 0542-2223232  
CIN : U85110DL2003PLC308206





This report is not for medico legal purpose. If clinical correlation is not established, kindly repeat the test at no additional cost within seven days.  
Facilities: Pathology, Bedside Sample Collection, Health Check-ups, Digital X-Ray, ECG (Bedside also), Allergy Testing, Test And Health Check-ups, Ultrasonography, Sonomammography, Bone X-Ray, Bone Density (BMD), Doppler Studies, 2D Echo, CT Scan, MRI, Blood Bank, TMT, EEG, PFT, OPG, Endoscopy, Digital Mammography, Electromyography (EMG), Nerve Conduction Velocity (NCV), Audiology, Brainstem Evoked Response Audiometry (BERA), Colonoscopy, Ambulance Services, Online Booking Facilities for Diagnostics, Online Report Viewing  
\*Facilities Available at Select Location on



DR AP YADAV  
MD (CARDIOLOGIST)

COMPLETE BLOOD COUNT (CBC), Blood Group (ABO & Rh typing), URINE EXAMINATION, ROUTINE, STOOL, ROUTINE EXAMINATION, GI UCOSF FASTING, GI UCOSF PP, SUGAR, FASTING STAGE, SUGAR, PP STAGE, GI UCOSF ATFD HAFMOGI OBIN (HBAIC), THYROID PROFILE - TOTAL, LIPID PROFILE ( MINI ), Uric Acid, BUN (Blood Urea Nitrogen), CREATININE SERUM, L.F.T.(WITH GAMMA GT), X-RAY DIGITAL CHEST PA, PSA (Prostate Specific Antigen), Total, TREAD MILL TEST

\*\*\* End Of Report \*\*\*

FINAL IMPRESSION

Likely Electrolyte Imbalance, Sinus Rhythm.

9. T - Wave	Normal
8. S - T Segment	Normal
7. QT c Interval	Normal
6. QRS	Normal
5. P R Interval	Normal
4. P - Wave	Normal
3. Ventricular Rate	72/min
2. Atrial Rate	72/min
1. Mechanism, Rhythm	Sinus, Regular

ECG / EKG \*

DEPARTMENT OF CARDIAC

MEDIWHEEL BANK OF BARODA MALE ABOVE 40 YRS

Ref Doctor	: Dr. Mediwheel - Arcotemi Health Care Ltd.	Status	: Reported
Visit ID	: CVAR0052042122	Received	: N/A
UHD/MR NO	: CVAR.0000021171	Collected	: N/A
Age/Gender	: 52 Y O M O D /M	Registered On	: 17/Aug/2021 09:43:34
Patent Name	: Mr. KRISHNA GOPAL KESHARI - PKG10000	Registered On	: 17/Aug/2021 09:43:34



Add: 99, Shivaji Nagar Mahmoodorganj, Varanasi  
Ph: 9235447795, 0542-2223232  
CIN : U85110DL2003PLC308206



CHANDAN DIAGNOSTIC CENTRE



**CHANDAN DIAGNOSTIC CENTRE**

Name of Company: Bank of Baroda, (Medicines)  
Name of Executive: Krishna Gopal Keshari  
Date of Birth: 01-01-1969  
Sex: Male

Height: 168 cm

Weight: 50 kg

BMI (Body Mass Index): 17.7

Chest (Expiration / Inspiration): 78/82 cm

Abdomen: 76 cm

Blood Pressure: 130/86

Pulse: 86 bpm

RR: 21 per min

Ident Mark: Cut Hawk four Right Adhesive

Any Allergies: No

Vertigo: No

Any Medications: (1) Tab - Andes-80 - 5 started - AM - For hypertension

- 2 yrs - Dr. Manoj kr. (OPD)  
(1) fracture of Lt. Phalanges Bone (cut 2)  
- 1020 - Treatment on  
(1) chewing tobacco - 80 mg - 10 pack/day.  
Chief Complaints if any: No

Lab Investigation Reports: Yes Att

Eye Check up vision & Color vision: Power - Rt eye = 0.25 D -  
Left eye: vision less - ~~both~~ since birth.  
Right eye: Normal c glasses

Near vision: Power Rt eye = +0.25 D.





Chandan Diagnostic Center  
99, Shivaji Nagar, Mahmooorganj  
Varanasi-221010 (U.P.)  
Phone No.: 0542-2223232

Date: 17-8-21 Place: VARANASI

Name & Qualification: Dr. R.C. Roy (MBBS, MD)

Signature of Medical Examiner

Dr. R.C. Roy  
MBBS, MD. (Radio Diagnosis)  
Reg. No. - 26918

Client Signature

Certified that I examined ... S/o or D/o ... Radheshyam Babbari is presently in good health and free from any cardio-respiratory/communicable ailment, he/she is Fit / Unfit to join any organization.

Final impression:

Far vision : Normal  
ENT consultation : Normal  
Dental Checkup : Normal (Tobacco stains)  
Eye Checkup : Normal (described Above)

CHANDAN DIAGNOSTIC CENTRE



भारत सरकार

GOVERNMENT OF INDIA

कृष्ण गोपाल केशरी

Krishna Gopal Keshari

जन्म तिथि/ DOB: 01/01/1969


पुरुष / MALE



*Handwritten signature in blue ink.*

7910 5879 6967

Chandan Diagnostic Center  
99, Shival Nagar, Mahmorganj,  
Varanasi-221010 (U.P.)  
Phone No.:0542-2223232  
Dr. R.C. Roy  
MBBS, MD. (Radio Diagnostics)  
Reg. No.-26918



GMT 04:36 AM

LOCAL 10:06 AM

ALTITUDE 64 FEET

TUESDAY 08.17.2021


25.305428°

Latitude

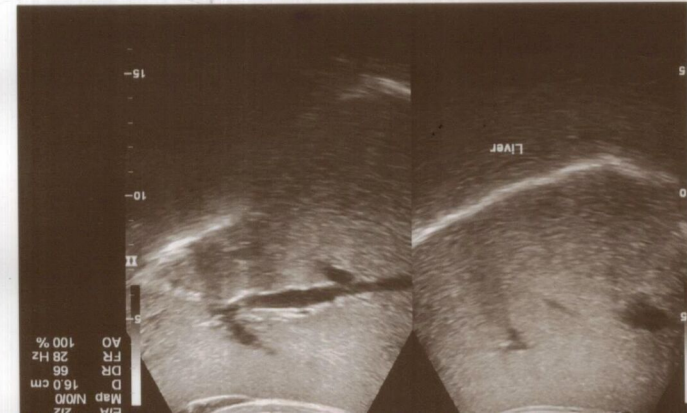
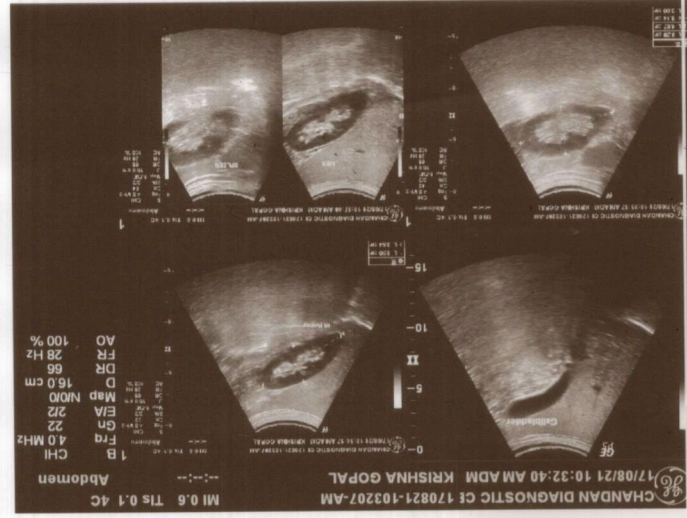
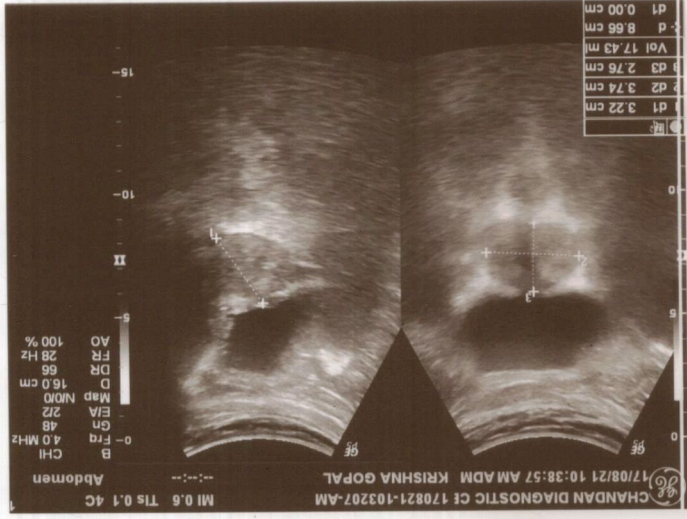
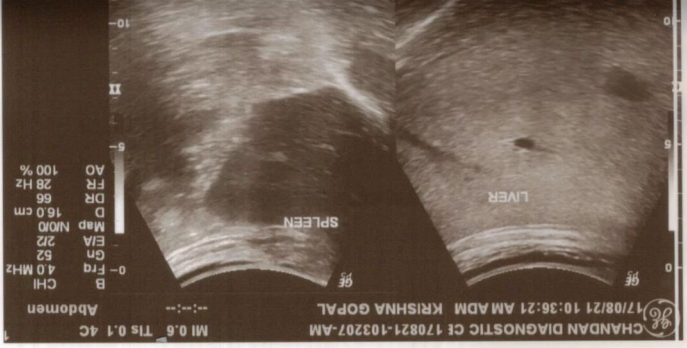
82.979116°

Longitude

P- 93, Shivaji Nagar Colony, Mahmooorganj,  
Varanasi, Uttar Pradesh 221010, India



**Dr. R.C. Roy**  
MBBS, MD (Radio Diagnosis)  
Reg. No. - 25913  
Shandan Diagnostic Center  
99, Shivaji Nagar, Mahmooorganj  
Varanasi-221010 (U.P.)  
Phone No.: 0542-2223232







# SURYA

Super Speciality Hospital  
(A unit of G. V. Meditech Pvt. Ltd.)

WE CARE

<b>Name:</b> Mr Krishna gopal keshari	<b>Gender:</b> Male	<b>Age:</b> 52 Yrs .
<b>UHID:</b> 72428	<b>Bill No:</b> 294748	<b>Lab No:</b>
<b>Ref By:</b> Self	<b>Date:</b> 17/08/2021	<b>Time:</b> 8.35 Pm

## X – RAY CHEST P A VIEW

Soft tissues & bones in view are normal.

Trachea and mediastinum are central.

Heart is normal in size .

B/L lung fields are normal seen.

B/L costophrenic angles are clear.

Both domes of diaphragms are normally seen.

Thoracic cage appears normal.

**IMPRESSION:** Normal study.  
Please correlate clinically.

**Radiologist**

The Emergency Helpline  
**0542-2220111**

D-63/6-K, Tulsipur (Near Akashwani), Mahmoorganj, Varanasi - 221010  
Phone : +91-542-2220770, 2220771, 2222416  
E-mail : info.suryahealthgroup@gmail.com | Website : www.suryahealthcare.in

