

2021/21/01

for medical permanent card



Report

(GEM213180307)(R)Allengers

Diwakar Diagnostic Centre
E-7/636, Arera Colony, Bhopal

899 / AMIT KUMAR BAGHEL / 44 Yrs / M / 0 Cms / 0 Kg Date: 10-Dec-2022 Refd By : BOB

Report :

TEST OBJECTIVE	: ROUTINE CHECKUP
RISK FACTOR	: MALE
ACTIVITY	: MODERATE ACTIVE
MEDICATION	: NONE
REASON FOR TERMINATION	: HEART RATE ACHIEVED
EXERCISE TOLERANCE	: GOOD
EXERCISE INDUCED ARRHYTHMIAS	: NO
HAEMODYNAMIC RESPONSE	: NORMAL
CHRONOTROPIC RESPONSE	: NORMAL
FINAL IMPRESSION	: STRESS TEST IS NEGATIVE FOR EXERCISE INDUCED ISCHAEMIC HEART DISEASE





Diwakar Diagnostic Centre
E-7/636, Arera Colony, Bhopal

899 / AMIT KUMAR BAGHEL / 44 Yrs / M / 0 Cms / 0 Kg Date: 10-Dec-2022 Refd By : BOB

Stage	Time	Duration	Belt Speed (mph)	Elevation	METs	Rate	% THR Achieved	BP	RPP	PVC	Comments
Supine	00:14	0:01	00.0	00.0	01.0	82	47 %	122/80	100	00	
Standing	00:22	0:01	00.0	00.0	01.0	82	47 %	122/80	100	00	
HV	00:33	0:01	00.0	00.0	01.0	080	45 %	122/80	097	00	
Warm Up	00:48	0:03	01.7	10.0	01.1	084	48 %	122/80	102	00	
ExStart	00:51	0:06	01.7	10.0	01.1	084	48 %	122/80	102	00	
BRUCE Stage 1	03:51	3:00	01.7	10.0	04.7	140	80 %	126/88	176	00	
BRUCE Stage 2	06:51	3:00	02.5	12.0	07.1	156	89 %	132/90	205	00	
PeakEx	06:56	0:07	00.0	00.0	07.2	158	90 %	132/90	208	00	
Recovery	07:55	1:00	00.0	00.0	01.2	120	68 %	126/88	151	00	
Recovery	08:55	2:00	00.0	00.0	01.0	099	56 %	122/82	120	00	
Recovery	09:55	3:00	00.0	00.0	01.0	096	55 %	122/82	117	00	
Recovery	10:06	3:10	00.0	00.0	01.0	093	53 %	122/82	113	00	

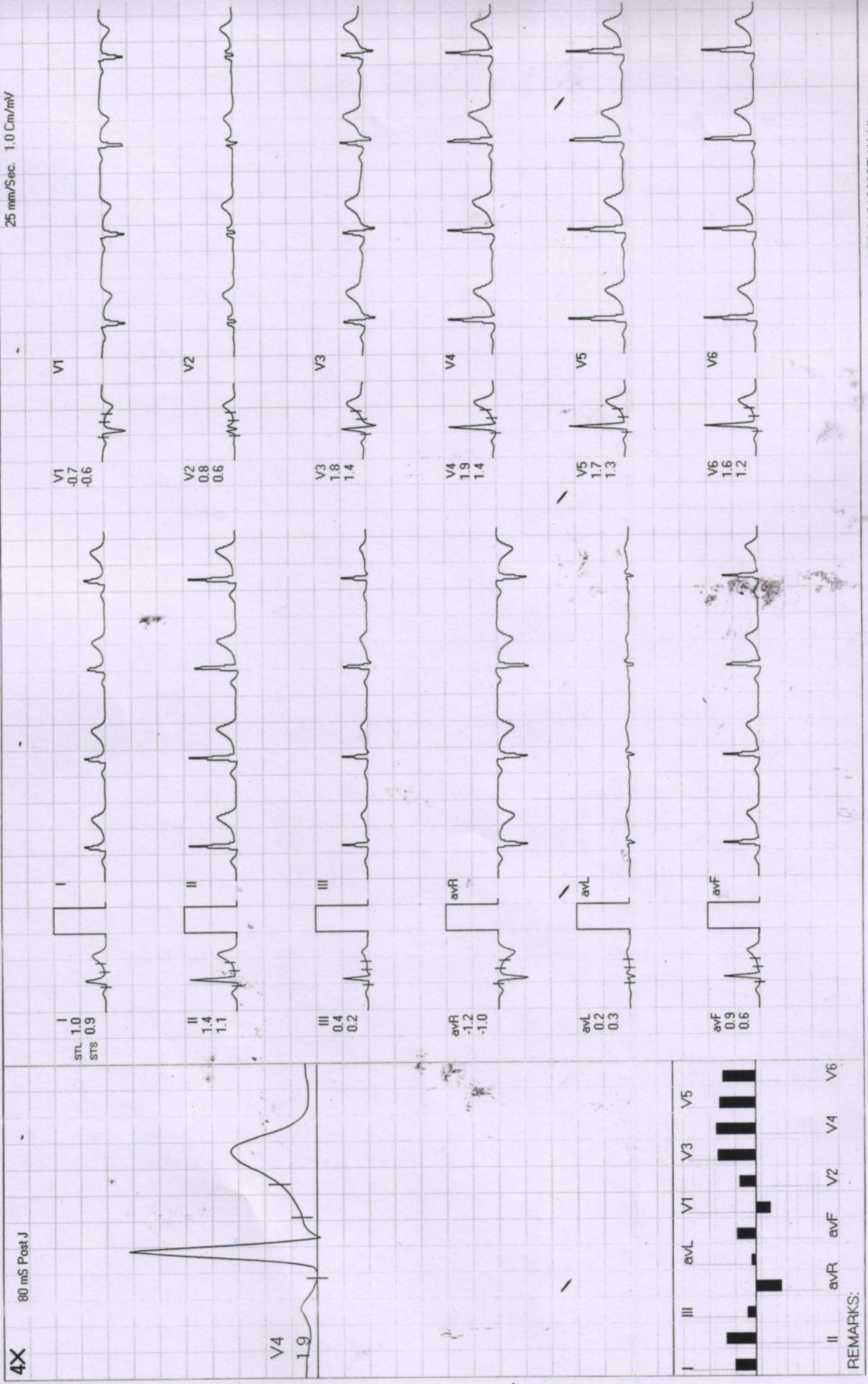
Findings :

- Exercise Time : 06:06
- Max HR Attained : 158 bpm 90% of Target 176
- Max BP Attained : (Sys) 132/90
- Max WorkLoad Attained : 7.2 Fair response to induced stress
- Test End Reasons : Heart Rate Achieved



Date: 10-Dec-2022 10:16:50 AM METS: 1.0/ 82 bpm 46% of THR BP: 122/80 mmHg Raw ECG/BLC On/ HF 0.05 Hz/LF 20 Hz

ExTime: 00:13 0.0 mph. 0.0%



STANDING

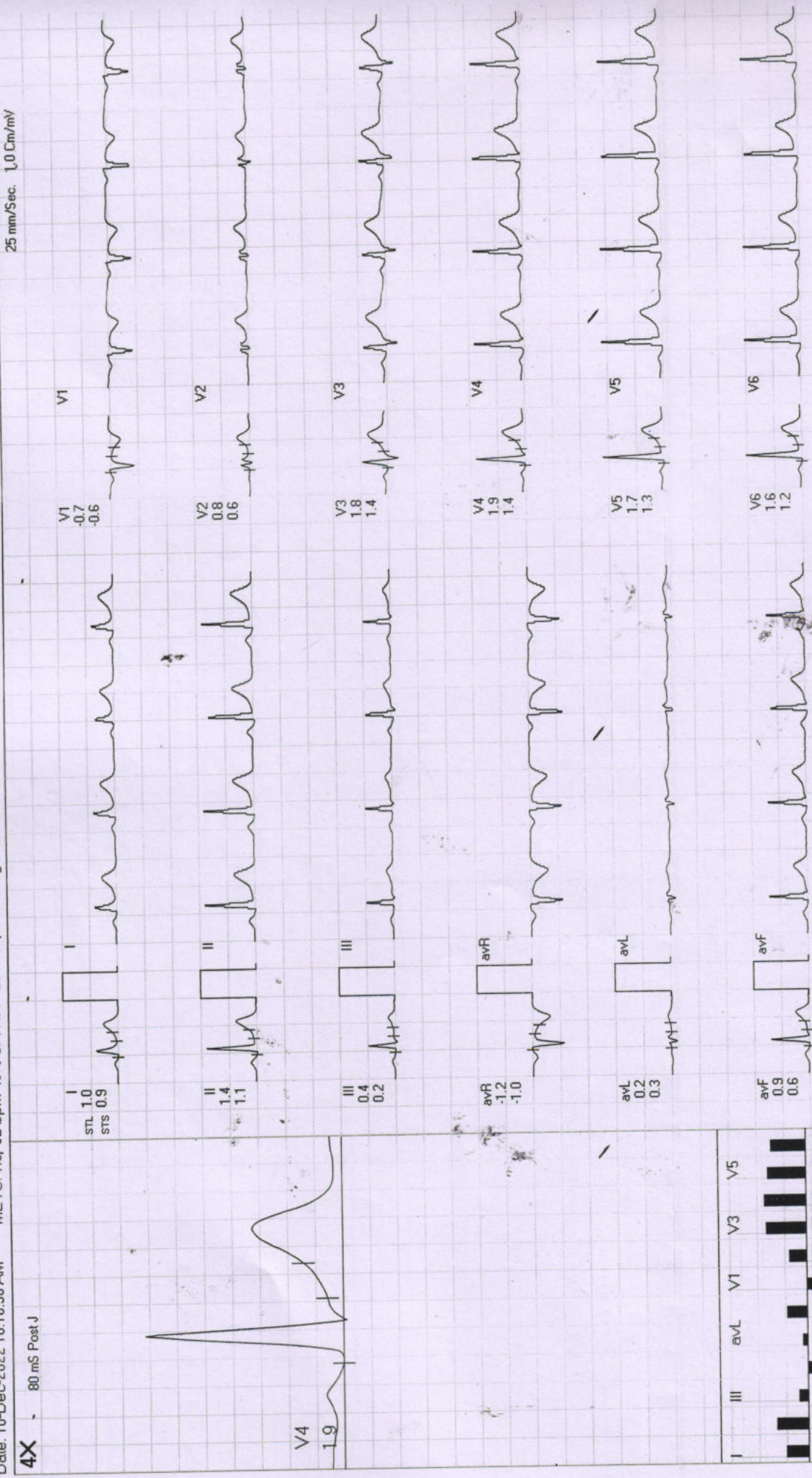


Diwakar Diagnostic Centre

899 / AMIT KUMAR BAGHEL / 44 Yrs / M

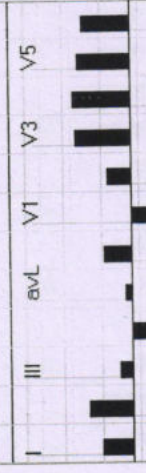Date: 10-Dec-2022 10:16:50 AM METS: 1.0/82 bpm 46% of THR BP: 122/80 mmHg Raw ECG/BLC On/ HF 0.05 Hz/LF 20 Hz

ExTime: 00:21 0.0 mph, 0.0%



4X - 80 mS Post J

V4 1.9

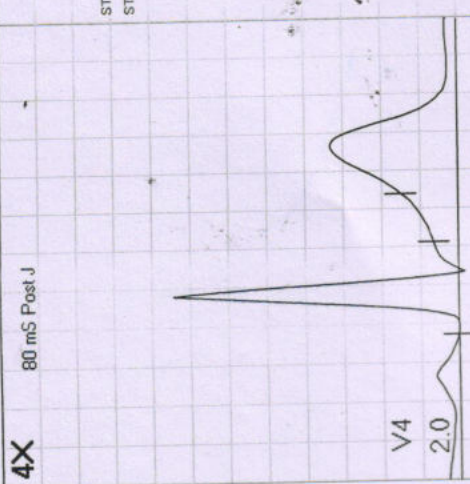
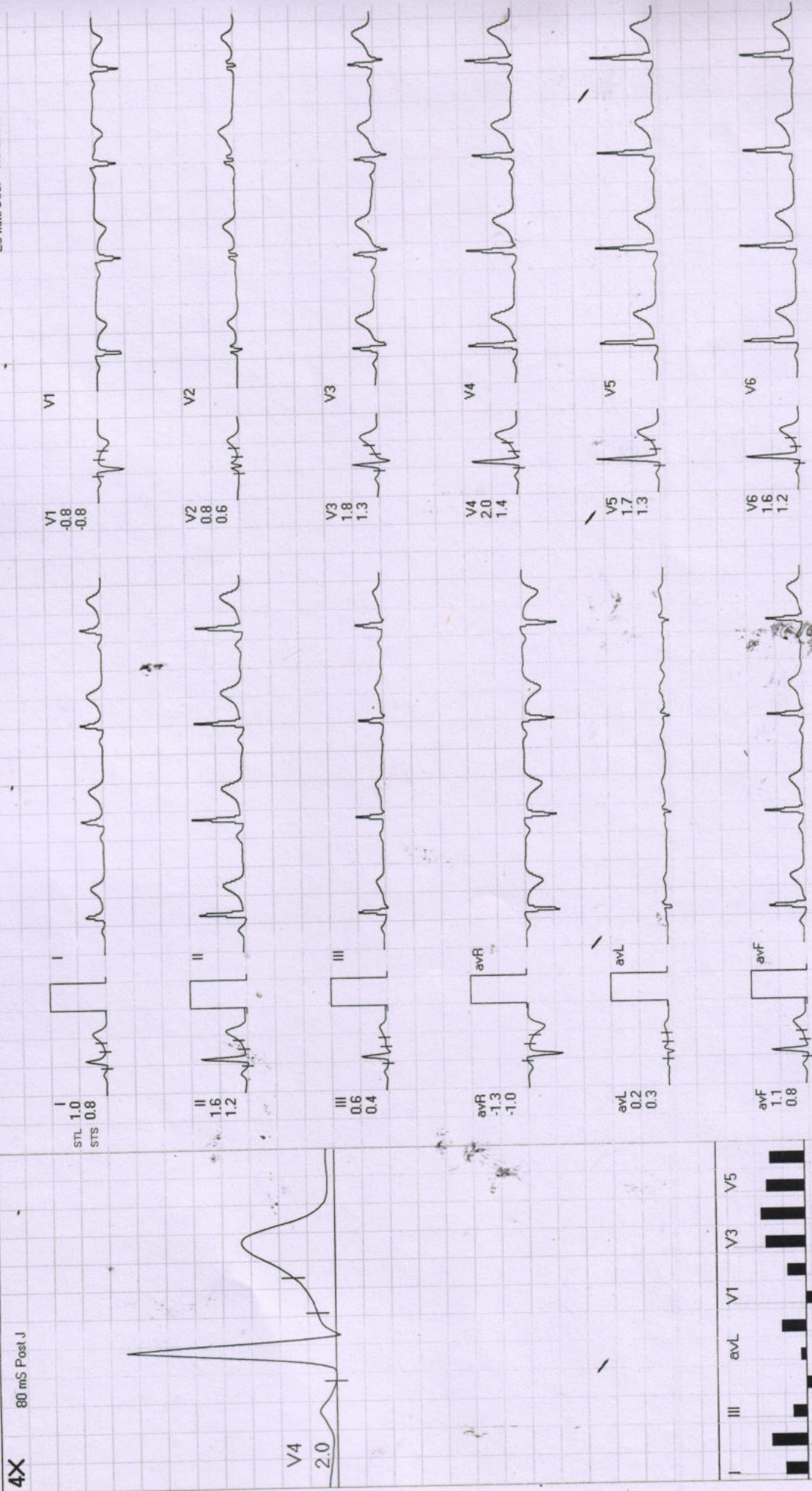


REMARKS:

(GEM213180307)(A)Allengers

Date: 10-Dec-2022 10:16:50 AM METS: 1.0/80 bpm 45% of THR BP: 122/80 mmHg Raw ECG/BLC On/ Notch On/ HF 0.05 Hz/LF 20 Hz

ExTime: 00:32 0.0 mph. 0.0%
25 mm/Sec. 1.0 Cm/mV

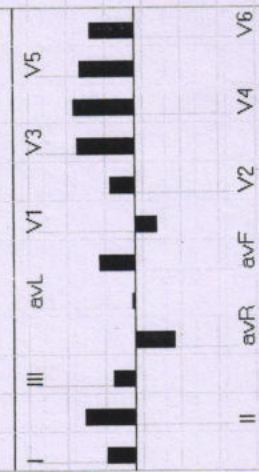
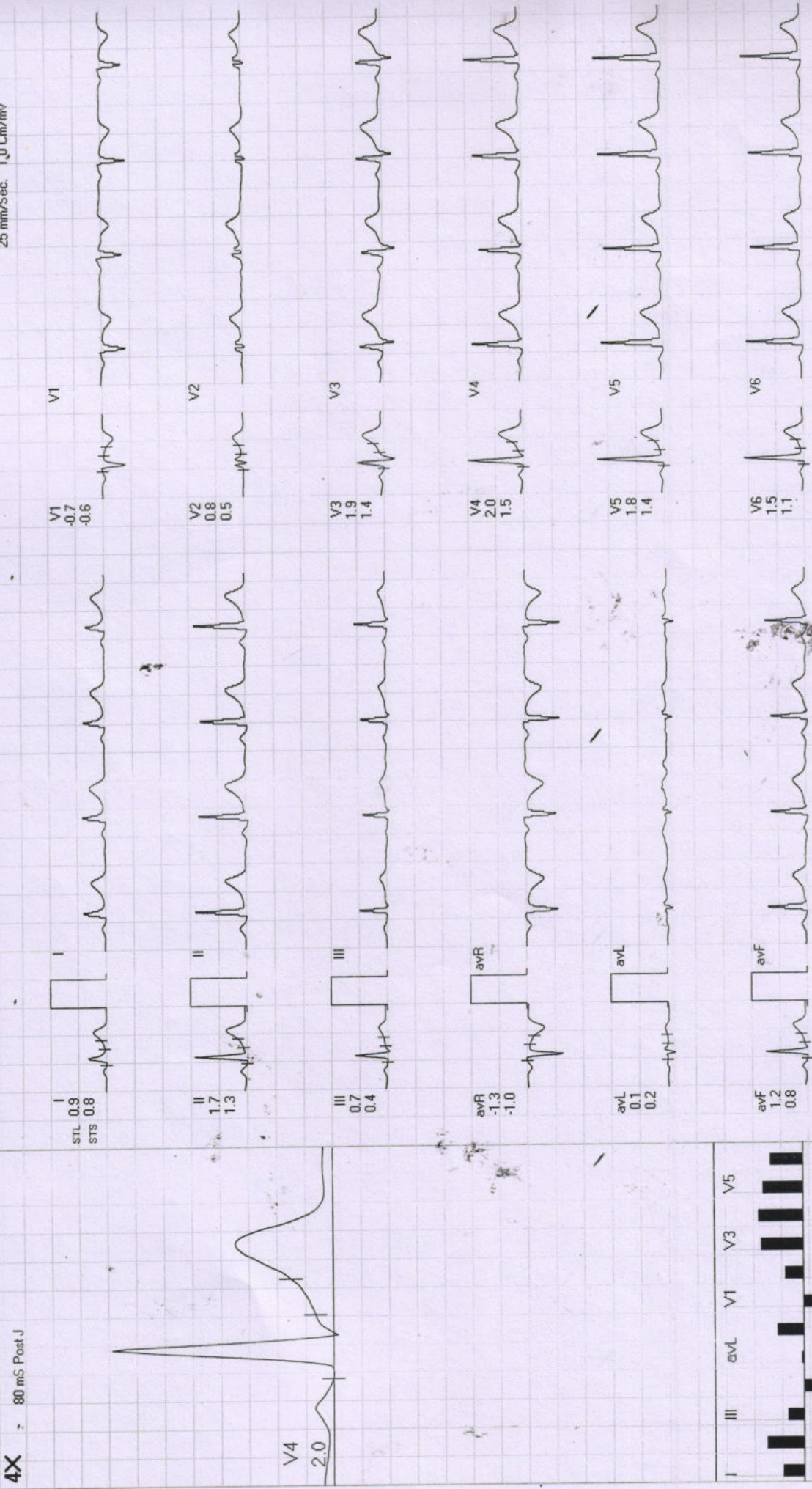


REMARKS:



Date: 10-Dec-2022 10:16:50 AM METS: 1.0 / 79 bpm 44% of THR BP: 122/80 mmHg Raw ECG/BLC On/ Natch On/ HF 0.05 Hz/LF 20 Hz

ExTime: 00:47 1.0 mph, 0.0%
25 mm/Sec. 1.0 Cm/mV

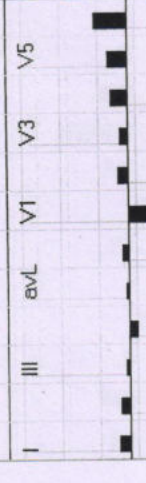
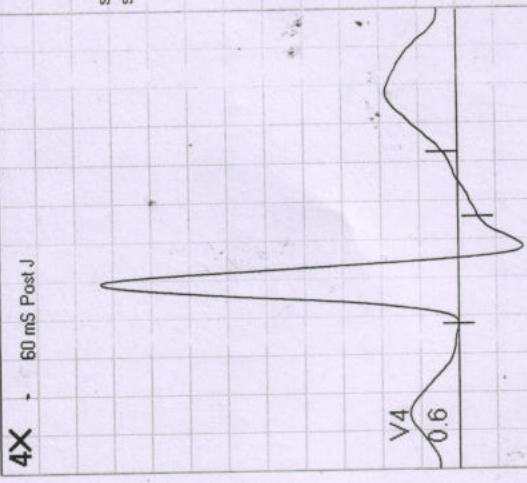
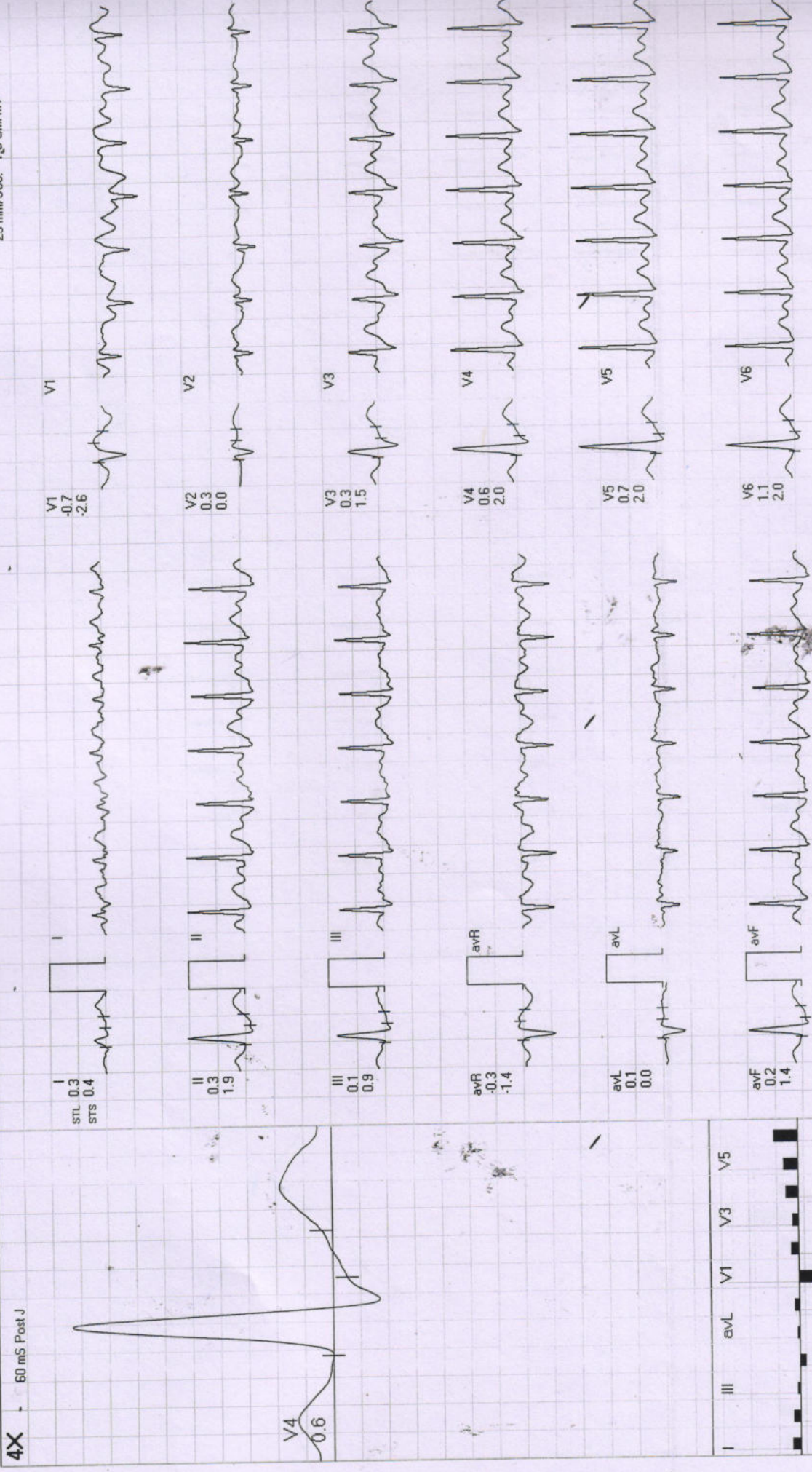


REMARKS:



ExTime: 03:00 1.7 mph, 10.0%
25 mm/Sec. 1.0 Cm/mV

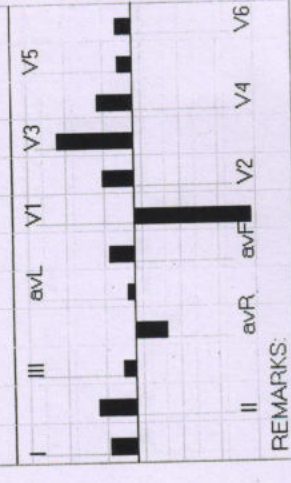
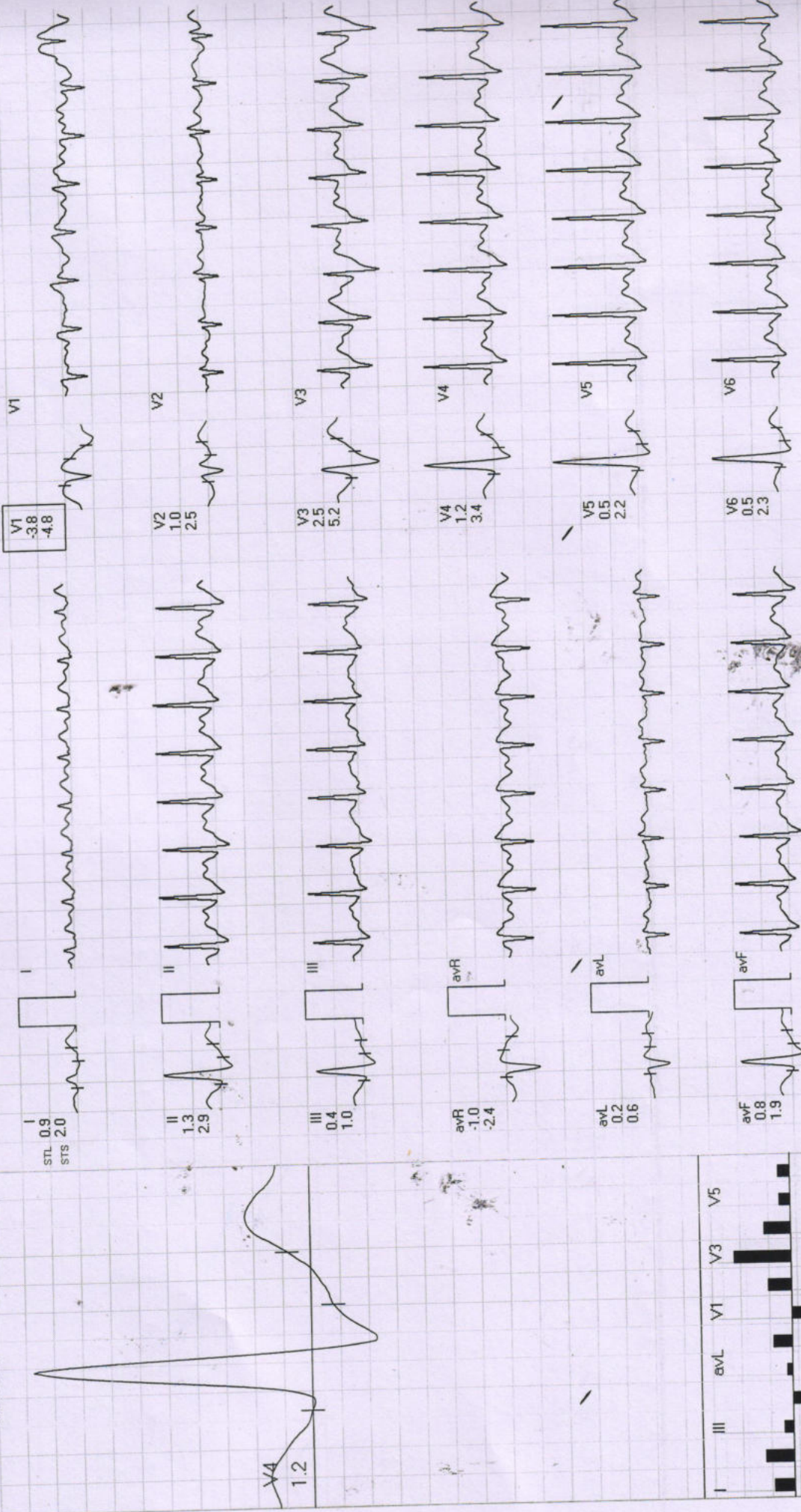
Date: 10-Dec-2022 10:16:50 AM METS: 4.7 / 140 bpm 79% of THR BP: 126/88 mmHg Raw ECG/BLC On/ HF 0.05 Hz/LF 20 Hz



REMARKS:

Date: 10-Dec-2022 10:16:50 AM METS: 7.1/156 bpm 88% of THR BP: 132/90 mmHg Raw ECG/BLC On/ Natch On/ HF 0.05 Hz/LF 20 Hz

4X 60 mS Post J








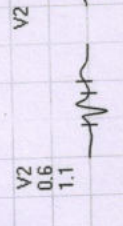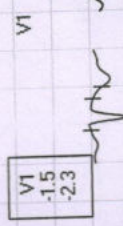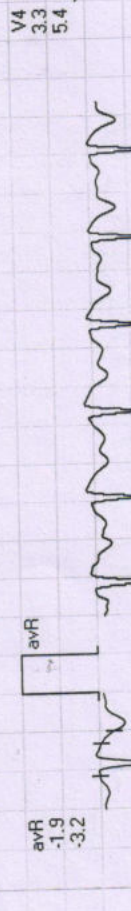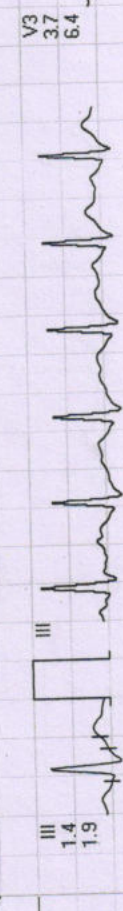
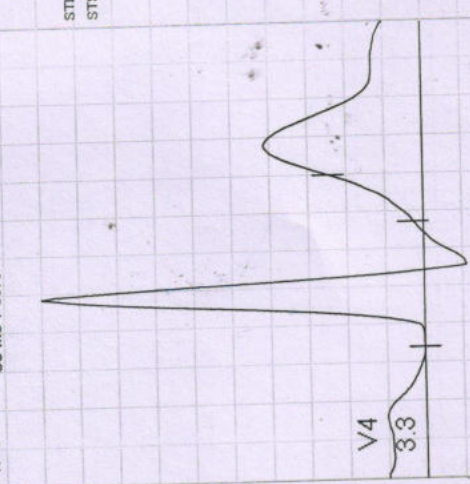
REMARKS:



ExtTime: 06:05 0.0 mph, 0.0%
25 mm/Sec. 1.0 Cm/mV

Date: 10-Dec-2022 10:16:50 AM METS: 1.1 / 120 bpm 68% of THR BP: 126/88 mmHg Raw ECG/BLC On/ Notch On/ HF 0.05 Hz/LF 20 Hz

4X 50 mS Post J



REMARKS:

Diwakar Diagnostic Centre


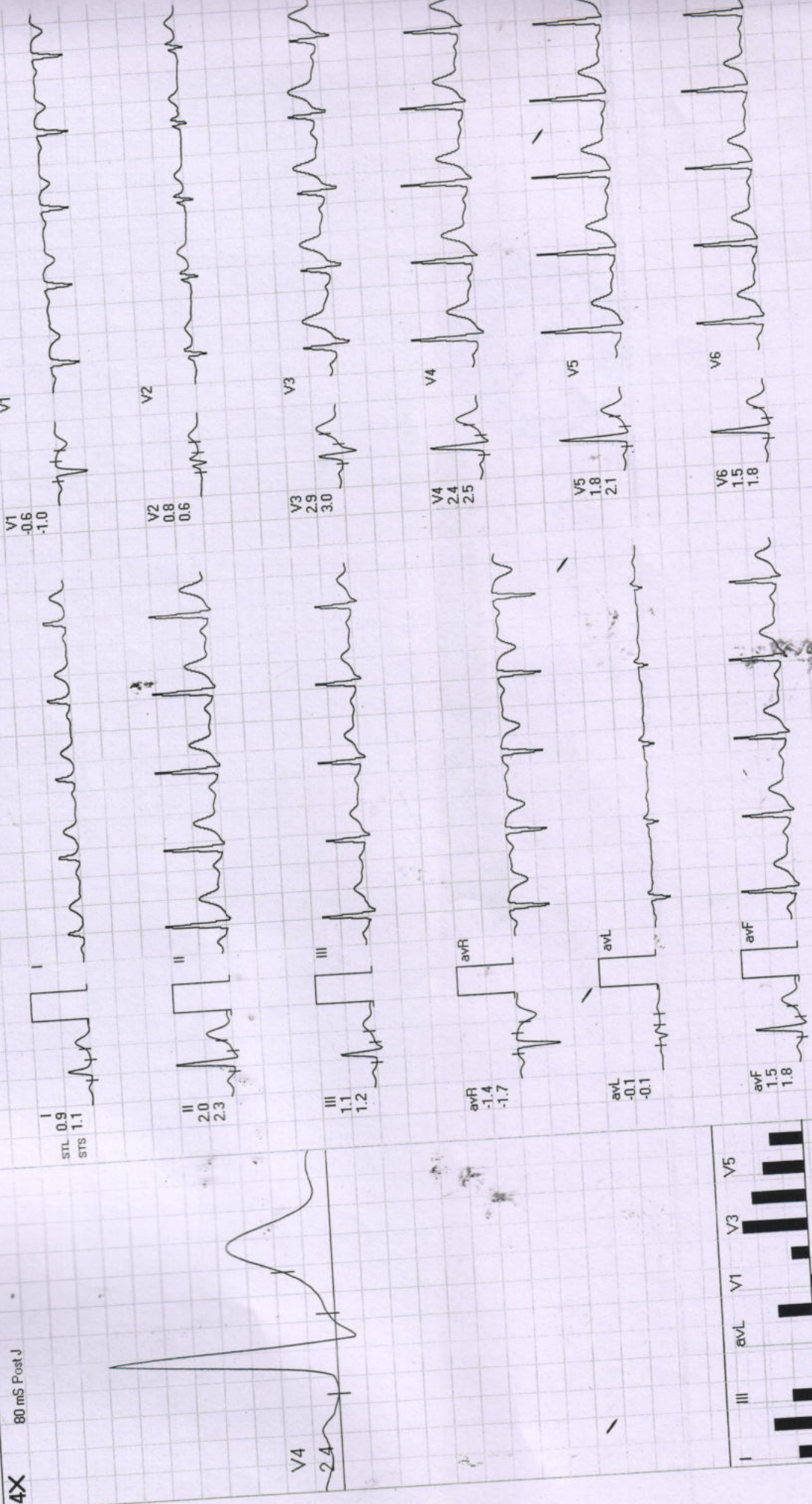
899 / AMIT KUMAR BAGHEL / 44 Yrs / M

ExTime: 06:05 0.0 mph, 0.0%

899 / AMIT KUMAR BAGHEL / 44 Yrs / M
Date: 10-Dec-2022 10:16:50 AM METS: 1.0/ 96 bpm 54% of THR BP: 122/82 mmHg Raw ECG/ BLC On/ HF 0.05 Hz/LF 20 Hz

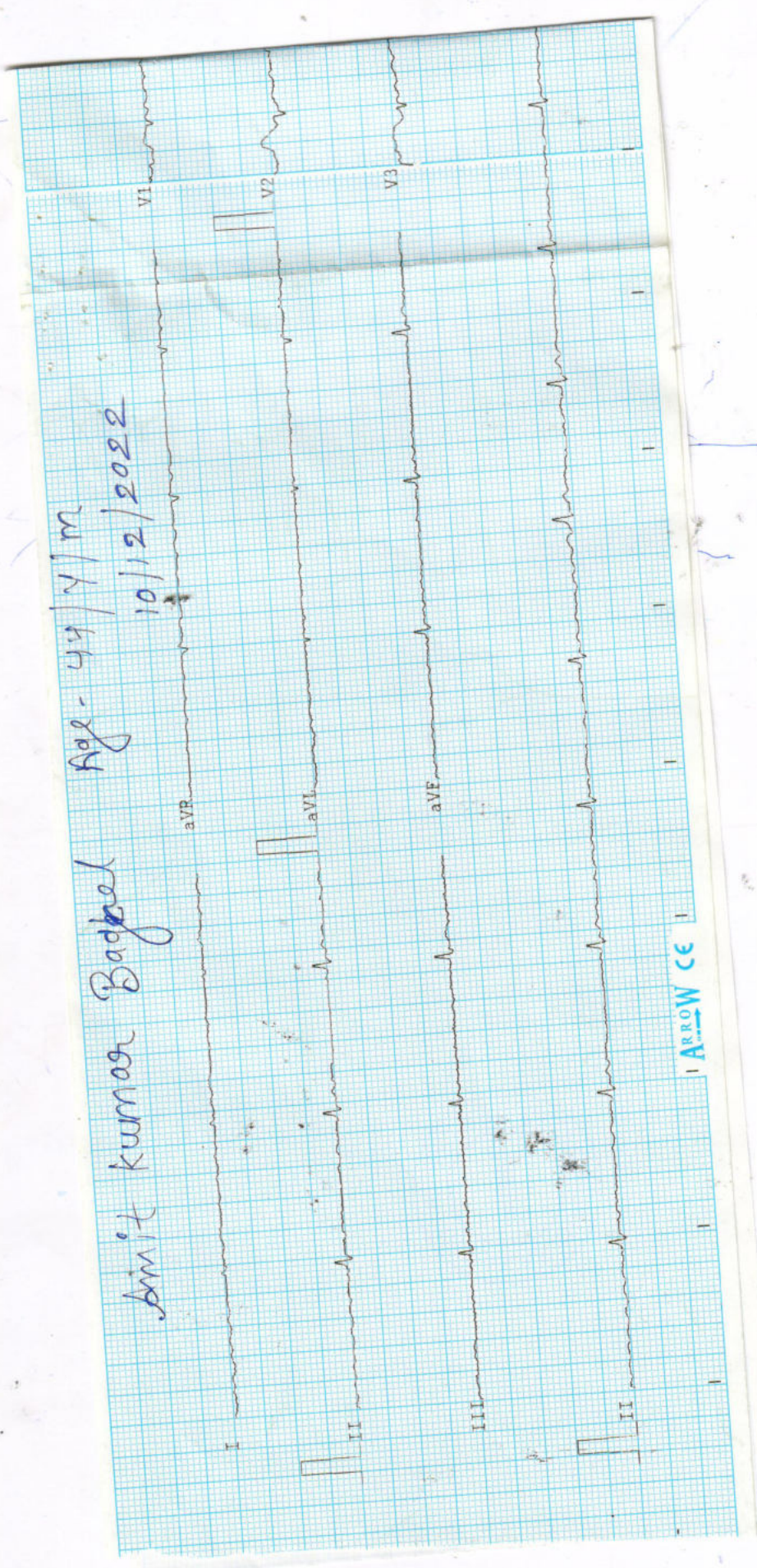
4X

80 mS Post J



REMARKS:

Amit Kumar Baghel
Age - 44/Y/M
10/12/2022



Arrow CE

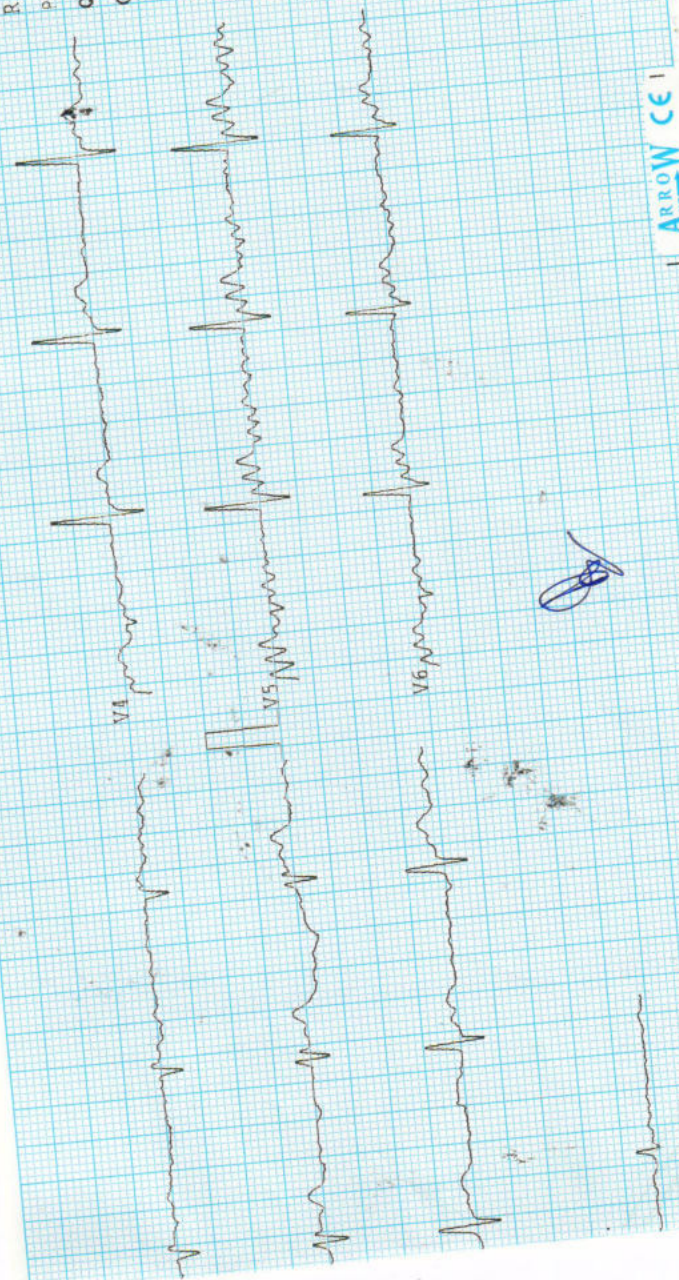
Observations :-

HR :- 65 bpm
R-R :- 920 ms
P-R :- 068 ms
QRS :- 67 ms
QT/QTc :- 241/251 ms
P Axis :- -31 °
R Axis :- 85 °
T Axis :- 64 °



Remarks :-

Unconfirmed report



ARROW CE



डॉ. सविता क्लिनिक

34, भूतल, मोहिनी अदिति आर्केड, शाहपुरा मस्जिद के पास
भरत नगर रोड, ई-7/194, अरेरा कॉलोनी, भोपाल - 462038

Mob. : 8989649694, 9516333619

Clinic Registration : CL/5392/Jun/2017
PNDT Registration : MPPCPNDT/BPL/2017/206



Name : Mrs. Anil-Kumar Baghel ⁴⁴ / Male ₃₆ Age 44 YRS. IF
R/B. Health check up No. 10/12/2022 Date

WHOLE ABDOMEN ULTRASOUND REPORT

Indication :

Liver appears normal / ~~enlarged~~ in size and shape with smooth in outline. ~~Normal~~ / increased perenchymal echogenicity is noted. No E/O focal lesion / IHBR dilatation is seen. Hepatic veins and portal veins appear normal. *go I fatty liver.*

No E/O Subdiaphragmatic Collection.

Gall Bladder is physiologically well distended / collapsed. No E/O echogenic foci in GB lumen. GB wall is normal / thickened. No E/O pericholecystic collection. common duct reveals normal course and caliber.

Pancreas appear normal in size, shape and echo texture with smooth contour. No peripancreatic pathology seen. ~~(Not seen due to gases)~~

Spleen is normal / ~~enlarged~~ in size and normal in echo texture.

IVC and aorta appear to be normal.

No evidence of lymphadenopathy is noted.

No evidence of free fluid is noted.

Right Kidney is normal in size, shape and position. Corticomedullary differentiation (CMD) is well maintained. Normal cortical thickness is noted. No E/O hydronephrosis or calculus is noted.

Dr. P. Savita, MD
MBBS, MD (O&G) Reg. No. 9971
स्त्री रोग विशेषज्ञ

PTO
Dr. Jayant Yadav, MD
MBBS, MD (Radiologist) Reg. No. 416
रेडियोलॉजिस्ट

Left Kidney is normal is size, shape and position. CMD is well maintained. Normal cortical thickness is noted. No E/O hydronephrosis or calculus is noted.

Urinary Bladder is well distended (physiological) / collapsed. Its contents are echo free. No E/O bladder wall thickening is noted. Post-void residue is insignificant.

Prostate is normal in size, shape and echo texture with smooth outline. No E/O focal lesion is noted.

Uterus is ante/retroverted and normal in size, shape and echotexture with smooth outline. No E/O focal lesion is noted, endometrial echo appear normal. Cervical and vaginal shadows appear normal.

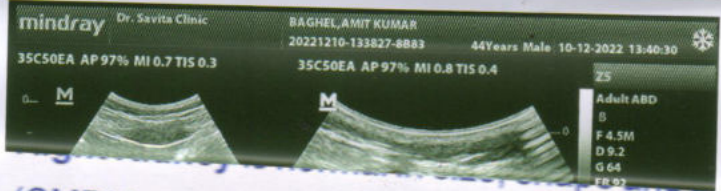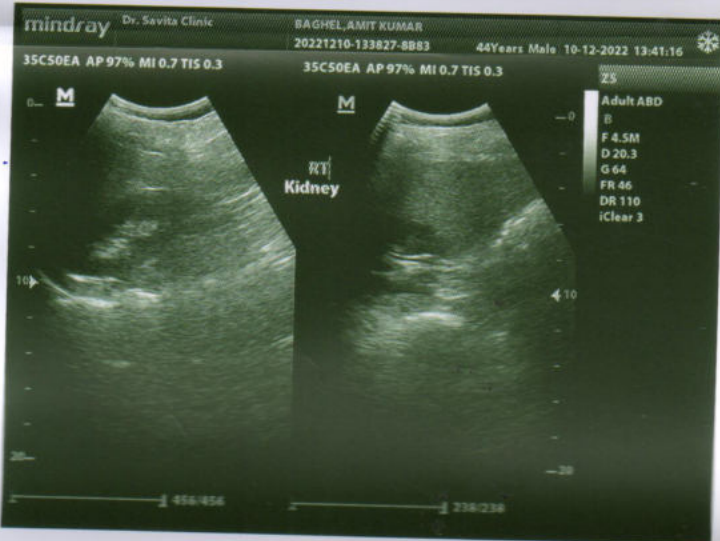
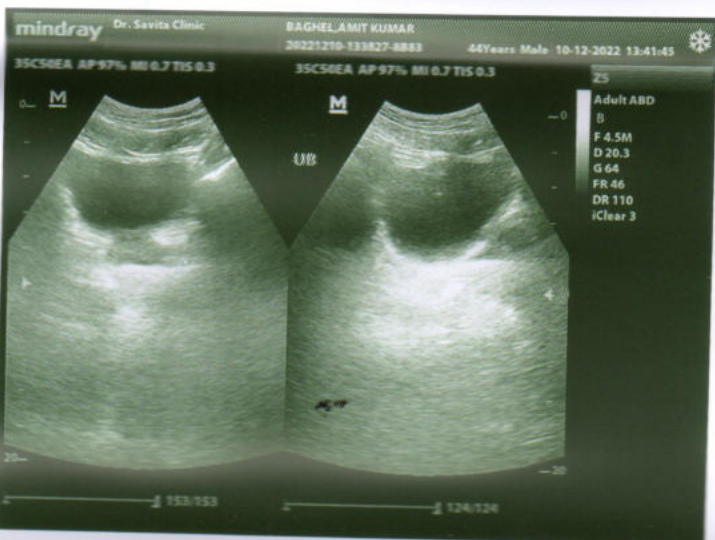
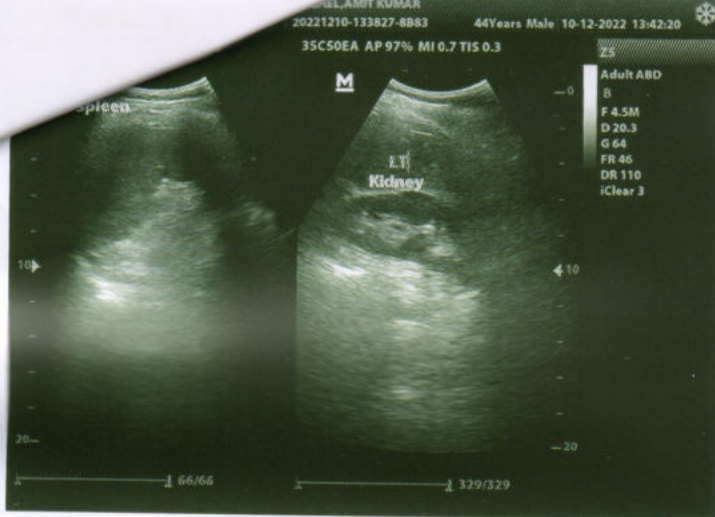
Right Ovary appears Enlarged / Normal in size, shape and echo texture.

Left Ovary appears Enlarged / Normal in size, shape and echo texture.

Impression: ~~Normal study.~~ *Grade 1 Fatty livers.*



Advised clinical Correlation.



क्लिनिक

केंड, शाहपुरा मस्जिद के पास
 काँलोनी, भोपाल - 462038
 94, 9516333619
 CL/5392/Jun/2017
 PCPNDT/BPL/2017/206

ghel. ⁴⁴ 88 / Male Age YRS:IF
 No. Date 10/12/2022

ASOUND REPORT

and shape with smooth in outline.
 noted. No E/O focal lesion / IHBR
 appear normal. *ge I fatty liver.*

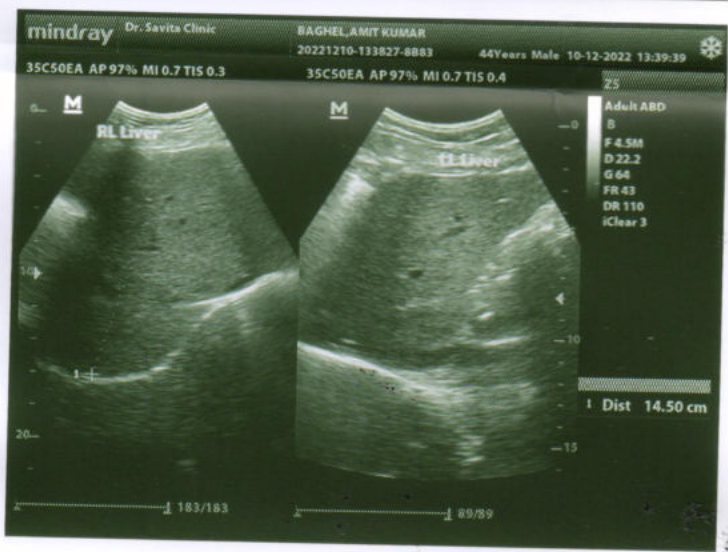
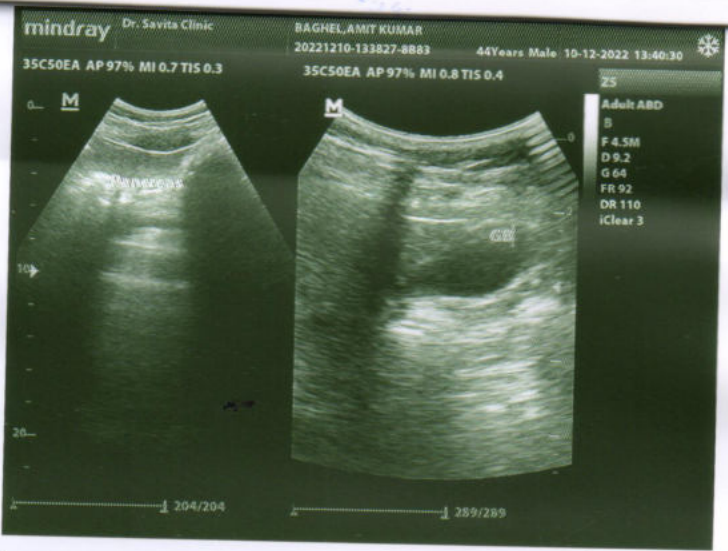
collapsed. No E/O echogenic foci in
 pericholecystic collection. common

o texture with smooth
 (seen due to gases)
 n echo texture.

(CMD) is well maintained. Normal cortical thickness is noted. No E/O hydronephrosis or calculus is noted. on. Corticomedullary differentiation

Dr. P. Savita, MD
 MBBS, MD (O&G) Reg. No. 9971
 स्त्री रोग विशेषज्ञ

PTO
Dr. Jayant Yadav, MD
 MBBS, MD (Radiologist) Reg. No. 4166





डिवाकर डायग्नोस्टिक सेंटर

E-7/636, पंचाल रेणुमल-बैंक के पास, मंग रोड, अरुण कॉलोनी थोपाल (म.प्र.)
फोन: 0755-2465288, 0755-3520545 फा: 9826340190

Pt Name :- Mr. Amit Kumar Baghel
Age :- 44/M
Lab. No. :- 06
Date :- 10/12/2022

EXAMINATION OF BLOOD

TEST	RESULT	NORMAL VALUE
Haemoglobin	11.7gms%	Female 12-16gms%, Male 14-18gms%
Red Cell count	5.64	4.5-5.6 million /cumm
Platelete Count	2.10	1.5-5.6 Lac/cumm
Leucocytes per.cumm	5200/cumm	5000-11000/cumm
Neutrophils	50%	50-70%
Lymphocytes	41%	20-40%
Eosinophils	04%	0-7%
Monocytes	05%	2-8%
PCV	37.5	37-47
MCV	66.5	76-96
MCH	20.7	27-32
MCHC	31.2	31-35
ESR	11	Male 0-9, Female 0-20mm/FHR
Blood Group	"A" Positive	By slide method
Total Serum Cholesterol	198.0	100-250 mg%
Serum Triglyceride	155.0	Up to 150 mg%
Serum Cholesterol HDL	49.0	Up to 65 mg%
Serum Cholesterol LDL	118.0	Up to 125 mg%
LDL	31.0	Up to 30 mg%
S.Bilirubin(Total)	0.90	0.2-1.0mg/dl
Direct	0.50	0.0-0.25mg/dl
Indirect	0.40	
SGOT	25.0	5-35U/L
SGPT	29.0	8-40U/L
Alk Phosphatase	10.1	3-13 KA units
S. Protein(Total)	6.9	6.0-8.0mg%
Albumin	4.9	3.7-5.3mg%
Globulin	2.0	1.5 to 3.5 mg%
Blood Urea	19.0	Up to 40 mg%
S.Creatine	0.97	0.5-1.4mg/dl
S. Uric Acid	6.9	3.5-7.5mg%
GGTP	15.0	5-35 U/L/Dl
Fasting Blood Sugar	98.2	Up to 110 mg%
PP Blood Sugar	124.0	Up to 125 mg%
Glycosylated Hemoglobin	5.8	Below - 6.0 % -Non Diabetic control 6-7 % -Excellent control Above- 8 % -Poor control
HBAtc		
Thyrod Stimulating Hormone(TSH)	3.12	0.27-4.2

All test have technical limitation. Collaborative clinic pathological interpretation is mandatory. In case of disparity test may be repeated immediately. Typographical mistakes should be get correct instantly. This report is not valid for medico legal purpose

Dr. B. M. Agarwal
MBBS, DCP
Consultant Pathologist



Pathologist



Pathologist

Dr. B. M. Agarwal
MBBS, DCP
Consultant Pathologist

A. PHYSICALEXAMINATION	
1. Colour	Pale Yellow
2. Appearance	Clear
3. Specific Gravity	Q.N.S.
B. CHEMICAL EXAMINATION	
1. Reaction	Acidic
2. Albumin	Nil
3. Sugar	Nil
4. Bile Salts	Absent
C. MICROSCOPIEXAMINATION	
Pus Cells	2-3/HPF
R.B.C.	Nil
Epithelial Cell	1-2/HPF
Cast	Nil
Crystals(Cal.Oxa)	Nil
Bacteria	Nil
Amorphous	Nil
T. Vaginitis	Nil

URINE ANALYSIS

Pt Name :- Mr. Amit Kumar Baghel
Age :- 44/M
Lab. No. :- 06
Date :- 10/12/2022

E-7/636, पंजाब-संस्थान बँक के पास, मैन रोड, अरुण कॉलोनी भीपाल (म.प्र.)
फोन: 0755-2465288, 0755-3520545 फा: 9826340190

डिवाकर डायग्नोस्टिक सेंटर

