

भारत सरकार
GOVERNMENT OF INDIA



अदित्य मिश्रा
Aditya Mishra
जन्म तिथि/DOB: 25/07/1992
पुरुष / MALE



8824 0303 0796

मेरा आधार, मेरी पहचान

Aditya Mishra

[Signature]
Dr. NITIN AGARWAL
MBBS, MD
Regn. No. DMC-R-1436

MEERA AADHAAR, MERI PEHACHAN

8824 0303 0796


7/8 नगर, चोली बजार,
तिरुवांगुर, तमिल नाडु,
भारत - 786125

पता: S/O: Vinay Kumar Mishra, Guru
nanak Market, AT Road, Hingun,
Chotungral Tal. 7/8 Nlr,
Tinsukia,
Assam - 786125

आर्य समाज, विनाय कुमार मिश्रा,
गुरु नानक बाजार, चोली बजार,
तिरुवांगुर, तमिल नाडु,
भारत - 786125

एनआईएचआर, भारत सरकार

ONEPLUS ULTRASOUND LAB
67, Harsh Vihar, Pitam Pura,
Delhi-110034
Phone: 42480101, 9599913051
Email: oneplusul@gmail.com



Dr. NITIN AGARWAL
MBBS, MD
Regn. No. DMC-R-1436

ONEPLUS ULTRASOUND LAB
47, Harsh Vihar, Pitam Pura,
Delhi-110034
Ph. 011-42480101, 9599913051
E-mail: oneplusul@gmail.com

ONEPLUS ULTRASOUND LAB

47, HARSH VIHAR, PITAMPURA, DELHI- 110034

Mr. ADITYA MISHRA
Age : 30M
Ref. by : MEDWHEEL
Indication1 :
Indication2 :
Indication3 :
COMMENTS : Normal ECG

ID : 2200
HMM : 182/86
Recorded : 4-4-2023 10:18
Medication1 :
Medication2 :
Medication3 :

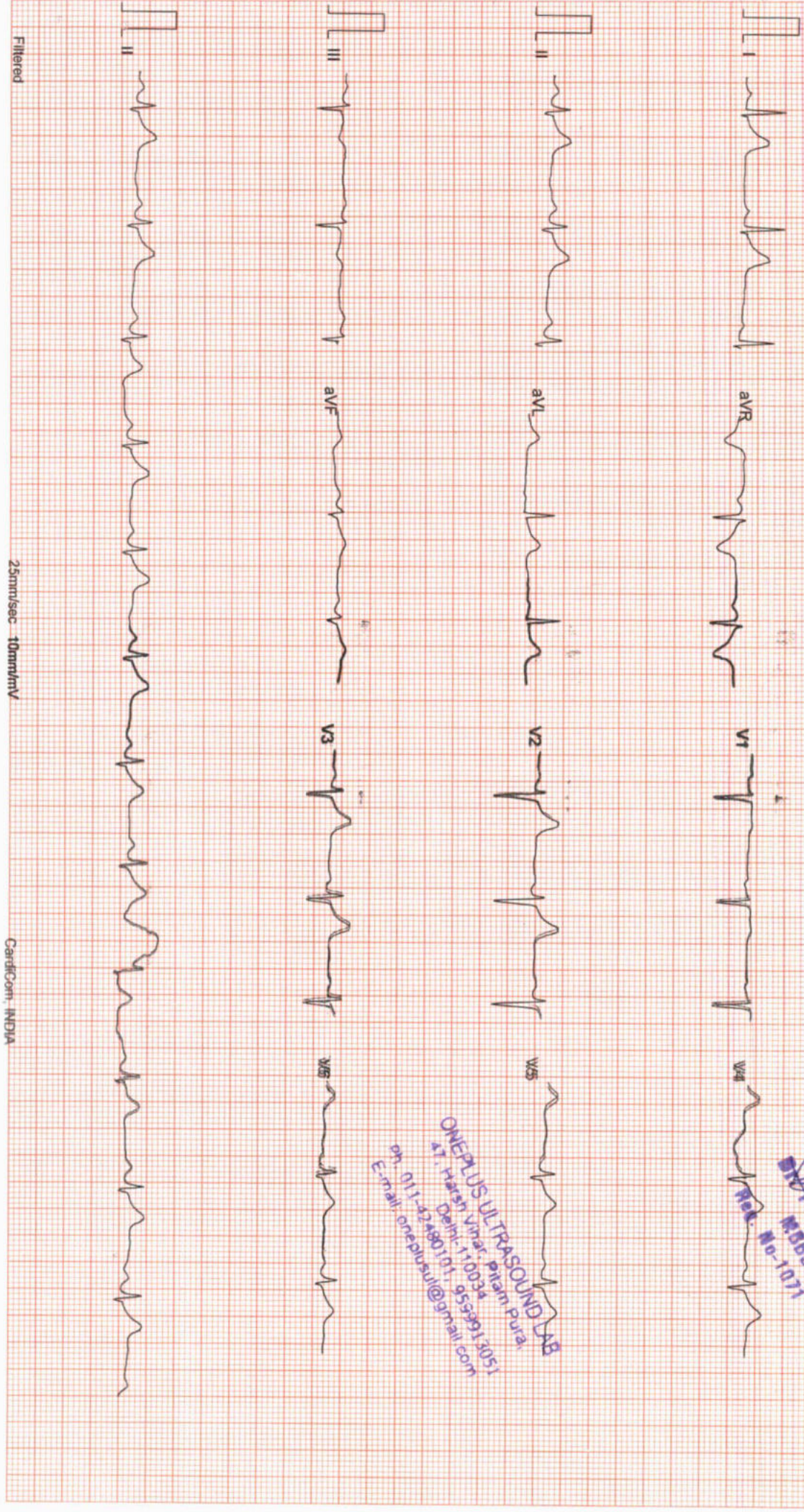
BPM : 75
BP : 122/84
P Axis : 58 deg
QRS Axis : 1 deg
T Axis : 24 deg

P duration : 100 msec
PR duration : 156 msec
QRS duration : 106 msec
QT interval : 323 msec
QTc interval : 349 msec

Unconfirmed Report Reviewed By:
Cardiologist

(Signature)
Dr. P. K. GUPTA
MBBS, MD
Reg. No-1071

ONEPLUS ULTRASOUND LAB
47, Harsh Vihar, Pitam Pura,
Delhi-110034
Ph. 011-22480101, 9539913051
E-mail: oneplusul@gmail.com



ONEPLUS ULTRASOUND LAB

47, HARSH VIHAR PITAMPURA DELHI 110034

Mr. ADITYA MISHRA
Age/Sex : 30/M
Ref by : MEDWHEEL
Indication 1 :
Indication 2 :
Indication 3 :

ID : 994
HWM : 182/86
Recorded : 4-4-2023 10:21

TREADMILL TEST SUMMARY REPORT
Protocol: BRUCE
History:
Medication 1 :
Medication 2 :
Medication 3 :

PHASE	PHASE TIME	STAGE TIME	SPEED (km./hr.)	GRADE (%)	H.R (bpm)	B.P. (mmHg)	RPP X100	ST LEVEL (mm)	V2	V5	METS
SUPINE											
STANDING											
STAGE 1	2:59	2:59	2.70	10.00	73	122/84	89	1.3	2.1	1.1	4.80
STAGE 2	5:59	2:59	4.00	12.00	89	122/84	108	1.1	1.6	0.8	7.10
STAGE 3	8:59	2:59	5.40	14.00	91	122/84	111	1.2	2.7	1.3	10.00
STAGE 4	11:59	2:59	6.70	16.00	119	140/88	186	1.3	3.1	1.5	14.00
STAGE 5	12:59	0:59	8.00	18.00	144	150/90	216	2.3	5.3	2.6	14.00
PEAK EXER	13:00	1:00			180	160/94	288	2.0	4.2	1.7	15.98
RECOVERY	2:59	2:59	0.00	0.00	89	124/94	110	1.9	3.1	1.6	16.01

RESULTS
Exercise Duration : 13:00 Minutes
Max Heart Rate : 180 bpm 94 % of target heart rate 190 bpm
Max Blood Pressure : 160/94 mmHg
Max Work Load : 16.01 METS
Reason of Termination :

Handwritten note: Negative for valve disease

Dr. P.K. GUPTA
MBBS, MD
Reg. No-1071
Cardiologist

ONEPLUS ULTRASOUND LAB
47, Harsh Vihar, Pitam Pura,
Delhi-110034
Ph: 011-2486101, 9599913051
E-mail: oneplusui@gmail.com

Handwritten signature: Aditya Mishra

ONEPLUS ULTRASOUND LAB

SUPINE
PRETEST

ST @ 10mm/mV
80ms PostU

Mr. ADITYA MISHRA

I.D. : 994

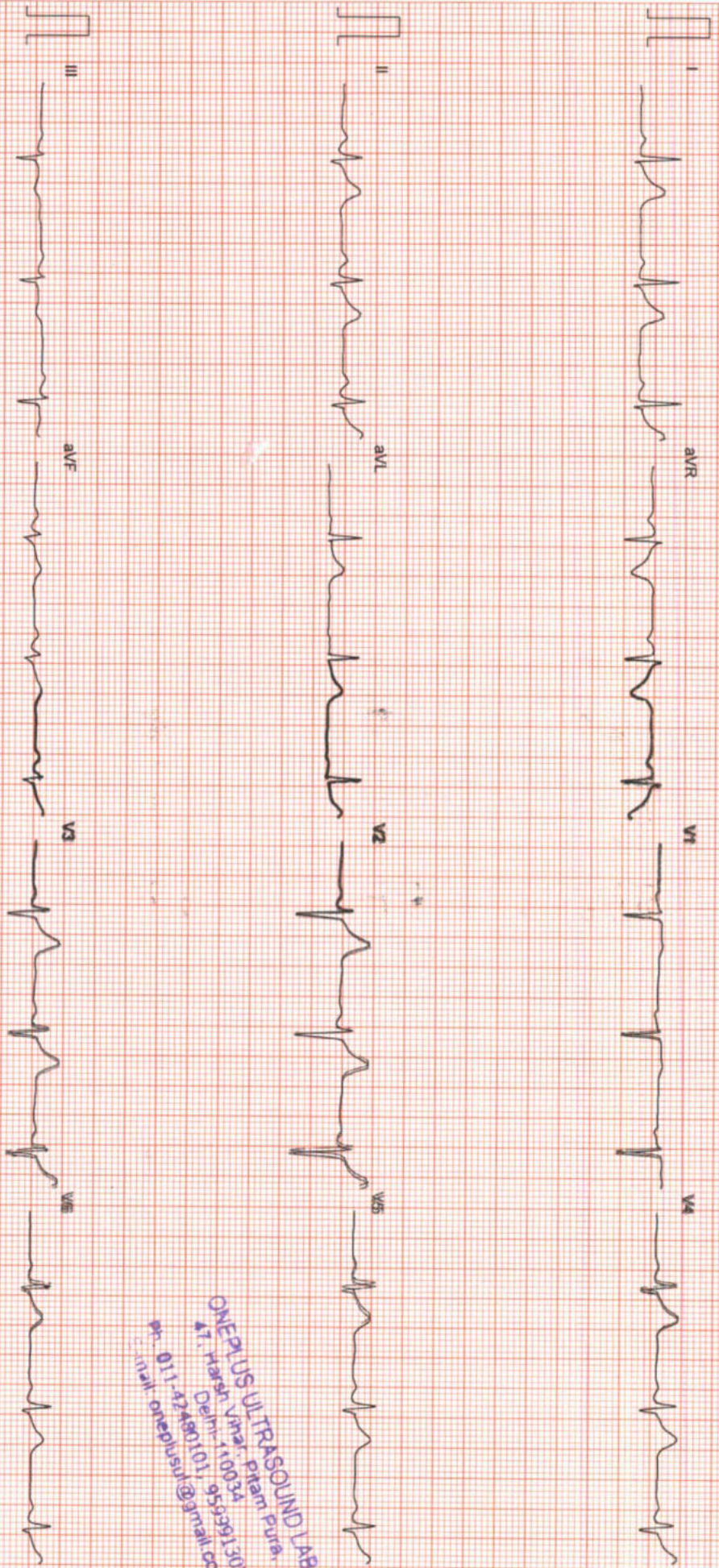
AGE/SEX : 30/M

RECORDED : 4-4-2023 10:21

RATE : 73 BPM

B.P. : 122/84 mmHg

RAW E.C.G.



ONEPLUS ULTRASOUND LAB
Dr. Harsh Vihar Pitam Pura,
Delhi-110034
Ph. 011-42480101, 9599913051
Email: oneplusul@gmail.com

Filtered

25mm/sec 10mm/mV

CardiCom, INDIA Ph. 091-731-2620740, TeleFax 091-731-2431214

ONEPLUS ULTRASOUND LAB

STANDING
PRETEST

ST @ 10mm/mV
80ms PostJ

Mr. ADITYA MISHRA

I.D. : 994

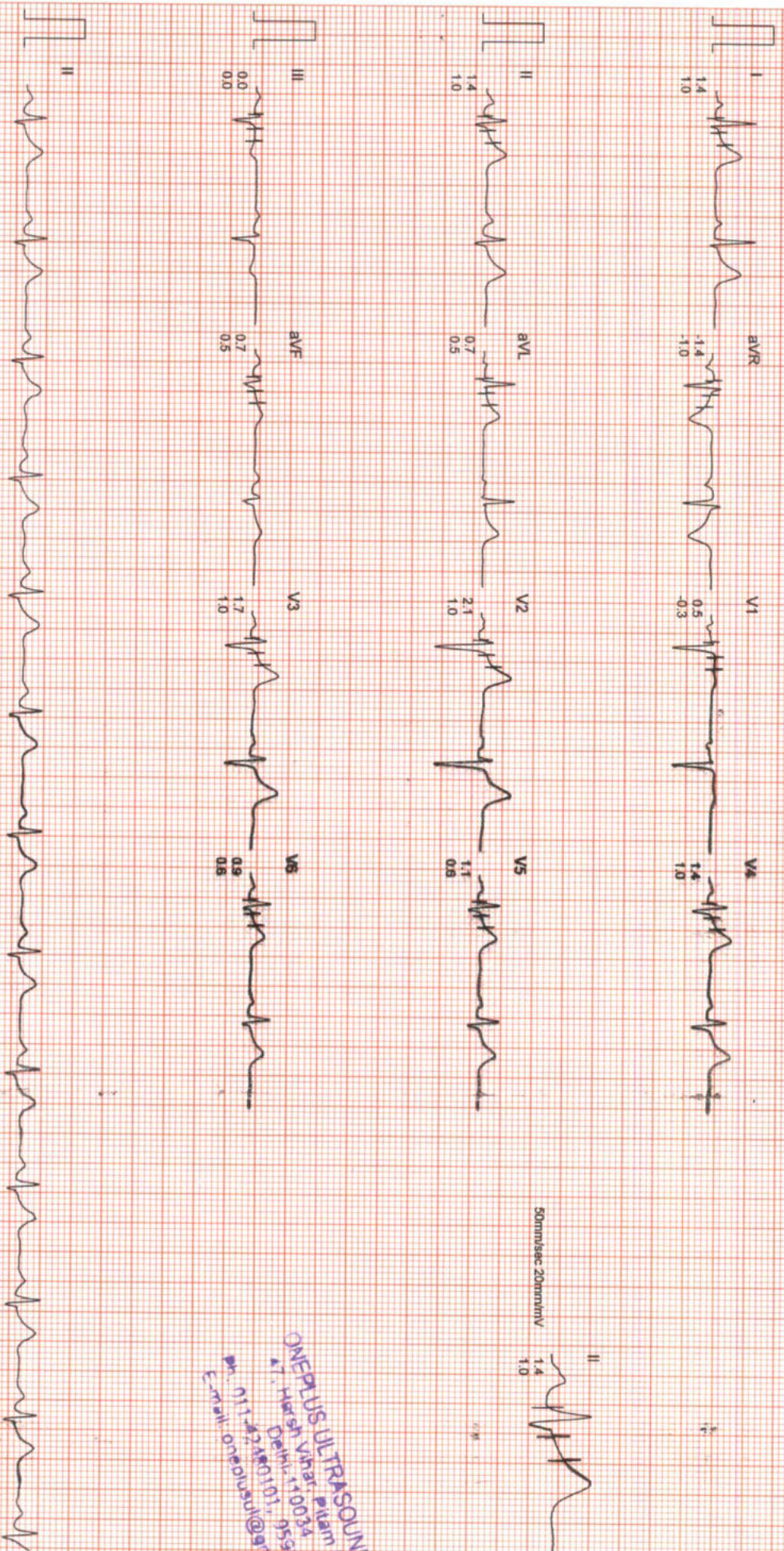
AGE/SEX : 30/M

RECORDED : 4-4-2023-10:21

RATE : 75 BPM

B.P. : 122/84 mmHg

LINKED MEDIAN



50mm/sec 20mm/mV
II
1.4
1.0

ONEPLUS ULTRASOUND LAB
Hareesh Vihar, Pitam Pura
Delhi - 110034
Ph: 011-24301101, 95599913051
E-mail: onepplusul@ gmail.com

ONEPLUS ULTRASOUND LAB

Mr. ADITYA MISHRA

I.D. : 994

AGE/SEX : 30/M

RECORDED : 4-4-2023-10:21

RATE : 89 BPM

B.P. : 122/84 mmHg

BRUCE

EXERCISE 1

PHASE TIME : 2:59

STAGE TIME : 2:59

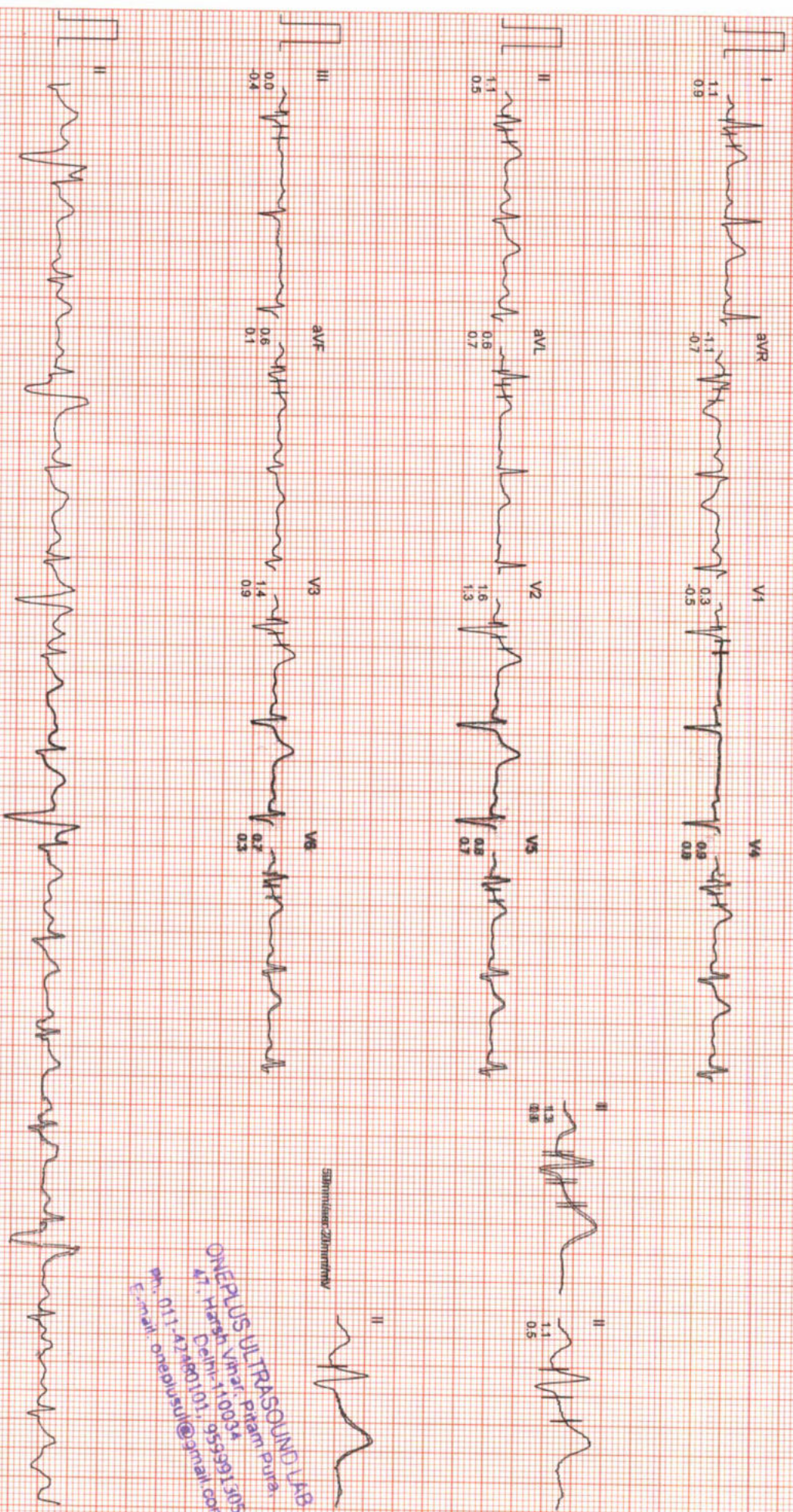
ST @ 10mm/mV

80ms PostJ

SPEED : 2.7 Km./Hr.

GRADE : 10.0 %

LINKED MEDIAN



ONEPLUS ULTRASOUND LAB
47, Harsh Vihar, Pitam Pura,
Delhi-110034
9959915091
ph: 011-22480101
E-mail: oneplusul@cmil.com

ONEPLUS ULTRASOUND LAB

ST @ 10mm/mV

80ms PostJ

SPEED : 4.0 Km./Hr.

GRADE : 12.0 %

BRUCE

EXERCISE 2

PHASE TIME : 5:59

STAGE TIME : 2:59

Mr. ADITYA MISHRA

I.D. : 994

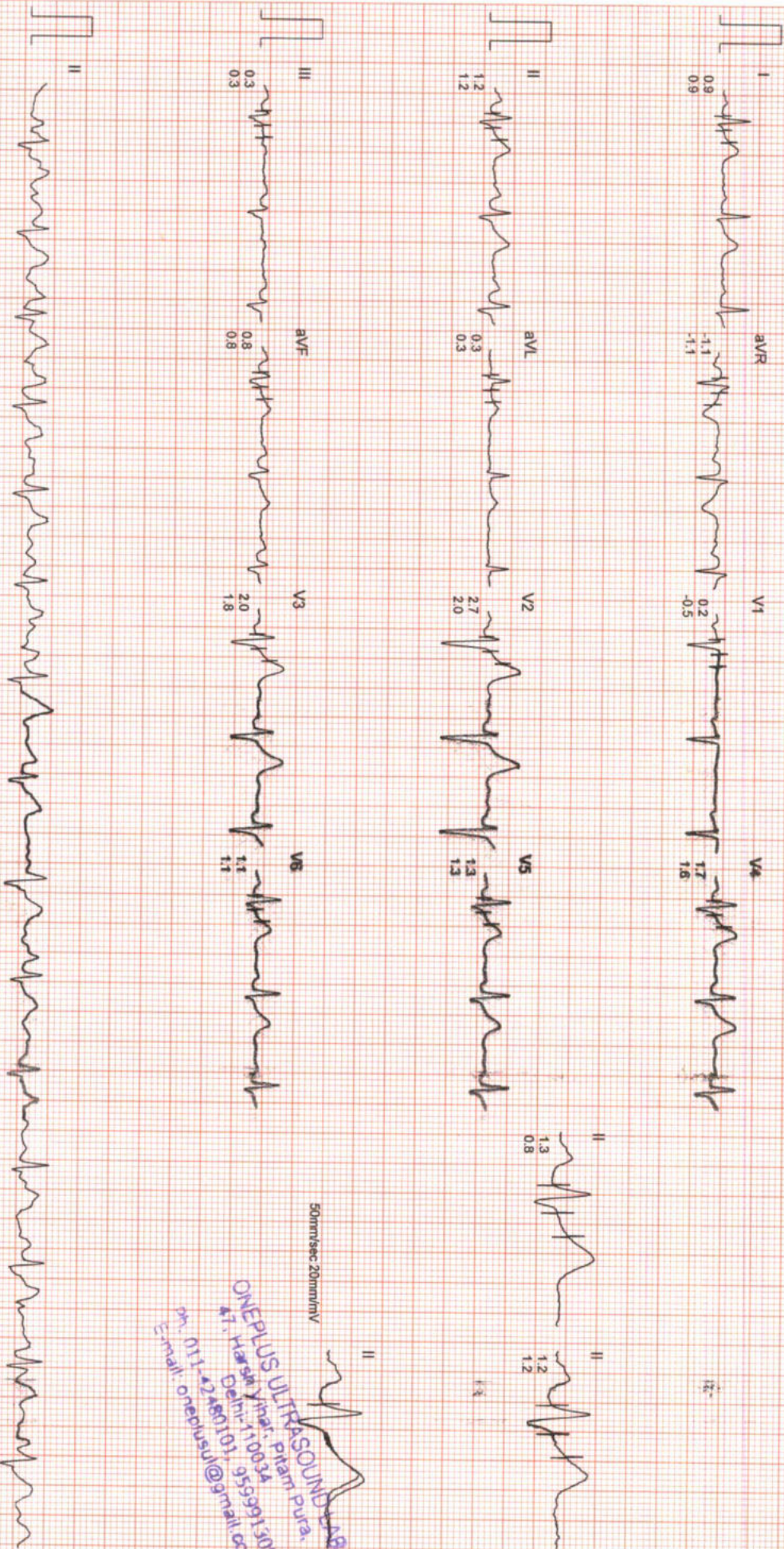
AGE/SEX : 30/M

RECORDED : 4-4-2023 10:21

RATE : 91 BPM

B.P. : 122/84 mmHg

LINKED MEDIAN



50mm/sec 20mm/mV

ONEPLUS ULTRASOUND LAB
* 7, Harshyinar, Pitam pura,
Delhi-110034
Ph: 011-42480101, 9559913054
E-mail: oneplusul@gmail.com

Filtered

Computer Corrected Baseline

25mm/sec 10mm/mV

CardiCent, INDIA Ph.:091-731-2620740, TeleFax:091-731-2431214

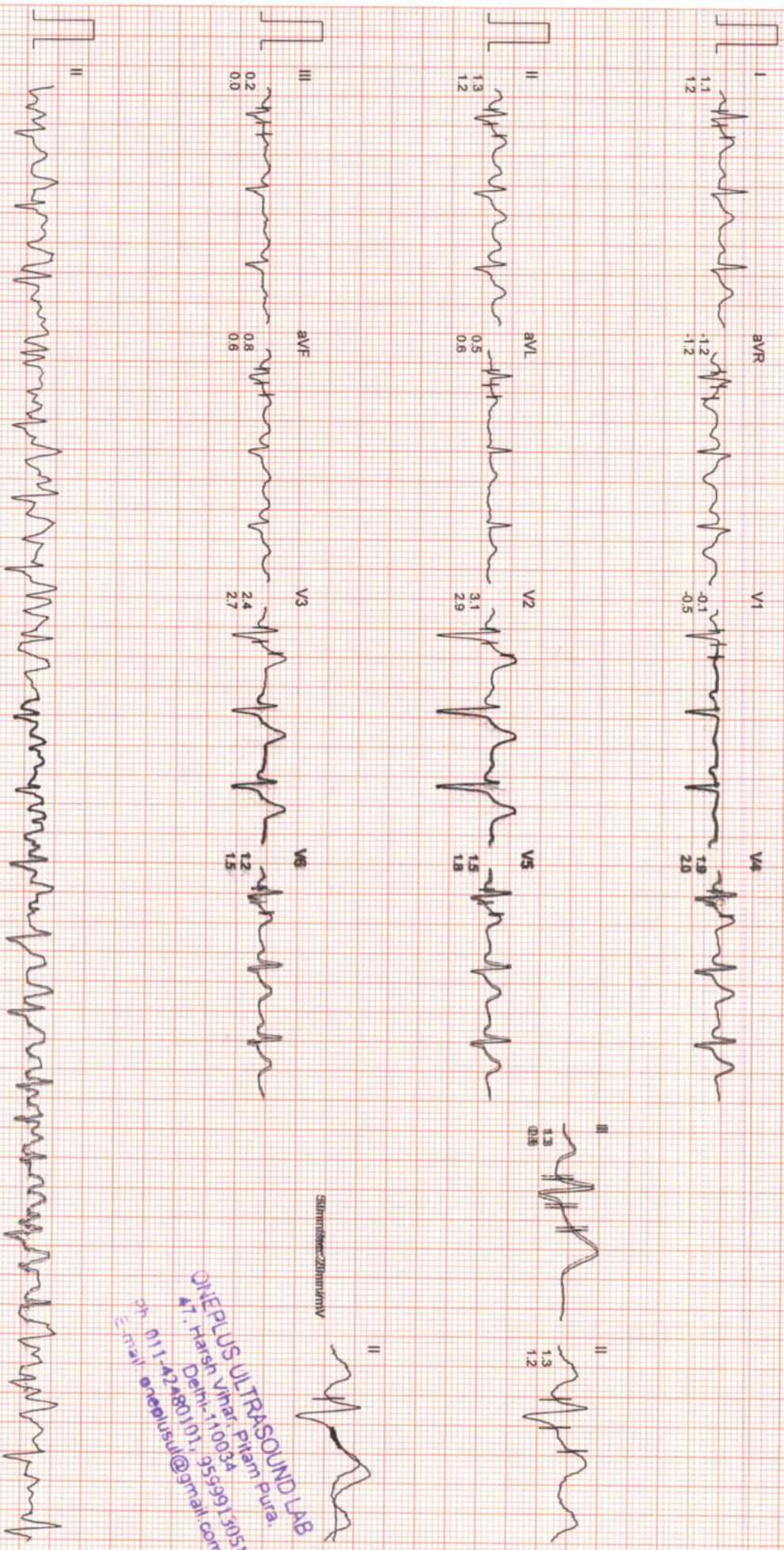
ONEPLUS ULTRASOUND LAB

Mr. ADITYA MISHRA
I.D. : 994
AGE/SEX : 30/M
RECORDED : 4-4-2023-10:21

RATE : 119 BPM
B.P. : 140/88 mmHg

BRUCE
EXERCISE 3
PHASE TIME : 8:59
STAGE TIME : 2:59

ST @ 10mm/mV
80ms PostJ
SPEED : 5.4 Km./Hr.
GRADE : 14.0 %
LINKED MEDIAN



ONEPLUS ULTRASOUND LAB
#1, Harsh Vihar, Pitam Pura,
Delhi-110034
Ph: 011-42480101, 9599913051
E-mail: oneplusul@gmail.com

ONEPLUS ULTRASOUND LAB

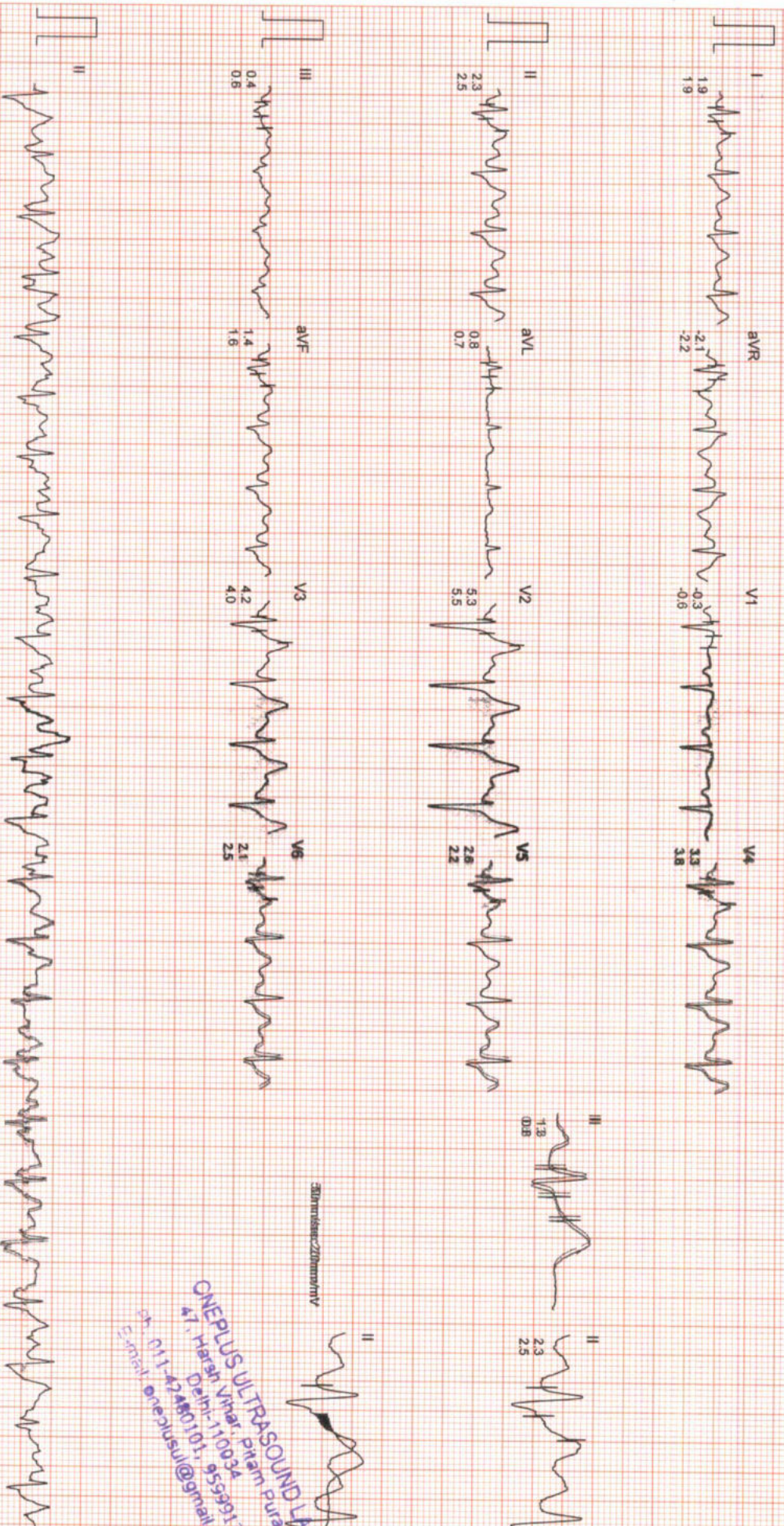
Mr. ADITYA MISHRA
I.D. : 994
AGE/SEX : 30/M
RECORDED : 4-4-2023-10:21

RATE : 144 BPM
B.P. : 150/90 mmHg

BRUCE
EXERCISE 4
PHASE TIME : 11:59
STAGE TIME : 2:59

ST @ 10mm/mV
80ms PostJ
SPEED : 6.7 Km./Hr.
GRADE : 16.0%

LINKED MEDIAN



ONEPLUS ULTRASOUND LAB
47, Harsh Vihar, Pitam Pura,
Delhi-110034
Ph. 011-42480101, 9559913051
E-mail: oneplusul@gmail.com

ONEPLUS ULTRASOUND LAB

Mr. ADITYA MISHRA

I.D. : 994

AGE/SEX : 30/M

RECORDED : 4-4-2023 10:21

RATE : 180 BPM

B.P. : 160/94 mmHg

BRUCE:

PEAK EXER

PHASE TIME : 13:00

STAGE TIME : 1:00

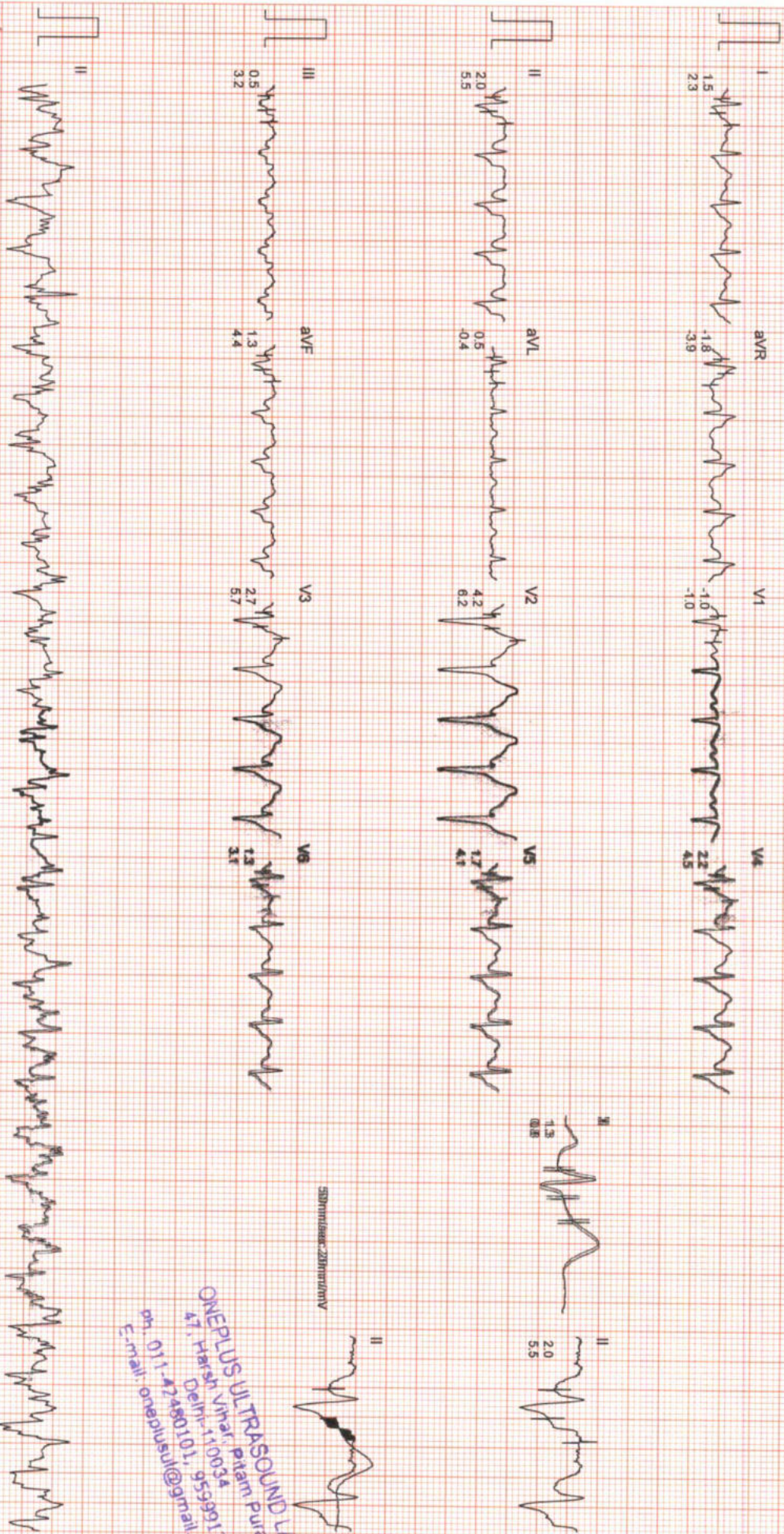
ST @ 10mm/mV

80ms PostJ

SPEED : 8.0 Km./Hr.

GRADE : 18.0 %

LINKED MEDIAN



50mm/msec 20mm/mV

ONEPLUS ULTRASOUND LAB
4, 17, Harsh Vihar, Pitam Pura,
Delhi-110034
Ph. 011-2490101, 9559913051
E-mail: oneplusul@gmail.com

Filtered

Computer Corrected Baseline

25mm/sec 10mm/mV

CardiCom, INDIA Ph. 091-731-2620740, TeleFax: 091-731-2431214

ONEPLUS ULTRASOUND LAB

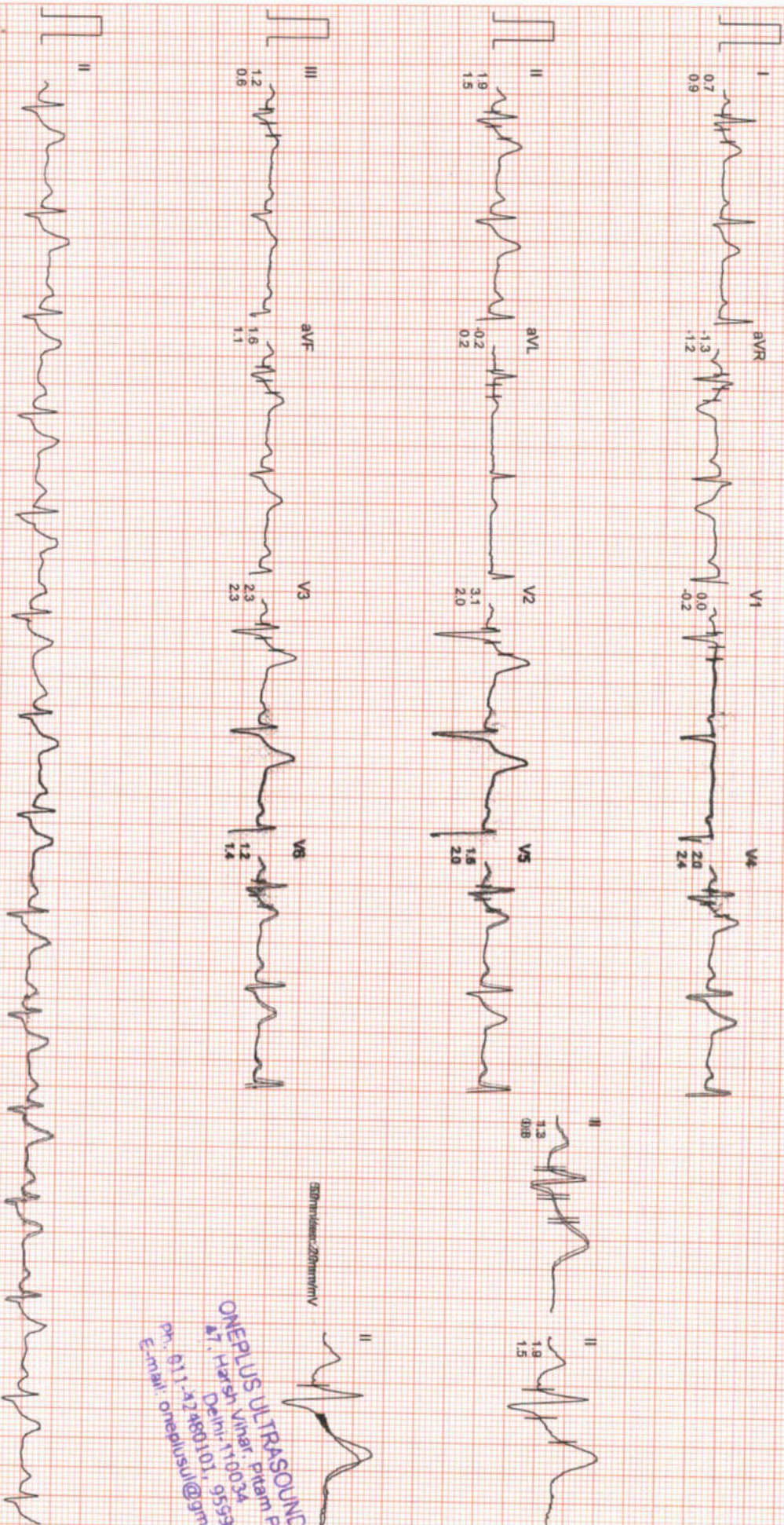
Mr. ADITYA MISHRA
I.D. : 994
AGE/SEX : 30/M
RECORDED : 4-4-2023 10:21

RATE : 89 BPM
B.P. : 124/94 mmHg

BRUCE
RECOVERY
PHASE TIME : 2:59

ST @ 10mm/mV
80ms PostJ
SPEED : 0.0 Km./Hr.
GRADE : 0.0 %

LINKED MEDIAN



ONEPLUS ULTRASOUND LAB
7, Hariish Vihar Pitam Pura,
Delhi-110034
Ph: 011-42480101, 9559913051
E-mail: onepusul@gmail.com

STAGE	HR	BP	SpO2	ECG Lead	ECG Trace	ECG Lead	ECG Trace	ECG Lead	ECG Trace	ECG Lead	ECG Trace	ECG Lead	ECG Trace	ECG Lead	ECG Trace	ECG Lead	ECG Trace
SUPINE	73 bpm	122/84	80ms Postul	I		II		III		aVF		V1		V2		V5	
STANDING	75 bpm	122/84	80ms Postul	I		II		III		aVF		V1		V2		V5	
STAGE 1	89 bpm	122/84	80ms Postul	I		II		III		aVF		V1		V2		V5	
STAGE 2	91 bpm	122/84	80ms Postul	I		II		III		aVF		V1		V2		V5	
STAGE 3	119 bpm	140/88	80ms Postul	I		II		III		aVF		V1		V2		V5	
STAGE 4	144 bpm	150/90	80ms Postul	I		II		III		aVF		V1		V2		V5	
PEAK EXERCISE	180 bpm	160/90	80ms Postul	I		II		III		aVF		V1		V2		V5	
RECOVERY	89 bpm	124/84	80ms Postul	I		II		III		aVF		V1		V2		V5	


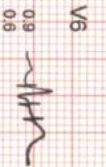
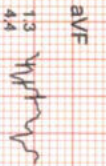
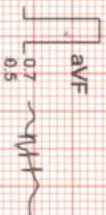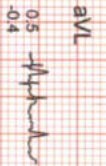


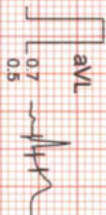


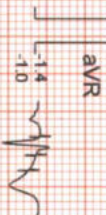
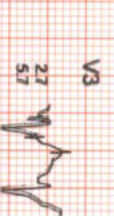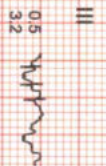

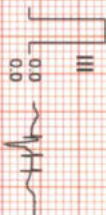
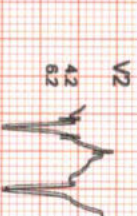
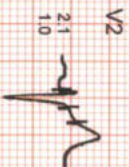
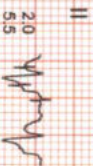
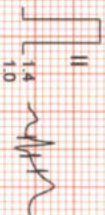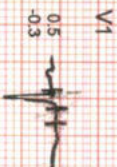

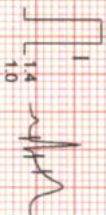
ONEPLUS ULTRASOUND LAB
 #17 Harsh Mihar, Pitam Pura,
 Delhi-110034
 Ph: 011-42460101, 9559513503
 E-mail: oneplusul@gmail.com
 www.oneplusultrasound.com

STANDING
0.0Kmph
0.0%
75 bpm
B.P. 122/84
80ms PostJ

PEAK EXERCISE
13:00
1:00
8.0Kmph
18.0%
180 bpm
B.P. 160/94
80ms PostJ

STANDING
0.0Kmph
0.0%
75 bpm
B.P. 122/84
80ms PostJ

PEAK EXERCISE
13:00
1:00
8.0Kmph
18.0%
180 bpm
B.P. 160/94
80ms PostJ



ONEPLUS ULTRASOUND LAB
47, H. Harsh Vihar, Pitam Pura,
Delhi-110034
Ph: 011-2280101, 9559913051
E-mail: oneplusul@gmail.com



OnePLUS Ultrasound Lab

QUALITY FIRST... ALWAYS!

Dr. Nitin Agarwal
Pathologist & Director
Ex. Sr. Res. MAMC
& Lok Nayak Hospital
Ex. Chief of Lab Dr. Lal Path Labs.

Dr. Pooja (Garg) Agarwal
Radiologist & Director
MAMC & Lok Nayak Hospital



NAME	:Mr. ADITYA MISHRA	Barcode No	:10141616
AGE/GENDER	:29 YRS/Male	SPECIMEN DATE	:04/Apr/2023 09:09AM
PATIENT ID	:111916	SPECIMEN RECEIVED	:04/Apr/2023 01:10PM
REFERRED BY	:Dr. MEDIWHEEL	REPORT DATE	:04/Apr/2023 01:47PM
CENTRE NAME	:ONEPLUS ULTRASOUND LAB	LAB NO.	:012304040013

Test Name	Result	Unit	Ref. Range
-----------	--------	------	------------

HAEMATOLOGY

Medi Wheel Health checkup < 40 Male

Glycosylated Hemoglobin (HbA1c)	5.3	%	Non Diabetic adults <5.7 Prediabetic (at risk) 5.7-6.4 Diabetes >6.4
Estimated average blood glucose (eag)	105		

Reference range (mg/dl):

90 - 120:Excellent control, 121 - 150:Good Control, 151 - 180:Average Control, 181 - 210:Action Suggested

>211:Panic value

BLOOD GROUP (ABO)	O
Rh typing	POSITIVE

NOTE :

- * Apart from major A,B,H antigens which are used for ABO grouping and Rh typing, many minor blood group antigens exist. Agglutination may also vary according to titre of antigen and antibody.
- * So before transfusion, reconfirmation of blood group as well as cross-matching is needed.
- * Presence of maternal antibodies in newborns, may interfere with blood grouping.
- * Auto agglutination (due to cold antibody, falciparum malaria, sepsis, internal malignancy etc.) may also cause erroneous result.

CBC

Haemoglobin	13.8	g/dl	13.0-17.0
Total Leucocyte Count	4800	/cumm	4000-10000
Differential leucocyte count			
Neutrophils	47.6	%	40-80
Lymphocyte	45.00	%	20-40
Monocytes	5.00	%	2-10
Eosinophils	2.0	%	1-6
Basophils	0.4	%	0-2
RBC Count	5.10	million/cumm	4.5 - 5.5

Checked By.

Dr. NITIN AGARWAL
M.B.B.S., MD (Path)
DMC/R/01436
DR. NITIN AGARWAL
MBBS,MD(PATHOLOGIST)

47, Harsh Vihar, Pitampura, New Delhi-110034 | Ph.: 011-42480101, 9599913051

E-mail: oneplusul@gmail.com | Web.: www.oneplusul.in

Page 1 of 5





OnePLUS Ultrasound Lab

QUALITY FIRST... ALWAYS!

Dr. Nitin Agarwal
Pathologist & Director
Ex. Sr. Res. MAMC
& Lok Nayak Hospital
Ex. Chief of Lab Dr. Lal Path Labs.

Dr. Pooja (Garg) Agarwal
Radiologist & Director
MAMC & Lok Nayak Hospital



NAME	:Mr. ADITYA MISHRA	Barcode No	:10141616
AGE/GENDER	:29 YRS/Male	SPECIMEN DATE	:04/Apr/2023 09:09AM
PATIENT ID	:111916	SPECIMEN RECEIVED	:04/Apr/2023 01:10PM
REFERRED BY	:Dr. MEDIWHEEL	REPORT DATE	:04/Apr/2023 01:47PM
CENTRE NAME	:ONEPLUS ULTRASOUND LAB	LAB NO.	:012304040013

Test Name	Result	Unit	Ref. Range
PCV(Hematocrit)	46.9	%	40-50
MCV	91.4	fL	83-101
MCH	26.9	Pg	27-32
MCHC	29.4	G/dL	32-35
RDW-CV	13.9	%	11.4-14.0
Platelet count	168000	/cumm	150000-450000

BIOCHEMISTRY

<u>Blood sugar fasting</u>	92	mg/dL	70-110
<u>Bun (blood urea nitrogen)</u>	12.60	mg/dl	8.9-21.6
<u>Uric acid, serum</u>	4.6	mg/dl	3.5-7.2
<u>Creatinine, serum</u>	0.8	mg/dl	0.60-1.2

LFT(LIVER FUNCTION TEST)

Bilirubin Total	0.54	mg/dl	0.1-1.2
Bilirubin Conjugated	0.23	mg/dl	0-0.4
Bilirubin Unconjugated	0.31	mg/dl	up to 0.7
SGOT (AST)	24	U/L	0-46
SGPT (ALT)	32	U/L	0-49
Alkaline phosphatase	95	U/L	40-129
Gamma glutamyl transpeptidase	26	U/L	10-45
Total Protein	6.8	gm/dl	6.60 - 8.70
Albumin serum	3.9	g/dL	3.0-5.2
Globulin	2.90	gm/dl	1.8-3.4
Albumin/Globulin Ratio	1.34		1.10 - 2.50

LIPID PROFILE

Cholesterol	182	mg/dl	50-200
Triglycerides	101	mg/dL	25-150
HDL Cholesterol	45	mg/dL	40 - 60
LDL cholesterol	117	mg/dL	<130

Checked By.

Dr. NITIN AGARWAL
MBBS, MD (Path)
DMC/R/01436

DR. NITIN AGARWAL
MBBS, MD (PATHOLOGIST)

47, Harsh Vihar, Pitampura, New Delhi-110034 | Ph.: 011-42480101, 9599913051

E-mail: oneplusul@gmail.com | Web.: www.oneplusul.in

Page 2 of 5



OnePLUS Ultrasound Lab

QUALITY FIRST... ALWAYS!

Dr. Nitin Agarwal
Pathologist & Director
Ex. Sr. Res. MAMC
& Lok Nayak Hospital
Ex. Chief of Lab Dr. Lal Path Labs.

Dr. Pooja (Garg) Agarwal
Radiologist & Director
MAMC & Lok Nayak Hospital



NAME	:Mr. ADITYA MISHRA	Barcode No	:10141616
AGE/GENDER	:29 YRS/Male	SPECIMEN DATE	:04/Apr/2023 09:09AM
PATIENT ID	:111916	SPECIMEN RECEIVED	:04/Apr/2023 01:10PM
REFERRED BY	:Dr. MEDIWHEEL	REPORT DATE	:04/Apr/2023 01:47PM
CENTRE NAME	:ONEPLUS ULTRASOUND LAB	LAB NO.	:012304040013

Test Name	Result	Unit	Ref. Range
VLDL cholesterol	20.2	mg/dL	5-40
Cholesterol/HDL Ratio	4.0		Low Risk 3.3-4.97 Average Risk 4.4-7.1 Moderate Risk 7.1-11.0 High Risk >11.0
LDL/HDL Ratio	2.6		0 - 3.55

According to ATP III and NCEP guidelines

Parameter	Normal	Desirable	Borderline	High
Total cholesterol	<200		200-239	240
Triglycerides	<150	150-199	200-499	500
LDL	Optimal <100 Near Optimal 100-129	130-159	160-180	190
HDL	<40 : LOW 60 : HIGH			

BUN/Creatinine ratio

Bun (blood urea nitrogen)	12.60	mg/dl	8.9-21.6
CREATININE	0.80	mg/dl	0.30-1.10
BUN/Creatinine ratio	15.75		10.0 - 20.0

ENDOCRINOLOGY

THYROID PROFILE(T3,T4,TSH)

Triiodothyronine total [t3]	0.68	ng/dl	0.52-1.9
Thyroxine total [t4]	7.50	µg/dl	4.4 - 10.8
TSH (Thyroid Stimulating Hormone)	2.30	µIU/ml	0.25-5.0

AGE WISE VARIATION IN TSH

AGE	TSH(µIU/ml)	AGE	TSH(µIU/ml)
1-4 weeks	1.00 - 19.0	16-20 yrs	0.25 - 5.0

Checked By.

DR. NITIN AGARWAL
MBBS, MD (P)
MAMC/18/01435
DR. NITIN AGARWAL
MBBS, MD (PATHOLOGIST)

47, Harsh Vihar, Pitampura, New Delhi-110034 | Ph.: 011-42480101, 9599913051

E-mail: onepusul@gmail.com | Web.: www.oneplusul.in

Page 3 of 5



OnePLUS Ultrasound Lab

QUALITY FIRST... ALWAYS!

Dr. Nitin Agarwal
Pathologist & Director
Ex. Sr. Res. MAMC
& Lok Nayak Hospital
Ex. Chief of Lab Dr. Lal Path Labs.

Dr. Pooja (Garg) Agarwal
Radiologist & Director
MAMC & Lok Nayak Hospital



NAME	:Mr. ADITYA MISHRA	Barcode No	:10141616
AGE/GENDER	:29 YRS/Male	SPECIMEN DATE	:04/Apr/2023 09:09AM
PATIENT ID	:111916	SPECIMEN RECEIVED	:04/Apr/2023 01:10PM
REFERRED BY	:Dr. MEDIWHEEL	REPORT DATE	:04/Apr/2023 01:47PM
CENTRE NAME	:ONEPLUS ULTRASOUND LAB	LAB NO.	:012304040013

Test Name	Result	Unit	Ref. Range
1-12 mths	1.70 - 9.1	21 - 80 yrs	0.25 - 5.0
1-5 yrs	0.80 - 8.2	I st trimester	0.25 - 5.0
6-10 yrs	0.25 - 5.0	II nd trimester	0.50 - 5.0
11-15 yrs	0.25 - 5.0	II rd trimester	0.4 - 6.0

Reference ranges - Interpretation of Diagnostic tests - (Jacques Wallach)

1. Primary hypothyroidism is accompanied by depressed serum T3 and T4 values and elevated serum TSH level.
2. Primary hyperthyroidism is accompanied by elevated serum T3 and T4 levels along with depressed TSH values.
3. Slightly elevated T3 levels may be found in pregnancy and estrogen therapy, while depressed levels may be encountered in severe illness, renal failure and during therapy with drugs like propranolol and propyl thiouracil.
4. Although elevated TSH levels are nearly always indicative of primary hypothyroidism, and may be seen in secondary thyrotoxicosis

CLINICAL PATHOLOGY

URINE ROUTINE

Physical examination

Quantity	30	ML
Colour	PALE YELLOW	
Transparency	CLEAR	CLEAR
Sp.gravity	1.015	1.010-1.030
pH	6.00	
Reaction	ACIDIC	ACIDIC

Chemical examination

Urine protein	NIL	NIL
Urine sugar	NIL	NIL
Bilirubin, urine	NEGATIVE	NEGATIVE
Urobilinogen	NORMAL	NORMAL
Ketones	NEGATIVE	NEGATIVE

Microscopic examination

Pus cells.	2-3	/HPF	0-2
Epithelial cells	2-3	/HPF	NIL

Checked By.

DR. NITIN AGARWAL
M.B.B.S., MD (P)
MAMC/19/01476
DR. NITIN AGARWAL
MBBS, MD(PATHOLOGIST)

47, Harsh Vihar, Pitampura, New Delhi-110034 | Ph.: 011-42480101, 9599913051

E-mail: oneplusul@gmail.com | Web.: www.oneplusul.in

Page 4 of 5



NAME	:Mr. ADITYA MISHRA	Barcode No	:10141616
AGE/GENDER	:29 YRS/Male	SPECIMEN DATE	:04/Apr/2023 09:09AM
PATIENT ID	:111916	SPECIMEN RECEIVED	:04/Apr/2023 01:10PM
REFERRED BY	:Dr. MEDIWHEEL	REPORT DATE	:04/Apr/2023 01:47PM
CENTRE NAME	:ONEPLUS ULTRASOUND LAB	LAB NO.	:012304040013

Test Name	Result	Unit	Ref. Range
R.B.C.	NIL	/HPF	NIL
Casts	NIL	/HPF	NIL
Crystals	NIL	/HPF	NIL
Bacteria	NIL	/HPF	NIL
Others.	NIL	NIL	NIL

*** End Of Report ***

Checked By.

DR. NITIN AGARWAL
MBBS, MD (PATHOLOGY)
51122/01426
DR. NITIN AGARWAL
MBBS, MD (PATHOLOGIST)

47, Harsh Vihar, Pitampura, New Delhi-110034 | Ph.: 011-42480101, 9599913051
E-mail: oneplusul@gmail.com | Web.: www.oneplusul.in

Page 5 of 5

Name	: Mr. ADITYA MISHRA	Age/Sex	: 29 YRS/Male
Ref. By	: Dr. MEDIWHEEL	Lab No	: 012304040013
Date	: 04-Apr-2023	Patient ID	: LSHHI111916

ULTRASOUND EXAMINATION----WHOLE ABDOMEN

Liver is normal in size (14.3 cm) and outline with normal echopattern. **Diffuse increase in echogenicity of liver parenchyma is noted, suggestive of fatty infiltration (grade I).** No abscess or mass lesion seen. Hepatic veins, portal vein, IVC and aorta are normal. Intrahepatic biliary radicles are not dilated. CBD is normal in caliber.

Gall bladder is well distended with anechoic lumen. Wall thickness is normal.

Both kidneys are normal in size, shape, position, outline and echopattern. Corticomedullary differentiation is maintained. No pelvicalyceal dilation or calculus or mass lesion is seen.

Spleen is normal in size and echotexture. No mass lesion seen.

Pancreas is normal in size, outline and echotexture.

Urinary bladder is normal in shape and position. No evidence of intravesical stone or mass seen.

Prostate is normal in size, shape and echopattern.

Prostate measures 4.1 x 3.2 x 2.8 cm. **Weight of prostate is 20.1 grams.**

No abnormal bowel wall thickening seen in right iliac fossa.

No free fluid seen anywhere in abdomen.

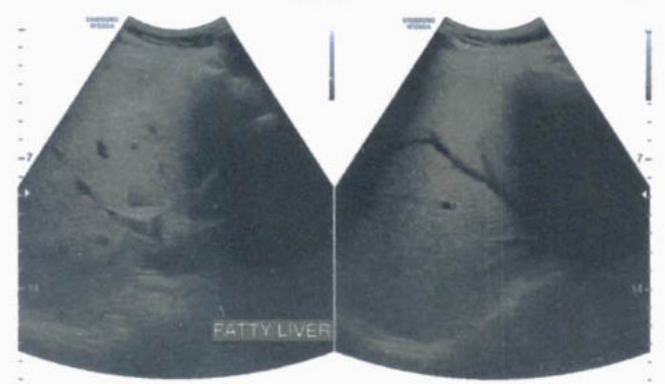
IMPRESSION: Fatty infiltration of liver (grade I) with no hepatomegaly.

DR. POOJA GARG
RADIOLOGIST
M.B.B.S., D.M.R.D
Reg No. DMC/R/03398
Radiologist

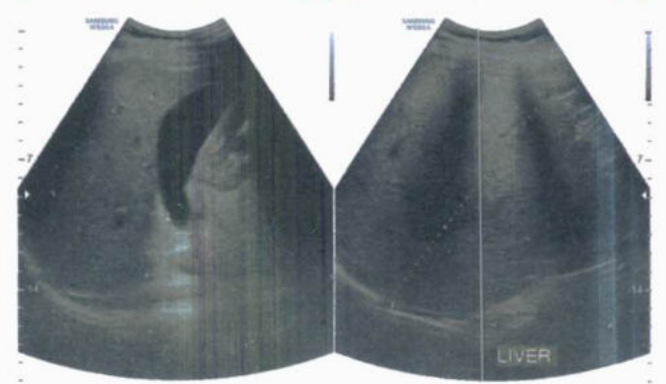
Type By : darshita

47, Harsh Vihar, Pitampura, New Delhi-110034 | Ph.: 011-42480101, 9599913051
E-mail: oneplusul@gmail.com | Web.: www.oneplusul.in

MR ADITYA 29/M
OnePlus Ultrasound Lab MI 1.4 04-04-2023
CA1-7A / Abdomen / FR 22Hz Tls 0.1 10:53:39 AM

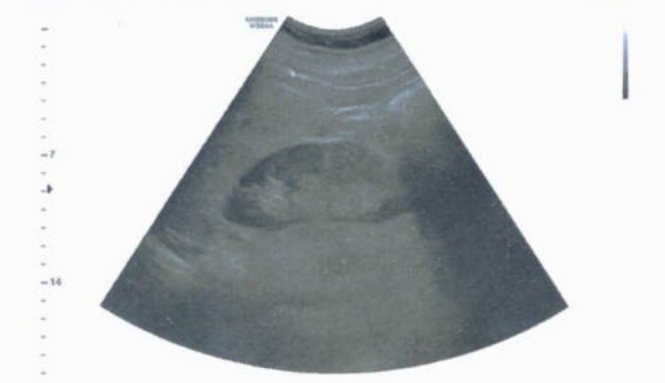

MR ADITYA 29/M
OnePlus Ultrasound Lab MI 1.4 04-04-2023
CA1-7A / Abdomen / FR 22Hz Tls 0.1 10:53:58 AM

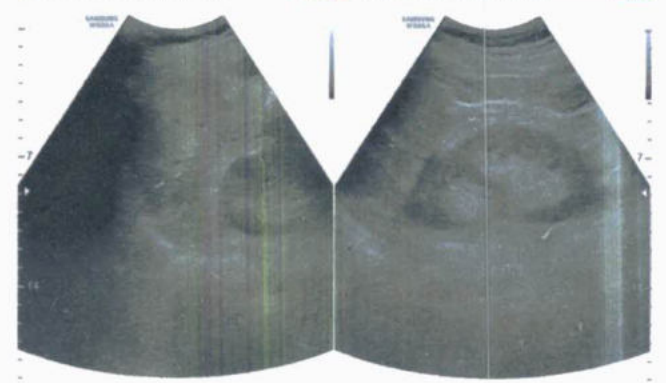

D1 14.32 cm

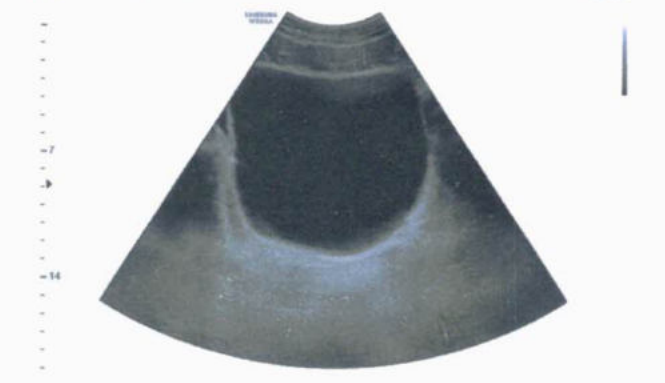
MR ADITYA 29/M
OnePlus Ultrasound Lab MI 1.4 04-04-2023
CA1-7A / Abdomen / FR 22Hz Tls 0.1 10:54:20 AM



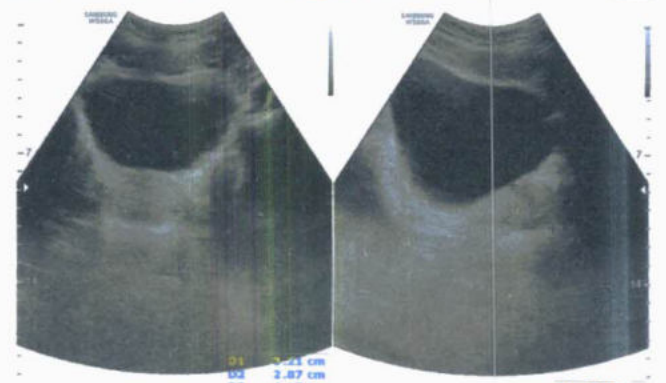
MR ADITYA 29/M
OnePlus Ultrasound Lab MI 1.4 04-04-2023
CA1-7A / Abdomen / FR 22Hz Tls 0.1 10:54:46 AM



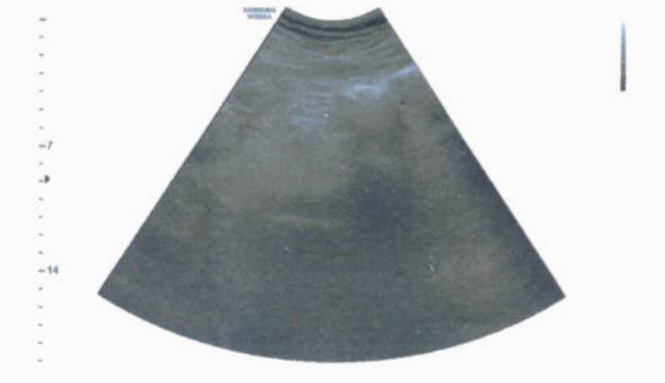MR ADITYA 29/M
OnePlus Ultrasound Lab MI 1.4 04-04-2023
CA1-7A / Abdomen / FR 22Hz Tls 0.1 10:54:58 AM



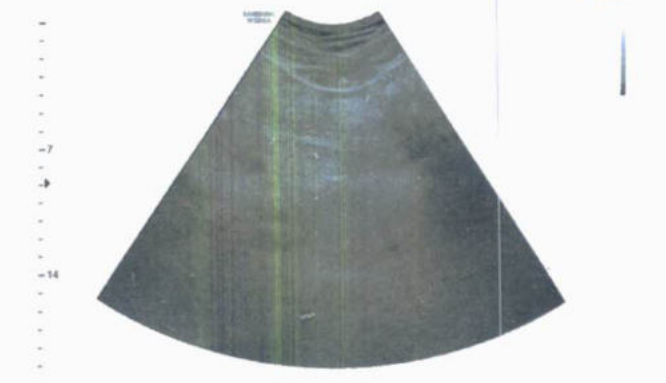
MR ADITYA 29/M
OnePlus Ultrasound Lab MI 1.4 04-04-2023
CA1-7A / Abdomen / FR 22Hz Tls 0.1 10:55:16 AM



MR ADITYA 29/M
OnePlus Ultrasound Lab MI 1.4 04-04-2023
CA1-7A / Abdomen / FR 22Hz Tls 0.1 10:55:46 AM



MR ADITYA 29/M
OnePlus Ultrasound Lab MI 1.4 04-04-2023
CA1-7A / Abdomen / FR 22Hz Tls 0.1 10:56:10 AM





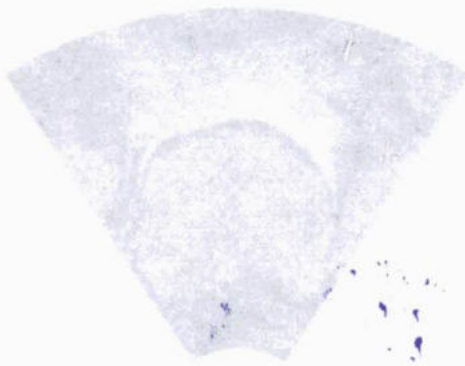100000

100000



100000

100000



100000

100000



100000



100000



100000

100000



100000



100000



100000

100000



100000



100000

100000



OnePLUS
Ultrasound Lab

— QUALITY FIRST... ALWAYS! —

Dr. Nitin Agarwal

Pathologist & Director
Ex. Sr. Res. MAMC
& Lok Nayak Hospital
Ex. Chief of Lab Dr. Lal Path Labs.

Dr. Pooja (Garg) Agarwal

Radiologist & Director
MAMC & Lok Nayak Hospital

Name	: Mr. ADITYA MISHRA	Age/Sex	: 29 YRS/Male
Ref. By	: Dr. MEDIWHEEL	Lab No	: 012304040013
Date	: 04-Apr-2023	Patient ID	: LSHHI111916

X-ray-Chest PA view

Bony cage and soft tissues are normal.
Cardiothoracic ratio is normal.
Mediastinum is normal.
Both hila are normal.
Both costophrenic angles are clear.
Both domes of diaphragm are normal.
Lung fields are clear. No parenchymal lesion seen.

IMPRESSION: Normal Study.

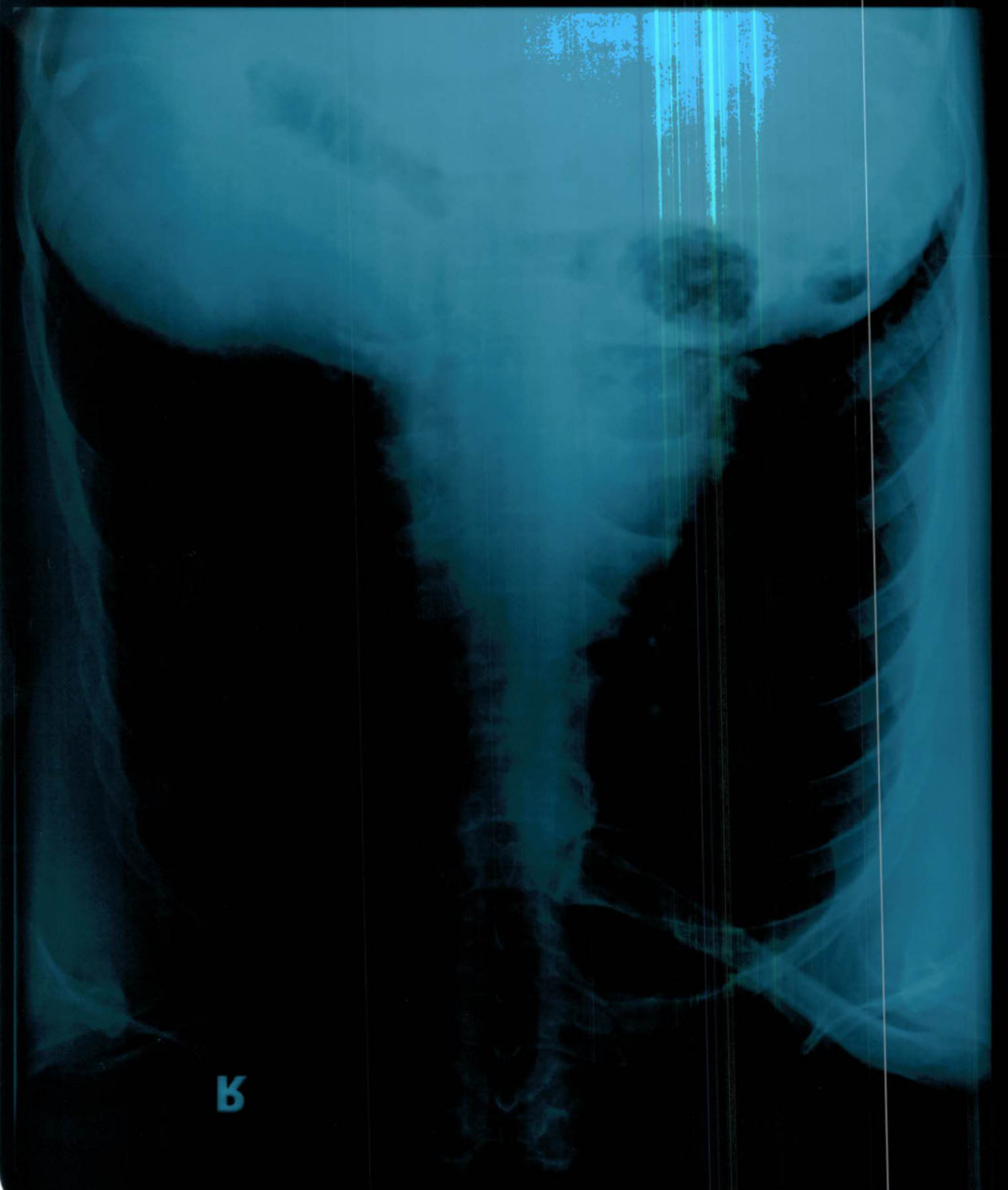
DR. POOJA GARG
M.B.B.S., D.M.R.D.
RADIOLOGIST
Reg No BMC/183398
REG NO- DMC/R/03398

Type By : darshita

47, Harsh Vihar, Pitampura, New Delhi-110034 | Ph.: 011-42480101, 9599913051

E-mail: oneplusul@gmail.com | Web.: www.oneplusul.in

ADITYA MISHRA 29Y/M 4413033 M CHEST PA VIEW 4413033
ONEERUS ULTRASONID LAB. 47-NARSH VINAY PITAMPURA



B

R

ADITYA MISHRA 29Y/M 4/4/2023 M CHEST PA VIEW 4/4/2023
ONEPLUS ULTRASOUND LAB.47-HARSH VIHAR,PITAMPURA