

Health Check up Booking Request(bobE13442),Package Code(PKG1000240),Beneficiary Code(81009)

1 message

Mediwheel <customercare@policywheel.com>

1 July 2022 at 16:14

To: "vidhidiagnostics@gmail.com" <vidhidiagnostics@gmail.com>

Cc: Mediwheel CC <customercare@mediwheel.in>, Mediwheel CC <mediwheelwellness@gmail.com>

011-41195959

Email:wellness@mediwheel.in

Dear Vidhi Diagnostics,
City : Ahmedabad . Location : .New Wadaj,

We have received the following request for Health Check up from

Name : MR. SAXENA ROBIN
Age : 35
Gender : Male
Member Relations : Employee
Package Name : Medi-Wheel Metro Full Body Health Checkup Male Below 40
Package Code : PKG1000240
User Location : Gujarat,AHMEDABAD,382418
Contact Details : 9620809019
Booking Date : 01-07-2022
Appointment Date : 08-07-2022

Member Information			
Booked Member Name	Age	Gender	Cost(In INR)
MR. SAXENA ROBIN	35	Male	Cashless
Total amount to be paid			Cashless

Please login to your account to confirm the same. Also you mail us for confirmation

Package Name : Medi-Wheel Metro Full Body Health Checkup Male Below 40 -
Includes (37)Tests

Tests included in this
Package

Ecg, TSH, X-ray Chest, Stress Test (tmt)/ 2d Echo, Blood Sugar Postprandial, A:g Ratio, Blood Group, Total Cholesterol, Triglycerides, Fasting Blood Sugar, Ultrasound Whole Abdomen , Glycosylated Haemoglobin (hba1c), Hdl, Vldl, Urine Analysis, LDL, Total Protine, General Consultation, HDL/ LDL ratio, GGT(Gamma-glutamyl Transferase), Eye Check-up consultation, ALP (ALKALINE PHOSPHATASE), Uric Acid, AST/ALT Ratio, Serum Protein, CBC with ESR, Stool Analysis, Urine Sugar Fasting, Urine Sugar PP, T3, T4, Cholesterol Total / HDL Ratio, BUN, BUN/Creatinine Ratio, Bilirubin Total & Direct and Indirect, Albumin, Globulin

Dr. Dinesh S. Modh

M.D., D.M.R.E. (Radiodiagnosis)

Consultant Radiologist & Sonologist

Ex. Junior Lecturer, B.J. Medical College, Civil Hospital, A'bad.

Panel Doctor of L.I.C.



08/07/2022

Robim Saxena
36 yrs male

Height! - 164 cm

Weight! - 87 kg.

BP! - 130/90 mmHg

Pulse! - 60 per min

SPO₂! - 99

T! - (N)

RS (N)
CVS (N)

Asymptomatic

No H/O DM, HTN, Thyroid or TB.

Eye checkup! -

R/O normal vision in both
eye with specs (-4.00)

N/O normal vision in both
eye

No night & colour blindness

Vidhi Diagnostics

L-86, Swatantra-Senani Nagar,
Opp. Akharnagar Bus Terminals,
Nr. Akharnagar Circle,
New Vadaj, Ahmedabad-13.

ISO 9001:2015 Certified Diagnostics Center

Vidhi Imaging Center

L-86, Swatantra Senani Nagar, Opp. Akharnagar Petrol Pump, Nr. Akharnagar Circle, Nava-Vadaj, Ahmedabad - 380 013.

Phone : 079-2762 1406, Mobile : 98799 29406, 98250 09406, E-mail : vidhidiagnostics@gmail.com, Website : www.vidhidiagnostics.com

Time : Mon. to Sat. 9.00 am to 2.00 pm, 5.00 pm to 9.00 pm, Sunday 9.00 am to 12.00 Noon

Dr. Vidhi D. Modh
MBBS
Reg. No. G-74640

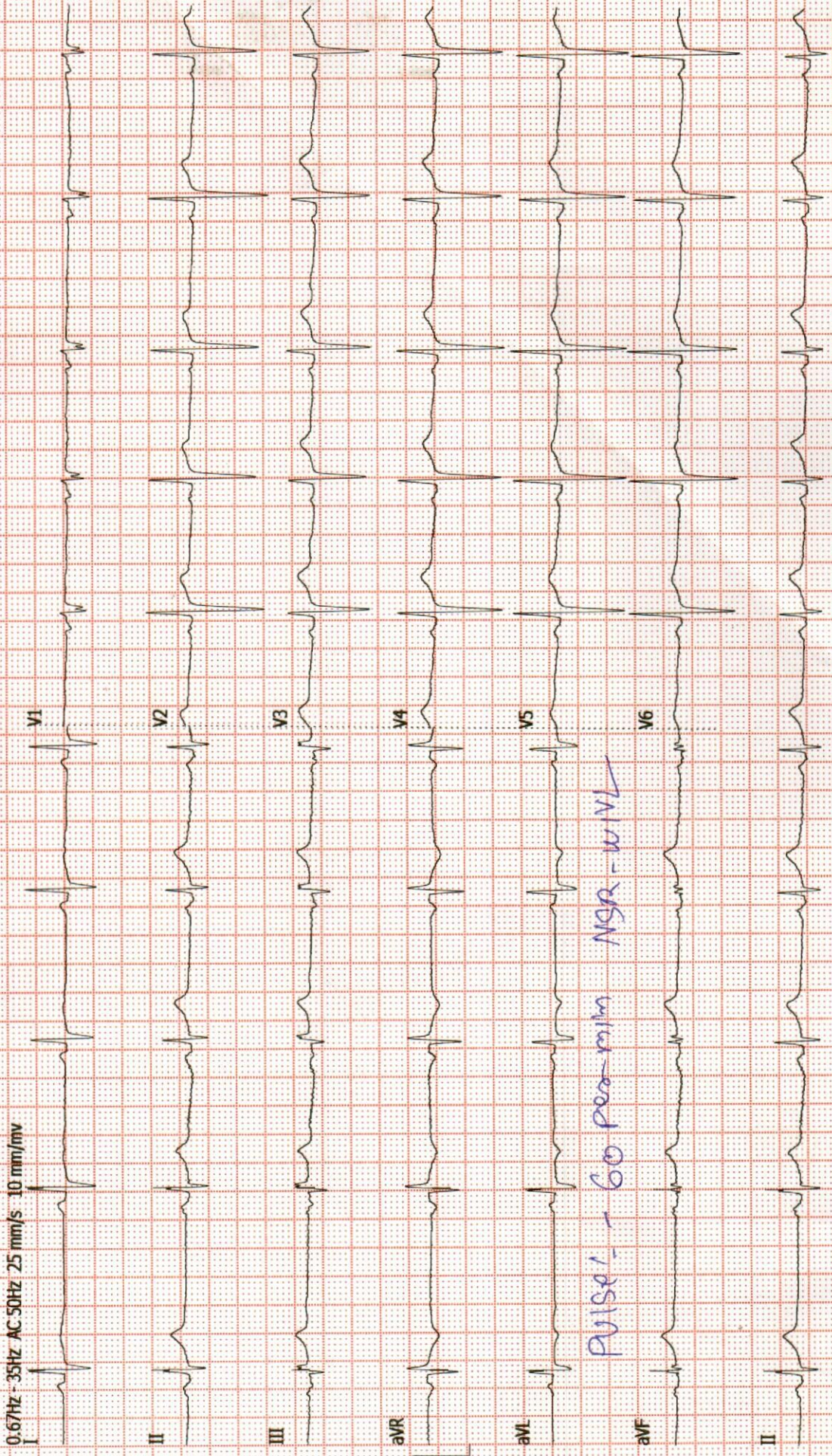
ID: 5439
 Name: robin saxena
 Age: 36yrs
 Sex: Male
 Hospital:
 Department:

HR : 61 bpm
 PR : 142 ms
 QRS : 94 ms
 QT/QTc : 384/386 ms
 P/QRS/T : 18/38/71 deg.
 RV5/SV1 : 0.842/-0.324 mv
 RV5+SV1 : 1.166 mv

Dr. Avinash Bhaskar
 MBBS, D-Cardio
 Reg. No.: G-45946

Vidhi Diagnostics
 I-06, Swatantra-Senani Nagar,
 Opp Akharnagar Bus Terminals,
 Nr. Akharnagar Circle,
 New Wada, Ahmedabad-13.

Need to be confirmed by doctor. Doctor Name: _____



Pulse! - 60 per min NGR - WVL

Dr. Dinesh S. Modh

M.D., D.M.R.E. (Radiodiagnosis)

Consultant Radiologist & Sonologist

Ex. Junior Lecturer, B.J. Medical College, Civil Hospital, A'bad.

Panel Doctor of L.I.C.



Patient's name : ROBIN SAXENA
Reg. ID : R-3917-21
Referred by : Dr. MEDIWHEEL

Age/Sex : 36 Years/Male
Accession : 17621
Date : 08/07/2022

2D- ECHO REPORT

FINAL CONCLUSION:

LV IS NORMAL SIZE. GOOD LV SYSTOLIC FUNCTION NO RWMA.
LVEF - 60%. NO CONCENTRIC LVH.
NORMAL LV COMPLIANCE.
LA IS NORMAL SIZE. NO LA CLOT.
RV IS NORMAL SIZE. GOOD RV SYSTOLIC FUNCTION.
RA IS NORMAL SIZE.
MITRAL VALVE IS NORMAL. NO MS. NO MR. NO MVP.
AORTIC VALVE IS NORMAL. NO AS. NO AR.
TRICUSPID VALVE IS NORMAL. NO TR. RVSP-26 mmHg. NO PAH.

NO CLOT, NO VEGETATION, NO PERICARDIAL EFFUSION.

DIMENSIONS:

AORTA	2.6 C.M
LEFT ATRIUM	2.7 C.M
LVDD	4.1 C.M.
IVSD	1.0 C.M
PWD	1.0 C.M
LVDS	2.6 C.M.

COLOUR DOPPLER FINDING:

STRUCTURE	VELOCITY m/sec
	Max
PULMONARY VALVE	0.7
MITRAL VALVE	E : 0.7 A: 0.4
AORTIC VALVE	1.0

Avinash Bhaskar
Dr. Avinash Bhaskar
MBBS, D Cardio
Reg. No.: G-45946

DR AVINASH BHASKAR

ISO 9001:2015 Certified Diagnostics Center

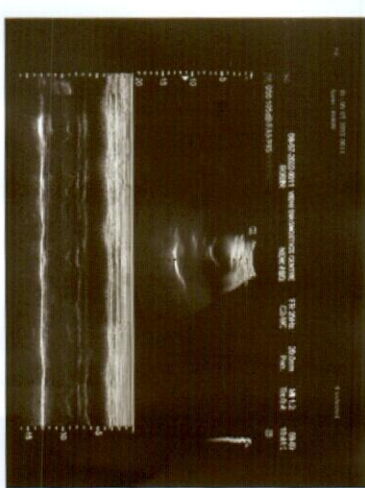
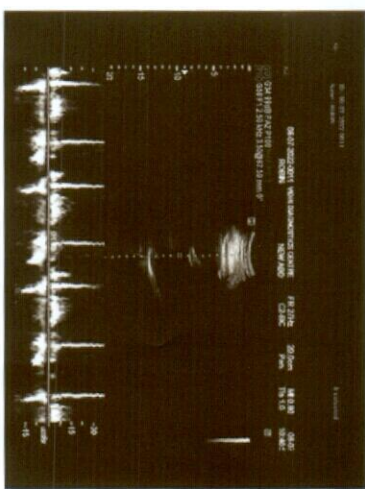
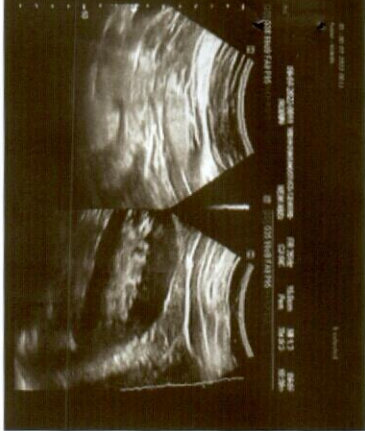
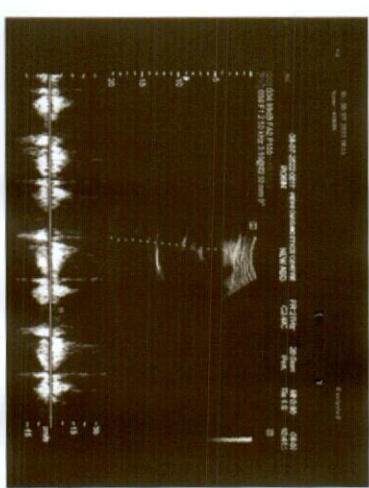
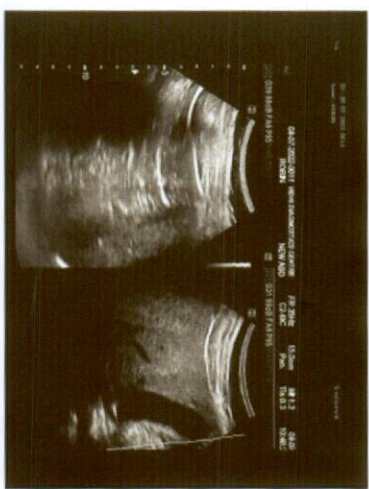
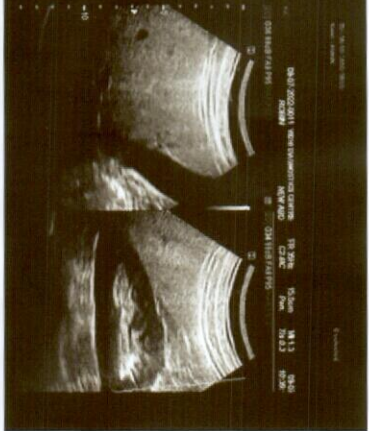
Vidhi Imaging Center

L-86, Swatantra Senani Nagar, Opp. Akhbarnagar Petrol Pump, Nr. Akhbarnagar Circle, Nava-Vadaj, Ahmedabad - 380 013.

Phone : 079-2762 1406, Mobile : 98799 29406, 98250 09406, E-mail : vidhidiagnostics@gmail.com, Website : www.vidhidiagnostics.com

Time : Mon. to Sat. 9.00 am to 2.00 pm, 5.00 pm to 9.00 pm, Sunday 9.00 am to 12.00 Noon

FACILITIES : Live 3D-4D Sonography | Colour Doppler | Echo Cardiography | Interventional Radiology | Fetal Medicine | Digital X-Ray
Digital Mammography | Digital OPG / TMJ | ECG / TMT / PFT / EEG / EMG | Pathology Laboratory | Health Check Up Plans | Pre Employment Check Up



Dr. Dinesh S. Modh

M.D., D.M.R.E. (Radiodiagnosis)

Consultant Radiologist & Sonologist

Ex. Junior Lecturer, B.J. Medical College, Civil Hospital, A'bad.

Panel Doctor of L.I.C.



Patient's name : ROBIN SAXENA
Reg. ID : R-3917-21
Referred by : Dr. MEDIWHEEL

Age/Sex : 36 Years/Male
Accession : 17621
Date : 08/07/2022

USG ABDOMEN

LIVER: Liver is normal in size and bright in echotexture s/o fatty liver grade1. Intrahepatic biliary radicals appear normal.

Portal vein is normal in caliber. Common Bile duct is normal in course & caliber. No e/o calculus is seen in biliary tree.

GALL BLADDER: is distended & appear normal. No e/o calculus or cholecystitis is seen. GB wall thickness appears normal. No evidence of pericholecystic fluid is seen.

SPLEEN: Spleen is normal in size & shows normal echo texture. No evidence of diffuse or focal lesion is seen. Splenic vein appears normal.

PANCREAS: Pancreas appears normal in size & echotexture. No evidence of diffuse or focal lesion is seen. Main pancreatic duct is normal.

KIDNEY: Both kidneys appear normal in size and echopattern. Corticomedullary differentiation is maintained.

No evidence of calculus or hydronephrosis is seen on both sides.
Both supra renal region appear normal.

No evidence of pre & para aortic lymphadenopathy is seen.

Gas filled non-dilated bowel loops are seen in abdomen.

No evidence of free fluid is seen in abdomen.

No evidence of dilated or thickened bowel loops is seen.

Urinary bladder appears normal. No e/o calculus or mass lesion is seen.

Prostate appears normal in size & echopattern.

Thanks for reference.

Dr. Dinesh S. Modh
MD DMRE (Radiodiagnosis)

G-23825
DR DINESH S. MODH

M.D. DMRE(RADIODIAGNOSIS)

ISO 9001:2015 Certified Diagnostics Center

Vidhi Imaging Center

L-86, Swatantra Senani Nagar, Opp. Akhbarnagar Petrol Pump, Nr. Akhbarnagar Circle, Nava-Vadaj, Ahmedabad - 380 013.

Phone : 079-2762 1406, Mobile : 98799 29406, 98250 09406, E-mail : vidhidiagnostics@gmail.com, Website : www.vidhidiagnostics.com

Time : Mon. to Sat. 9.00 am to 2.00 pm, 5.00 pm to 9.00 pm, Sunday 9.00 am to 12.00 Noon

FACILITIES : Live 3D-4D Sonography | Colour Doppler | Echo Cardiography | Interventional Radiology | Fetal Medicine | Digital X-Ray
Digital Mammography | Digital OPG / TMJ | ECG / TMT / PFT / EEG / EMG | Pathology Laboratory | Health Check Up Plans | Pre Employment Check Up

Dr. Dinesh S. Modh

M.D., D.M.R.E. (Radiodiagnosis)

Consultant Radiologist & Sonologist

Ex. Junior Lecturer, B.J. Medical College, Civil Hospital, A'bad.

Panel Doctor of L.I.C.



Patient's name : ROBIN SAXENA
Reg. ID : R-3917-21
Referred by : Dr. MEDIWHEEL

Age/Sex : 36 Years/Male
Accession : 17621
Date : 08/07/2022

X-RAY CHEST (PA VIEW)

Both lung fields appear normal.
No e/o consolidation or cavitations is seen.
Both costo-phrenic angles appear clear.
Cardiac size is within normal limits.
Both domes of diaphragm appear normal.
Bony thoracic cage appears normal.

Thanks for reference.


Dr. Dinesh S. Modh
MD DMRE (Radiodiagnosis)
G-23825
DR DINESH S. MODH
M.D. DMRE(RADIODIAGNOSIS)

ISO 9001:2015 Certified Diagnostics Center

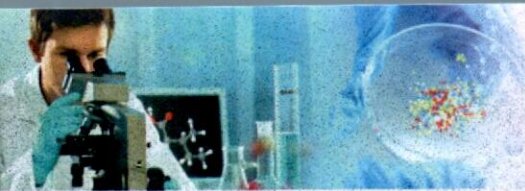Vidhi Imaging Center

L-86, Swatantra Senani Nagar, Opp. Akhbarnagar Petrol Pump, Nr. Akhbarnagar Circle, Nava-Vadaj, Ahmedabad - 380 013.

Phone : 079-2762 1406, Mobile : 98799 29406, 98250 09406, E-mail : vidhidiagnostics@gmail.com, Website : www.vidhidiagnostics.com

Time : Mon. to Sat. 9.00 am to 2.00 pm, 5.00 pm to 9.00 pm, Sunday 9.00 am to 12.00 Noon

FACILITIES : Live 3D-4D Sonography | Colour Doppler | Echo Cardiography | Interventional Radiology | Fetal Medicine | Digital X-Ray
Digital Mammography | Digital OPG / TMJ | ECG / TMT / PFT / EEG / EMG | Pathology Laboratory | Health Check Up Plans | Pre Employment Check Up



Creating life in Images



Pathology Department

Patient's name : ROBIN SAXENA
Age/Sex : 36 Years/Male
Referred by : Dr. MEDIWHEEL
Collection Time : 10:02

Reg. ID : P-2472-21
Accession : 17620
Order Dt/time : 08/07/2022 10:02

Complete Blood Count

Sample Type: EDTA

Test Name	Result	Units	Biological Reference Interval
<u>Blood Counts</u>			
Haemoglobin :	14.5	Gms%	13.5 - 18.0
Total R.B.C. :	4.38	mill/c.mm	4.7 - 6.0
Total W. B. C. :	7,500	/cu mm	4000 - 10500
Platelet Count :	2,63,000	/cu.mm	1,50,000 - 4,50,000
<u>Differential Count</u>			
Neutrophils :	62	%	40 - 70
Lymphocytes :	34	%	20 - 40
Eosinophils :	02	%	1 - 4
Monocytes :	02	%	2 - 6
Basophils :	00	%	0 - 01
<u>Blood Indices</u>			
P. C. V :	43.1	%	42 - 52
M. C. V. :	98.6	fl	78 - 100
M.C.H :	33.1	pg	27 - 31
M. C. H. C :	33.5	%	32 - 36
R.D.W :	13.5	%	11.5 - 14.0
<u>E.S.R.(Westergren Method)</u>			
After one hour :	04	mm/hr	1 - 7

TESTS DONE ON FULLY AUTOMATED HEMATOLOGY ANALYZER.

Dr. Gayatri M. Mehta
M. D. (Patho)

DR GAYATRI MEHTA
MD(PATHOLOGY) 32215

DR. ANAND D. PARIKH
MD(PATHOLOGY)

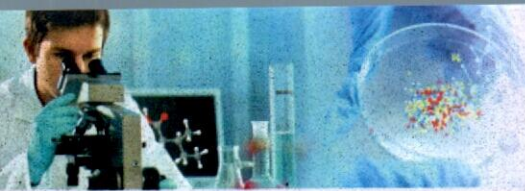LAB USE ONLY (Entered by :GM Enter Date/Time:08/07/2022 11:32:00 AM) (Verify by :GM Verify Date/Time:08/07/2022 6:19:00 PM)

ISO 9001:2015 Certified Diagnostics Center
Vidhi Imaging Center | Pathology Department


L-86, Swatantra Senani Nagar, Opp. Akhbarnagar Petrol Pump, Nr. Akhbarnagar Circle, Nava-Vadaj, Ahmedabad - 380 013.
Ph. (Pathology) : 079-2764 5405, 8849893954 M. 98799 29406, 98250 09406, E-mail : vidhidiagnostics@gmail.com, Web. : www.vidhidiagnostics.com
Time (Pathology) : Mon. to Sat. 8.30 am to 8.00 pm, Sunday 9 am to 12 Noon

Pathology means science behind medicine

CT SCAN & CBCT FACILITY NOW AVAILABLE



Pathology Department



Patient's name : ROBIN SAXENA
Age/Sex : 36 Years/Male
Referred by : Dr. MEDIWHEEL
Collection Time : 10:02

Reg. ID : P-2472-21
Accession : 17620
Order Dt/time : 08/07/2022 10:02

Blood Group

Sample Type: EDTA sample.

Test Name	Result
BG :	" AB "
RH :	NEGATIVE
Remarks	Done by forward grouping method.

Dr. Gayatri M. Mehta
M. D. (Patho)

Reg. No. G-32215
DR GAYATRI MEHTA
MD(PATHOLOGY)

DR. ANAND D. PARIKH
MD(PATHOLOGY)

LAB USE ONLY (Entered by :GM Enter Date/Time:08/07/2022 3:58:00 PM) (Verify by :GM Verify Date/Time:08/07/2022 6:19:00 PM)

ISO 9001:2015 Certified Diagnostics Center

Vidhi Imaging Center | Pathology Department

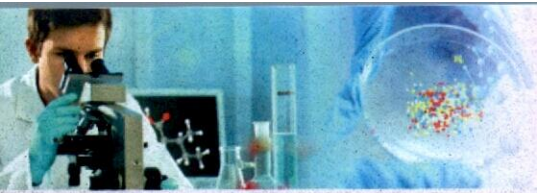L-86, Swatantra Senani Nagar, Opp. Akhbarnagar Petrol Pump, Nr. Akhbarnagar Circle, Nava-Vadaj, Ahmedabad - 380 013.

Ph. (Pathology) : 079-2764 5405, 8849893954 M. 98799 29406, 98250 09406, E-mail : vidhidiagnostics@gmail.com, Web. : www.vidhidiagnostics.com

Time (Pathology) : Mon. to Sat. 8.30 am to 8.00 pm, Sunday 9 am to 12 Noon

Pathology means science behind medicine

CT SCAN & CBCT FACILITY NOW AVAILABLE



Pathology Department



Patient's name : ROBIN SAXENA
Age/Sex : 36 Years/Male
Referred by : Dr. MEDIWHEEL
Collection Time : 10:02

Reg. ID : P-2472-21
Accession : 17620
Order Dt/time : 08/07/2022 10:02

Blood Glucose

Sample Type: Serum

Test Name	Result	Units	Biological Reference Interval
Fasting Blood Glucose : <i>GOD-POD Method.</i>	147.4	mg/dl	70 - 110

Lipid Profile

Sample Type: Serum

Test Name	Result	Units	Biological Reference Interval
S. Cholesterol : <i>Oxidase-esterase method.</i>	200.0	mg/dl	0 - 200
S. Triglyceride : <i>Enzymatic Colorimetry method</i>	139.9	mg/dL	0 - 200
S. HDL - Cholesterol : <i>Serum by Enzymatic method.</i>	53.5	mg/dL	35 - 65
S. LDL - Cholesterol : <i>Serum by Enzymatic method</i>	118.52	mg/dL	0 - 130
S. VLDL - Cholesterol :	27.98	mg/dL	0 - 30
S. Chole/HDL.Ratio :	3.74		1 - 6
S. LDL / HDL Cholesterol Ratio :	2.22		0 - 3.5

Dr. Gayatri M. Mehta
DR. GAYATRI MEHTA M. D. (Patho)
MD(PATHOLOGY)-32215

DR. ANAND D. PARIKH
MD(PATHOLOGY)

LAB USE ONLY (Entered by :GM Enter Date/Time:08/07/2022 3:59:00 PM) (Verify by :GM Verify Date/Time:08/07/2022 6:19:00 PM)

ISO 9001:2015 Certified Diagnostics Center

Vidhi Imaging Center | Pathology Department

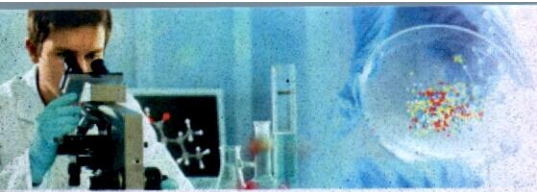L-86, Swatantra Senani Nagar, Opp. Akhbar Nagar Petrol Pump, Nr. Akhbar Nagar Circle, Navā-Vadaj, Ahmedabad - 380 013.

Ph. (Pathology) : 079-2764 5405, 8849893954 M. 98799 29406, 98250 09406, E-mail : vidhidiagnostics@gmail.com, Web. : www.vidhidiagnostics.com

Time (Pathology) : Mon. to Sat. 8.30 am to 8.00 pm, Sunday 9 am to 12 Noon

Pathology means science behind medicine

CT SCAN & CBCT FACILITY NOW AVAILABLE



Pathology Department



Patient's name : ROBIN SAXENA
Age/Sex : 36 Years/Male
Referred by : Dr. MEDIWHEEL
Collection Time : 10:02

Reg. ID : P-2472-21
Accession : 17620
Order Dt/time : 08/07/2022 10:02

HbA1C

Sample Type: Serum

Test Name	Result	Units	Biological Reference Interval
HbA1C :	<u>7.0</u>	%	Non-diabetic: 4.2-6.2 Pre-diabetic : 6.3-7.2 Diabetic : 7.3-8.2
Mean Blood Glucose of Last 03 months.	154.2	mg/dl	

Comment

*As per the new 2009 update of American Diabetes Association regarding HbA1C & Mean Blood Glucose relationship.

NOTE:

This test is used to monitor diabetic patients compliance with the therapeutic regimen and logo It's level is proportional to both the average blood glucose concentration and the life span of the red blood cells (RBC) in circulation. HbA1c values are free of day to day glucose fluctuations and are unaffected by exercise or recent food intake.

Dr. Gayatri M. Mehta
M. D. (Patho)

DR GAYATRI MEHTA
MD(PATHOLOGY)

DR. ANAND D. PARIKH
MD(PATHOLOGY)

LAB USE ONLY (Entered by :GM Enter Date/Time:08/07/2022 3:58:00 PM) (Verify by :GM Verify Date/Time:08/07/2022 6:19:00 PM)

ISO 9001:2015 Certified Diagnostics Center

Vidhi Imaging Center | Pathology Department

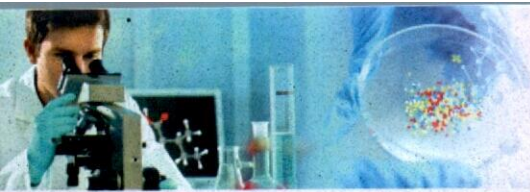L-86, Swatantra Senani Nagar, Opp. Akharnagar Petrol Pump, Nr. Akharnagar Circle, Nava-Vadaj, Ahmedabad - 380 013.

Ph. (Pathology) : 079-2764 5405, 8849893954 M. 98799 29406, 98250 09406, E-mail : vidhidiagnostics@gmail.com, Web. : www.vidhidiagnostics.com

Time (Pathology) : Mon. to Sat. 8.30 am to 8.00 pm, Sunday 9 am to 12 Noon

Pathology means science behind medicine

CT SCAN & CBCT FACILITY NOW AVAILABLE



Pathology Department

VIDHI
DIAGNOSTICS

Creating life in Images

Patient's name : ROBIN SAXENA
Age/Sex : 36 Years/Male
Referred by : Dr. MEDIWHEEL
Collection Time : 10:02

Reg. ID : P-2472-21
Accession : 17620
Order Dt/time : 08/07/2022 10:02

BIOCHEMISTRY

Sample type : Serum

Test Name	Result	Units	Biological Reference Interval
Urea, (Serum by GLDH method) :	20.5	mg/dl	10 - 50
S.Uric acid, (Serum by Uricase method) :	5.6	mg/dl	3.4 - 7.0
Bun :	9.6	mg/dl	6-20
Creatinine, (Serum by Enzymatic reaction) :	0.72	mg/dl	0.5-1.2
S.G.P.T (ALT) : (Serum by IFCC method)	80.6	U/L	0 - 40
S.G.O.T (AST) : (Serum by IFCC method)	41.1	U/L	0 - 37
ALK.PHOSPHATASE : (Serum by PNP method)	127.0	U/L	40-129
G.G.T :	23.4	U/L	8 - 78
<u>BILIRUBIN</u>			
Total :	0.85	mg/dl	Up to 1.2
Direct :	0.37	mg/dl	0-0.7
Indirect :	0.48	mg/dl	0 - 0.5
<u>SERUM PROTEINS</u>			
Total Protein (Serum by Biuret method) :	7.56	gms/dl	6.6 - 8.7
Albumin (Serum by BCG method) :	4.23	gms/dl	3.97-4.94
Globulins :	3.33	gms/dl	2.3 - 3.5
A/G Ratio :	1.27		0.9 - 2.9

Dr. Gayatri M. Mehta

M. D. (Patho)

Reg. No. G-32215

DR GAYATRI MEHTA
MD(PATHOLOGY)

DR. ANAND D. PARIKH
MD(PATHOLOGY)

LAB USE ONLY (Entered by : GM Enter Date/Time:08/07/2022 3:58:00 PM) (Verify by : GM Verify Date/Time:08/07/2022 6:19:00 PM)

ISO 9001:2015 Certified Diagnostics Center

Vidhi Imaging Center | Pathology Department

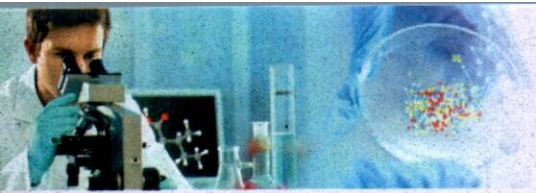L-86, Swatantra Senani Nagar, Opp. Akhbaragar Petrol Pump, Nr. Akhbaragar Circle, Nava-Vadaj, Ahmedabad - 380 013.

Ph. (Pathology) : 079-2764 5405, 8849893954 M. 98799 29406, 98250 09406, E-mail : vidhidiagnostics@gmail.com, Web. : www.vidhidiagnostics.com

Time (Pathology) : Mon. to Sat. 8.30 am to 8.00 pm, Sunday 9 am to 12 Noon

Pathology means science behind medicine

CT SCAN & CBCT FACILITY NOW AVAILABLE



Pathology Department



Patient's name : ROBIN SAXENA
Age/Sex : 36 Years/Male
Referred by : Dr. MEDIWHEEL
Collection Time : 10:02

Reg. ID. : P-2472-21
Accession : 17620
Order Dt/time : 08/07/2022 10:02

Thyroid Function Test

Sample Type: Serum

Test Name	Result	Units	Biological Reference Interval
TOTAL T3 :	1.49	ng/ml	0.84 - 2.0
TOTAL T4 :	10.77	ug/dl	5.1 - 14.0
TSH(Ultra sensitive) :	2.037	mIU/L	0.27 - 4.2
Method	Electrochemiluminescence Immunoassay "ECLIA"		

Test done on Roche Cobas e411 Immunoassay Analyser

Dr. Gayatri M. Mehta
M. D. (Patho)
DR. GAYATRI MEHTA
MD (PATHOLOGY) 32215

DR. ANAND D. PARIKH
MD (PATHOLOGY)

LAB USE ONLY (Entered by :GM Enter Date/Time:08/07/2022 3:59:00 PM) (Verify by :GM Verify Date/Time:08/07/2022 6:19:00 PM)

ISO 9001:2015 Certified Diagnostics Center
Vidhi Imaging Center | Pathology Department

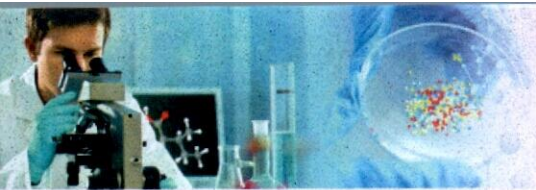L-86, Swatantra Senani Nagar, Opp. Akhbarnagar Petrol Pump, Nr. Akhbarnagar Circle, Nava-Vadaj, Ahmedabad - 380 013.

Ph. (Pathology) : 079-2764 5405, 8849893954 M. 98799 29406, 98250 09406, E-mail : vidhidiagnostics@gmail.com, Web. : www.vidhidiagnostics.com

Time (Pathology) : Mon. to Sat. 8.30 am to 8.00 pm, Sunday 9 am to 12 Noon

Pathology means science behind medicine

CT SCAN & CBCT FACILITY NOW AVAILABLE



Pathology Department



Patient's name : ROBIN SAXENA
 Age/Sex : 36 Years/Male
 Referred by : Dr. MEDIWHEEL
 Collection Time : 10:02

Reg. ID : P-2472-21
 Accession : 17620
 Order Dt/time : 08/07/2022 10:02

Urine Analysis

Sample Type: Urine

Test Name	Result	Units	Biological Reference Interval
<u>Physical Examination</u>			
Quantity :	20	ml	0 - 500 ml
Colour :	Yellowish		Pale Yellow
Transparency :	Slight Turbid.		Clear
Reaction :	Acidic		4.6 - 8.0
Specific Gravity :	1.030		1.016 - 1.022
Sediment :	Present		
<u>Chemical Examination</u>			
Albumin :	Present (Trace)		Absent
Sugar :	NIL		Absent
Acetone :	Absent		Absent
Bile Salts :	Absent		Absent
Bile Pigments :	Absent		Absent
Urobilogen :	Absent		Absent
Nitrites :	Absent		Absent
<u>Microscopic Examination</u>			
Red blood Cells :	2-3	/h.p.f	Absent
Pus Cells :	1-2	/h.p.f	Absent
Epithelial Cells :	1-2	/h.p.f	< 10.0
Amorphous :	Absent	/h.p.f	Absent
Bacteria :	Absent	/h.p.f	Absent
Crystals :	Absent	/h.p.f	Absent
Casts :	Absent	/h.p.f	Absent
Fungus :	Not seen	/h.p.f	Absent

Dr. Gayatri M. Mehta
 M. D. (Patho)

DR. GAYATRI MEHTA
 MD(PATHOLOGY)

DR. ANAND D. PARIKH
 MD(PATHOLOGY)

ISO 9001:2015 Certified Diagnostics Center

LAB USE ONLY (Entered by :GM Entered Date/Time: 08/07/2022 3:58:00 PM) Verify by: GMent Verify Date/Time: 08/07/2022 6:19:00 PM)

L-86, Swatantra Senani Nagar, Opp. Akhbarnagar Petrol Pump, Nr. Akhbarnagar Circle, Nava-Vadaj, Ahmedabad - 380 013.

Ph. (Pathology) : 079-2764 5405, 8849893954 M. 98799 29406, 98250 09406, E-mail : vidhidiagnostics@gmail.com, Web. : www.vidhidiagnostics.com

Time (Pathology) : Mon. to Sat. 8.30 am to 8.00 pm, Sunday 9 am to 12 Noon

Pathology means science behind medicine

CT SCAN & CBCT FACILITY NOW AVAILABLE

AADHAAR CARD



Robin Saxena

1985-10-05

MALE

XXXXXXXXX4155

Address

S/O Ishwar Kant Saxena, C/958, Dewa Road, Durgapuri,
Nawabganj, Bara Banki, Uttar Pradesh, 225001



~~XXXXXXXXXXXX~~
~~XXXXXXXXXXXX~~
~~REG. NO. G-74540~~

Robin Saxena

Did you know?

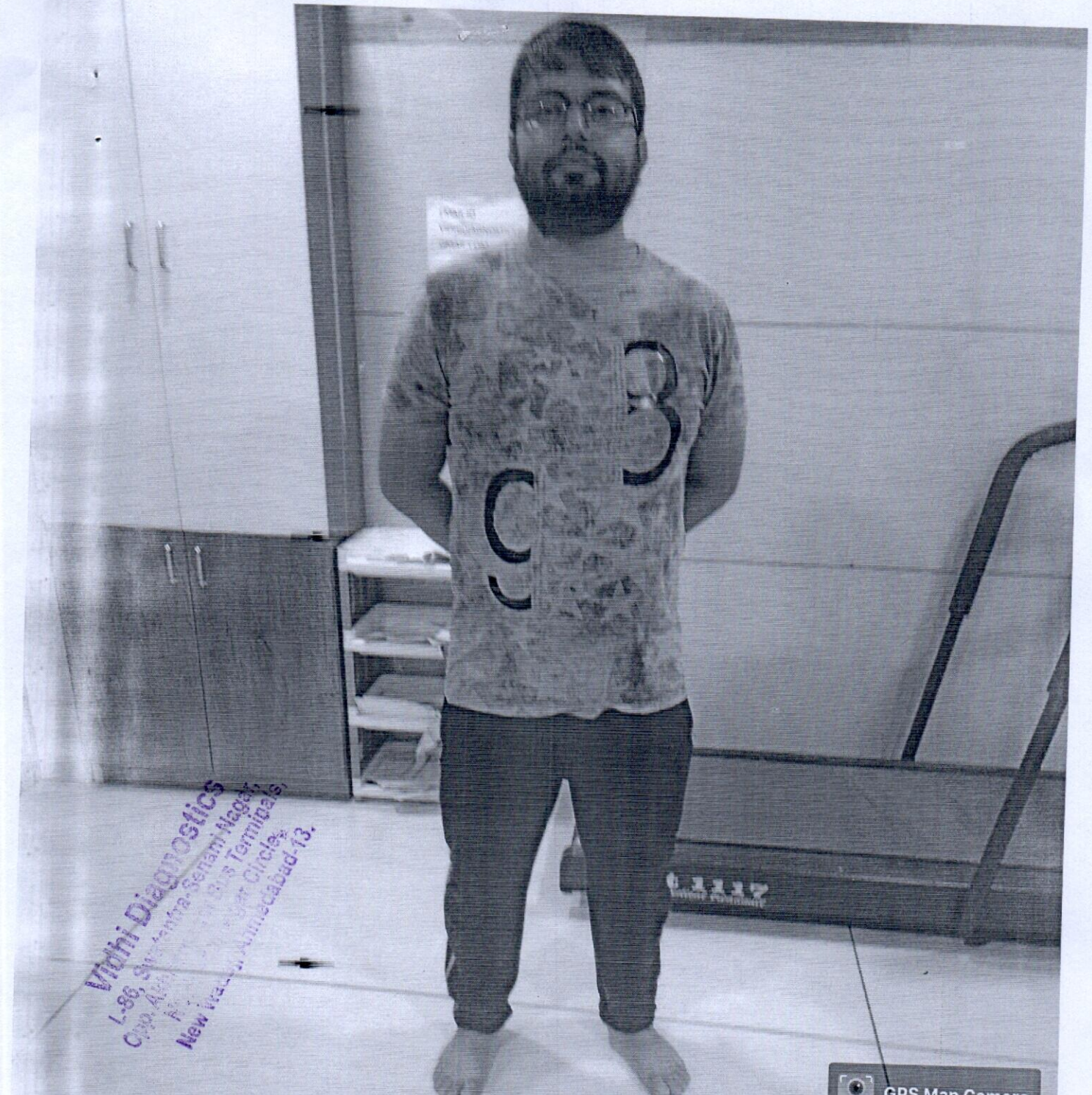
Vidhi Diagnostics
L-86, Swatantra-Senani Nagar,
Opp. Akhbarnagar Bus Termipals,
Nr. Akhbarnagar Circle,
New Wadaj, Ahmedabad-13.

Indian Railways and Airports accept Digital Aadhaar through DigiLocker as valid identity proof.

Dr. Vidhi D. Modh
MBBS
Reg. No. G-74540

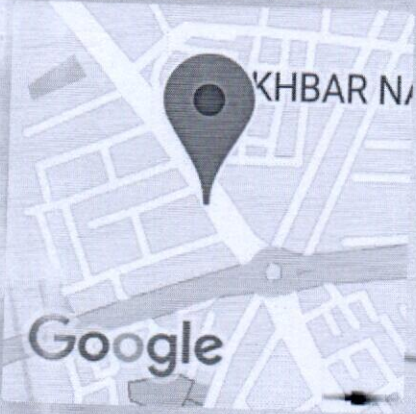Tell your friends and family about DigiLocker





Vidhi Diagnostics
L-86, Swatantra Senani Nagar,
Opp. Akhbar Nagar, Farmigals,
Nr. Akhbar Nagar Circle,
New Wada, Ahmedabad-13.

GPS Map Camera



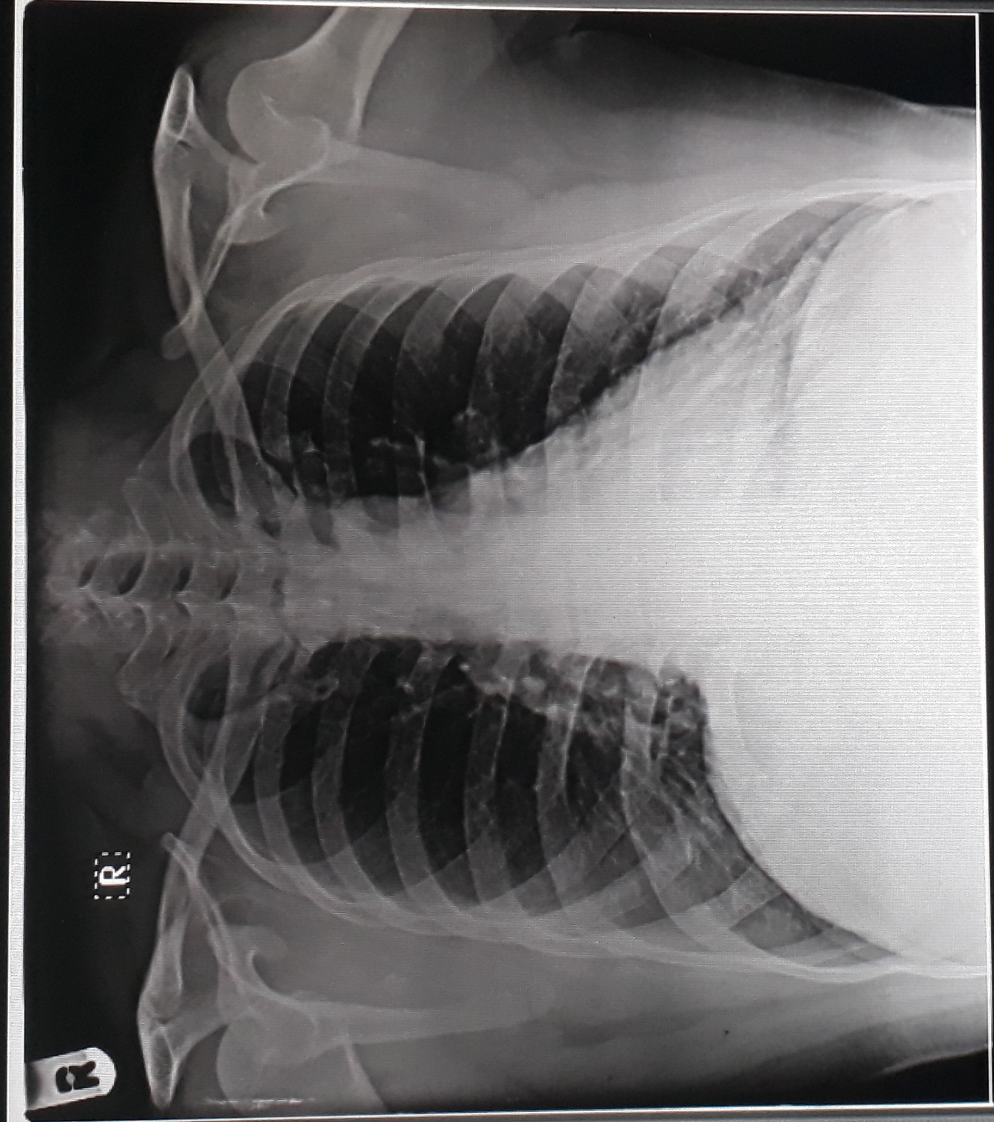
Ahmedabad, Gujarat, भारत
3H96+6PR, Chandlodiya Rd, Swatantra Senani Nagar,
Nava Vadaj, Ahmedabad, Gujarat 380013, भारत
Lat 23.068097°
Long 72.561761°
08/07/22 11:03 AM

Dr. Vidhi B. Modh
MBBS
Reg. No. G-74540

Vidhi Diagnostics
L-86, Swatantra Senani Nagar,
Opp. Akhbar Nagar, Farmigals,
Nr. Akhbar Nagar Circle,
New Wada, Ahmedabad-13.

ROBIN SAXENA 36 YRS

08072204



1 (1)



ALL



DELL