

Patient Name: *Saxona*

Age: *31* Yrs

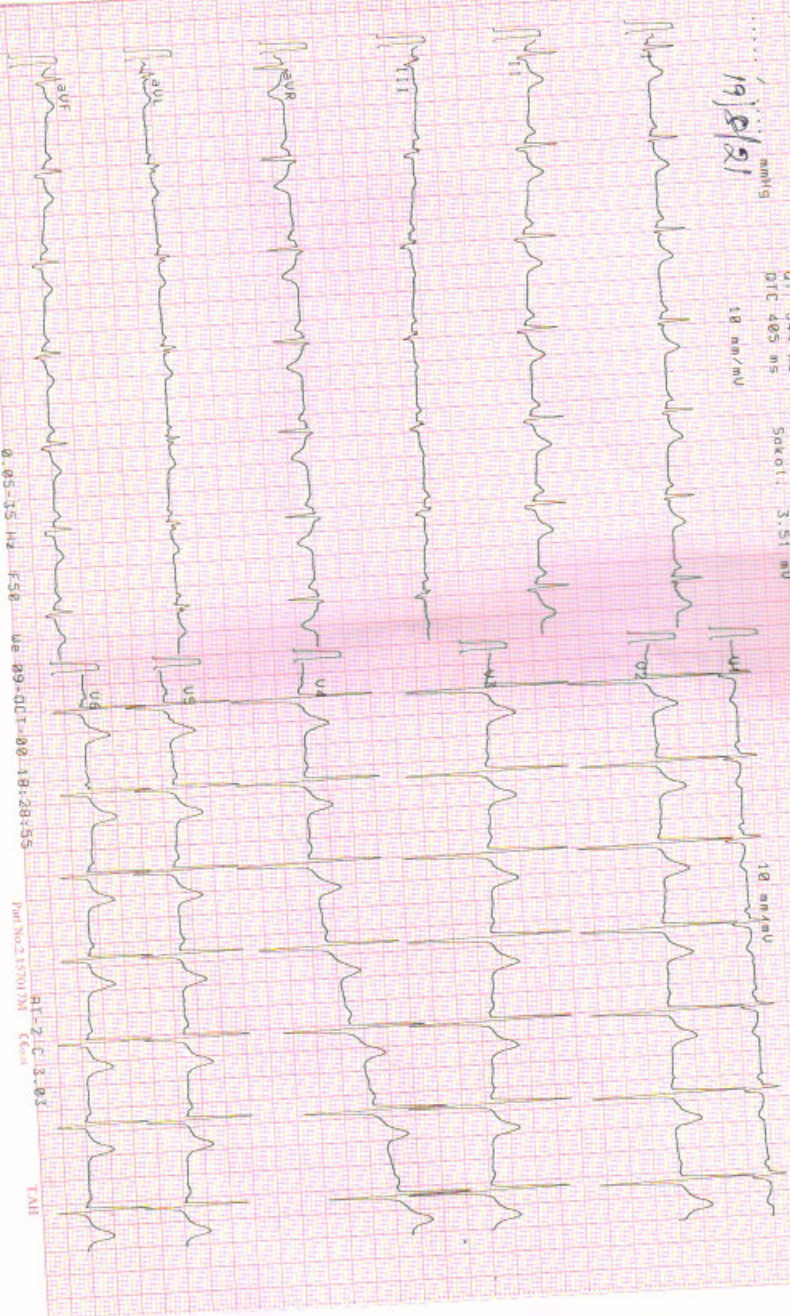
Sex: *F*

Date: *19/01/21*

HR	82/min	HRIS	44°
Interval	128 ms	P	23°
PR	118 ms	QRS	30°
QR	90 ms	T	30°
QT	344 ms	P (1)	0.16 mV
QTc	403 ms	S (U1)	-0.39 mV
		R (U5)	1.53 mV
		Saxct.	3.51 mV

SINUS RHYTHM  
NORMAL ECG  
5.70

UNCONFIRMED REPORT



25 mm/s

50 mm

0.05-35 Hz F50 We 09-01-20 18:28:55

RI-2-C-3-03

TAM