

NAME : MR. JIFLIN DAS

AGE:36/M

DATE: 09/03/2024

CHEST X-RAY REPORT

CHEST X-RAY PA VIEW : Trachea central  
 No cardiomegaly  
 Normal vascularity  
 No parenchymal lesion.  
 Costophrenic and cardiophrenic angles clear

➤ **IMPRESSION** : Normal Chest Xray

ELECTRO CARDIOGRAM : NSR: 65/minute  
 No evidence of ischaemia

➤ **IMPRESSION** : Normal Ecg.

Dr. SERIN LOPEZ. MBBS  
 Reg. No. 77656  
 MEDICAL OFFICER  
 DDRC AGILUS PATHLABS LTD.  
 Aster Square, Medical College. P.O, TVM



Company name: MEDIWHEEL

DR SERIN LOPEZ MBBS

Reg No 77656

DDRC AGILUS PATHLABS LTD

V1

V2

V3

V4

ID: 2

Diagnosis Information:

Female  
36 Y ears  
cm

mmHg  
kg

*No TST/ST/ST*

HR	65	bpm
P	108	ms
PR	149	ms
QRS	94	ms
QT/QTc	380/396	ms
P/QRST	63/56/33	°
RV5/SVI	1.077/0.765	mV

Report Confirmed by:



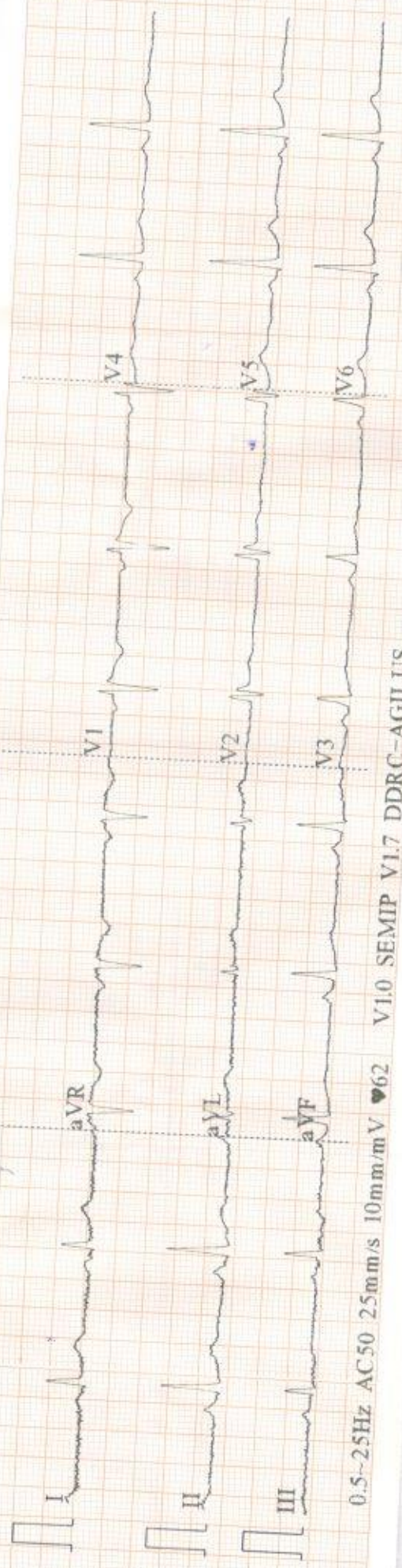
*[Signature]*  
**DR. SERIN LOPEZ, MBBS**  
 Reg. No. 77656  
 MEDICAL OFFICER

DDRC AGILUS PATHLABS LTD.  
 Aster Square, Medical College  
 Standard

V6

Standard	L1	L II	L III	L III Inspiration
----------	----	------	-------	-------------------

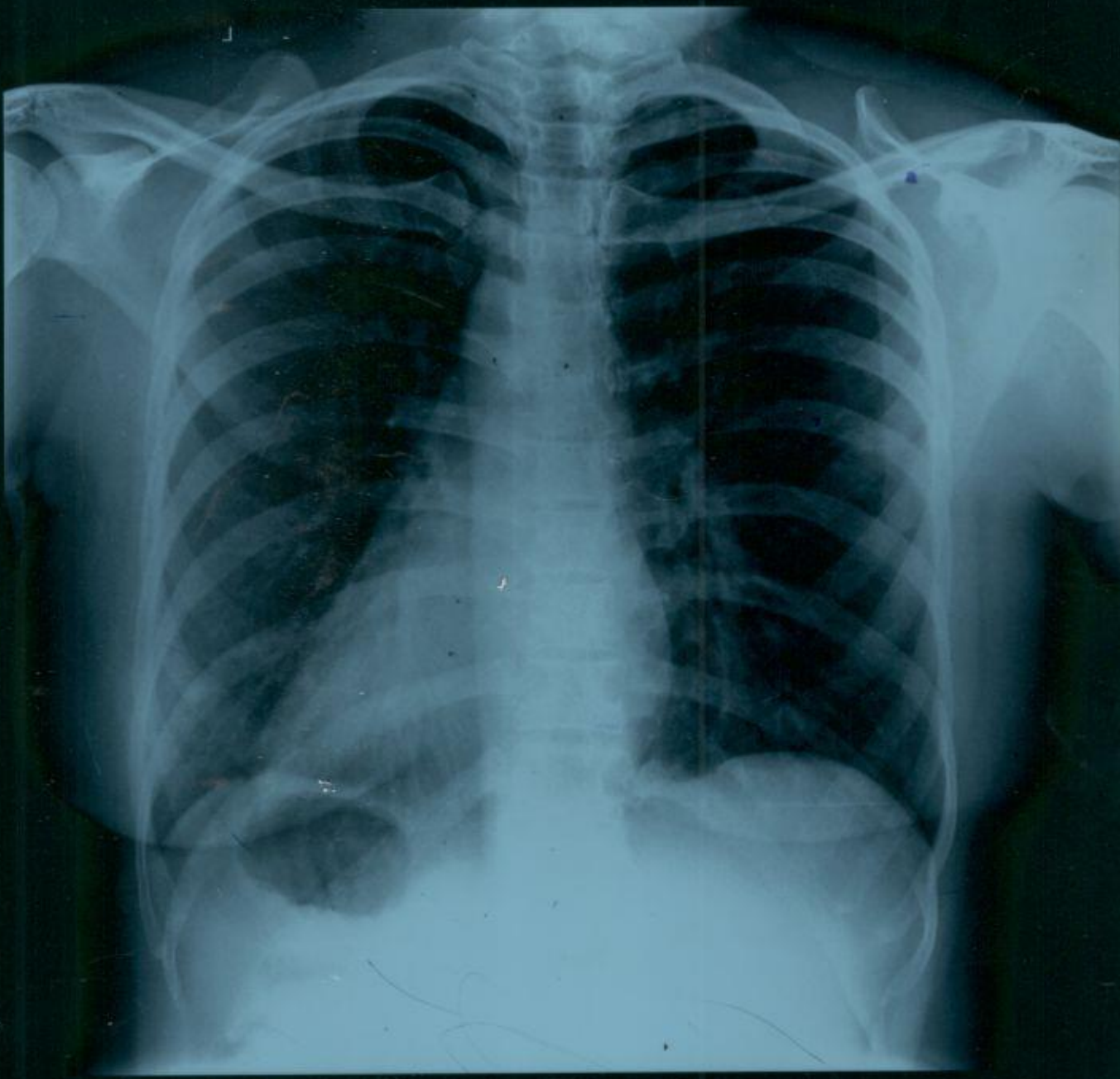
ID: 2 09-03-2024 09:37:42 AM



0.5-25Hz AC50 25mm/s 10mm/mV ♡62 V1.0 SEMIP V1.7 DDRC-AGILUS

Arrow CE





MRS JIFLIN DAS 36Y F 31812024 CHEST- PA XC003278 v  
DRCR AGILUS

If the examinee is suffering from an acute life threatening situation, you may be obliged to disclose the result of the medical examination to the examinee.

1. Name of the examinee	:	Mr./Mrs./Ms.	<u>Jifin Das</u>
2. Mark of Identification	:	(Mole/Scar/any other (specify location)):	
3. Age/Date of Birth	:	<u>36/P</u>	Gender: F/M
4. Photo ID Checked	:	(Passport/Election Card/PAN Card/Driving Licence/Company ID)	

### PHYSICAL DETAILS:

a. Height <u>151</u> (cms)	b. Weight <u>51</u> (Kgs)	c. Girth of Abdomen <u>72</u> (cms)
d. Pulse Rate <u>87</u> (b/min)	e. Blood Pressure:	Systolic * Diastolic
	1 <sup>st</sup> Reading	<u>120</u>
	2 <sup>nd</sup> Reading	<u>80</u>

### FAMILY HISTORY:

Relation	Age if Living	Health Status	If deceased, age at the time and cause
Father			
Mother			
Brother(s)			
Sister(s)			

### HABITS & ADDICTIONS: Does the examinee consume any of the following?

Tobacco in any form	Sedative	Alcohol
<u>-</u>	<u>-</u>	<u>-</u>

### PERSONAL HISTORY

- |   |   |
|---|---|
| a. Are you presently in good health and entirely free from any mental or Physical impairment or deformity. If No, please attach details. <u>Y/N</u> | c. During the last 5 years have you been medically examined, received any advice or treatment or admitted to any hospital? <u>Y/N</u> |
| b. Have you undergone/been advised any surgical procedure? <u>Y/N</u>   | d. Have you lost or gained weight in past 12 months? <u>Y/N</u>   |

### Have you ever suffered from any of the following?

- |  |   |
|--|---|
| • Psychological Disorders or any kind of disorders of the Nervous System? <u>Y/N</u> | • Any disorder of Gastrointestinal System? <u>Y/N</u>                               |
| • Any disorders of Respiratory system? <u>Y/N</u>                                    | • Unexplained recurrent or persistent fever, and/or weight loss <u>Y/N</u>          |
| • Any Cardiac or Circulatory Disorders? <u>Y/N</u>                                   | • Have you been tested for HIV/HBsAg / HCV before? If yes attach reports <u>Y/N</u> |
| • Enlarged glands or any form of Cancer/Tumour? <u>Y/N</u>                           | • Are you presently taking medication of any kind? <u>Y/N</u>                       |
| • Any Musculoskeletal disorder? <u>Y/N</u>   |   |



• Any disorders of Urinary System?

~~Y/N~~

• Any disorder of the Eyes, Ears, Nose, Throat or Mouth & Skin

~~Y/N~~

**FOR FEMALE CANDIDATES ONLY**

a. Is there any history of diseases of breast/genital organs?

Y/N

d. Do you have any history of miscarriage/abortion or MTP

Y/N

b. Is there any history of abnormal PAP Smear/Mammogram/USG of Pelvis or any other tests? (If yes attach reports)

Y/N

e. For Parous Women, were there any complication during pregnancy such as gestational diabetes, hypertension etc

Y/N

c. Do you suspect any disease of Uterus, Cervix or Ovaries?

Y/N

f. Are you now pregnant? If yes, how many months?

Y/N

**CONFIDENTIAL COMMENTS FROM MEDICAL EXAMINER**

- Was the examinee co-operative? ~~Y/N~~
- Is there anything about the examinee's health, lifestyle that might affect him/her in the near future with regard to his/her job? ~~Y/N~~
- Are there any points on which you suggest further information be obtained? ~~Y/N~~
- Based on your clinical impression, please provide your suggestions and recommendations below; ~~Y/N~~

*Gyneec Consultant - Bhand, et.*

➤ Do you think he/she is **MEDICALLY FIT** or **UNFIT** for employment.

**MEDICAL EXAMINER'S DECLARATION**

I hereby confirm that I have examined the above individual after verification of his/her identity and the findings stated above are true and correct to the best of my knowledge.

Name & Signature of the Medical Examiner :

Seal of Medical Examiner :

**Dr. SERIN LOPEZ. MBBS**  
Reg. No. 77656  
MEDICAL OFFICER  
DDRC AGILUS PATHLABS LTD.  
Aster Square, Medical College. P.O, TVM

Name & Seal of DDRC SRL Branch :

Date & Time :

*09/03/2024*



**DDRC agilus Pathlabs Limited.**

Corp. Office : Express House, Second Floor, Opp. Pothys Silks, Banerjee Road, Kaloor -682017

Contact :- 93334 93334, Web :- www.ddrcagilus.com Email :- info.ddrc@agilus.in

**RADIOLOGY DIVISION**

Acc no: <b>4182XC003278</b>	Name: <b>Mrs. Jiflin Das</b>	Age: <b>36 y</b>	Sex: <b>Female</b>	Date: <b>09.03.24</b>
-----------------------------	------------------------------	------------------	--------------------	-----------------------

**US SCAN WHOLE ABDOMEN (TAS + TVS)**

**LIVER** is normal in size (14.5 cm). Margins are regular. Hepatic parenchyma shows normal echogenicity. No focal lesions seen. No dilatation of intrahepatic biliary radicles. CBD is not dilated. Portal vein is normal in caliber (11.9 mm).

**GALL BLADDER** is distended and lumen clear. No calculi / polyp noted. Wall thickness is normal. No pericholecystic fluid seen.

**SPLEEN** is normal in size (8.8 cm) and parenchymal echotexture. No focal lesion seen.

**PANCREAS** Head and body visualized, appears normal in size and parenchymal echotexture. Pancreatic duct is not dilated.

**RIGHT KIDNEY** is normal in size (9.2 x 3.6 cm) and shows normal parenchymal echotexture. Cortico medullary differentiation is maintained. Parenchymal thickness is normal. No echogenic focus with shadowing suggestive of renal calculi seen. No dilatation of pelvicalyceal system seen. Ureter is not dilated. Perinephric spaces are normal.

**LEFT KIDNEY** is normal in size (9.8 x 3.8 cm) and shows normal parenchymal echotexture. Cortico medullary differentiation is maintained. Parenchymal thickness is normal. No echogenic focus with shadowing suggestive of renal calculi seen. No dilatation of pelvicalyceal system seen. Ureter is not dilated. Perinephric spaces are normal.

**PARAAORTIC AREA** No retroperitoneal lymphadenopathy or mass seen.

**URINARY BLADDER** is distended, normal in wall thickness, lumen clear.


**UTERUS** measures 8.5 x 3.4 x 4.9 cm, myometrial echopattern normal. No focal lesions seen. Endometrial thickness is 12.5 mm.

Both ovaries are normal. Right ovary measures 3 x 2 cm. Left ovary measures 3.8 x 1.5 cm and shows corpus luteum measuring 2.2 x 1.2 cm. No adnexal mass seen. No fluid in pouch of Douglas. No ascites or pleural effusion.

**Gaseous distension of bowel loops noted. No obvious bowel wall thickening seen sonologically.**

**CONCLUSION:-**

- **No significant abnormality detected in present study.**

  
**Dr. Nisha Unni MD, DNB (RD)**  
Consultant radiologist.

*Thanks for referral. Your feedback will be appreciated.*

*(Please bring relevant investigation reports during all visits)*

*Because of technical and technological limitations complete accuracy cannot be assured on imaging.*

*Suggested correlation with clinical findings and other relevant investigations consultations, and if required repeat imaging recommended in the event of controversies.*

**(For appointments / any clarification of report please contact 9496005190 between 9 am – 5.30 pm).**

**DDRC** *agilus* Pathlabs Limited.

Corp. Office : Express House, Second Floor, Opp. Pothys Silks, Banerjee Road, Kaloor -682017

Contact :- 93334 93334, Web :- www.ddrcagilus.com Email :- info.ddrc@agilus.in







**ECHO REPORT**

**RADIOLOGY DIVISION**

SRD No :4182XC003278	Name:JIFLIN DAS	Age:36Y	Sex:F	Date:09/03/24
----------------------	-----------------	---------	-------	---------------

**Left Ventricle:-**

	Diastole	Systole
IVS	1.04cm	1.09cm
LV	4.11cm	2.34cm
LVPW	1.09cm	1.15cm

EF -74%      FS- 43%

AO	LA
3.13cm	3.59cm

PV            -    0.81m/s  
AV            -    1.73m/s  
MVE          -    0.99m/s  
MVA          -    0.73m/s  
E/A           -    1.37

**IMPRESSION:-**

- Normal chambers dimension
- No RWMA
- Good LV systolic function
- Good RV function
- No diastolic dysfunction
- No AS,AR,MR,MS,TR,PAH
- IAS/IVS intact.No clots/effusion/coarctation

**Dr. SAJITH. K**  
MD,DNB  
CONSULTANT CARDIOLOGIST  
Reg.No: 19436



*[Signature]*  
Consultant Cardiologist





**PATIENT NAME : JIFLIN DAS**
**REF. DOCTOR : SELF**
**CODE/NAME & ADDRESS : CA00010147 -**

 MEDIWHEEL ARCOFEMI HEALTHCARE LIMITED  
 F701A, LADO SARAI, NEW DELHI, SOUTH DELHI,  
 DELHI,  
 SOUTH DELHI 110030  
 8800465156

**ACCESSION NO : 4182XC003278**
**PATIENT ID : JIFLF20088727**
**CLIENT PATIENT ID:**
**ABHA NO :**
**AGE/SEX : 36 Years Female**
**DRAWN :**
**RECEIVED : 09/03/2024 08:51:36**
**REPORTED : 11/03/2024 08:23:06**
**Test Report Status Final**
**Results**
**Biological Reference Interval Units**
**MEDIWHEEL HEALTH CHECKUP BELOW 40(F)2DECHO**
**OPHTHAL**

OPTHAL

RESULT GIVEN

**PHYSICAL EXAMINATION**

PHYSICAL EXAMINATION

RESULT GIVEN


  
**DR NISHA UNNI, MBBS,MD**  
**(RD),DNB (Reg.No:50162)**  
**Consultant Radiologist**


View Details



View Report

**PERFORMED AT :**

 DDRC AGILUS PATHLABS LIMITED  
 ASTER SQUARE BUILDING, ULLOOR,  
 MEDICAL COLLEGE P.O  
 TRIVANDRUM, 695011  
 KERALA, INDIA  
 Tel : 93334 93334, Fax : CIN - U85190MH2006PTC161480  
 Email : customercare.ddrc@agilus.in

**Patient Ref. No. 66600008146089**

<b>PATIENT NAME : JIFLIN DAS</b>		<b>REF. DOCTOR : SELF</b>	
<b>CODE/NAME &amp; ADDRESS :</b> CA00010147 - MEDIWHEEL ARCOFEMI HEALTHCARE LIMITED F701A, LADO SARAI, NEW DELHI,SOUTH DELHI, DELHI, SOUTH DELHI 110030 8800465156	<b>ACCESSION NO :</b> <b>4182XC003278</b>	<b>AGE/SEX :</b> 36 Years Female	
	<b>PATIENT ID :</b> JIFLF20088727	<b>DRAWN :</b>	
	<b>CLIENT PATIENT ID:</b>	<b>RECEIVED :</b> 09/03/2024 08:51:36	
	<b>ABHA NO :</b>	<b>REPORTED :</b> 11/03/2024 08:23:06	

Test Report Status	Final	Results	Units
--------------------	-------	---------	-------

**MEDIWHEEL HEALTH CHECKUP BELOW 40(F)2DECHO**

**ECG WITH REPORT**

**REPORT**

REPORT GIVEN

**USG ABDOMEN AND PELVIS**

**REPORT**

REPORT GIVEN

**CHEST X-RAY WITH REPORT**

**REPORT**

REPORT GIVEN

**2D - ECHO WITH COLOR DOPPLER**

**REPORT**

REPORT GIVEN

**HAEMATOLOGY**

**MEDIWHEEL HEALTH CHECKUP BELOW 40(F)2DECHO**

**GLYCOSYLATED HEMOGLOBIN(HBA1C), EDTA WHOLE BLOOD**

HBA1C	5.1	Non-diabetic Adult < 5.7 Pre-diabetes 5.7 - 6.4 Diabetes diagnosis: > or = 6.5 Therapeutic goals: < 7.0 Action suggested : > 8.0 (ADA Guideline 2021)	%
MEAN PLASMA GLUCOSE	99.7	< 116.0	mg/dL

**DR NISHA UNNI, MBBS,MD**  
(RD),DNB (Reg.No:50162)  
Consultant Radiologist

**DR.HARI SHANKAR, MBBS MD**  
(Reg No - TCMC:62092)  
HEAD - Biochemistry & Immunology

**DR.VAISHALI RAJAN, MBBS DCP**  
(Pathology)  
(Reg No - TCC 27150)  
HOD - HAEMATOTOLOGY



View Details



View Report

**PERFORMED AT :**

DDRC AGILUS PATHLABS LIMITED  
ASTER SQUARE BUILDING, ULLOOR,  
MEDICAL COLLEGE P.O  
TRIVANDRUM, 695011  
KERALA, INDIA  
Tel : 93334 93334, Fax : CIN - U85190MH2006PTC161480  
Email : customercare.ddrc@agilus.in





**PATIENT NAME : JIFLIN DAS**

**REF. DOCTOR : SELF**

**CODE/NAME & ADDRESS :** CA00010147 -

MEDIWHEEL ARCOFEMI HEALTHCARE LIMITED  
F701A, LADO SARAI, NEW DELHI, SOUTH DELHI,  
DELHI,  
SOUTH DELHI 110030  
8800465156

**ACCESSION NO :** 4182XC003278

**PATIENT ID :** JIFLF20088727

**CLIENT PATIENT ID:**

**ABHA NO :**

**AGE/SEX :** 36 Years Female

**DRAWN :**

**RECEIVED :** 09/03/2024 08:51:36

**REPORTED :** 11/03/2024 08:23:06

Test Report Status	Final	Results	Units
--------------------	-------	---------	-------

**BLOOD COUNTS, EDTA WHOLE BLOOD**

HEMOGLOBIN	12.3	12.0 - 15.0	g/dL
RED BLOOD CELL COUNT	4.32	3.80 - 4.80	mil/ $\mu$ L
WHITE BLOOD CELL COUNT	7.51	4.0 - 10.0	thou/ $\mu$ L
PLATELET COUNT	346	150 - 410	thou/ $\mu$ L

**RBC AND PLATELET INDICES**

HEMATOCRIT	38.7	36.0 - 46.0	%
MEAN CORPUSCULAR VOL	89.6	83.0 - 101	fL
MEAN CORPUSCULAR HGB.	28.5	27.0 - 32.0	pg
MEAN CORPUSCULAR HEMOGLOBIN CONCENTRATION	31.8	31.50 - 34.50	g/dL
RED CELL DISTRIBUTION WIDTH	13.7	11.60 - 14.0	%
MENTZER INDEX	20.7		
MEAN PLATELET VOLUME	9.6	6.80 - 10.90	fL

**WBC DIFFERENTIAL COUNT**

SEGMENTED NEUTROPHILS	55	40.0 - 80.0	%
LYMPHOCYTES	36	20.0 - 40.0	%
MONOCYTES	5	2.0 - 10.0	%
EOSINOPHILS	4	1.0 - 6.0	%
BASOPHILS	0	0.0 - 1.0	%
ABSOLUTE NEUTROPHIL COUNT	4.14	2.0 - 7.0	thou/ $\mu$ L
ABSOLUTE LYMPHOCYTE COUNT	2.73	1.0 - 3.0	thou/ $\mu$ L
ABSOLUTE MONOCYTE COUNT	0.36	0.20 - 1.0	thou/ $\mu$ L
ABSOLUTE EOSINOPHIL COUNT	0.30	0.02 - 0.50	thou/ $\mu$ L
ABSOLUTE BASOPHIL COUNT	0.00		thou/ $\mu$ L
NEUTROPHIL LYMPHOCYTE RATIO (NLR)	1.5		

**DR. HARI SHANKAR, MBBS MD**  
(Reg No - TCMC:62092)  
**HEAD - Biochemistry & Immunology**

**DR. VAISHALI RAJAN, MBBS DCP**  
(Pathology)  
(Reg No - TCC 27150)  
**HOD - HAEMATOLOGY**



View Details



View Report

**PERFORMED AT :**

DDRC AGILUS PATHLABS LIMITED  
ASTER SQUARE BUILDING, ULLOOR,  
MEDICAL COLLEGE P.O  
TRIVANDRUM, 695011  
KERALA, INDIA  
Tel : 93334 93334, Fax : CIN - U85190MH2006PTC161480  
Email : customercare.ddrc@agilus.in



**Patient Ref. No. 66600008146089**

**PATIENT NAME : JIFLIN DAS****REF. DOCTOR : SELF****CODE/NAME & ADDRESS :** CA00010147 -
 MEDIWHEEL ARCOFEMI HEALTHCARE LIMITED  
 F701A, LADO SARAI, NEW DELHI,SOUTH DELHI,  
 DELHI,  
 SOUTH DELHI 110030  
 8800465156
**ACCESSION NO :** 4182XC003278**PATIENT ID :** JIFLF20088727**CLIENT PATIENT ID:****ABHA NO :****AGE/SEX :** 36 Years Female**DRAWN :****RECEIVED :** 09/03/2024 08:51:36**REPORTED :** 11/03/2024 08:23:06

Test Report Status	Final	Results	Units
--------------------	-------	---------	-------

**ERYTHROCYTE SEDIMENTATION RATE (ESR),EDTA BLOOD**

SEDIMENTATION RATE (ESR)	18	0 - 20	mm at 1 hr
--------------------------	----	--------	------------

**SUGAR URINE - POST PRANDIAL**

SUGAR URINE - POST PRANDIAL	NOT DETECTED	NOT DETECTED
-----------------------------	--------------	--------------

**SUGAR URINE - FASTING**

SUGAR URINE - FASTING	NOT DETECTED	NOT DETECTED
-----------------------	--------------	--------------

**IMMUNOHAEMATOLOGY****MEDIWHEEL HEALTH CHECKUP BELOW 40(F)2DECHO****ABO GROUP & RH TYPE, EDTA WHOLE BLOOD**

ABO GROUP	TYPE O
RH TYPE	POSITIVE

METHOD : COLUMN AGGLUTINATION TECHNOLOGY

&lt;b&gt;Interpretation(s)&lt;/b&gt;

ABO GROUP & RH TYPE, EDTA WHOLE BLOOD-Blood group is identified by antigens and antibodies present in the blood. Antigens are protein molecules found on the surface of red blood cells. Antibodies are found in plasma. To determine blood group, red cells are mixed with different antibody solutions to give A,B,O or AB.

Disclaimer: "Please note, as the results of previous ABO and Rh group (Blood Group) for pregnant women are not available, please check with the patient records for availability of the same."

The test is performed by both forward as well as reverse grouping methods.



**DR.HARI SHANKAR, MBBS MD**  
 (Reg No - TCMC:62092)  
 HEAD - Biochemistry &  
 Immunology



**DR.VAISHALI RAJAN, MBBS DCP**  
 (Pathology)  
 (Reg No - TCC 27150)  
 HOD - HAEMATOLOGY

Page 4 Of 9



View Details



View Report

**PERFORMED AT :**

DDRC AGILUS PATHLABS LIMITED  
 ASTER SQUARE BUILDING, ULLOOR,  
 MEDICAL COLLEGE P.O  
 TRIVANDRUM, 695011  
 KERALA, INDIA  
 Tel : 93334 93334, Fax : CIN - U85190MH2006PTC161480  
 Email : customercare.ddrc@agilus.in



Patient Ref. No. 666000008146089



**PATIENT NAME : JIFLIN DAS**

**REF. DOCTOR : SELF**

**CODE/NAME & ADDRESS :** CA00010147 -  
 MEDIWHEEL ARCOFEMI HEALTHCARE LIMITED  
 F701A, LADO SARAI, NEW DELHI,SOUTH DELHI,  
 DELHI,  
 SOUTH DELHI 110030  
 8800465156

**ACCESSION NO :** **4182XC003278**  
**PATIENT ID :** JIFLF20088727  
**CLIENT PATIENT ID:**  
**ABHA NO :**

**AGE/SEX :** 36 Years Female  
**DRAWN :**  
**RECEIVED :** 09/03/2024 08:51:36  
**REPORTED :** 11/03/2024 08:23:06

Test Report Status	Final	Results	Units
--------------------	-------	---------	-------

**BIO CHEMISTRY**

**MEDIWHEEL HEALTH CHECKUP BELOW 40(F)2DECHO**

**BLOOD UREA NITROGEN (BUN), SERUM**

BLOOD UREA NITROGEN 6 Adult(<60 yrs) : 6 to 20 mg/dL

**BUN/CREAT RATIO**

BUN/CREAT RATIO 9.5

**CREATININE, SERUM**

CREATININE 0.63 18 - 60 yrs : 0.6 - 1.1 mg/dL

**GLUCOSE, POST-PRANDIAL, PLASMA**

GLUCOSE, POST-PRANDIAL, PLASMA 92 Diabetes Mellitus : > or = 200. mg/dL  
 Impaired Glucose tolerance/  
 Prediabetes : 140 - 199.  
 Hypoglycemia : < 55.

**GLUCOSE FASTING,FLUORIDE PLASMA**

FBS (FASTING BLOOD SUGAR) 91 Diabetes Mellitus : > or = 126. mg/dL  
 Impaired fasting Glucose/  
 Prediabetes : 101 - 125.  
 Hypoglycemia : < 55.

**LIVER FUNCTION TEST WITH GGT**

BILIRUBIN, TOTAL 0.32 General Range : < 1.1 mg/dL  
 BILIRUBIN, DIRECT 0.14 General Range : < 0.3 mg/dL

**DR.HARI SHANKAR, MBBS MD**  
 (Reg No - TCMC:62092)  
 HEAD - Biochemistry &  
 Immunology



View Details



View Report

**PERFORMED AT :**

DDRC AGILUS PATHLABS LIMITED  
 ASTER SQUARE BUILDING, ULLOOR,  
 MEDICAL COLLEGE P.O  
 TRIVANDRUM, 695011  
 KERALA, INDIA  
 Tel : 93334 93334, Fax : CIN - U85190MH2006PTC161480  
 Email : customercare.ddrc@agilus.in



**Patient Ref. No. 66600008146089**

**PATIENT NAME : JIFLIN DAS**

**REF. DOCTOR : SELF**

**CODE/NAME & ADDRESS :** CA00010147 -  
 MEDIWHEEL ARCOFEMI HEALTHCARE LIMITED  
 F701A, LADO SARAI, NEW DELHI,SOUTH DELHI,  
 DELHI,  
 SOUTH DELHI 110030  
 8800465156

**ACCESSION NO :** **4182XC003278**  
**PATIENT ID :** JIFLF20088727  
**CLIENT PATIENT ID:**  
**ABHA NO :**

**AGE/SEX :** 36 Years Female  
**DRAWN :**  
**RECEIVED :** 09/03/2024 08:51:36  
**REPORTED :** 11/03/2024 08:23:06

Test Report Status	Final	Results	Units
--------------------	-------	---------	-------

BILIRUBIN, INDIRECT	0.18	General Range : <0.85	mg/dL
TOTAL PROTEIN	7.1	Ambulatory : 6.4 - 8.3 Recumbant : 6 - 7.8	g/dL
ALBUMIN	4.5	20-60yrs : 3.5 - 5.2	g/dL
GLOBULIN	2.6	General Range : 2 - 3.5 Premature Neonates : 0.29 - 1.04	g/dL
ALBUMIN/GLOBULIN RATIO	1.7	General Range : 1.1 - 2.5	RATIO
ASPARTATE AMINOTRANSFERASE (AST/SGOT)	17	Adults : < 33	U/L
ALANINE AMINOTRANSFERASE (ALT/SGPT)	36	Adults : < 34	U/L
ALKALINE PHOSPHATASE	69	Adult (<60yrs) : 35 - 105	U/L
GAMMA GLUTAMYL TRANSFERASE (GGT)	<b>68 High</b>	Adult (female) : < 40	U/L

**TOTAL PROTEIN, SERUM**

TOTAL PROTEIN	7.1	Ambulatory : 6.4 - 8.3 Recumbant : 6 - 7.8	g/dL
---------------	-----	---	------

**URIC ACID, SERUM**

URIC ACID	3.5	Adults : 2.4-5.7	mg/dL
-----------	-----	------------------	-------

**BIOCHEMISTRY - LIPID**

**MEDIWHEEL HEALTH CHECKUP BELOW 40(F)2DECHO**

**LIPID PROFILE, SERUM**

CHOLESTEROL	186	Desirable : < 200 Borderline : 200-239 High : >or= 240	mg/dL
TRIGLYCERIDES	53	Normal : < 150 High : 150-199	mg/dL

**DR.HARI SHANKAR, MBBS MD**  
 (Reg No - TCMC:62092)  
**HEAD - Biochemistry & Immunology**



View Details



View Report

**PERFORMED AT :**

DDRC AGILUS PATHLABS LIMITED  
 ASTER SQUARE BUILDING, ULLOOR,  
 MEDICAL COLLEGE P.O  
 TRIVANDRUM, 695011  
 KERALA, INDIA  
 Tel : 93334 93334, Fax : CIN - U85190MH2006PTC161480  
 Email : customercare.ddrc@agilus.in



**Patient Ref. No. 666000008146089**



<b>PATIENT NAME : JIFLIN DAS</b>		<b>REF. DOCTOR : SELF</b>	
<b>CODE/NAME &amp; ADDRESS : CA00010147 -</b> MEDIWHEEL ARCOFEMI HEALTHCARE LIMITED F701A, LADO SARAI, NEW DELHI,SOUTH DELHI, DELHI, SOUTH DELHI 110030 8800465156		<b>ACCESSION NO : 4182XC003278</b>	<b>AGE/SEX : 36 Years Female</b>
		<b>PATIENT ID : JIFLF20088727</b>	<b>DRAWN :</b>
		<b>CLIENT PATIENT ID:</b>	<b>RECEIVED : 09/03/2024 08:51:36</b>
		<b>ABHA NO :</b>	<b>REPORTED : 11/03/2024 08:23:06</b>

Test Report Status	Final	Results	Units
--------------------	-------	---------	-------

HDL CHOLESTEROL	47	Hypertriglyceridemia : 200-499 Very High : > 499 General range : 40-60	mg/dL
LDL CHOLESTEROL, DIRECT	123	Optimum : < 100 Above Optimum : 100-129 Borderline High : 130-159 High : 160-189 Very High : >or= 190	mg/dL
NON HDL CHOLESTEROL	139	Desirable : < 130 Above Desirable : 130 -159 Borderline High : 160 - 189 High : 190 - 219 Very high : > / = 220	mg/dL
VERY LOW DENSITY LIPOPROTEIN CHOL/HDL RATIO	10.6 4.0	</= 30.0 Low Risk : 3.3 - 4.4 Average Risk : 4.5 - 7.0 Moderate Risk : 7.1 - 11.0 High Risk : > 11.0	mg/dL
LDL/HDL RATIO	2.6	Desirable/Low Risk - 0.5-3 Borderline/Moderate Risk- 3.1-6 High Risk- >6.0	

**SPECIALISED CHEMISTRY - HORMONE**

**MEDIWHEEL HEALTH CHECKUP BELOW 40(F)2DECHO**

**THYROID PANEL, SERUM**

T3	129.00	Non-Pregnant : 80-200 Pregnant Trimester-wise 1st : 81-190 2nd : 100-260 3rd : 100-260	ng/dL
T4	7.70	Adults : 4.5-12.1	µg/dl

**DR.HARI SHANKAR, MBBS MD**  
(Reg No - TCMC:62092)  
**HEAD - Biochemistry & Immunology**



View Details



View Report

**PERFORMED AT :**

DDRC AGILUS PATHLABS LIMITED  
ASTER SQUARE BUILDING, ULLOOR,  
MEDICAL COLLEGE P.O  
TRIVANDRUM, 695011  
KERALA, INDIA  
Tel : 93334 93334, Fax : CIN - U85190MH2006PTC161480  
Email : customercare.ddrc@agilus.in



**Patient Ref. No. 66600008146089**

**PATIENT NAME : JIFLIN DAS**

**REF. DOCTOR : SELF**

**CODE/NAME & ADDRESS :** CA00010147 -  
 MEDIWHEEL ARCOFEMI HEALTHCARE LIMITED  
 F701A, LADO SARAI, NEW DELHI, SOUTH DELHI,  
 DELHI,  
 SOUTH DELHI 110030  
 8800465156

**ACCESSION NO :** **4182XC003278**  
**PATIENT ID :** JIFLF20088727  
**CLIENT PATIENT ID:**  
**ABHA NO :**

**AGE/SEX :** 36 Years Female  
**DRAWN :**  
**RECEIVED :** 09/03/2024 08:51:36  
**REPORTED :** 11/03/2024 08:23:06

Test Report Status	Final	Results	Units
--------------------	-------	---------	-------

TSH 3RD GENERATION	1.980	Non-Pregnant : 0.4-4.2 Pregnant Trimester-wise : 1st : 0.1 - 2.5 2nd : 0.2 - 3 3rd : 0.3 - 3	µIU/mL
--------------------	-------	--	--------

**CLINICAL PATH - URINALYSIS**

**MEDIWHEEL HEALTH CHECKUP BELOW 40(F)2DECHO**

**PHYSICAL EXAMINATION, URINE**

COLOR	PALE YELLOW
APPEARANCE	CLEAR

**CHEMICAL EXAMINATION, URINE**

PH	5.0	4.7 - 7.5
SPECIFIC GRAVITY	1.015	1.003 - 1.035
PROTEIN	NOT DETECTED	NOT DETECTED
GLUCOSE	NOT DETECTED	NOT DETECTED
KETONES	NOT DETECTED	NOT DETECTED
BLOOD	NOT DETECTED	NOT DETECTED
BILIRUBIN	NOT DETECTED	NOT DETECTED
UROBILINOGEN	NORMAL	NORMAL
NITRITE	NOT DETECTED	NOT DETECTED

**MICROSCOPIC EXAMINATION, URINE**

RED BLOOD CELLS	NOT DETECTED	NOT DETECTED	/HPF
WBC	3-5	0-5	/HPF
EPITHELIAL CELLS	5-7	0-5	/HPF

**DR. HARI SHANKAR, MBBS MD**  
 (Reg No - TCMC:62092)  
 HEAD - Biochemistry &  
 Immunology

**DR. VAISHALI RAJAN, MBBS DCP**  
 (Pathology)  
 (Reg No - TCC 27150)  
 HOD - HAEMATOLOGY



View Details



View Report

**PERFORMED AT :**

DDRC AGILUS PATHLABS LIMITED  
 ASTER SQUARE BUILDING, ULLOOR,  
 MEDICAL COLLEGE P.O  
 TRIVANDRUM, 695011  
 KERALA, INDIA  
 Tel : 93334 93334, Fax : CIN - U85190MH2006PTC161480  
 Email : customercare.ddrc@agilus.in



**Patient Ref. No. 66600008146089**

**PATIENT NAME : JIFLIN DAS**

**REF. DOCTOR : SELF**

**CODE/NAME & ADDRESS :** CA00010147 -

MEDIWHEEL ARCOFEMI HEALTHCARE LIMITED  
F701A, LADO SARAI, NEW DELHI, SOUTH DELHI,  
DELHI,  
SOUTH DELHI 110030  
8800465156

**ACCESSION NO :** 4182XC003278

**PATIENT ID :** JIFLF20088727

**CLIENT PATIENT ID:**

**ABHA NO :**

**AGE/SEX :** 36 Years Female

**DRAWN :**

**RECEIVED :** 09/03/2024 08:51:36

**REPORTED :** 11/03/2024 08:23:06

Test Report Status	<u>Final</u>	Results	Units
--------------------	--------------	---------	-------

CASTS NEGATIVE

CRYSTALS NEGATIVE

**DR.VAISHALI RAJAN, MBBS DCP**  
**(Pathology)**  
**(Reg No - TCC 27150)**  
**HOD - HAEMATOLOGY**



View Details



View Report

**PERFORMED AT :**

DDRC AGILUS PATHLABS LIMITED  
ASTER SQUARE BUILDING, ULLOOR,  
MEDICAL COLLEGE P.O  
TRIVANDRUM, 695011  
KERALA, INDIA  
Tel : 93334 93334, Fax : CIN - U85190MH2006PTC161480  
Email : customercare.ddrc@agilus.in



**Patient Ref. No. 66600008146089**