



THAREJA NURSING HOME



DIGITAL X-RAY, OPG, COMPUTERISED ECG & EEG, DIAGNOSTIC LABORATORY EQUIPED WITH COMPUTERISED AUTO ANALYZER & CBC

1, Ram Kuteer, Company Bagh Road, ALWAR - 301001 (Raj.) Ph: 0144-2700184, 2331842

PROPOSAL NO. PKG1000227 Date 12-11-2022
 Patient Name MR DEEPAK SHARMA Age 30 Yrs.
 Ref. By Dr. M. N. THAREJA Sex M

Details of packages		Patients report	Units	Normal value
HB		15.9	gm%	M-11.5-18
TRBC		5.17	million /cu mm	M-4.0-5.5, F-3.9-5.6
TWBC		7300		4000-11000
DLC	Polymorphs	60	%	42-75
	Lymphocytes	35	%	20-50
	Eosinophil	05	%	1-6
ESR		02	mm 1 st Hr.	M-0-9, F-0-20
Platelets		280000	Lack / cu mm	1.5-4
PCV		43.4	%	37-54
MCV		83.9	Cubicmicrons	86-96
MCH		30.8	Picograms	26-34
MCHC		36.6	%	32-36
Blood Grouping & Rh Factor		"B" Rh +VE(Positive)		
BUN		12.0	Mg %	05-20
S.Creatinine		0.90	Mg/100ml	0.9-1.4 mg /100 ml
HBsAg		-		
HIV I & II		-	Elisa Method	
HbA1C		5.5	%	4-6%
PSA			Ng/ml	Less Then 4.0 Ng/ml

Details of packages		Patients report	Units	Normal value	
LFT	GGTP	23.0	U/L	5-60	
	SGOT	28.0	Units / ml	Upto 40	
	SGPT	30.0	Units / ml	Upto 40	
	S. Bilirubin	Total	0.8	mg%	Upto 1.2
		Direct	0.4	mg%	0-0.25
		Indirect	0.4	mg%	
	T. Protein	7.7	Gm%	6.2-8.3	
	S. Albumin	4.3	Gm%	3.2-5.3	
	Globulin	3.4	Gm%		
	Alkaline phosphate	121.0	IU/L	60 - 170	
S. Calcium	-	Gm%	8.5-10.5		
Uric Acid	4.0	Mg%	2.5-7 mg%		
Blood Sugar Fasting	70.0	Mg%	60-110 mg %		
Blood Sugar PP		Mg%	Upto 160		
Lipid Profile	S. Cholesterol	247.0	mg%	120-220	
	S. Triglycerides	130.0	mg/ml	Upto 170	
	HDL Cholesterol	54.0	IU/L		
	LDL cholesterol	167.0	IU/L	450 at 37° C	
	VLDL	26.0	mg %	Upto 35	

Routine Urine Analysis

Physical/ Chemical	Microscopic:
Appearance	RBCs
Specific Gravity	WBCs
Ph	Epith. Cells
Albumin	Casts
Glucose	Crystals
Ketones	Bacteria
Blood	Urine for Nicotine

Signature of Technician

Dr. *Prasanth Thareja*
 M.S. (Ophthalmology) Doctor
 Fellow (CORNEA)
 L.V. Prasad Eye Institute
 CORNEA CONSULTANT

This Report is not Valid for Medical Legal Purpose



THAREJA NURSING HOME



DIGITAL X-RAY, OPG, COMPUTERISED ECG & EEG, DIAGNOSTIC LABORATORY EQUIPED WITH COMPUTERISED AUTO ANALYZER & CBC

1, Ram Kuteer, Company Bagh Road, ALWAR - 301001 (Raj.) Ph: 0144-2700184, 2331842

Name : **DEEPAK SHARMA**

age **30**

Sex : **MALE**

Ref. By : **M.N. THAREJA**

Lab No. :

Date : **November 12, 2022**

HORMONES & MARKERS

Test	Value	Units	Biological Ref. Values
T3 (Total Triiodothyronine)	0.81	ng/dL	0.60-1.81 ng/dL Adults
T4 (Total Thyroxine)	3.52	µg/dL	3.2-12.60 µg/dL : Adults
TSH (Thyroid Stimulating Hormone)	0.80	µIU/mL	Adults : 0.35-5.50 µIU/mL

Interpretation of TSH :-

Children

0 Days : 1.0~39.0 uIU/mL

5 days : 1.7~9.1 uIU/mL

1 year : 0.4~8.6 uIU/mL

2 years : 0.4~7.6 uIU/mL

3 years : 0.3~6.7 uIU/mL

4-19 years : 0.4~6.2 uIU/mL

Interpretation of TSH :-

Children

3.20 - 34.6 µIU/mL 1 - 2 Days

0.70 - 15.4 µIU/mL 3 - 4 Days

0.70 - 9.10 µIU/mL 15 Days - 5 Months

0.70 - 6.40 µIU/mL 5 Months - 20 Years

Adults

20-54 years : 0.35-5.50 uIU/mL

55-87 years : 0.5-8.9 uIU/mL

Pregnancy

1st Trimester : 0.30 - 4.50 µIU/mL

2nd Trimester : 0.50 - 4.60 µIU/mL

3rd Trimester : 0.80 - 5.20 µIU/mL

Pregnancy

0.30 - 4.50 µIU/mL 1st Trimester

0.50 - 4.60 µIU/mL 2nd Trimester

0.80 - 5.20 µIU/mL 3rd Trimester

Method : **Fluorescence Immunoassay Technology**

Sample Type : **Fresh Blood Serum**

Remarks :


Primary malfunction of the Thyroid gland may result in excessive (hyper) or Low (hypo) release of T3 or T4. In addition, as TSH directly affect thyroid function, malfunction of the pituitary or the hypothalamus influences the thyroid gland activity.

Disease in any portion of the thyroid-pituitary-hypothalamus system may influence the level of T3 and T4 in the blood, in Primary Hypothyroidism,

TSH levels are significantly elevated, while in secondary and tertiary hypothyroidism, TSH levels may be low. In addition, in Euthyroid sick syndrome, multiple alterations in serum thyroid function test findings have been recognized.


Signature of Technician

This Report is not Valid for Medical Legal Purpose


Dr. Shriwareja
M. Signature of Doctor
Fellow (CORNEA)
L.V. Prasad Eye Institute
CORNEA CONSULTANT



THAREJA NURSING HOME



DIGITAL X-RAY, OPG, COMPUTERISED ECG & EEG, DIAGNOSTIC
LABORATORY EQUIPED WITH COMPUTERISED AUTO ANALYZER & CBC

1, Ram Kuteer, Company Bagh Road, ALWAR - 301001 (Raj.) Ph: 0144-2700184, 2331842

PROPOSAL NO.

Patient Name DEEPAK SHARMA

Ref. By Dr. M. N. THAREJA

Date 12/11/2022

Age 30 Yrs.

Sex F

PART - X-RAYED : X-RAY CHEST PA VIEW

REPORT : X-RAY CHEST P.A. VIEW

:- Chest is bilaterally symmetrical.

:- C.P. Angles are clear.

CONCLUSSION: NORMAL STUDY

Vijay
Signature of Technician

Shivani
Signature of Doctor
Dr. Shiva
M.S. (CORNEA)
Fellow (CORNEA)
L.V. Prasad Eye Institute
CORNEA CONSULTANT

This Report is not Valid for Medical Legal Purpose

Patient Name: Deepak Mondal

67/min

P axis: 0°

SINUS RHYTHM
OTHERWISE NORMAL ECG

UNCONFIRMED REPORT

Age: 30 M / F
cm / kg
mmHg

Intervals:
RR 900 ms
P 110 ms
PR 176 ms
QRS 82 ms
QT 322 ms
QTc 343 ms

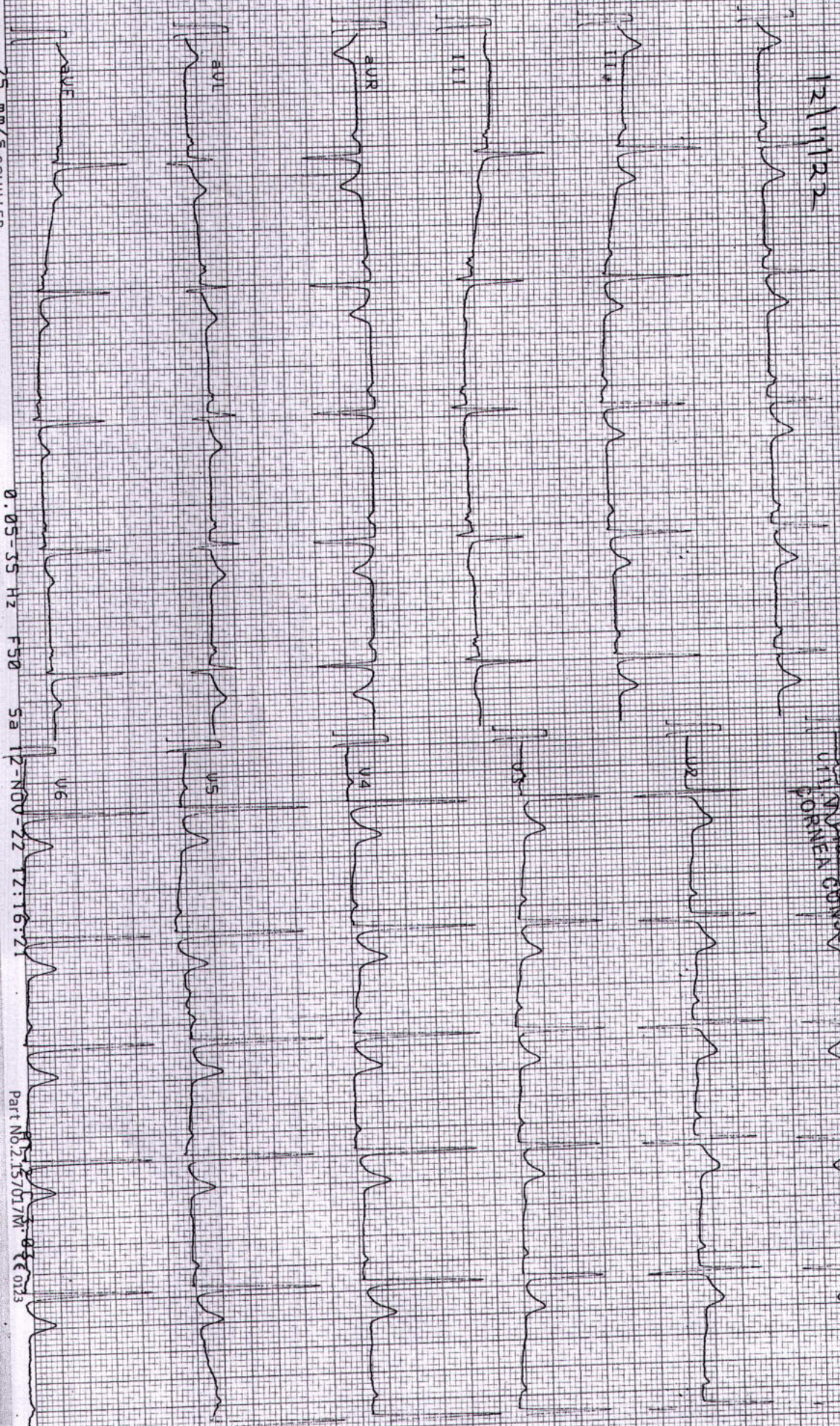
P (-1) 0.28 mV
S (V1) -0.98 mV
R (V5) 2.51 mV
50kOhm 3.63 mV

10 mm/mV

Dr. Sivaraman Tharola
M.S. (OPHTHALM)
Fellow (CORNEA)
Uttara Pradesh Eye Institute
CORNEA CONSULTANT

[Signature]

12/11/22

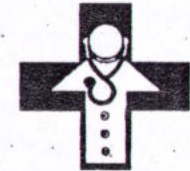

SBA

Part No: 157017M 03 013



THAREJA CLINIC



1, Ram Kuteer Company Bagh Road, ALWAR (Raj.) ☎ 2700184, 2331842 (H)

POLY CLINIC EQUIPPED WITH COMPUTERISED AUTOANALYSER, CBC
SONOGRAPHY, X-RAY, OPG, COMPUTERISED ECG, EEG &
DIAGNOSTIC LABORATORY, COMPUTERISED LUNG FUNCTION TEST

DEADDICATION CENTRE

Dr. M.N. Thareja

M.B.B.S., F.C.G.P.
F.R.S.T.M. & H (London)

- ❖ Vice Chairperson of Sex Education & Parenthood International.
- ❖ Vice President of National Sexology Society of India
- ❖ Member of American Association of Sex Educator USA
- ❖ Executive Member of Indian Andro-Pause Society
- ❖ Life Member of Association for Prevention & Control of Rabies in India (APCRI)
- ❖ Life Member of Indian Red Cross Society
- ❖ Life Member of IMA College of General Practitioners
- ❖ Post Graduate Certificate Course of HIV/AIDS & STD Management Counsellor.
- ❖ Post Graduate Certificate Course Environmental & Occupational Health.

ELECTROCARDIOGRAM

Patient Name Deepak Sharone

Date 12-11-22 Age 30yrs Sex m

Referred by Dr. M N Thareja



THAREJA NURSING HOME

1, Ram Kuteer Company Bagh Road, ALWAR - 301001 (Raj.)
Mob. 9982111801, Ph. 0144-2700184, 2331842, Telefax: 0144-2342339
E-mail: drmnthareja@yahoo.com



Name Mr. Deepak Shama Age..... Yr OPD/UHID..... Date 12/11/21
Address Mobile No.....

VITALS	B.P.	Pulse	Temp.	Wt.	Ht.	Allergies
--------	------	-------	-------	-----	-----	-----------

Complaints

Routine eye check up

Findings

*VA - 6/24 P → 6/6
6/9 P → 6/6*

*NG
NG*

*9L
Cornea clear B/E*

Color vision ^{WNL} _{WNL} B/E Refractive error

Treatment

*Adv
@ glasses*

Shivani
Dr. Shivani Thareja
M.S. (OPHTHAL)
Fellow (CORNEA)
L.V. Prasad Eye Institute
CORNEA CONSULTANT

DR. M.N. THAREJA
7233 (RMC)
Male Infertility Specialist

DR. SAVITA THAREJA
7600 (RMC)
Female Infertility Specialist

DR. JAYANT THAREJA
A-0824 (RSDC)
M.D.S.
Oral & Maxillo - Facial Surgery
Ex Resident Trauma Centre,
AIIMS, Delhi

DR. SHIVANI THAREJA
10807 / 31220 (RMC)
Ophthalmologist
Cornea Specialist

DR. PRERNA THAREJA
A-3574
MDS (Endodontics)
Root Canal Specialist
Ex Resident
AIIMS, Jodhpur

DR. H.R. GUPTA
1744 (RMC)
Senior Consultant
M.S. Gen Surgeon

DR. VARUN SAPRA
Reg. No. 70990 (DMC)
MBBS DNB ORTHO, D.ORTHO
Joint Replacement &
Arthroscopy Surgeon

Pain Scale

0	2	4	6	8	10
No Pain	Mild Pain	Distressing	Disressing	Intense	Excruciating



GUPTA ENT AND HEART CENTRE

Dayanand Marg, Nangli Circle, Alwar (Raj.) Ph. 0144-3591336 | M. 7378184427

Echocardiography Report

Name : Mr. Deepak Sharma
Age / Sex : 30yrs./male

Refd by: Dr. M. N. Thareja
Date : 12 November 2022

Clinical Diagnosis : For Cardiac Evaluation
2D Echocardiography Findings
Mitral Valve : Normal
Aortic Valve : Normal
Tricuspid Valve : Normal
Pulmonary Valve : Normal
Left Atrium : 4.1cm: Dilated
Left Ventricle : Normal LV size with normal LV systolic function. No RWMA


LVIDd	4.0cm.	IVSd	1.1cm.	EF	60%	Visual
LVIDs	2.5cm.	PWd	1.1cm.	EF	%	F.S.

Right Atrium : Normal
Right Ventricle : Normal
Aorta : 2.8cm: Normal
Pulmonary Artery : Normal
Pulmonary Veins : Normal
Superior Venacava : Normal
Inferior Venacava : Normal
Pericardium : Normal
Intracardiac Masses : No Intracardiac masses seen
IAS/IVS : Intact

Doppler Findings:

Valve	Peak Velocity (cm/s)	Peak Gradient (mmHg)	Mean Gradient (mmHg)	Regurgitation Grade	others/comments
Mitral Valve	E-/A-98/74			No MR	
Aortic Valve	119				
Tricuspid Valve				No TR, No PAH.	
Pulmonary Valve	80				

Diagnosis : Transthoracic echo done in supine position at resting heart rate of 70bpm, shows **Normal LV size with normal LV systolic function. LVEF~60% (Visual). No RWMA.**
Dilated LA, other cardiac chambers are normal in Size.
No MR, No TR, No PAH.
Normal MIP.
No pericardial effusion /Vegetation /Clot Intracardiac masses seen.
Normal left sided arch of aorta, No Coarctation.


Dr. Praem Gupta
MBBS, PGDC
Dr. Praem Gupta
(Non-invasive cardiologist)
Gupta ENT and Heart Centre
Nangli Circle, Alwar

Please correlate clinically

This report is not valid for medico legal purpose.



MEHAR'S

SAHARA DIAGNOSTICS

Reg. No. NHM/434

Dr. R.D. Arora

M.D., D.M.R.E (Radio-dagnosis)

University Topper

R.M.C. Reg. No. 28052 & 009456

Mob.: 9829136035

The Healing Ashram, 12 Kailash Colony, Bhagat Singh Circle, Alwar

12 NOV 2022

NAME : DEEPAK SHARMA
Clinician: Dr THAREJA HOSP
FOR : ABDOMEN
c/o pain abdomen [indication/ reason for scan]

On real time B-mode sonography

Liver is enlarged in size and echo pattern enhanced, no SOL is seen. Hepatic and portal veins are normal. CBD is normal in caliber, no obstruction is seen.

Gall Bladder is normal in size and shape, no calculus or inflammation is seen.

Pancreas is normal in size and echopattern, no SOL is seen.

Spleen is normal in size and echopattern, no SOL is seen.

Kidneys, bilaterally are normal in size and shape, no calculus or dilated calyces are seen.

Right Iliac region appendix could not be traced at present

No evidence of ascites, free Pleural effusion or lymphadenopathy is seen.

Urinary Bladder is normal in size, wall is normal in thickness, no calculus or growth is seen.

Prostate normal

IMPRESSION:

Fatty liver gr 2

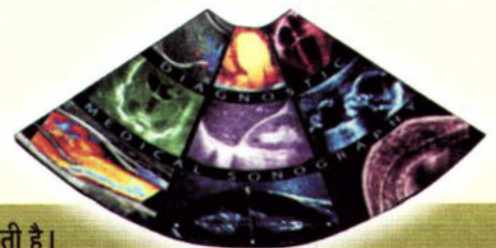Further evaluation is suggested.

Patient information - Kindly note no luminal pathology can be detected in non distended urinary tract.

Dr Ram das arora

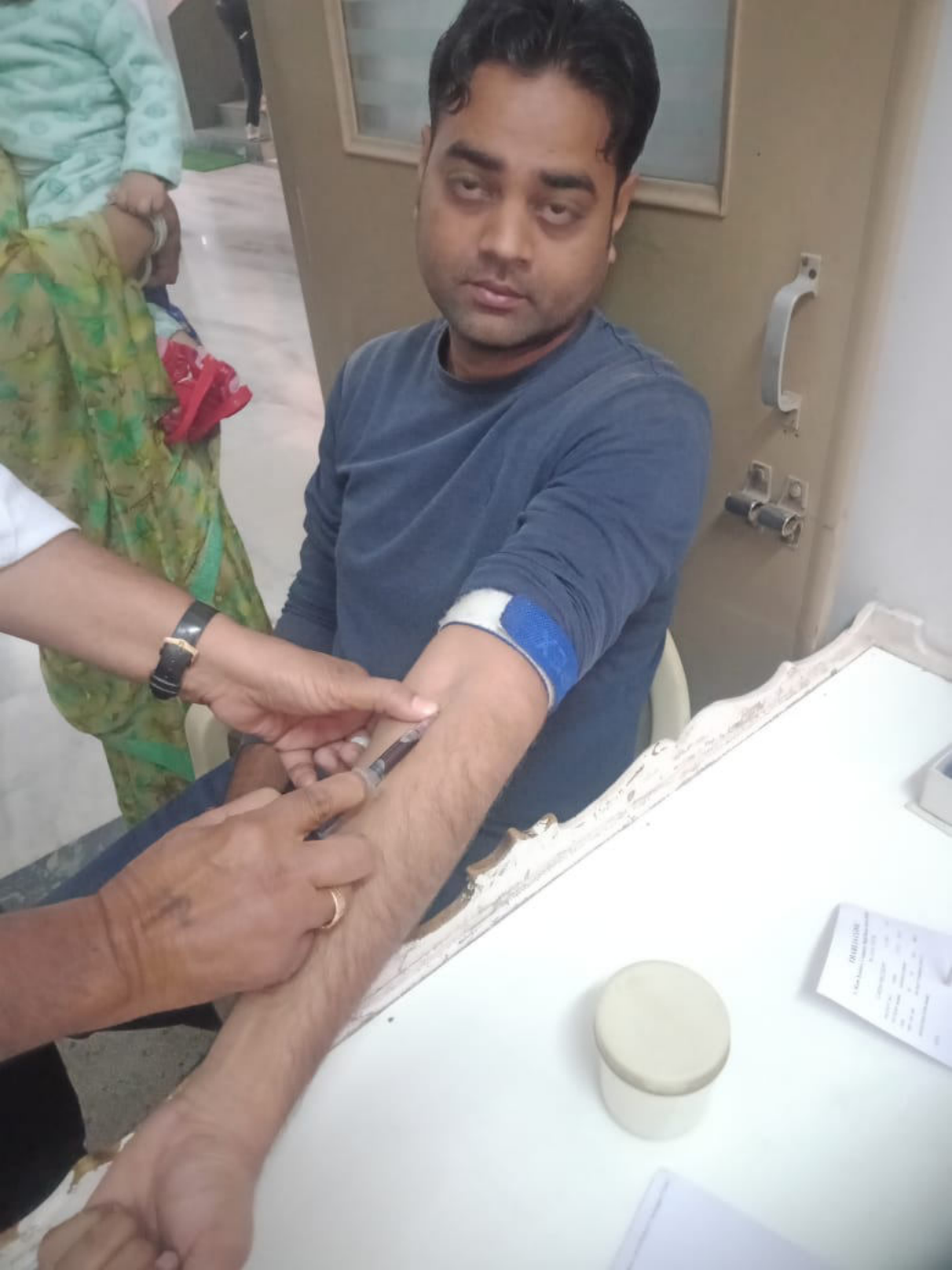Ultrasound scan is an investigation and therefore has technical limitations as well as inaccuracies inherent in the laboratory and statistical analysis of biological process. It should always be viewed in this perspective. Further this is a routine general scan grossly containing information sought by ref consultant and report generated thus, is for his perusal only. Considering pace of advances in the field of sonography, more specified information can also be obtained by prior intimation.

- Consultant of Radiology works
- Working hours 10 a.m. to 4 p.m. On Call Basis



“ भ्रूण लिंग परीक्षण करवाना जघन्य अपराध है तथा इसकी शिकायत 104 टोल फ्री सेवा पर की जा सकती है।

“ • “बेटी बचाओं - बेटी पढ़ाओं”



Dr. [Name]
[Address]
[Phone Number]
[Email Address]

RIGHT

DEEPAK SHARMA 30 Y BY DR M.N.THAREJA 10568.2 M CHEST, PA 11/12/2022
THAREJA NURSING HOME. COMPANY BAGH ROAD, ALWAR