



H Swaminarayan Nagar, Off Mumbai-Agra Highway,
Panchvati, Nashik - 422 003.
+91- 253 - 2510250 / 350 / 450 / 550 / 750
apollonashik@apollohospitals.com
www.askapollo.com

QFAHN/BILL/003/V1



Name : Mr. PANKAJ BHAGWAN TURAKNE (32 /M)
Address : 8 FRENCH VILLA KAILAS NAGAR INDIRA NAGAR NASHIK, NASHIK, NASHIK,
MAHARASHTRA, INDIA

Date : 08/10/2022

Examined by:
Package : MediWheel Full Body Health Checkup Male Below 40
Package

UHID : MHN1.0000126518

AHC No : NSKAH27898

CHIEF COMPLAINTS

For corporate health checkup
No specific complaints

PRESENT KNOWN ILLNESS

Present known illness

No history of : - Diabetes mellitus, Hypertension, Thyroid disorder, Heart disease, Stroke, Asthma, COPD, Cancer

DRUG ALLERGY

NO KNOWN ALLERGY

:10/10/2022

SYSTEMIC REVIEW

Cardiovascular system

- Nil Significant

Past medical history

Do you have any allergies? - No
Do you have any drug allergies? - No
Past medical history - nil significant
Covid 19 - Yes
Post detection (3 Weeks) - No
Hospitalization for Covid 19 - No
Oxygen support - No

Surgical history

Surgical history - Nil

Immunization history

- Covid Dose1, Covid Dose2

Personal history

Marital status - Married
No. of children - 01
Diet - Vegetarian
Alcohol - does not consume alcohol
Smoking - No
Chews tobacco - No
Physical activity - Active

Family history

Father - alive
Aged - 54 yrs
Mother - alive
Aged - 49 yrs
Brothers - 1
Diabetes - father
Coronary artery disease - none
Cancer - None

PHYSICAL EXAMINATION

General



H Swaminarayan Nagar, Off Mumbai-Agra Highway,
Panchvati, Nashik - 422 003.

+91- 253 - 2510250 / 350 / 450 / 550 / 750

apollonashik@apollohospitals.com

www.askapollo.com

QFAHN/BLL/003/V1



Name : Mr. PANKAJ BHAGWAN TURAKNE (32 /M)


UHID : MHN1.0000126518

Date : 08/10/2022

Package : MediWheel Full Body Health Checkup Male Below 40 Package

AHC No : NSKAH27898


General appearance - normal
 Build - normal
 Height - 166
 Weight - 77.8
 BMI - 28.23
 Pallor - No
 Oedema - no
 Temperature - 97.6
 S₀₂ - 98

 **Cardiovascular system**


Heart rate (Per minute) - 87
 Rhythm - Regular
 - B.P. Supine
 Systolic(mm of Hg) - 120
 Diastolic(mm of Hg) - 70
 Heart sounds - S1S2+

Respiratory system

Breath sounds - Normal vesicular breath sounds

 **Abdomen**

Organomegaly - No
 Tenderness - No





H Swaminarayan Nagar, Off Mumbai-Agra Highway,
Panchvati, Nashik - 422 003.

+91- 253 - 2510250 / 350 / 450 / 550 / 750

apollonashik@apollohospitals.com

www.askapollo.com

QFAHN/BILL/003/V1



Name : Mr. PANKAJ BHAGWAN TURAKNE (32 /M)

UHID : MHN1.0000126518

Date : 08/10/2022

Package : MediWheel Full Body Health Checkup Male Below 40 Package

AHC No : NSKAH27898

C B C WITH ESR (AUTOMATION + STANDARD METHOD)

Test Name	Result	Unit	Level	Range
Hemoglobin	14.8	g/dl	●	13.0-18.0
Haematocrit	46.2	%	●	39.0-54.0
RBC COUNT	5.20	Million/ ul	●	4.2-6.5
MCV	88.7	fl	●	75.0-95.0
MCH	28.5	pg	●	26.0-32.0
MCHC	32.1	g/dl	●	31.0-36.0
RDW	16.2 *	%	●	11-16
Platelet Count(Optical/Impedance)	280	10 ⁹ /m ³	●	140-440
TLC Count	8.30	10 ³ /m ³	●	4.0-11.0
Neutrophils	40 *	%	●	45-75
Lymphocytes	53 *	%	●	20-45
Eosinophils	02	%	●	1-6
Monocytes	05	%	●	1-10
Basophils	00	%	●	0-1
ERYTHROCYTE SEDIMENTATION RATE (ESR)	06	mm/1st hr	●	0-10

ALKALINE PHOSPHATASE - SERUM/PLASMA 66 U/L ● 0-100

AST (SGOT) - SERUM 31 U/L ● 15-37

BILIRUBIN, TOTAL - SERUM 0.7 mg/dL ● 0.0-1.0

LIPID PROFILE TEST (PACKAGE)

Test Name	Result	Unit	Level	Range
Total Cholesterol	195	mg/dL	●	0-200

CREATININE - SERUM / PLASMA

Test Name	Result	Unit	Level	Range
CREATININE - SERUM / PLASMA	0.9	mg/dL	●	0.8-1.3

LIVER FUNCTION TEST (PACKAGE)

Test Name	Result	Unit	Level	Range
GGTP: GAMMA GLUTAMYL TRANSPEPTIDASE - SERUM	21	U/L	●	0-50

GLUCOSE - SERUM / PLASMA (FASTING)

Test Name	Result	Unit	Level	Range
Glucose - Plasma (Fasting)	70	mg/dL	●	70-100
URINE GLUCOSE(FASTING): (Strip Method)	Nil			

BLOOD GROUPING AND TYPING (ABO and Rh)

Test Name	Result	Unit	Level	Range
ABO Group:	AB			
Rh (D) Type:	POSITIVE			

LIVER FUNCTION TEST (PACKAGE)

Test Name	Result	Unit	Level	Range
ALT(SGPT) - SERUM / PLASMA	26 *	U/L	●	30-65
ALBUMIN - SERUM	4.5	g/dL	●	3.5-5

GLUCOSE - SERUM / PLASMA (POST PRANDIAL)

Test Name	Result	Unit	Level	Range
Glucose - Plasma (POST PRANDIAL)	100	mg/dL	●	70-140
URINE GLUCOSE(POST PRANDIAL):(Strip Method)	Nil			

LIPID PROFILE TEST (PACKAGE)

● Within Normal Range ● Borderline High/Low ● Out of Range



H Swaminarayan Nagar, Off Mumbai-Agra Highway,
Panchvati, Nashik - 422 003.
+91- 253 - 2510250 / 350 / 450 / 550 / 750
apollonashik@apollohospitals.com
www.askapollo.com

QFAHN/BILL/003/V1



Name : Mr. PANKAJ BHAGWAN TURAKNE (32 /M)

UHID : MHN1.0000126518

Date : 08/10/2022

Package : MediWheel Full Body Health Checkup Male Below 40 Package

AHC No : NSKAH27898

Test Name	Result	Unit	Level	Range
HDL CHOLESTEROL - SERUM / PLASMA	48	mg/dL	●	40-60
TOTAL CHOLESTEROL/HDL CHOLESTEROL RATIO(Calculated)	4.1		●	0.0-4.5
LDL Cholesterol (Direct)	151	mg/dL	●	

Test Name	Result	Unit	Level	Range
BILIRUBIN CONJUGATED (DIRECT) - SERUM	0.2	mg/dL	●	0.0-0.3
BILIRUBIN UNCONJUGATED - SERUM(Calculated)	0.5	mg/dL	●	0.0-0.7

LIVER FUNCTION TEST (PACKAGE)

Test Name	Result	Unit	Level	Range
PROTEIN, TOTAL - SERUM / PLASMA	8.3 *	g/dL	●	6.4-8.2
PROTEIN, TOTAL - SERUM / PLASMA	8.3 *	g/dL	●	6.4-8.2

THYROID PROFILE - I(T3,T4 AND TSH)

Test Name	Result	Unit	Level	Range
TOTAL T3: TRI IODOTHYRONINE - SERUM	155	ng/dL	●	Healthy Adults: 69 - 215
TOTAL T4: THYROXINE - SERUM	10.8	µg/dL	●	Healthy Adults: 5.2-12.7

LIPID PROFILE TEST (PACKAGE)

Test Name	Result	Unit	Level	Range
Triglycerides - Serum	94	mg/dL	●	0-150

THYROID PROFILE - I(T3,T4 AND TSH)

Test Name	Result	Unit	Level	Range
TSH: THYROID STIMULATING HORMONE - SERUM	2.7	uIU/mL	●	Euthyroid: 0.3 - 4.5 Hypothyroid: 7.1 - >75

URIC ACID - SERUM

Test Name	Result	Unit	Level	Range
URIC ACID - SERUM	7.2	mg/dL	●	3.5-7.2

LIVER FUNCTION TEST (PACKAGE)

CARDIAC STRESS TEST - (TMT)

ECG

ULTRASOUND - WHOLE ABDOMEN

No significant abnormality is detected.

X-RAY CHEST PA

INVESTIGATIONS NOT DONE / NOT YET REPORTED / NOT PART OF PACKAGE(LAB,RADIOLOGY & CARDIOLOGY)

Haematology

STOOL ROUTINE

● Within Normal Range ● Borderline High/Low ● Out of Range

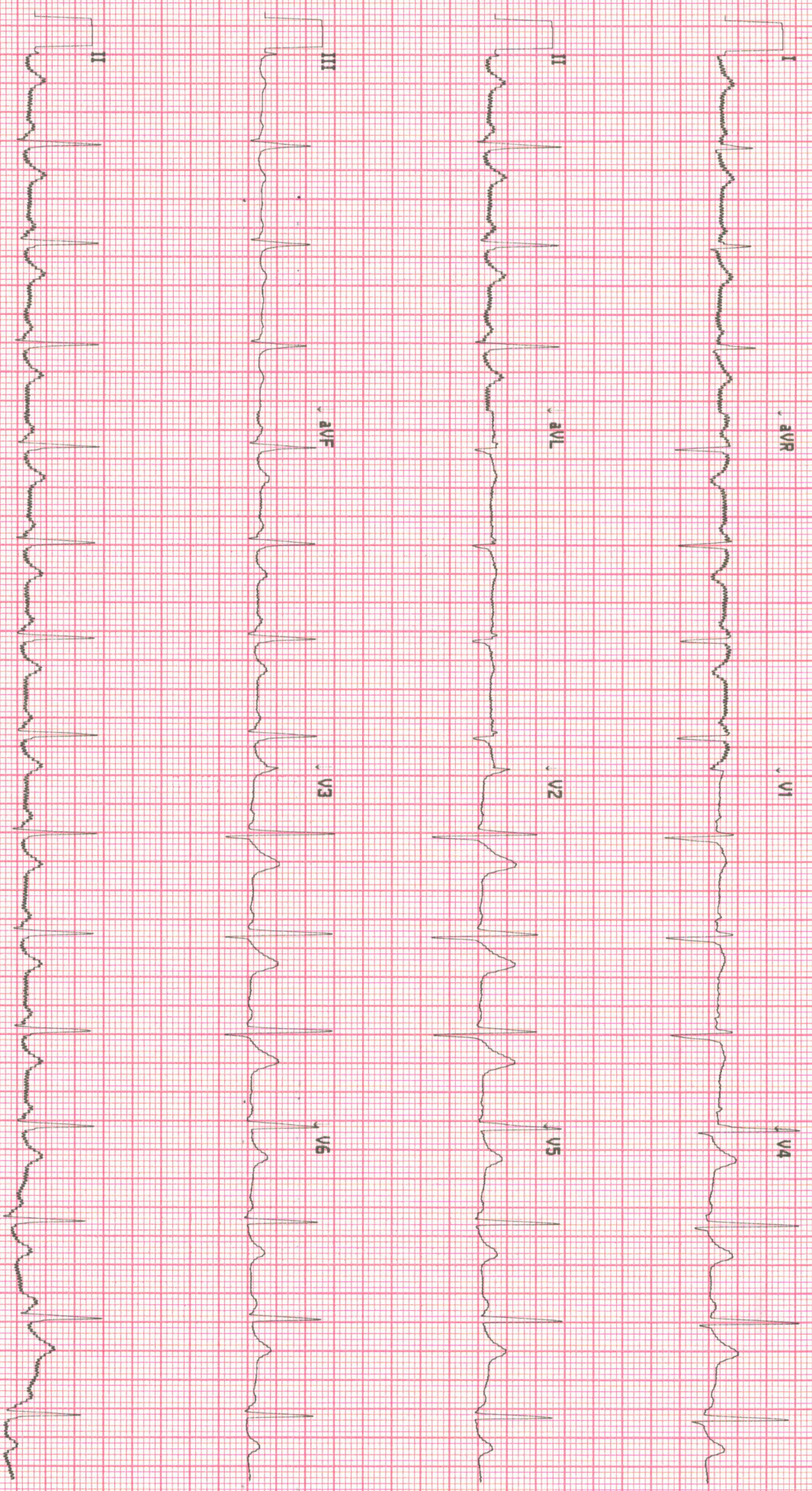
Turakne, Pankaj
ID:
DOB:
32yr, Male

8-Oct-2022 12:46:05

Vent Rate: 87 BPM
PR Int: 137 ms
QRS dur: 85 ms
QT/QTc: 340/385 ms
P-R-T axes: 51 70 49

SINUS RHYTHM
NORMAL ECG

UNCONFIRMED REPORT



113500188213

No Site Name

Site * 0 Cart *

Z Version 2.0.4.0 Sequence #20474 25mm/5 10mm/mV 0.05-40 Hz



H Swaminarayan Nagar, Off Mumbai-Agra Highway,
Panchvati, Nashik - 422 003.

+91- 253 - 2510250 / 350 / 450 / 550 / 750

apollonashik@apollohospitals.com

www.askapollo.com

QFAHN/BILL/003/V1



Radiology

Patient Details : Mr. PANKAJ BHAGWAN TURAKNE | Male | 32Yr 5Mth 28Days

UHID : MHN1.0000126518 **Patient Location:** AHC

Patient Identifier: NSKAH27898



DRN : 122038600 **Completed on :** 08-OCT-2022 09:58

Ref Doctor : Dr. Rajashri Dhongade

X-RAY CHEST PA

Mild rotation.

Both lung fields are clear.

Costophrenic angles are clear.

Cardiac size and contour are within normal limits.


Rib cage is normal.

Soft tissues are normal.

Suggest : Clinical correlation.

Impression

--- END OF THE REPORT ---


Dr. Gorakhnath T

CONSULTANT-RADIOLOGY



H Swaminarayan Nagar, Off Mumbai-Agra Highway,
Panchvati, Nashik - 422 003.

+91- 253 - 2510250 / 350 / 450 / 550 / 750

apollonashik@apollohospitals.com

www.askapollo.com

QFAHN/BILL/003/V1



MD (Radiology)

Patient Details : Mr. PANKAJ BHAGWAN TURAKNE | Male | 32Yr 5Mth 28Days

UHID : MHN1.0000126518 **Patient Location:** AHC

Patient Identifier: NSKAH27898



DRN : 222023470 **Completed on :** 08-OCT-2022 11:55

Ref Doctor : Dr. Rajashri Dhongade

ULTRASOUND - WHOLE ABDOMEN

LIVER : Normal in size. Echotexture is uniform and normal. No I.H.B.D./ focal lesions.

PORTAL VEIN: Normal in size.

GALL BLADDER: Well distended with normal walls and lumen.
No calculi/pericholecystic fluid.

COMMON BILE DUCT: Normal in size.

PANCREAS : Visualized portion of head and body of pancreas appears normal in size and echotexture. Rest of the pancreas is obscured due to bowel gases.

AORTA, IVC and para aortic areas are normal.

SPLEEN : Normal in size and echotexture.

KIDNEYS: Both kidneys are normal in site, size and echotexture.

No evidence of calculi/ hydronephrosis.

Right kidney measures: 9.2 x 4.6 cm.

Left kidney measures : 10 x 5.5 cm.

URINARY BLADDER: Well distended with normal walls.

No evidence of calculi/ growth/ diverticula .

PROSTATE : Normal in size with homogenous echogenicity. No evidence of calcification within.

Seminal vesicles are normal.



H Swaminarayan Nagar, Off Mumbai-Agra Highway,
Panchvati, Nashik - 422 003.

+91- 253 - 2510250 / 350 / 450 / 550 / 750

apollonashik@apollohospitals.com

www.askapollo.com

QFAHN/BILL/003/V1



Mr. PANKAJ BHAGWAN TURAKNE

MHN1.0000126518

NSKAH27898

ULTRASOUND - WHOLE ABDOMEN

Visualized bowel loops appear grossly normal.

No evidence of any free fluid in the peritoneal cavity.


Impression

No significant abnormality is detected.

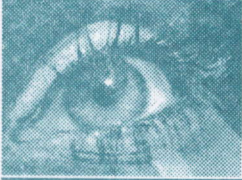--- END OF THE REPORT ---

Kunal Kalyanrao Patil

Consultant - MD (Radiodiagnosis)



20-20-20



OPHTHALMOLOGY



Name : Mr. Pawkaj Turakne
 Occupation : _____
 Age : 32 Sex : Male Female S/M/W/D
 Address : Nsle
 Tel. No. _____

Date 8/10/22 UNIT _____
 Room No. _____ Out Patient
 Ref. Physician : _____
 Copies to : _____

REPORT ON OPHTHALMIC EXAMINATION

HISTORY : _____

PRESENT COMPLAINT : - Routine checkup

PAST HISTORY : DM / HTN / ALLERGY

ON EXAMINATION

VISION :

RE UR 6/9P LE UR 6/6P

	RIGHT				LEFT				
	PGP	SPH	CYL	AXIS	VA	SPH	CYL	AXIS	VA
DIST		0.5	-	-	6/6	0.5	-	-	6/6
NEAR					2				2

R / Retinoscopy :

	RIGHT			LEFT		
	SPH	CYL	AXIS	SPH	CYL	AXIS
	1.75	-	-	1.75	0.75	135

Refraction or Acceptance :



	RIGHT				LEFT			
	SPH	CYL	AXIS	VA	SPH	CYL	AXIS	VA
DIST	0.75	-	-	6/6	0.5	-	-	6/6
NEAR				2				2

CR 10

Anterior Segment :

RE

LE

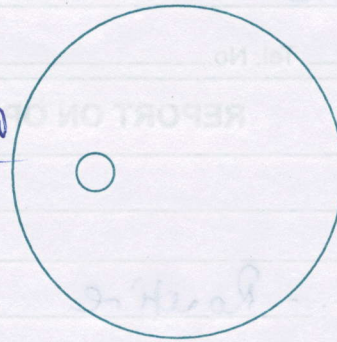


Bupupih mmm
@ kelen

Fundus :

RE

LE



gowa

Diagnosis :

Myopia

Advise / Rx:

eye exam
eye drops

CONSULTANT OPHTHALMOLOGIST



H Swaminarayan Nagar, Off Mumbai-Agra Highway,
Panchvati, Nashik - 422 003.

+91- 253 - 2510250 / 350 / 450 / 550 / 750

apollonashik@apollohospitals.com

www.askapollo.com

QFAHN/BJLL/003/V1



8/10/22

Mr Parthaj Tralokhe

IM

- Partial \uparrow \overline{c} \leftarrow $\frac{\quad}{8}$

- mild
- occlusal Phagoc seen

- Super class 3 malocclusion bilaterally

Adv 1 - Scaling req.
Exth \overline{c} \leftarrow $\frac{\quad}{8}$

ID: 000126518

Visit:

32years

Asian

Male

BRUCE

Max HR: 169bpm 94% of max predicted 178bpm

Max BP: 130/80

Reason for Termination: Max HR attained

Total Exercise time: 7:28

Maximum workload: 9.2METS

25.0 mm/s

10.0 mm/mV

100hz

Referred by:

Test ind:

Phase Name	Stage Name	Time in Stage	Speed (mph)	Grade (%)	WorkLoad (METS)	HR (bpm)	BP (mmHg)	RPP (x100)
PRETEST	SUPINE	0:51	**.*	**.*	1.0	103	110/70	113
	STANDING	0:18	**.*	**.*	1.0	106	110/70	117
	HYPERVENT	0:16	0.8	0.0	1.0	102	110/70	112
EXERCISE	STAGE 1	3:00	1.7	10.0	4.6	131		
	STAGE 2	3:00	2.5	12.0	7.0	148	120/70	178
	STAGE 3	1:28	3.4	14.0	9.2	169	130/80	220
RECOVERY	Post	4:10	**.*	**.*	1.0	117	130/80	152

test mild positive for ST