


Health checkup at tie-up Ctr

HealthChkup Authorisatn letter



Union Bank of India
RO - AHMEDNAGAR
AHMEDNAGAR, AHMEDNAGAR,
Maharashtra, - 0

To,

The Chief Medical Officer

M/S Mediwheel
https://mediwheel.in/signup011-
41195959(A brand name of
Arcofemi Healthcare Ltd).
Mumbai400021

Dear Sir,

Tie-up arrangement for Health Checkup under Health Checkup

35-40 Female

Shri/Smt./Kum. SHINDE, SONALI MAHESH

P.F. No. 602127

Designation : Asst Manager

Checkup for Financial Year

2023-
2024

Approved Charges Rs.

3000.00

The above mentioned staff member of our Branch/Office desires to undergo Health Checkup at your Hospital/Centre/Clinic, under the tie-up arrangement entered into with you, by our bank.

Please send the receipt of the above payment and the relevant reports to our above address.

Thanking you,

Yours Faithfully,

(Signature of the Employee)

BRANCH MANAGER/SENIOR MANAGER



PS. : Status of the application - Sanctioned

View Worklist

Health checkup at tie-up Ctr | HealthChkup Authorisatn letter

व्यापार व वैयक्तिक
सोने तारण कर्ज उपलब्ध
* सोपी सुलाभ व जलद व
* कमीत कमी कागदपत्रे



Union Home

GET INSTANT HOME LOAN
AT ATTRACTIVE TERMS
WITH MINIMUM PAPERWORK

Interest on daily
reducing balance

अधिक माहित

कर्ज वितरण करणारी शा

आयकर विभाग
INCOME TAX DEPARTMENT
MAHESH SUBHASH SUTAR
SUBHASH SHANKAR SUTAR
31/01/1988
Permanent Account Number
CARPS7219G
Signature
भारत सरकार
GOVT. OF INDIA
10022013

[Handwritten Signature]

Dr. Jai B. Raisinghani

M.D. Card.
Clinical Cardiologist
Reg. No. 29981 (MCI)



MER- MEDICAL EXAMINATION REPORT

Date of Examination	1/6/24		
NAME	Mahesh Sule		
AGE	36	Gender:	M
HEIGHT(cm)	161	WEIGHT(kg):	81 BMI: 31.2
B.P.	130/80 mmHg		
ECG	Attach		
X Ray	Attach.		
Vision Checkup:	Left Eye		Right Eye
	Distance Vision:	6/6	6/6
	Near Vision:	6/6	6/6
	Color Vision:	Normal	
ENT / Audiometry Checkup	Normal		
Present Ailments	No Complaint		
Details of Past ailments (If Any)	NO		
Comments / Advice : She /He is Physically Fit	<input checked="" type="checkbox"/> He is physically Fit No History No symptoms		

Dr. Jai B. Raisinghani

M.D., A.C.C.
Clinical Cardiologist
Reg. No. 29981 (MCI)

Signature with Stamp of Medical Examiner



Patient Name : Mahesh Sutar	Patient ID : AHCN-34031052401000
Age/Sex : 36 Years /Male	Register Date : 01 Jun, 2024
Ref. By : Apollo Health - Arcofemi - Mediwheel	Reported Date : 01 Jun, 2024

CBC with ESR

Investigation	Observed Value		Biological Reference Interval	Unit
Hemoglobin (Hb)	15.4		13 - 17	g/dL
Hemoglobin %	90.59		0 - 100 Based on 17=100%	%
Total RBC Count	5.54	High	4.5 - 5.5	mill/cumm
Packed Cell Volume (PCV)	42.0		40.7 - 50.3	%
Mean Corpuscular Volume(MCV)	75.81	Low	78.2 - 97.90	fL
Mean Corpuscular Hemoglobin (MCH)	27.80		27 - 33	pg/cell
Mean Corpuscular Hemoglobin Concentration (MCHC)	36.67	High	33 - 36	g/dL
Hematocrit Value (Hct)	42.0		40 - 50	%
Red cell Distribution Width (RDW)	14.5	High	11.5 - 14	%
Total WBC Count	6035		4000 - 11000	cumm
Neutrophils	57		40 - 70	%
Lymphocytes	36		20 - 40	%
Eosinophils	03		1 - 4	%
Monocytes	04		1 - 6	%
Basophils	00		0 - 1	%
Platelet Count	368000		150000 - 450000	/cumm
Erythrocyte Sedimentation Rate (ESR)	10		0 - 22	mm/hr

Dr. S N Tripathi
M.D. (Path)
Reg No. 2000/04/1994

The above result relate only to the specimens received and tested in laboratory and should be always correlate with clinical findings and other laboratory markers.

Patient Name : Mahesh Sutar	Patient ID : AHCN-34031052401000
Age/Sex : 36 Years /Male	Register Date : 01 Jun, 2024
Ref. By : Apollo Health - Arcofemi - Mediwheel	Reported Date : 01 Jun, 2024

Investigation	Observed Value	Biological Reference Interval	Unit
---------------	----------------	-------------------------------	------

BLOOD GROUP, ABO & RH TYPING

Blood Group, ABO & RH Typing

ABO Group	B
RH Factor	Positive

The test to determine your blood group is called ABO typing. Your blood sample is mixed with antibodies against type A and B blood. Then, the sample is checked to see whether or not the blood cells stick together. If blood cells stick together, it means the blood reacted with one of the antibodies.

Rhesus (Rh) factor is an inherited protein found on the surface of red blood cells. **If your blood has the protein, you're Rh positive. If your blood lacks the protein, you're Rh negative.**

Indirect, Direct & Total Bilirubin

Indirect, Direct & Total Bilirubin


Indirect Bilirubin	0.64	0.2 - 0.8	mg/dL
Direct Bilirubin	0.30	0 - 0.3	mg/dL
Total Bilirubin	0.94	0 - 2.0	mg/dL

Fasting Glucose And Post Prandial Glucose

Fasting Blood Glucose	93.83	70 - 110	mg/dL
Fasting Urine Glucose	Absent		
Fasting Urine ketone	Absent		
Post Prandial Blood Glucose	105.8	70 - 140	mg/dL
Post Prandial Urine Glucose	SNR		
Post Prandial Urine ketone	SNR		

SGPT (ALT)

SGPT (ALT)	38.9	00 - 40	U/L
Interpretation			



Dr. S N Tripathi
M.D. (Path)
Reg No. 2000/04/1994

The above result relate only to the specimens received and tested in laboratory and should be always correlate with clinical findings and other laboratory markers.

Patient Name : Mahesh Sutar	Patient ID : AHCN-34031052401000
Age/Sex : 36 Years /Male	Register Date : 01 Jun, 2024
Ref. By : Apollo Health - Arcofemi - Mediwheel	Reported Date : 01 Jun, 2024

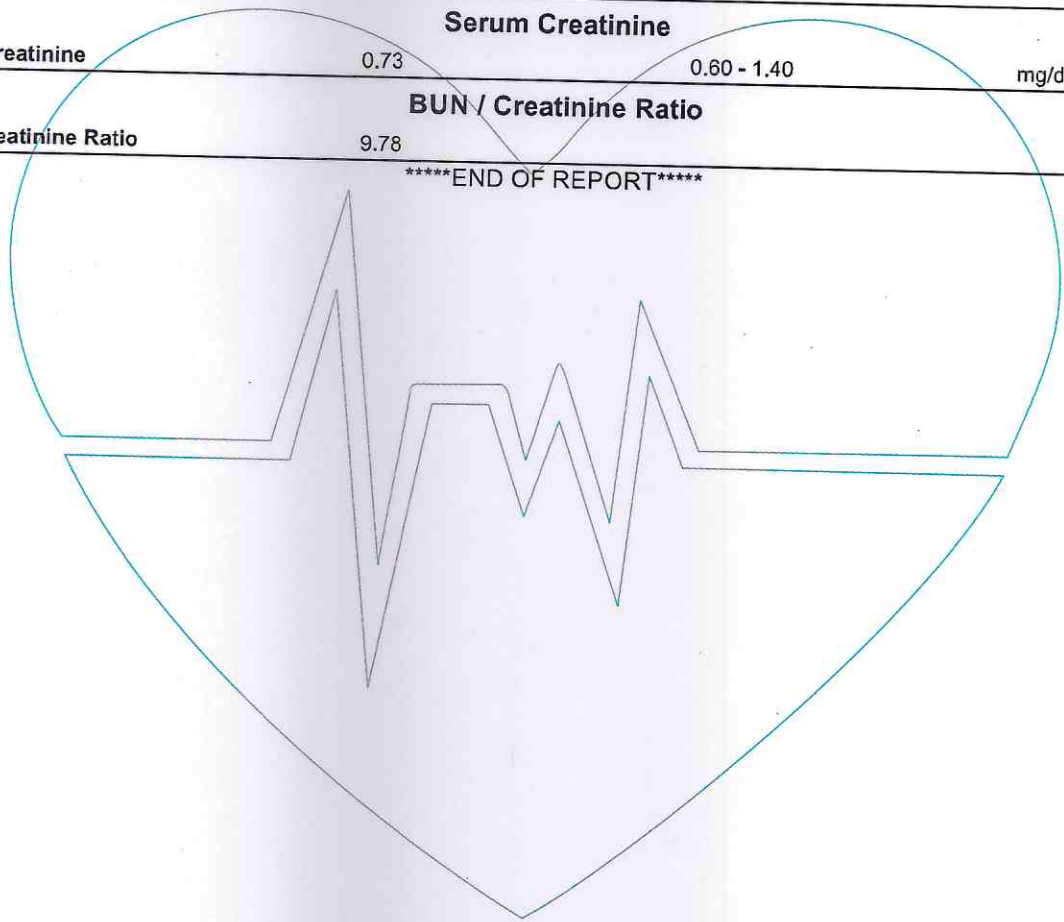

Investigation	Observed Value	Biological Reference Interval	Unit
---------------	----------------	-------------------------------	------

SGPT exists predominantly in the liver and leaks into the bloodstream when produced in excess. The SGPT normal range is about 0 - 28 units per liter of blood serum. Thus, very high level of SGPT in the blood can be an indication of damage or problems related to the liver.

Serum Creatinine			
Serum Creatinine	0.73	0.60 - 1.40	mg/dL

BUN / Creatinine Ratio			
BUN / Creatinine Ratio	9.78		

*****END OF REPORT*****

Dr. S N Tripathi
M.D. (Path)
Reg No. 2000/04/1994


The above result relate only to the specimens received and tested in laboratory and should be always correlate with clinical findings and other laboratory markers.

Patient Name : Mahesh Sutar
 Age/Sex : 36 Years /Male
 Ref. By : Apollo Health - Arcofemi - Mediwheel
 Patient ID : AHCN-34031052401000
 Register Date : 01 Jun, 2024
 Reported Date : 01 Jun, 2024

Urine Examination Routine

Urine Examination Routine

Investigation	Observed Value	Biological Reference Interval	Unit
Quantity	30		ml
Appearance clear	Clear		
Colour	Pale yellow		
PH	6.5	5.0 - 8.0	
Specific Gravity	1.015	1.005 - 1.030	
Proteins	Absent		
Glucose	Absent		
Ketones	Absent		
Bilirubin	Absent		
Urobilinogen	Absent		
Leucocyte Esterase	Absent		
Nitrite	Absent		
Occult Blood	Absent		
R.B.C.	Absent		
Pus Cells	1-3	0 - 5	WBC / hpf
Epithelial Cells	2-2	0 - 2	/hpf
Casts	Absent	0 - 0	/lpf
Crystals	Absent		
Amorphous Material	Absent		
Bacteria	Absent		



Dr. S N Tripathi
 M.D. (Path)
 Reg No. 2000/04/1994

The above result relate only to the specimens received and tested in laboratory and should be always correlate with clinical findings and other laboratory markers.



Clarity Medical Pvt. Ltd.

D7-Mahesh Sutar
36 Yrs / M / Non-Smoker
Ht/Wt : 161 Cms / 81 Kgs

Date-Time : 01-06-24 - 10:32
Ref By :
By (mmHg) : /

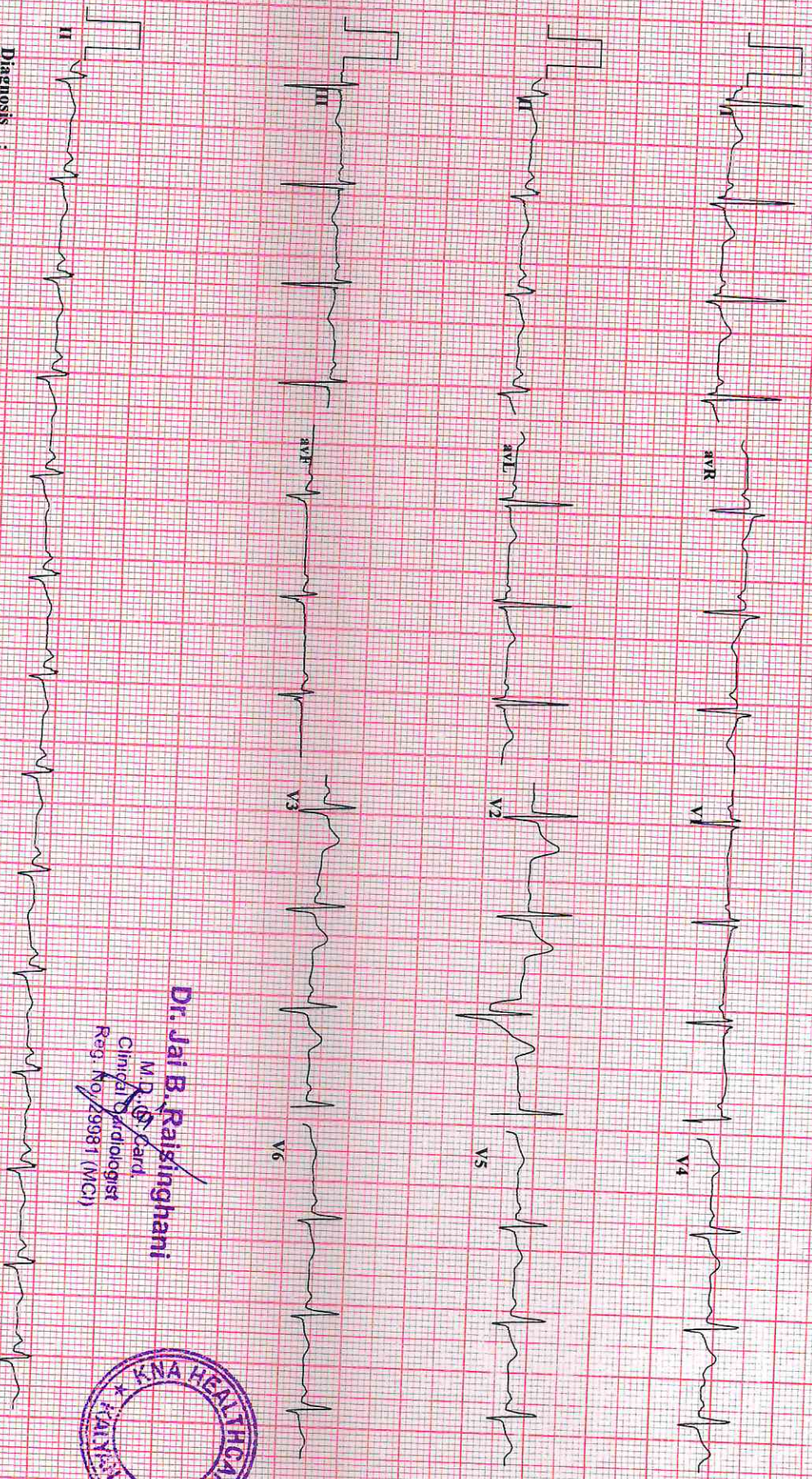
Sweep : 25 mm/Sec
Gain : 10 mm/mV
Filter/Notch : 0.1-35Hz / R50

HeartRate : 74
P Interval : 42 msec
PR Interval : 50 msec

QRS Interval : 55 msec
QT Interval : 87 msec
QTc Interval : 97 msec
P axis : +157°
QRS axis : +144°
T axis : +165°

KNA HEALTH CARE

Kna Healthcare Kalyan East (Mumbai)



Diagnosis :
Medication :

Comments : Sinus Rhythm, Normal ECG, Sinus Rhythm, Normal ECG, obse

Dr. Jai B. Raisinghani
M.D. Card
Clinical Cardiologist
Reg. No. 29981 (MCI)



Dr. Jai B. Raisinghani

within Normal limits

Dr. Jai B. Raisinghani
MD Cardiologist



SHREE GANESH DIAGNOSTIC CENTER

Let's do good...

SONOGRAPHY | COLOR DOPPLER | DIGITAL X-RAY | PATHOLOGY

Dr. Abhishek Singh
MBBS, DMRE, FMF (Mumbai)

Consultant Radiologist & Sonologist

Previous post in

1) Krishna Scan (Chennai)

2) Premier Scan (Kerala)

3) Bhabha Atomic Research Centre (Chembur, Mumbai)

4) Lokmanya Tilak Hospital (Sion, Mumbai)

5) Maharishi Valmiki Hospital (Delhi)

Name of patient : MAHESH SUTAR

Age/Sex : 36Years/MALE

Date 1/06/2024

RADIOGRAPH OF CHEST PA VIEW

Both the lung fields are clear.

The broncho vascular markings are appears normal.

The hilar shadows are appears normal.

Both Cardiophrenic and Costophrenic angles are clear.

The Cardiac silhouette is within normal limits.

Aortic shadow is normal.

Both domes of diaphragms are normal.

The visualised bony thorax is normal.

CONCLUSION : No Active Pulmonary Parenchymal Lesion is seen.

Abhishek

**DR ABHISHEK SINGH,
MBBS DMRE FMF
CONSULTANT RADIOLOGIST**

R

MAHESH SUTAR 36 Y MALE 1201202120 CHEST,FRN P->A 1-6-24
SHREE GANESH DIAGNOSTIC CLINIC