



LAB REPORT

Patient Name : Mrs. SUJITHA.V
Age / Gender : 29-Years / Female
UHID ID : MH20220040985
Doctor Name : Dr. ARUN PRAKASH

OP Report No. : INVA2107490
Bill No. : INV2204811
Sample Date : 23/10/2022 - 10:09 AM
Report Date : 23/10/2022 - 06:03 PM

Test Name	Result	Units	Reference Interval
HAEMATOLOGY			
Complete Blood Cell Count(CBC)			
HAEMOGLOBIN	<u>11.2</u>	gms/dl	male :13.0 - 17.0 female :12.0 - 15.0
PACKED CELL VOLUME	36.4	%	male : 40 - 50 female : 36 - 46
RBC COUNT	5.03	millions cells/cu.mm	female: 3.8 - 4.8 male : 4.5 - 5.5
TOTAL WBC	8,800	Cells/Cumm	4,000 - 11,000
Differential Count			
NEUTROPHILS	64	%	40 - 65
LYMPHOCYTES	31	%	30-50
EOSINOPHILS	05	%	01-06
MONOCYTES	<u>00</u>	%	1-10
BASOPHILS	00	%	0-2
ESR 60 MTS	09	mm	5 - 20
PLATELET COUNT	2.98	Lakhs/cumm	1.5 - 4.5
MCV	<u>72.5</u>	fL	76 - 96
MCH	<u>22.2</u>	pg	27 - 32
MCHC	30.7	gms/dl	30 - 36

INTERPRETATION: Test done on automated three part cell counter, all abnormal results are reviewed and confirmed microscopically.

BLOOD GROUPING & RH TYPING " O " POSITIVE

Healing Hearts and Lives



MURUGAN HOSPITALS

HEALING HANDS



LAB REPORT

Patient Name : Mrs. SUJITHA.V
 Age / Gender : 29-Years / Female
 UHID ID : MH20220040985
 Doctor Name : Dr. ARUN PRAKASH

OP Report No. : INVA2107490
 Bill No. : INV2204811
 Sample Date : 23/10/2022 - 10:09 AM
 Report Date : 23/10/2022 - 06:03 PM

Test Name	Result	Units	Reference Interval
BIO CHEMISTRY			
BLOOD SUGAR FASTING	301	mg/dl	70-110
BLOOD SUGAR POST PRANDIAL	<u>432</u>	mg/dl	80- 160
SERUM URIC ACID	3.2	mg/dl	male 3.1-7.0 , female 2.5-5.6
SERUM CREATININE	0.7	mg/dl	0.6-1.4
LIPID PROFILE			
TOTALCHOLESTEROL	189	mg/dl	< 200
TRIGLYCERIDE	214	mg/dl	< 150
HDL	42	mg/dl	35 - 80
VLDL	43	mg/dl	2 to 30
LDL	104	mg/dl	<130
CHOLESTEROL/ HDL RATIO	4.5	mg/dl	



LAB REPORT

Patient Name : Mrs. SUJITHA.V
Age / Gender : 29-Years / Female
UHID ID : MH20220040985
Doctor Name : Dr. ARUN PRAKASH

OP Report No. : INVA2107490
Bill No. : INV2204811
Sample Date : 23/10/2022 - 10:09 AM
Report Date : 23/10/2022 - 06:03 PM

Test Name	Result	Units	Reference Interval
LIVER FUNCTION TEST			
BILLIRUBIN(TOTAL)	0.4	mg/dl	0.0 -1.0
BILLIRUBIN(DIRECT)	0.2	mg/dl	0.1- 0.30
BILLIRUBIN(INDIRECT)	0.2	mg/dl	0.2-0.8
SGOT	12	IU/L	0-38
SGPT	17	IU/L	0.0-40
ALKALINE PHOSPHATASE	115	IU/L	40-140
			4-6Years 93-309
			13-15Years 74-390
TOTAL PROTEIN	7.2	gm/dl	6.6-8.7
ALBUMIN	4.3	gm/dl	3.5 - 5.5
GLOBULIN	2.9	gm/dl	2.0-3.5
AG RATIO	1.4		
GAMMA G T	20	U/L	male<49
			female<32
BLOOD UREA NITROGEN	<u>6.0</u>	mg/dl	7-21
HBA1C	9.2	%	normal: <6.0
			good control: 6.1-7.0
			fair control: 7.1- 8.0
			poor control:8.1 -10.0
			unsatisfactory: >10.0



LAB REPORT

Patient Name : Mrs. SUJITHA.V
Age / Gender : 29-Years / Female
UHID ID : MH20220040985
Doctor Name : Dr. ARUN PRAKASH

OP Report No. : INVA2107490
Bill No. : INV2204811
Sample Date : 23/10/2022 - 10:09 AM
Report Date : 23/10/2022 - 06:03 PM

Test Name	Result	Units	Reference Interval
-----------	--------	-------	--------------------

CLINICAL PATHOLOGY

URINE SUGAR (PP)	++++		
URINE ROUTINE			
COLOUR	Yellow		
APPEARANCE	Clear		
REACTION	Acidic		
SUGAR	+++		
ALBUMIN	Nil		
DEPOSITES			
PUS CELLS	6 - 8	/ HPF	
EPI CELLS	2 - 3	/ HPF	
RBC COUNT	Nil	/ HPF	
CAST	Nil		
CRYSTALS	Nil		
OTHERS	Nil		

NITHYALAB
Verified by

*** End of Report ***





LAB REPORT

NAME :	MRS. SUJITHA V	SAMPLE NO :	3822101415
PIN :	AND22380153914	COLLECTED ON :	23/10/2022 05:34 PM
AGE/GENDER :	29 Year(s)/Female	RECEIVED ON :	23/10/2022 05:34 PM
REFERRED BY :	Dr.ARUN PRAKASH	REPORTED ON :	23/10/2022 06:14 PM
CLIENT NAME :	MURUGAN HOSPITAL	REPRINT DATE :	23/10/2022 06:14 PM

Test	Obtained Value	Units	Bio.Ref.Intervals
------	----------------	-------	-------------------

CLINICAL PATHOLOGY

Stool Routine

General Examination (Stool)

Colour	Brownish yellow	Yellow to Brown
Form & Consistency	Semi solid	Semi solid
Mucus	Absent	Absent
Blood	Absent	Absent

Chemical Examination (Stool)

pH(pH strip test)	ACIDIC	Variable depending on food
--------------------	--------	----------------------------

Microscopy (Saline and Iodine mount) (Stool)

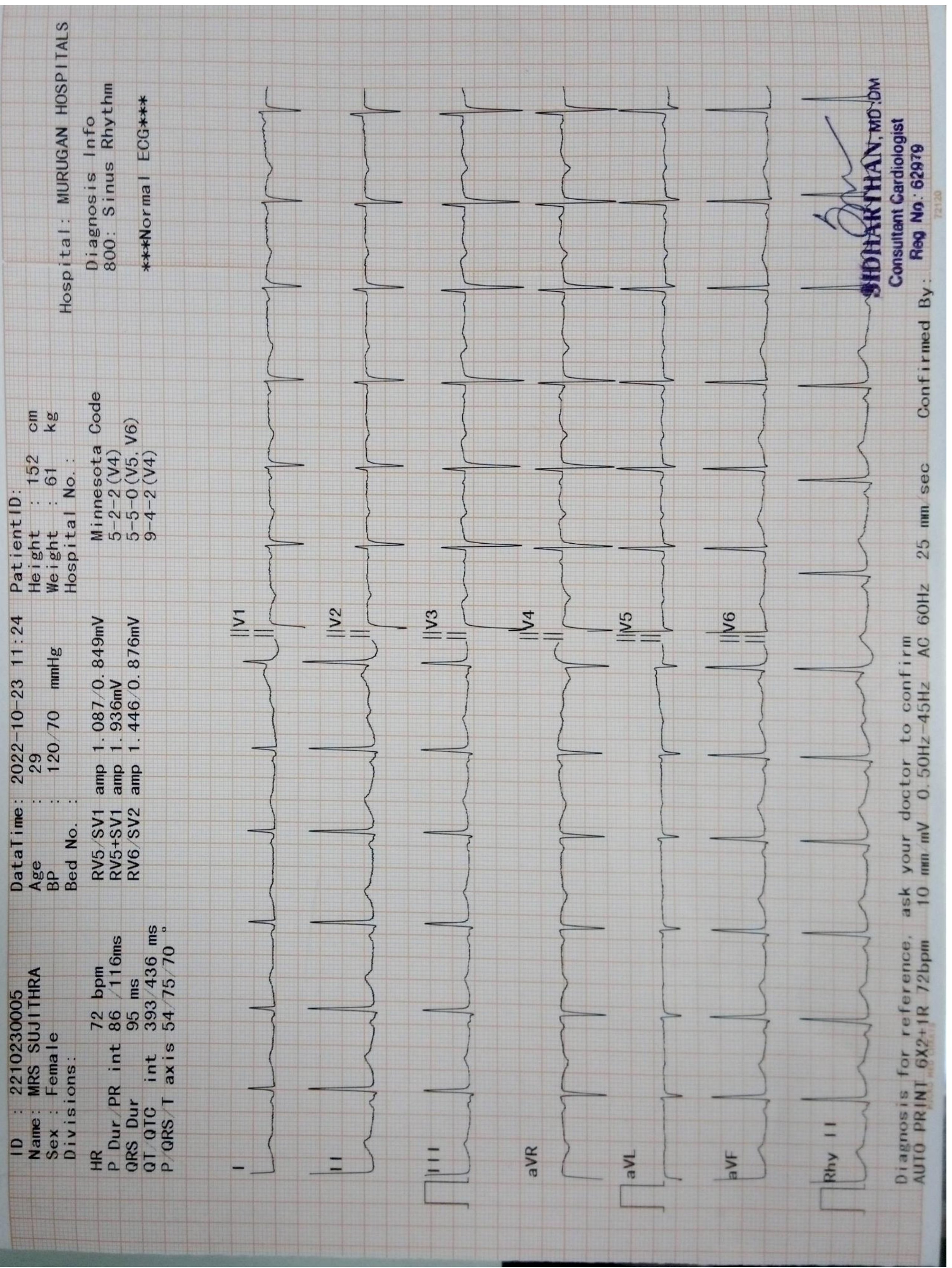
Cyst	Not Present	Absent
Ova	Not Present	Absent
Trophozoites	Not Present	
Red Blood Cells	Not Present	/hpf Absent
Pus Cells	3 - 4	/hpf 0-5
Epithelial Cells	Not Present	/hpf 0-4
OTHER	Not present	

-- End of Report --

Dr Sarangan A MD Pathology
Dr Sarangan A MD Pathology
Consultant Pathology
Reg. No. 84981

Healing Hearts and Lives

264/125, Kilpauk Garden Road, Kilpauk, Chennai - 600 010.
Phone : +91 44 4644 8989 / 75500 53335 | Email : muruganhosp@gmail.com
Website : www.muruganhospitals.in



Diagnosis for reference, ask your doctor to confirm
 AUTO PRINT 6X2+1R 72bpm 10 mm mV 0.50Hz-45Hz AC 60Hz 25 mm/sec Confirmed By: **SIDHARTHAN, MD:DM** Consultant Cardiologist Reg No: 62979



MURUGAN HOSPITALS

HEALING HANDS



ECHO CARDIOGRAM REPORT

NAME : MRS.SUJITHA.V PATIENT ID : MH20220040985
 AGE/SEX : 29 Years / FEMALE IP / OP NO : OP21033306
 CONSULTANT : DR.ARUN PRAKASH DATE : 23/10/2022

2D PLAX (mm)

RV - 24 mm
 AO - 26 mm
 LA - 21 mm

M-Mode (mm)

IVS - 06 mm
 PW - 08 mm
 LVD - 41 mm
 LVS - 23 mm
 EF - 74 %
 FS - 43 %

COLOR DOPPLER

Normal

DOPPLER (m/sec)

MITRAL E - 0.4 m/s
 MITRAL A - 0.5 m/s
 PULMONARY - 0.9 m/s
 AORTIC - 1.2 m/s
 TRICUSPID - 0.3 m/s

IMPRESSION:

No RWMA
 Normal LV Systolic function
 Grade I left ventricular diastolic dysfunction
 Normal RV function
 No pulmonary hypertension
 No pericardial effusion
 No clot/ Vegetation.


 DR.SIDHARTHAN M.D.D.M.,
 CONSULTANT CARDIOLOGIST

Healing Hearts and Lives

264/125, Kilpauk Garden Road, Kilpauk, Chennai - 600 010.
 Phone : +91 44 4644 8989 / 75500 53335 | Email : muruganhosp@gmail.com
 Website : www.muruganhospitals.in



MURUGAN HOSPITALS

HEALING HANDS



SCAN REPORT

NAME	:MRS.SUJITHA.V	PATIENT ID	:MH20220040985
AGE/SEX	:29 Years /FEMALE	IP / OP NO	:OP21033306
CONSULTANT	:DR.ARUN PRAKASH	DATE	:23/10/2022

ULTRA SOUND SCAN OF ABDOMEN

LIVER: Normal in size and measures- 14.7 cm and **increased in** echotexture. No focal lesions are seen. No dilatation of intra-hepatic biliary radicals present. Hepatic veins and IVC appear normal. Portal vein is normal in caliber. Common bile duct is normal in caliber.

GALL BLADDER: Normal in size and wall thickness. No evidence of any calculus or mass present. No evidence of pericholecystic collections.

PANCREAS: Normal in size and echotexture. No focal lesions are seen. No evidence of calculi or calcifications. No evidence of pancreatic duct dilation.

PARA AORTIC AREAS: Aorta and IVC appear normal. No evidence of para aortic lymphadenopathy.

SPLEEN: Normal in size and measures-8.9 cm. Normal in echotexture. No evidence of focal lesions.

RIGHT KIDNEY: Measures 9.7 x 3.9 cm and is normal in size and echotexture. Cortico medullary differentiation is well maintained. There is no hydronephrosis or mass.

LEFT KIDNEY: Measures 10.9 x 4.2 cm and is normal in size and echotexture. Cortico medullary differentiation is well maintained. There is no calculus or hydronephrosis or mass.

Healing Hearts and Lives

264/125, Kilpauk Garden Road, Kilpauk, Chennai - 600 010. Phone : +91 44 4644 8989 / 75500 53335
Email : muruganhosp@gmail.com | Website : www.muruganhospitals.in

URINARY BLADDER: Normal in size, contour and wall thickness. There is no evidence of calculus or mass. No vesical diverticulum present.

UTERUS AND OVARIES : Normal in size and measures- 7.2 x 3.5 cm echotexture. ET- 5.9 mm.

Right ovary measures- 2.7 x 1.6 cm.

Left ovary measures- 2.8 x 1.6 cm.

Both ovaries appears normal.

No ascites present. No retroperitoneal lymphadenopathy present.

IMPRESSION:

- ***Fatty liver grade I***
- ***No significant abnormality detected in the visualized abdominal organs.***



DR. SAKTHI, M.D.,

CONSULTANT RADIOLOGIST,



MURUGAN HOSPITALS
HEALING HANDS

NAME : MR.SUJITHA
AGE /GENDER:29YRS/ FEMALE
CONSULTANT: DR.ARUNPRAKASH

UHID : MH20220040985
IP/OP : OP
DATE : 23.10.2022

X-RAY CHEST (PA VIEW)

- The cardio thoracic ratio is normal
- The heart size and configuration are within normal limits
- The aortic arch is normal
- The lung fields show normal broncho- Vascular markings
- Both the pulmonary hila are normal in size
- The costophrenic and cardiophrenic recesses and the domes of diaphragm are normal
- The bones and soft tissues of the chest wall show no abnormality

IMPRESSION:

Normal Study



264/125, Kilpauk Garden Road, Kilpauk, Chennai - 600 010.

☎ : +91 44 4644 8989 / 75500 53335 email : muruganhosp@gmail.com

Website : www.muruganhospitals.in



MURUGAN HOSPITALS
HEALING HANDS

NAME: MRS. SUJITHA
AGE / SEX : 29 Y/FEMALE
CONSULTANT: DR. ARUN PRAKASH

UHID : MH20220040985
OP/IP : OP
DATE : 23.10.2022

ENT

Bilateral Ear :

Normal; no obvious reduction in conduction of sound or any other pathology.

Bilateral Nose :

No nasal deviation / septal defect.

Throat :

Clear and malampati class I.

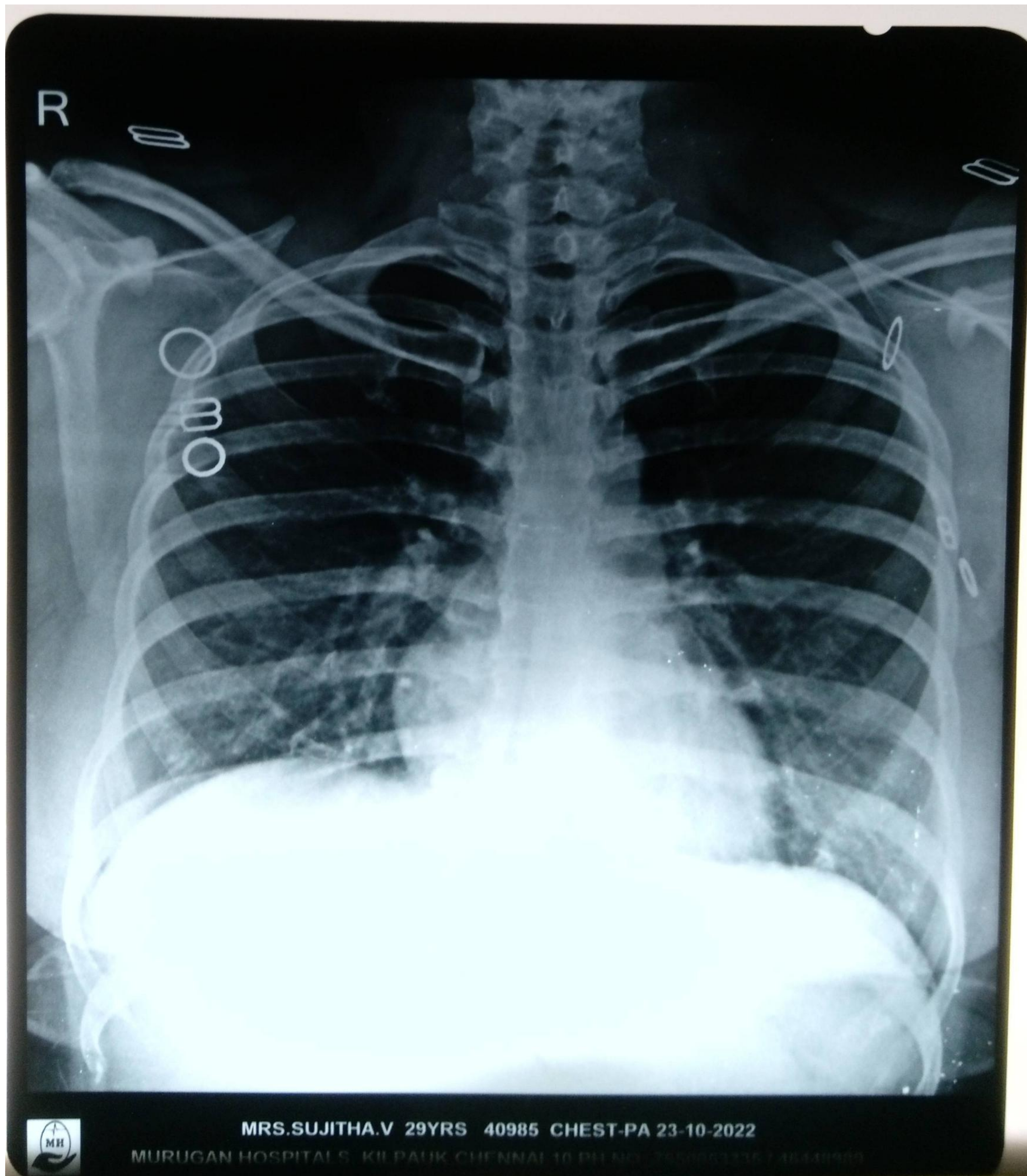


CONSULTANT ENT

264/125, Kilpauk Garden Road, Kilpauk, Chennai - 600 010.

☎ : +91 44 4644 8989 / 75500 53335 email : muruganhosp@gmail.com

Website : www.muruganhospitals.in



Scanned by TapScanner