



PARKLINE DIAGNOSTICS PVT. LTD.

L.G. 3, 4 & 5, Bhuvana Towers, S.D. Road, Secunderabad - 500 003.
Tel : +91 40-2784 5852, 6649 1787, 7995421787, 7093445852, Fax : +91 40 2784 7864
Email parklinediagnostics@gmail.com www.parklinediagnostics.com



NABL Accredited
Certificate No.MC-2566

MEDICAL EXAMINATION REPORT

Name	Mr. G.V. prasanna kumar		Date :	13/11/2021	
Company	Olo: Mediwheel		Reg. No. :	1495236	
Contact No.	8142203000		Sex	<input checked="" type="checkbox"/> M	Age : <input type="checkbox"/> 30
Type	Pre-Emp		Emp. No.:	spouse	
	Overseas		Height	170 cms	
	Annual	<input checked="" type="checkbox"/>	Weight	72 kgs	
Remarks	Hypertniglyceridemia, Advice follow up. - Lab & physical parameters within (N) limits.				
Fitness Status	Medically Fit / Unfit		Physician's Signature DR. PRIYANKA SANNIDHI MBBS		

Regn. No : 11351

COMPREHENSIVE MEDICAL EXAMINATION REPORT

NAME Mr. G.V. Prasanna Kumar

AGE 30 yrs

MARITAL STATUS Married CHILDREN: M F

IDENTIFICATION (IF ANY) A scab on chest

PAST HISTORY

Any family H/o : High Blood Pressure, Heart Disease, Tuberculosis, Diabetes, Asthma, Cancer

Any personal H/o Major illness like : Typhoid.....No.....Jaundice.....No.....Etc.

Any H/o STD.....No.....Skin infection.....No.....

H/o Blood Transfusion.....No.....Recent Vaccination.....COVAXIN 2 Doses ✓

H/o Epilepsy.....No.....Giddiness.....No.....

H/o Surgery.....No.....Fracture in the past.....No.....

Any Personal H/O.

High Blood Pressure, Heart Disease Tuberculosis, Diabetes, Asthma, Cancer

Drug Abuse, Drug Allergy, Micturition, Bowels, Alcohol, Smoking, Sleep, MC, Wt. Loss/Wt. Gain

Present illness / Medication _____

GENERAL EXAMINATION

Conjunctiva :

Skin :

Ears :

Nose :

Throat & Oral Cavity :

Bone, Joints : No

Nutritional Status : Healthy

Lymph Nodes : No

Edema Feet : No

Varicose Veins : No

CANDIDATE'S DECLARATION

I hereby solemnly declare that I am not suffering from Asthma, Hypertension, Diabetes, Occult Psychological disorders or any other ailment which can be suppressed without my voluntary declaration.

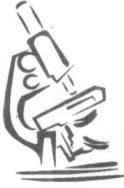Date :



Signature

Place :

Note : General Physical Examination and Investigation included in the health check-up Have certain limitations and may not be able to detect all latent and asymptomatic diseases. Any new symptoms developing after the health check-up or persisting thereafter should be brought to the attention of the treating physician.



PARKLINE DIAGNOSTICS PVT. LTD.

L.G. 3, 4 & 5, Bhuvana Towers, S.D. Road, Secunderabad - 500 003. Tel : +91 40-2784 5852, 6649 1787, 7995421787, 7093445852, Fax : +91 40 2784 7864 Email parklinediagnostics@gmail.com www.parklinediagnostics.com



NABL Accredited
Certificate No.MC-2566

ENT CONSULTATION

S.No. 1495230

Emp.No.

Date 13/11/2021

Name MR. Prasanna Kumar
~~DR. Praveen A.~~

Age 30 Yrs

Sex M/F

EARS :

Right

Left

EAC : patent, no Cerumen.

- do.

TM : Intact, pearly white.

- do.

TFT : Cone of light (+)
Dinne's +ve

Dinne's eve.

Weber's - Centralist

NOSE

: Septum: (N), Bil. T's & meatus: (N), Polyps: (N), non tender

THROAT

: Oropharynx: (N), Bil. v.c's & (N) moving

NECK

: (N) Anteriorly bil.

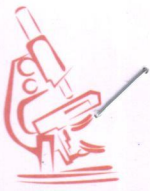IMPRESSION:

ENT clinically NAD

Dr. D. Hari Krishna Reddy
MS (ENT)

Head & Neck Surgeon

Reg. No: 88379



PARKLINE DIAGNOSTICS PVT. LTD.

L.G. 3, 4 & 5, Bhuvana Towers, Sarojini Devi Road, Secunderabad - 500 003 Tel. +91 40-2784 5852
6649 1787 Fax :+91 40 2784 7864 Email : parklinediagnostics@gmail.com www.parklinediagnostics.com



NABL Accredited
Certificate No. MC-2566

TEST REPORT

Name : **Mr . G V PRASANNA KUMAR [SPOUSE]**
Age / Gender : 30 Years / Male
Ref.By : Medi Wheel
Req. No : BIL1495236

TID : UMR0584339
Registered on : 13-Nov-2021 10:29 AM
Reported On : 13-Nov-2021 01:51 PM

DEPARTMENT OF ULTRASOUND Ultrasound Whole Abdomen

LIVER : Normal in size and echotexture. No focal lesions.
No IHBD /CBD dilatation. Portal vein is normal.

SPLEEN: Normal in size and echotexture. No focal lesion seen.

GALL BLADDER: Well distended. No sludge / gall stones / sol.
Gall bladder - Wall thickness is normal.
No pericholecystic oedema.

PANCREAS : Normal in size and echotexture.No calcification / sol.
Pancreatic duct is normal. No peripancreatic fluid collection.


RIGHT KIDNEY : 10.74 x 4.94 cms.
*Normal in size and echotexture.
Cortical thickness is normal.
No evidence of calculi / sol.
Pelvi calyceal system is normal.

LEFT KIDNEY : 10.82 x 4.97 cms.
Normal in size and echotexture.
Cortical thickness is normal.
No evidence of calculi / sol.
Pelvi calyceal system is normal.

URINARY BLADDER : Well distended.Normal in contour.
Wall thickness is normal. No calculus / sol.

PROSTATE : Normal in size and echotexture.
No calcification / sol.
No pre or para aortic adenopathy / ascites noted.

IMPRESSION : No significant sonographic abnormality detected.
Clinical correlation


Dr. PRAJAKTA SUKHADEVI
DNB RADIOLOGY
Reg. No. 68493

The Test marked with*are not accredited by NABL

Lab Timings (Weekdays) : 7.00 am to 8.30 pm
Sundays & Holidays : 7.00 am to 1.00 pm

Radiologists Timings (Weekdays) : 7.30 am to 1.30 pm
& 5.30 pm to 7.45 pm
Sundays & Holidays : 7.30 am to 9.30 am



PARKLINE DIAGNOSTICS PVT. LTD.

L.G. 3, 4 & 5, Bhuvana Towers, Sarojini Devi Road, Secunderabad - 500 003 Tel. +91 40-2784 5852
6649 1787 Fax : +91 40 2784 7864 Email : parklinediagnostics@gmail.com www.parklinediagnostics.com



NABL Accredited
Certificate No. MC-2566

TEST REPORT

Name : Mr . G V PRASANNA KUMAR [SPOUSE]
Age / Gender : 30 Years / Male
Ref.By : Medi Wheel
Req. No : BIL1495236

TID : UMR0584339
Registered on : 13-Nov-2021 10:29 AM
Reported On : 13-Nov-2021 12:21 PM

DEPARTMENT OF X-RAY X-Ray Chest PA View

Lung fields are clear.

Cardia is normal.


Hila are normal.

C P angles are free.

Bony cage is normal.

Soft tissues are normal.

IMPRESSION : NORMAL CHEST XRAY.


Dr. PRAJAKTA SUKHADEVE
DNB RADIOLOGY
Reg. No. 68493

The Test marked with*are not accredited by NABL

Lab Timings (Weekdays) : 7.00 am to 8.30 pm

Sundays & Holidays : 7.00 am to 1.00 pm

Radiologists Timings (Weekdays) : 7.30 am to 1.30 pm
& 5.30 pm to 7.45 pm

Sundays & Holidays : 7.30 am to 9.30 am

ID: 1495236

13-11-2021 11:04:12 AM

BPL-12

MR.G.V.PRASANNA KUMAR

Male 30Years

HR : 67 bpm
P : 115 ms
PR : 160 ms
QRS : 85 ms
QT/QTc : 379/402 ms
P/QRS/T : 17/12/16 °
RV5/SV1 : 1.609/0.611 mV

hmm

ll

Dr. M. SUDHIR

MBBS, MD, DNB(Med), DNB(Gen), FICP
PHYSICIAN & GASTROENTEROLOGIST
Regd No. 9270
3-4-2001, Sivasundaram Street,
Secunderabad - 500 003.

Diagnosis Information:
Sinus Rhythm
Normal ECG

Report Confirmed by:

PATIENT SUMMARY REPORT

PARKLINE DIAGNOSTICS PVT.LTD

ID : 1495236
NAME : MR G.V.PRASANNA KUMAR
AGE / SEX : 30 / MALE

HEIGHT (cm) : 170
WEIGHT (kg) : 72
PROTOCOL : BRUCE

REF. BY : MEDIWHEEL
DONE BY : DR.PANDURANGA
TECHNICIAN : G.M.SURESH

CASE HISTORY :

MEDICATION :

OBJECT OF TEST : Routine Check Up.

RISK FACTOR : None.

ACTIVITY : Very Active.

OTHER INVESTIGATION : ECG

REASON FOR TERMINATION : THR ACHIEVED

EXERCISE TOLERANCE : Good (> 10 METS).

EXERCISE INDUCED ARRHYTHMIAS : No.

HAEMO RESPONSE : Normal.

CHRONO RESPONSE : Normal.

FINAL IMPRESSION :

EXTRA COMMENTS :

*This negative for
Producible
Ischemia*

DR PANDURANGA
MD., DM
Consultant Interventional Cardiologist
Reg No TSMC/FMR/09054

Confirmed By : _____

Signature