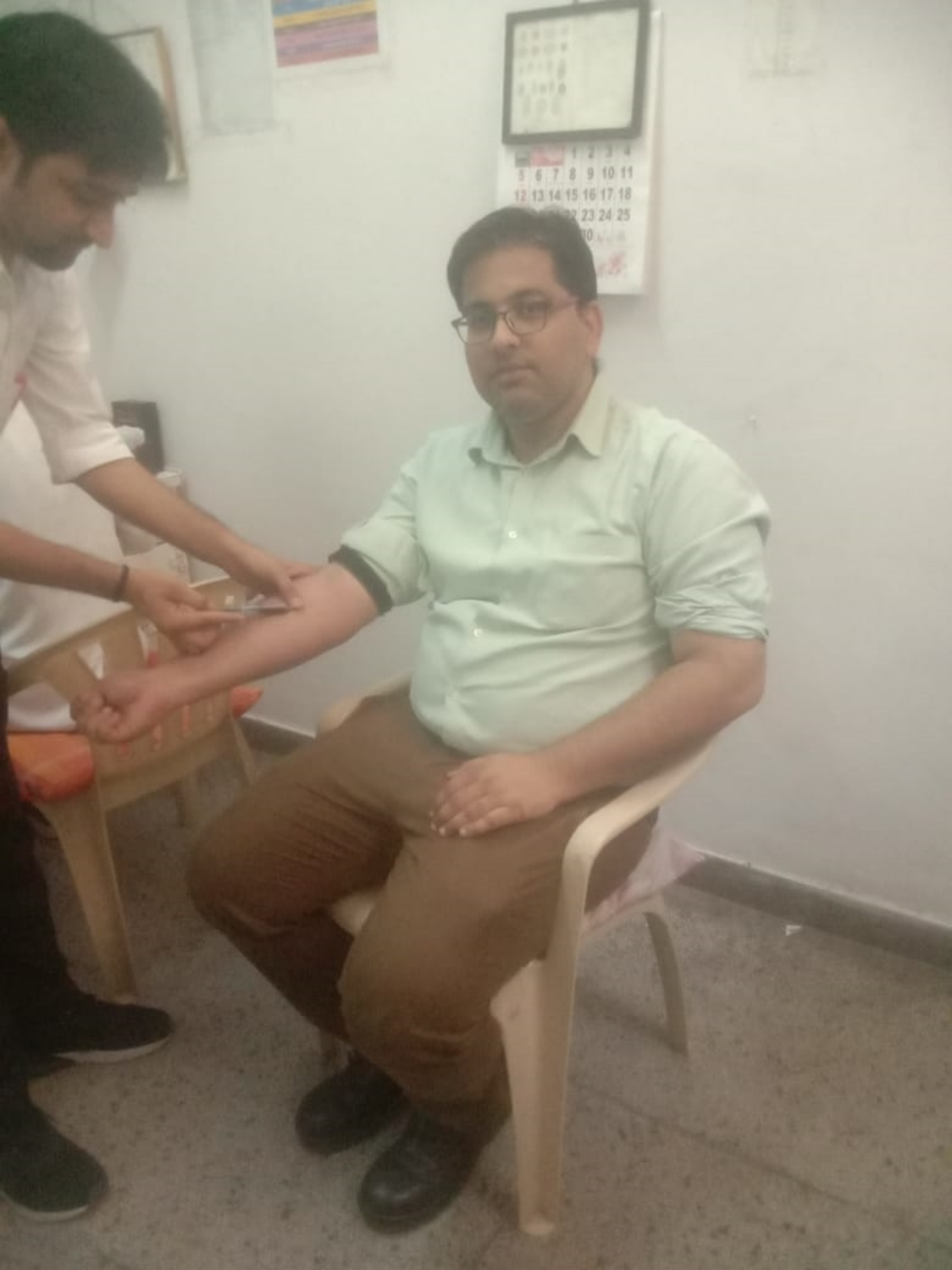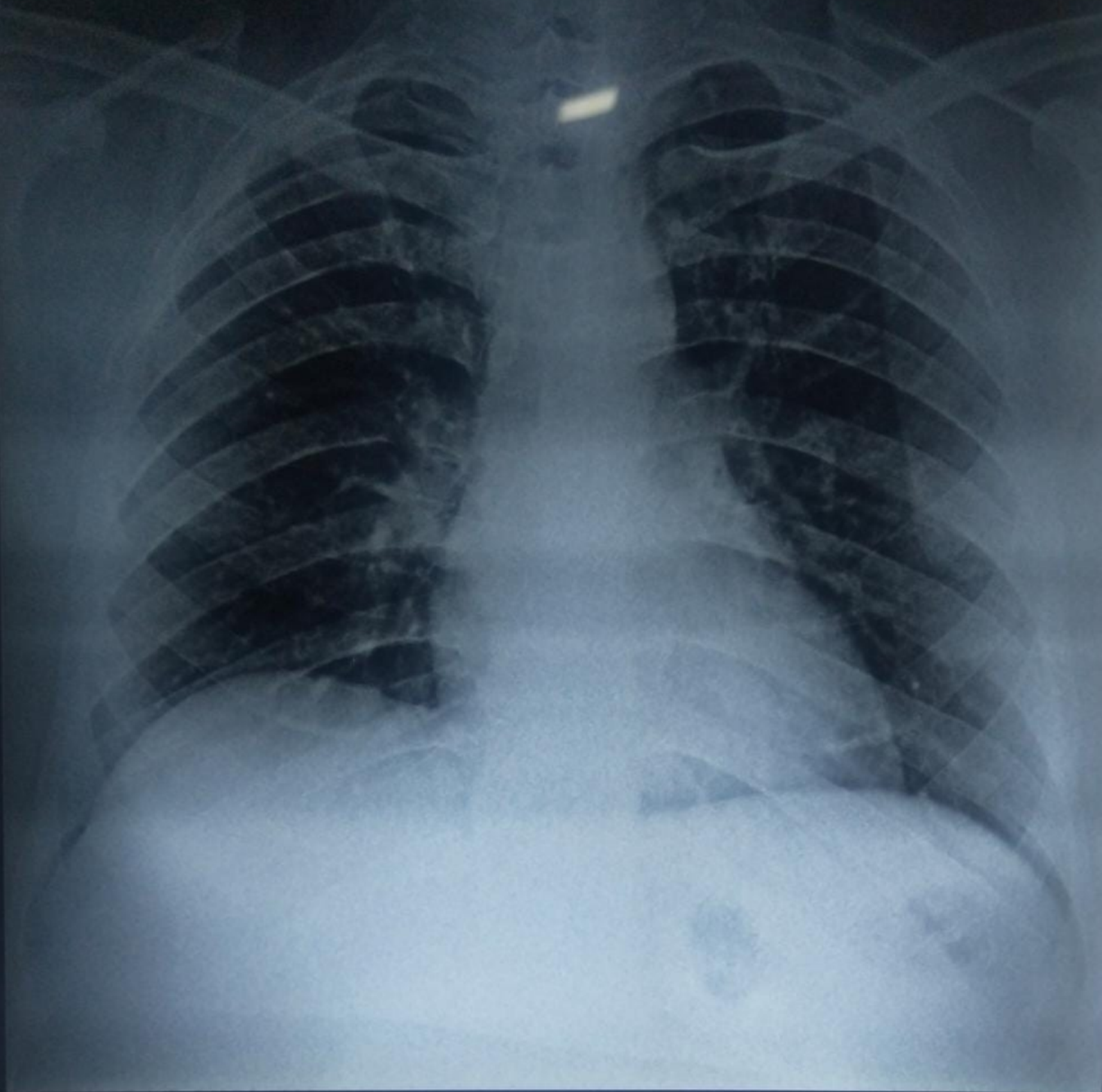




Right



DINKAR YADAV 35Y BY DR M.N.THAREJA 5220.21.4 M CHEST, PA 9/25/2021
THAREJA NURSING HOME. COMPANY BAGH ROAD, ALWAR

भारत सरकार
GOVERNMENT OF INDIA

डिंकर यादव
Dinkar Yadav
जन्म तिथि/DOB: 17/09/1986
पुलक / MALE

8244 1581 7705

मेरा आधाar, मेरी पहचान

Copy

भारतीय विशिष्ट पहचान प्राधिकरण
INDIAN IDENTIFICATION AUTHORITY (I/A)

पता: Address:

S/O पावन राम यादव,
ए-१४१, अजीब विहार,
कर्मचारी कॉलोनी, अलवर,
राजस्थान - 301001

S/O Paawan Ram Yadav, A-141,
Ajib Vihar, Karamchari Colony,
Alwar, Rajasthan - 301001

8244 1581 7705

MERA AADHAAR, MERI PEHACHAN

Thareja

THAREJA NURSING HOME
COMPANY BAGH ROAD, ALWAR
PH. 0144-2700184, 2331842



THAREJA NURSING HOME



DIGITAL X-RAY, OPG, COMPUTERISED ECG & EEG, DIAGNOSTIC LABORATORY EQUIPED WITH COMPUTERISED AUTO ANALYZER & CBC

1, Ram Kuteer, Company Bagh Road, ALWAR - 301001 (Raj.) Ph: 0144-2700184, 2331842

PROPOSAL NO. 21S167886100004438S
Patient Name MR DINKAR YADAV
Ref. By Dr. M. N. THAREJA

Date 25/09/2021
Age 35 Yrs.
Sex M

Details of packages		Patients report	Units	Normal value	
DLC	HB	13.2	gm%	M-13.5-18, F-11.5-16.5	
	TRBC	4.74	million/cu mm	M-4.0-5.5, F-3.9-5.6	
	TWBC	8300	cu mm	4000-11000	
	Polymorphs	60	%	42-75	
	Lymphocytes	37	%	20-50	
	Eosinophil	03	%	1-6	
	ESR	04	mm 1 st Hr.	M-0-9, F-0-20	
	Platelets	233000	Lack / cu mm	1.5-4	
	PCV	36.7	%	37-54	
	MCV	77.4	Cubicmicrons	86-98	
	MCH	27.8	Picograms	26-34	
	MCHC	36.0	%	32-36	
	Blood Grouping & Rh Factor		"A" Rh+(POSITIVE)		
		BUN	15.0	mg %	M-7-20
	S. Creatinine	0.98	Mg/100ml	0.9-1.4 mg /100 ml	
	HBsAg	-			
	HIV I & II	-	Elisa Method		
	HbA1C	-	%	4-6%	
	VDRL	-			

Details of packages		Patients report	Units	Normal value	
LFT	GGTP	25.0	U/L	5-60	
	SGOT	26.11	Units / ml	Upto 40	
	SGPT	29.20	Units / ml	Upto 40	
	S. Bilirubin	Total Bilirubin	0.97	mg%	Upto 1.2
		Direct Bilirubin	0.21	mg%	0-0.25
		Indirec Bilirubin	0.67	mg%	
		T. Protein	7.2	Gm%	6.2-8.3
		S. Albumin	4.1	Gm%	3.2-5.3
		Globulin	3.1	Gm%	
		Alkaline phosphate	117.0	IU/L	60 170
	S. Calcium	-	Gm%	8.5-10.5	
	Uric Acid	4.2	Mg%	2.5-7 mg%	
	Blood Sugar Fasting	81.0	Mg%	60-110 mg %	
	Blood Sugar PP	130.0	Mg%	Upto 160	
Lipid Profile	S. Cholesterol	190.0	mg%	120-220	
	S. Triglycerides	122.0	mg/ml	Upto 170	
	HDL Cholesterol	58.0	IU/L		
	LDL cholesterol	24.4	IU/L	450 at 37° C	
	VLDL	107.6	mg %	Upto 35	

Routine Urine Analysis

Physical/Chemical		Microscopic:	
Appearance	Clear	RBCs	Nil
Specific Gravity	1010	WBCs	1-2/HPF
pH	ACIDIC	Epith. Cells	1-2/HPF
Albumin	Nil	Casts	Nil
Glucose F	NIL	Crystals	Nil
Ketones	----	Bacteria	Nil
Blood	Nil	Glucose P.P.	NIL

Signature of Technician

THAREJA NURSING HOME
COMPANY BAGH ROAD, ALWAR
PH. 0144-2700184, 2331842

Signature of Doctor

This Report is not Valid for Medical Legal Purpose



THAREJA NURSING HOME

1, Ram Kuteer Company Bagh Road, ALWAR - 301001 (Raj.)
Mob. 9982111801, Ph. 0144-2700184, 2331842, Telefax: 0144-2342339
E-mail: drmnthareja@yahoo.com



Name Mr. Dinkar Yadav Age..... Yr OPD/UHID..... Date 19/21
Address..... Mobile No.....

VITALS	B.P.	Pulse	Temp.	Wt.	Ht.	Allergies
--------	------	-------	-------	-----	-----	-----------

Complaints

Routine dental checkup.

Findings

oral hygiene status Good.

Investigation

Treatment

Adv Regular dental checkup

DR. M.N. THAREJA
7233 (RMC)
Family Physician

DR. SAVITA THAREJA
7600 (RMC)
Infertility Specialist

DR. JAYANT THAREJA
A-0824 (RSDS)
Ex. Sr AIIMS

DR. SHIVANI THAREJA
10807 / 31220 (RMC)
Ophthalmologist




DR. PRERNA THAREJA
A-3574
MDS (Endodontics)
Ex. Sr AIIMS

DR. H.R. GUPTA
1744 (RMC)
Sr. Surgeon, MS. Gen.

DR. VARUN SAPRA
Reg. No. 70990
DNB, Ortho

Dr. Prerna Thareja
MDS (Endodontics)
Diploma in Oral Implantology
Diploma in Hospital Administration
Ex Senior Resident AIIMS, Jodhpur
Life Member GCI A-3574

Pain Scale



Patient Name:

Doktor Yanbar

HR 98/min

Px 39

SINUS RHYTHM
NORMAL ECG

UNCONFIRMED REPORT

Guravani Thangaraj

Age: 35 Yr M / S

Weight: 65 kg

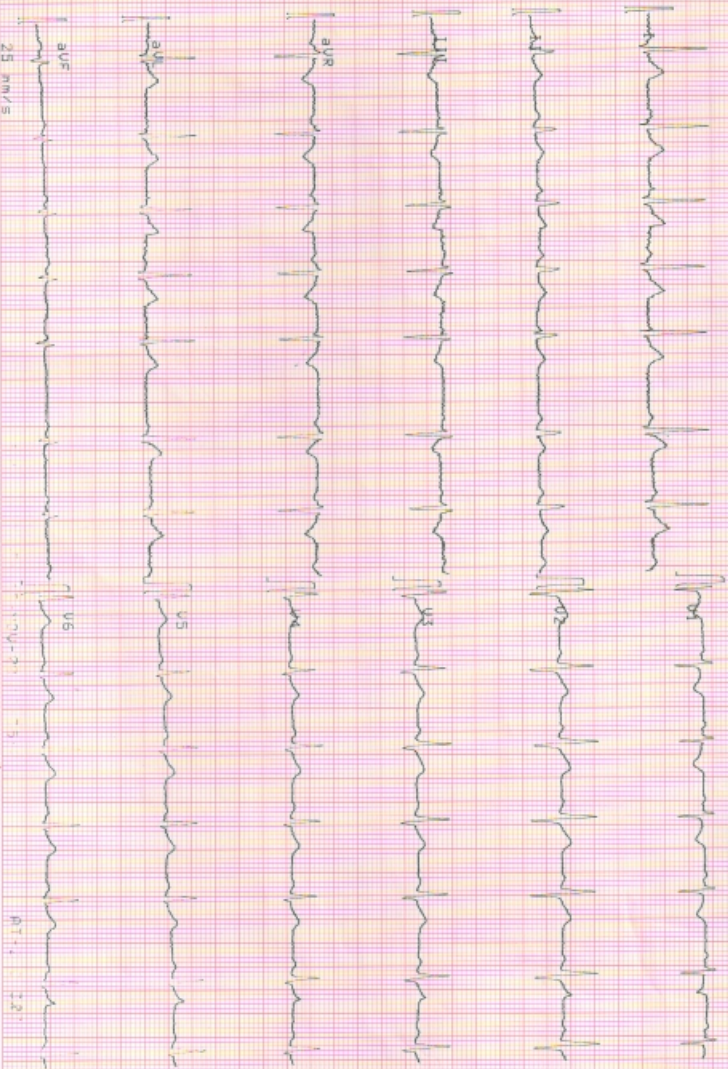
Height: 170 cm

25/9/81

Interval	RR 620 ms	P-R-T	39	7	3
P	106 ms	P (1)	0.09 mV		
PR	130 ms	S (U)	-0.68 mV		
QRS	86 ms	R (U)	0.77 mV		
QT	329 ms	Sectn.	1.44 mV		
QTc	405 ms				

10 mmV

25/9
10 mmV



SCHILLER

Part No. 2.157077M (C) 0123

588



GUPTA ENT AND HEART CENTRE

Dayanand Marg, Nanqli Circle, Alwar (Raj.) Ph. 0144-3591336 | M. 7378184427

Echocardiography Report

Name : Mr. Dhinkar Yadav Refd by: Dr. M.N. Thareja
Age / Sex : 35yrs./male Weight: 114kg Date : 25 September 2021

Clinical Diagnosis : For Cardiac Evaluation
2D Echocardiography Findings :
Mitral Valve : Normal
Aortic Valve : Normal
Tricuspid Valve : Normal
Pulmonary Valve : Normal
Left Atrium : 4.1cm: Mildly dilated
Left Ventricle : Normal LV size with normal LV systolic function. No RWMA

LVIDd	4.7cm.	IVSd	1.1cm.	EF	60%	Visual
LVIDs	2.4cm.	PWd	1.0cm.	EF	%	F.S.

Right Atrium : Normal
Right Ventricle : Normal
Aorta : 3.0cm: Normal
Pulmonary Artery : Normal
Pulmonary Veins : Normal
Superior Venacava : Normal
Inferior Venacava : Normal
Pericardium : Normal
Intracardiac Masses : No Intracardiac masses seen
IAS/IVS : Intact

Doppler Findings:

Valve	Peak Velocity (cm/s)	Peak Gradient (mmHg)	Mean Gradient (mmHg)	Regurgitation Grade	others/comments
Mitral Valve	E-/A-97/70			Trace MR	
Aortic Valve	102				
Tricuspid Valve				Trace TR, No PAH.	
Pulmonary Valve	82				

Diagnosis : Transthoracic echo done in supine position at resting heart rate of 110bpm, shows **POOR ACOUSTIC WINDOW**
Normal LV size with normal LV systolic function. LVEF~60% (Visual).
No RWMA.
Mildly dilated LA, other cardiac chambers are normal in Size.
Trace MR, Trace TR, No PAH.
Normal MIP.
No pericardial effusion /Vegetation /Clot Intracardiac masses seen.
Normal left sided arch of aorta, No Coarctation.

Dr. Prachi Gupta
MBBS, PGDCC
(Non-invasive cardiologist)

Prachi Gupta

Please correlate clinically

THAREJA NURSING HOME
COMPANY BAGH ROAD, ALWAR
PH. 0144-3770184, 23

This report is not valid for medico legal purpose.



THAREJA NURSING HOME

1, Ram Kuteer Company Bagh Road, ALWAR - 301001 (Raj.)
Mob. 9982111801, Ph. 0144-2700184, 2331842, Telefax: 0144-2342339
E-mail: drmnthareja@yahoo.com



Name Mr. Dinkar Yadav Age 35 yrs / M Date 25/9/21
Address Mobile No.....
OPD/UHID.....

VITALS	B.P.	Pulse	Temp.	Wt.	Ht.	Allergies
--------	------	-------	-------	-----	-----	-----------

Complaints

Routine eye checkup

DR. M.N. THAREJA
7233 (RMC)
Family Physician

Findings

VA - 6/6 = glasses
6/6 = glasses
Investigation
3/L
Cornea clear B/E

DR. SAVITA THAREJA
7600 (RMC)
Infertility Specialist

DR. JAYANT THAREJA
A-0824 (RSDS)
Ex. Sr AIIMS

Color vision WNC
WNC

DR. SHIVANI THAREJA
10807 / 31220 (RMC)
Ophthalmologist

Treatment

Adv
Continue glasses

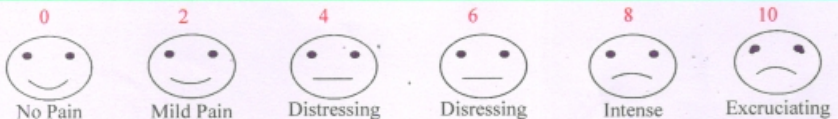
DR. PRERNA THAREJA
A-3574
MDS (Endodontics)
Ex. Sr AIIMS

DR. H.R. GUPTA
1744 (RMC)
Sr. Surgeon, MS. Gen.

DR. VARUN SAPRA
Reg. No. 70990
DNB, Ortho

Dr. Shivani Thareja
M.S. (OPHTHAL)
Fellow (CORNEA)
C.V. Prasad Eye Institute
CORNEA CONSULTANT

Pain Scale





THAREJA NURSING HOME



DIGITAL X-RAY, OPG, COMPUTERISED ECG & EEG, DIAGNOSTIC
LABORATORY EQUIPED WITH COMPUTERISED AUTO ANALYZER & CBC

1, Ram Kuteer, Company Bagh Road, ALWAR - 301001 (Raj.) Ph: 0144-2700184, 2331842

Name : **DINKAR YADAV**

age **35**

Sex : **MALE**

Ref. By : **DR M.N. THAREJA**

Lab No. : **4438S**

Date : **September 25, 2021**

HORMONES & MARKERS

<u>Test</u>	<u>Value</u>	<u>Units</u>	<u>Biological Ref. Values</u>
T3 (Total Triiodothyronine)	1.21	ng/dL	0.60-1.81 ng/dL Adults
T4 (Total Thyroxine)	3.95	µg/dL	3.2-12.60 µg/dL : Adults
TSH (Thyroid Stimulating Hormone)	0.62	µIU/mL	Adults : 0.35-5.50 µIU/mL

Interpretation of TSH :-

Children

0 Days	: 1.0-39.0 uIU/mL
6 days	: 1.7-9.1 uIU/mL
1 year	: 0.4-8.6 uIU/mL
2 years	: 0.4-7.6 uIU/mL
3 years	: 0.3-6.7 uIU/mL
4-19 years	: 0.4-6.2 uIU/mL

Interpretation of TSH :-

Children

3.20 - 34.6 µIU/mL	1 - 2 Days
0.70 - 15.4 µIU/mL	3 - 4 Days
0.70 - 9.10 µIU/mL	15 Days - 5 Months
0.70 - 6.40 µIU/mL	5 Months - 20 Years

Adults

20-54 years	: 0.35-5.50 uIU/mL
55-87 years	: 0.5-8.9 uIU/mL

Pregnancy

1st Trimester	: 0.30 - 4.50 µIU/mL
2nd Trimester	: 0.50 - 4.60 µIU/mL
3rd Trimester	: 0.80 - 5.20 µIU/mL

Pregnancy

0.30 - 4.50 µIU/mL	1st Trimester
0.50 - 4.60 µIU/mL	2nd Trimester
0.80 - 5.20 µIU/mL	3rd Trimester

Method : **Fluorescence Immunoassay Technology**

Sample Type : **Fresh Blood Serum**

Remarks :

Primary malfunction of the Thyroid gland may result in excessive (hyper) or Low (hypo) release of T3 or T4. In addition, as TSH directly affect thyroid function, malfunction of the pituitary or the hypothalamus influences the thyroid gland activity.

Disease in any portion of the thyroid-pituitary-hypothalamus system may influence the level of T3 and T4 in the blood, in Primary Hypothyroidism,

TSH levels are significantly elevated, while in secondary and tertiary hypothyroidism, TSH levels may be low. In addition, in Euthyroid sick syndrome, multiple alterations in serum thyroid function test findings have been recognized.

Signature of Technician

THAREJA NURSING HOME
COMPANY BAGH ROAD, ALWAR
Signature of Doctor *Ravi Thareja*

This Report is not Valid for Medical Legal Purpose 0184, 2331842



MEHAR'S

SAHARA DIAGNOSTICS

Reg. No. NHM/434

Dr. R.D. Arora

M.D., D.M.R.E (Radio-dagnosis)
University Topper
R.M.C. Reg. No. 28052 & 009456
Mob.: 9829136035

The Healing Ashram, 12 Kailash Colony, Bhagat Singh Circle, Alwar

25 SEP 2021

NAME :DNKAR YADAV
Clinician: Dr THAREJA HOSP
FOR : ABDOMEN

c/o pain abdomen [indication/ reason for scan]

Patient information :Technically poor quality scans because of obesity and thick abd wall
+hypersthenia

On real time B-mode sonography

Liver is enlarged in size and echo pattern enhanced, no SOL is seen. Hepatic and portal veins are normal. CBD is normal in caliber, no obstruction is seen.

Gall Bladder is normal in size and shape, no calculus or inflammation is seen.

Pancreas is normal in size and echopattern, no SOL is seen.

Spleen is normal in size and echopattern, no SOL is seen.

Kidneys, bilaterally are normal in size and shape, no calculus or dilated calyces are seen.

Right iliac region appendix could not be traced at present

No evidence of ascites, free Pleural effusion or lymphadenopathy is seen.

Urinary Bladder is normal in size, wall is normal in thickness ,no calculus or growth is seen.

Prostate normal

IMPRESSION:

Fatty liver gr 2

Further evaluation is suggested.

Patient information :Kindly note no luminal pathology can be detected in non distended urinary tract.

Dr Ram das arora

Ultrasound scan is an investigation and therefore has technical limitations as well as inaccuracies inherent in the laboratory and statistical analysis of biological process. It should always be viewed in this perspective. Further this is a routine general scan grossly containing information sought by ref consultant and report generated thus, is for his perusal only. Considering pace of advances in the field of sonography, more specified information can also be obtained by prior intimation.

Thareja

THAREJA NURSING HOME
COMPANY BAGH ROAD, ALWAR
PH. 0144-2760184, 2331842

- Consultant of Radiology works
- Working hours 10 a.m. to 4 p.m. On Call Basis



“ भूख लिंग परीक्षण करवाना जघन्य अपराध है तथा इसकी शिकायत 104 टोल फ्री सेवा पर की जा सकती है।

“ बेटी बचाओ - बेटी पढ़ाओ ”



THAREJA NURSING HOME



DIGITAL X-RAY, OPG, COMPUTERISED ECG & EEG, DIAGNOSTIC
LABORATORY EQUIPED WITH COMPUTERISED AUTO ANALYZER & CBC

1, Ram Kuteer, Company Bagh Road, ALWAR - 301001 (Raj.) Ph: 0144-2700184, 2331842

PROPOSAL NO.	2151678861000044385	Date	25/09/2021
Patient Name	MR.DINKAR YADAV	Age	35 Yrs.
Ref. By Dr.	M. N. THAREJA	Sex	M

PART - X-RAYED : X-RAY CHEST PA VIEW
REPORT : X-RAY CHEST P.A. VIEW
:- Chest is bilaterally symmetrical.
:- C.P. Angles are clear.

CONCLUSION: Normal Study

Signature of Technician

Shivani Thareja
Signature of Doctor

This Report is not Valid for Medical Legal Purpose

THAREJA NURSING HOME
COMPANY BAGH ROAD, ALWAR
PH. 0144-2700184, 2331842