

HEALTH CHECKUP REPORT

Patient Name: BINDU PATEL

DATE: 23/07/2022

Age/Gender: 44/F

Reg. No: 376706

Package: MEDIWHEEL

COMPLAINTS (IF ANY):

- headache on change in weather

HISTORY OF HEALTH STATUS: No

PRESENT MEDICATIONS:

- Tab. Vitamin
- Tab. calcium

HYPERSENSITIVITY TO ANY DRUG: No

PERSONAL HISTORY:

- | | | | | | |
|---------------|---|----------|-----------------------------|---|-----|
| - Bowel | : | Regular | Diet | : | Veg |
| - Micturition | : | Normal | Habits | : | No |
| - Sleep | : | Adequate | Physical Activity/Exercise: | : | no |
| - Appetite | : | Adequate | | | |

HISTORY OF ILLNESS (WITH PAST MEDICATIONS):

- LMP :- HYSTOCORMY

FAMILY HISTORY: NAD

VITAL SIGNS:

- | | | | |
|------------|----------|---------|------------|
| - Height : | 171.7cms | Pulse : | 89/min. |
| - Weight : | 71.7 Kgs | B.P: | 117/74mmHg |

PHYSICIAN CONSULTATION:

1) Clinical Impression

- Reports within normal limit

2) Recommendations

- Healthy life style

(Dr. Rashmi Chovatia)

OPHTHALMO CONSULTATION:

Best corrected visual acuity

RE

LE

6/6

6/6

DENTAL CONSULTATION:

iv:

Cleaning

(Dr. Parvin Chandarana)

GYNEC CONSULTATION:

M/H: PMP- REGULAR

LMP: menopausal 2015

S/H: - AML - lap HYST X 2015

G P2 L2 A - FTND, FTLSCS

H/O: TL

M/H: Any other surgeries -

E: P/A - Soft

P/S - Cx. NAD

P/V - UT, RV, NS, FMR, Fx. Clear

Adv: USG Pelvis/TVS

Mammography

Pap Smear

} Follow up with reports

(Dr. Devang patel)

Please take regular medicine as prescribed by the Doctor. (If given)

FOR OFFICE USE ONLY

FOR OFFICE USE ONLY

Patient ID 314473
 Patient Name Mrs. BINDU PATEL
 Gender/Age Female/43
 Ref Doctor

Dt : 23/07/2022

Rx

| | Drug Name | Generic Name | | Morning | Afternoon | Evening | Night | Duration |
|------|-------------------------------|-------------------|-----------|---------|-----------|---------|-------|------------|
| Tab. | SHELCAL | CALCIUM + VITA D3 | (500 mg) | 0 | 1 | 0 | 0 | 3 Month(s) |
| Tab. | CALDISON D3 once in a week | - | (60 k) | - | - | - | - | 3 Month(s) |


Dr. Rashmi Chovatia

| | |
|------------------------------------|---|
| Reg. No : CIMS/A/2022/376706 | VisitNo : HC/210722/6 [HCV] |
| Patient Name : Mrs. BINDU PATEL | Age(Y-M-D)/Sex : 43 Y 7 M 7 D. / Female |
| Referring Doctor : Dr. CIMS DOCTOR | Doctor : |
| Ward/Room : | Bed : |

ORD/210722/1787 Lab No : 2022111866 LSN : 902685 (Whole Blood) Sample Quality : Normal
 Collection Time : 22/07/2022 8:30:48 Arrival : 22/07/2022 9:06:49 Validation Time : 22/07/2022 10:17:24AM

| | Result | Unit | Reference Range |
|--|--------|----------|----------------------|
| CBC With ESR | | | |
| TOTAL COUNT | | | |
| Hemoglobin <i>(SLS Hemoglobin Detection method)</i> | 13.6 | g/dl | 12.5 - 16.0 g/dl |
| Total RBC Count <i>(Hydro Dynamic Focusing Method)</i> | 5.01 | mill/Cmm | 4.2 - 5.4 mill/Cmm |
| MCV <i>(Hydro Dynamic Focusing Method)</i> | 40.5 | % | 37 - 47 % |
| Total WBC Count <i>(Flow Cytometry)</i> | 8090 | /Cmm | 4000 - 10500 /Cmm |
| Platelet Count <i>(Hydro Dynamic Focusing Method)</i> | 372000 | /Cmm | 150000 - 450000 /Cmm |
| DIFFERENTIAL COUNT (by Flow Cytometry) | | | |
| Polymorphs | 66 | % | 40 - 70 % |
| Lymphocytes | 28 | % | 22 - 45 % |
| Eosinophils | 02 | % | 01 - 04 % |
| Monocytes | 04 | % | 01 - 06 % |
| Basophils | 00 | % | 00 - 01 % |
| Immature Granulocytes | 00 | % | 0 - 2 % |
| Smear Study | | | |
| RBCs are Normochromic & Normocytic. Platelets are adequate in number. Malarial Parasites are not seen. No Premature cells are seen. | | | |
| PLASMA INDICES (by Calculated Method) | | | |
| M.C.V | 80.8 | fl | 78 - 100 fl |
| M.C.H | 27.1 | pg | 27 - 31 pg |
| M.C.H.C. | 33.6 | gm/dl | 32 - 36 gm/dl |
| RDW-CV | 12.3 | % | 11.5 - 14.0 % |

ESR (Red Cell Aggregation)



Dr. Shreya Patel
MD(Path)
Consultant Pathologist

Dr. Manisha Shah
MD (Path & Bact)
Consultant Pathologist
Reg. No. : G-15496

Dr. Jitendra Nayak
MD (Path)
Consultant Pathologist
Reg. No. : G-14786

Print By : ankita.rajpud





| | |
|------------------------------------|---|
| Reg. No : CIMS/A/2022/376706 | VisitNo : HC/210722/6 [HCV] |
| Patient Name : Mrs. BINDU PATEL | Age(Y-M-D)/Sex : 43 Y 7 M 7 D. / Female |
| Referring Doctor : Dr. CIMS DOCTOR | Doctor : |
| Ward/Room : | Bed : |

ORD/210722/1787 Lab No : 202211866 LSN :902685 (Whole Blood) Sample Quality : Normal
 Collection Time :22/07/2022 8:30:48 Arrival : 22/07/2022 9:06:49 Validation Time: 22/07/2022 10:17:24AM

After One Hour 20 mm 0 - 12 mm

Blood Group Rh
 ABO
 Rh

"B"
 POSITIVE

*** END OF REPORT ***

FOR PATHOLOGY REPORTS



Dr. Shreya Patel
 MD(Path)
 Consultant Pathologist

Dr. Manisha Shah
 MD (Path & Bact)
 Consultant Pathologist
 Reg. No.: G-15496

Dr. Jitendra Nayak
 MD (Path)
 Consultant Pathologist
 Reg. No. : G-14786

Print By : ankita.rajput





| | |
|------------------------------------|---|
| Reg. No : CIMS/A/2022/376706 | VisitNo : HC/210722/6 [HCV] |
| Patient Name : Mrs. BINDU PATEL | Age(Y-M-D)/Sex : 43 Y 7 M 7 D. / Female |
| Referring Doctor : Dr. CIMS DOCTOR | Doctor : |
| Ward/Room : | Bed : |

ORD/210722/1787 Lab No : 2022111866 LSN : 902685 (Whole Blood) Sample Quality : Normal
 Collection Time : 22/07/2022 8:30:48 Arrival : 22/07/2022 9:06:49 Validation Time : 22/07/2022 2:53:47PM

| | <u>Result</u> | <u>Unit</u> | <u>Reference Range</u> |
|--|---------------|-------------|--|
| HbA1c (Glycosylated Haemoglobin) | | | |
| TEST | | | |
| HbA1c (Glyco Hb) (Immuno Turbidimetric) | 5.40 | % | 4.8-5.9% Normal 5.9-7.0% Good diabetic control 7.0-10.0% Fair diabetic control >10.0% Poor diabetic control |
| Mean Plasma Glucose | 115 | mg/dL | 80 - 140 mg/dL |

FOR PATHOLOGY REPORT

[Signature]

Dr. Kazumi Gondalia
M.D. (Path)
Consultant Pathologist
Reg. No. : G-21729

Dr. Manisha Shah
 MD (Path & Bact)
 Consultant Pathologist
 Reg. No. : G-15496

Dr. Jitendra Nayak
 MD (Path)
 Consultant Pathologist
 Reg. No. : G-14786

Print By : **ankita.rajput**





| | |
|------------------------------------|---|
| Reg. No : CIMS/A/2022/376706 | VisitNo : HC/210722/6 [HCV] |
| Patient Name : Mrs. BINDU PATEL | Age(Y-M-D)/Sex : 43 Y 7 M 7 D. / Female |
| Referring Doctor : Dr. CIMS DOCTOR | Doctor : |
| Ward/Room : | Bed : |

ORD/210722/1787 Lab No : 2022111867 LSN :902685 (SERUM) Sample Quality : Normal
 Collection Time :22/07/2022 8:30:48 Arrival : 22/07/2022 9:06:49 Validation Time: 22/07/2022 2:56:30PM

Liver Function Test

| | <u>Result</u> | <u>Unit</u> | <u>Reference Range</u> |
|--|---------------|-------------|------------------------|
| Alkaline Phosphatase (PNPP,AMP Buffer Method,Colorimetric) | 70 | U/L | 35 - 104 U/L |
| Billirubin | | | |
| Total Billirubin (Diazospecial Iazonium Iron with Blank) | 0.61 | mg/dL | 0.0 - 1.0 mg/dL |
| Direct Billirubin (DIAZO,(Evelyn Malloy) with Blank) | 0.2 | mg/dL | 0.0 - 0.2 mg/dL |
| Indirect Billirubin (Calculated from Total and Direct Billirubin) | 0.41 | mg/dL | 0.0 - 0.8 mg/dL |
| SGPT (ALT) (IFCC without pyridoxal phosphate) | 16.6 | U/L | 0 - 33 U/L |
| SGOT (AST) (IFCC without pyridoxal 5 phosphate) | 19.5 | U/L | 0 - 32 U/L |
| Total Protein | | | |
| Total Proteins (Biuret Method) | 7.12 | gm/dl | 6.4 - 8.3 gm/dl |
| Albumin (Bromocresol Green Colorimetric) | 4.44 | gm/dl | 3.97 - 4.95 gm/dl |
| Globulin | 2.68 | gm/dl | 2.2 - 3.5 gm/dl |
| A/G Ratio | 1.66 | | 0.9 - 2.1 |

FOR PATIENT COPY RECORDS

Dr. Kazumi Gondalia
M.D. (Path)
Consultant Pathologist
Reg. No. : G-21729

Dr. Manisha Shah
MD (Path & Bact)
Consultant Pathologist
Reg. No. : G-15496

Dr. Jitendra Nayak
MD (Path)
Consultant Pathologist
Reg. No. : G-14786

Print By : ankita.rajpout



| | |
|------------------------------------|---|
| Reg. No : CIMS/A/2022/376706 | VisitNo : HC/210722/6 [HCV] |
| Patient Name : Mrs. BINDU PATEL | Age(Y-M-D)/Sex : 43 Y 7 M 7 D. / Female |
| Referring Doctor : Dr. CIMS DOCTOR | Doctor : |
| Ward/Room : | Bed : |

ORD/210722/1787 Lab No : 2022111867 LSN : 902685 (SERUM) Sample Quality : Normal
 Collection Time : 22/07/2022 8:30:48 Arrival : 22/07/2022 9:06:49 Validation Time : 22/07/2022 2:56:29PM

| | Result | Unit | Reference Range |
|---|--------|---------------|------------------------|
| Creatinine (Buffered Jaffe Reaction Kinetic Compensated) | 0.64 | mg/dL | 0.5 - 0.9 mg/dL |
| Estimated GFR | 123.46 | mL/min/1.73m2 | 50 - 102 mL/min/1.73m2 |
| Fasting Glucose (Hexokinase) | 97.5 | mg/dL | 70 - 100 mg/dL |
| Thyroid Function Test | | | |
| TOTAL T3 (T3) * (Electrochemiluminescence Assay) | 1.29 | ng/ml | 0.846 - 2.02 ng/ml |
| TOTAL T4 (T4) * (Electrochemiluminescence Assay) | 8.15 | µgm/dl | 5.13 - 14.06 µgm/dl |
| TSH (Electrochemiluminescence Assay) | 2.15 | µIU/ml | 0.27- 4.20 µIU/ml |
| Uric Acid (Uricase Colorimetric Enzymatic) | 5.15 | mg/dL | 2.4 - 5.7 mg/dL |

*** END OF REPORT ***

FOR PATHOLOGY REFERENCE



Dr. Kazumi Gondalia
M.D. (Path)
Consultant Pathologist
Reg. No. : G-21729

Dr. Manisha Shah
 MD (Path & Bact)
 Consultant Pathologist
 Reg. No. : G-15496

Dr. Jitendra Nayak
 MD (Path)
 Consultant Pathologist
 Reg. No. : G-14786

Print By : ankita.rajut



| | |
|------------------------------------|---|
| Reg. No : CIMS/A/2022/376706 | Visit No : HC/210722/6 [HCV] |
| Patient Name : Mrs. BINDU PATEL | Age(Y-M-D)/Sex : 43 Y 7 M 7 D. / Female |
| Referring Doctor : Dr. CIMS DOCTOR | Doctor : |
| Ward/Room : | Bed : |

ORD/210722/1787 Lab No : 2022111867 LSN : 902685 (SERUM) Sample Quality : Normal
 Collection : 22/07/2022 8:30:48AM Arrival: 22/07/2022 9:07:24 Validation Time 22/07/2022 10:11:02

Lipid Profile (With Direct LDL)

| Type of Sample | Result | Unit | Reference Range |
|--|-----------|-------|--|
| | : Fasting | | |
| Cholesterol <i>(Enzymatic/Colorimetric, Cholesterol Oxidas, Esterase, Peroxidase Gen.2)</i> | : 198.1 | mg/dL | Less than 160 mg/dl Excellent Less than 200 mg/dl Desirable 200-239 mg/dl Borderline High 240 mg/dl & over High |
| Triglyceride <i>(Enzymatic Colorimetric without Glycerol Blank without Serum Blank)</i> | : 157.5 | mg/dL | Less than 150 mg/dl Normal 150 - 199 mg/dl Borderline High 200-499 mg/dl High 500 mg/dl or greater Very High |
| H D L Cholesterol <i>(Direct Mearuse Homogenous Technique Modified Enzymatic Colorimetric Gen. 3)</i> | : 35.4 | mg/dL | Less than 40 mg/dl Low 60 mg/dl or above Excellent |
| L D L Cholesterol (DIRECT) <i>(Homogenous Enzymatic colorimetric Assay)</i> | : 139.3 | mg/dL | Less than 80 mg/dl Excellent Less than 100 mg/dl Optimal 100 - 129 mg/dl Near or above optimal 130 - 159 mg/dl Borderline High 160 - 189 mg/dl High 190 mg/dl & above Very High |
| VLDL Cholesterol <i>(Calculated)</i> | : 31.5 | mg/dL | 15 - 30 mg% |
| Cholesterol/HDL Ratio <i>(Calculated)</i> | : 5.6 | | Normal upto 4.5 |



Dr. Kazumi Gondalia
M.D. (Path)
Consultant Pathologist
Reg. No. : G-21729

Dr. Manisha Shah
 MD (Path & Bact)
 Consultant Pathologist
 Reg. No. : G-15496

Dr. Jitendra Nayak
 MD (Path)
 Print By: **ankita rajput**
 Consultant Pathologist
 Reg. No. : G-14786

Print Date/Time: 22/07/2022 3:39:14PM Page 1 of 2



FOR PATIENTS ONLY

| | |
|------------------------------------|---|
| Reg. No : CIMS/AJ/2022/376706 | VisitNo : HC/210722/6 [HCV] |
| Patient Name : Mrs. BINDU PATEL | Age(Y-M-D)/Sex : 43 Y 7 M 7 D. / Female |
| Referring Doctor : Dr. CIMS DOCTOR | Doctor : |
| Ward/Room : | Bed : |

ORD/210722/1787 Lab No : 2022111867 LSN : 902685 (SERUM) Sample Quality : Normal
Collection : 22/07/2022 8:30:48AM Arrival: 22/07/2022 9:07:24 Validation Time 22/07/2022 10:11:02

LDL/HDL Ratio : 3.94 Less than 3.5
(Calculated)

Remarks :

*** END OF REPORT ***

FOR PATHOLOGY REPORT



**Dr. Kazumi Gondalia
M.D. (Path)
Consultant Pathologist
Reg. No. : G-21729**

Dr. Manisha Shah
MD (Path & Bact)
Consultant Pathologist
Reg. No. : G-15496

Dr. Jitendra Nayak
MD (Path)
Print By: **ankita rajput**
Consultant Pathologist
Reg. No. : G-14786

Print Date/Time: 22/07/2022 3:39:15PM Page 2 of 2



| | |
|------------------------------------|---|
| Reg. No : CIMS/A/2022/376706 | VisitNo : HC/210722/6 [HCV] |
| Patient Name : Mrs. BINDU PATEL | Age(Y-M-D)/Sex : 43 Y 7 M 7 D. / Female |
| Referring Doctor : Dr. CIMS DOCTOR | Doctor : |
| Ward/Room : | Bed : |

ORD/210722/1787 Lab No : 2022111876 LSN : 902685 (Urine) Sample Quality : Normal
 Collection Time : 22/07/2022 9:11:15 Arrival : 22/07/2022 9:11:15 Validation Time: 22/07/2022 9:48:08AM

| | Result | Unit | Reference Range |
|-------------------------------------|-------------|---------|-----------------|
| Urine R & M | | | |
| PHYSICAL EXAMINATION | | | |
| Quantity | 20 cc | | |
| Colour | Pale Yellow | | |
| Transparency | Clear | | |
| Reaction (QDS-10 Strip) | 5.0 | | |
| Sp. Gravity (QDS-10 Strip) | 1.025 | | 1.005 - 1.035 |
| CHEMICAL EXAMINATION | | | |
| U. Albumin (QDS-10 Strip/Manual) | Nil | | |
| U. Glucose (QDS-10 Strip/Manual) | Nil | | |
| U. Acetone (QDS-10 Strip/Manual) | Absent | | |
| BS/BP (QDS-10 Strip/Manual) | Absent | | |
| MICROSCOPIC EXAMINATION | | | |
| Pus Cell | Occasional | /H.P.F. | /H.P.F. |
| Red Blood Cell | Nil | /H.P.F. | /H.P.F. |
| Epithelial Cell | 1-2 | /H.P.F. | /H.P.F. |
| Cast | Not Seen | | |
| Crystals | Not Seen | | |
| Leucocytocyturia | Absent | | |
| Trichomonads | Absent | | |

*** END OF REPORT ***



Dr. Manisha Shah
MD (Path & Bact)
Consultant Pathologist
Reg. No. : G-15496

Dr. Jitendra Nayak
MD (Path)
Consultant Pathologist
Reg. No. : G-14786

Print By : ankita.rajput

Print Date/Time : 22/07/2022 15:00:00





MARENGO ASIA NETWORK HOSPITAL



JCI (USA)



NABH



NABL
Certificate No. MC-3049



www.cims.org



CIMS Hospital

DoB/Sex: 14/12/1978 / Female

Name : Mrs. BINDU PATEL

Reg No : CIMS/A/2022/376706

ECHO Report

Dt : 23/07/2022

Patient Details

Patient ID 314473
Name Mrs. BINDU PATEL
Age 43 Years
Gender Female
Blood Group
Referral Doctor

ECHO Identification Detail

Doctor Incharge Dr. VIPUL KAPOOR
Clinical Status Of Patient
ECHO Code RP
Finding Description

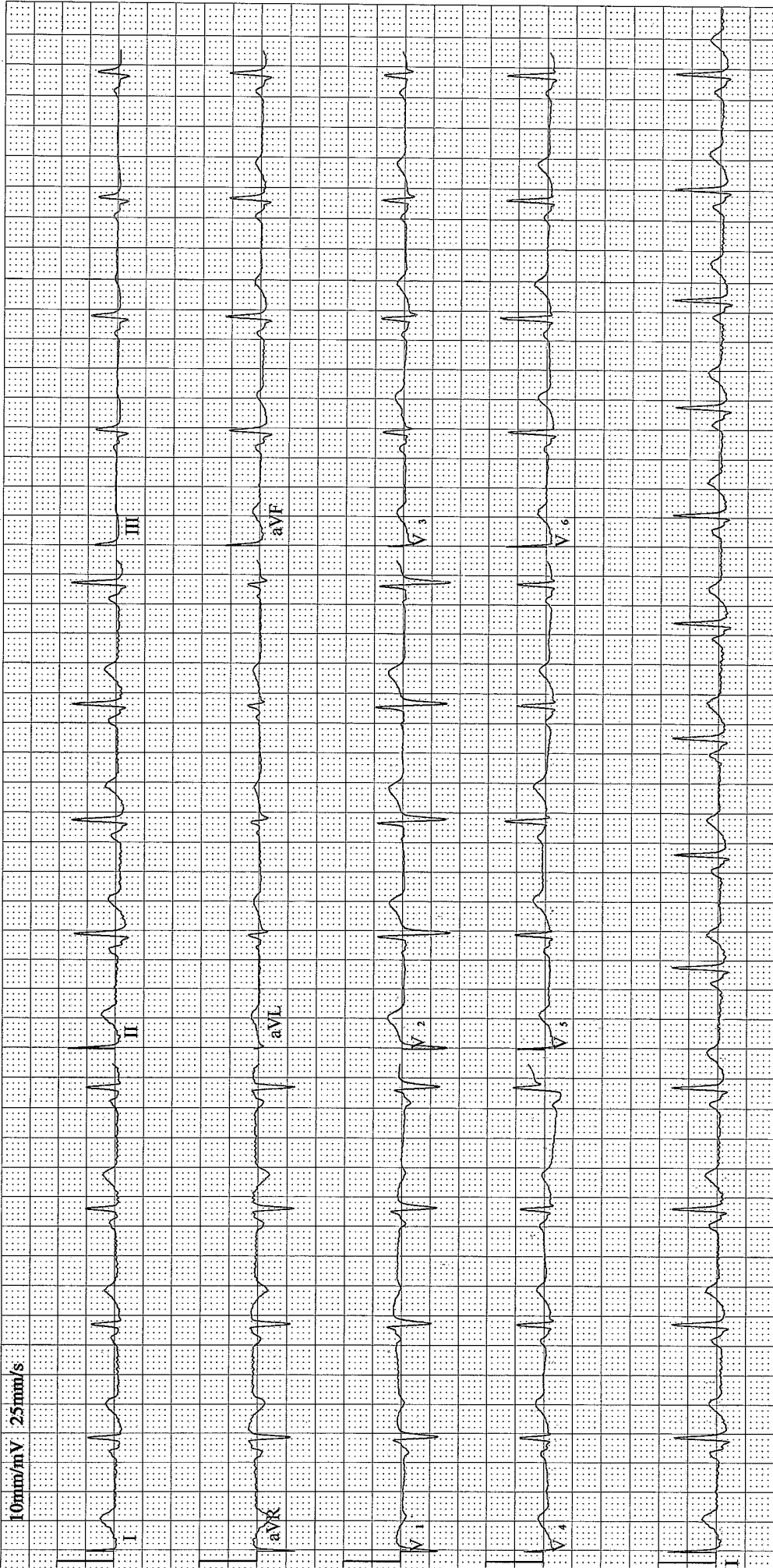
1. Normal sized LA, LV, RA, RV.
2. Normal LV systolic function, LVEF: 60%.
3. No RWMA.
4. Normal LV diastolic function.
5. All cardiac valves are structurally normal.
6. Trivial MR, Trivial TR, Trivial PR, No AR.
7. No PAH, RVSP: 25 mmHg.
8. IAS/IVS: Intact.
9. No clot/vegetation/pericardial effusion.
10. No coarctation of aorta.

Dr. VIPUL KAPOOR

FOR ECHO / TMT REPORTS ONLY

Name : Mrs. BINDU PATEL :

Sex : Female Age : 44 Date : 7-23-2022



| | | | |
|----------------|---------|----------------|--------|
| Frequency : | 1000 Hz | PR Interval : | 98 ms |
| Sample Time : | 17 s | QT Interval : | 363 ms |
| Heart Rate : | 77 bpm | QTc Interval : | 411 ms |
| P Duration : | 83 ms | P Axis : | 45.1° |
| QRS Duration : | 94 ms | QRS Axis : | 51.3° |
| T Duration : | 239 ms | T Axis : | 32.2° |

DOB / Sex : 14/12/1978 / Female

Handwritten Signature

Name : Mrs. BINDU PATEL

Reg No : CIMS/A/2022/376706

Physician Signature:



Patient's Name : BINDU PATEL
Reg. No. (IP/OP): HC-376706
Referred By Dr. : CIMS

Age, Sex : 44Y/F
Date : 23/07/2022

USG OF ABDOMEN & PELVIS

LIVER: Liver is normal in size and echotexture. No evidence of focal SOL or dilatation of IHBR seen. Porta hepatis appear normal.

GALLBLADDER: Gallbladder appeared normal. No calculus or mass lesion seen.

PANCREAS: Visualised pancreas appeared normal in size and echotexture. No focal lesion, mass or pancreatitis.

SPLEEN: Spleen appears normal in size and echotexture.

PARAAORTIC REGION: Aorta grossly appeared normal. No paraaortic lymphnodes seen.

KIDNEYS: Both kidneys appear normal in size, shape and in position. Cortex and collecting system of both kidneys appeared normal. No evidence of calculus or obstructive uropathy on either side. Right kidney: 98x41mm. Left kidney: 97x47mm.

URINARY BLADDER: Bladder appeared normal. No calculus or mass lesion is seen.

Uterus is not seen. (H/O Previous surgery).
No evidence of pelvic mass lesion seen.

No evidence of free fluid or collection is seen in peritoneal spaces.
Normal small bowel peristalsis noted.

COMMENTS:

- No significant abnormality detected.

DR KIRTAN SHAH DR DEEPA SHAH DR UMA MEHTA DR NIMISH SHARMA DR VRUSHTI GANDHI DR RAVINA CHAUHAN
M.D. RADIODIAG. M.D., D.M.R.E D.M.R.D. F.R.C.R D.M.R.D. (D.N.B.) M.D. RADIODIAG. M.D. RADIODIAG.
CONS. RADIOLOGIST CONS. RADIOLOGIST CONS. RADIOLOGIST CONS. RADIOLOGIST CONS. RADIOLOGIST CONS. RADIOLOGIST

Note: This is only a radiological impression and not the final diagnosis. All diagnostic modalities have their own limitations. Therefore radiological modality report should be interpreted in correlation with clinical and pathological findings.

FOR RADIOLOGY REPORTS ONLY

Patient's Name : BINDU PATEL
Reg. No. (IP/OP): HC-376706
Referred By Dr. : CIMS

Age, Sex : 44Y/F
Date : 23/07/2022

Plain Skiagram of Chest PA Standing View:
(Serial No-B-3296)

Rotation +.

Both lung fields appear normal.

No evidence of pleural effusion or pneumothorax is seen on either side.

Mediastinal shadow appears normal.

Heart size and aorta appear normal.

Domes of diaphragm appear normal.

Bones under view appears normal.

Kindly correlate clinically.

DR KIRTAN SHAH M.D. RADIOLOGIST
DR DEEPA SHAH M.D., D.M.R.E CONS. RADIOLOGIST
DR UMA MEHTA D.M.R.D. F.R.C.R CONS. RADIOLOGIST
DR NIMISH SHARMA D.M.R.D. (D.N.B.) CONS. RADIOLOGIST
DR VRUSHTI GANDHI M.D. RADIOLOGIST
DR RAVINA CHAUHAN M.D. RADIOLOGIST
CONS. RADIOLOGIST

Note: This is only a radiological impression and not the final diagnosis. All diagnostic modalities have their own limitations. Therefore radiological modality report should be interpreted in correlation with clinical and pathological findings.

FOR RADIOLOGY REPORTS ONLY

Patient's Name : BINDU PATEL
Reg. No. (IP/OP): HC-376706
Referred By Dr. : CIMS

Age, Sex : 44Y/F
Date : 23/07/2022

BILATERAL MAMMOGRAPHY:

Bilateral mammogram has been obtained using a low radiation dose film screen technique in the craniocaudal and oblique projections. Film markers are in the axillary / lateral portions of both breasts.

Both breasts reveal mixed fatty and fibroglandular parenchyma.

No obvious evidence of focal spiculated mass lesion, retraction of tissues or clusters of micro calcification.

No definite evidence of skin thickening seen.

SONOMAMMOGRAPHY:

- No evidence of any solid or cystic mass lesion in either breast.
- No evidence of axillary lymphadenopathy on either side.

CONCLUSION: No significant abnormality is seen on this study.

BI-RADS Assessment Categories: Category 1: Negative.

DR KIRTAN SHAH DR DEEPA SHAH DR UMA MEHTA DR NIMISH SHARMA DR VRUSHTI GANDHI DR RAVINA CHAUHAN
M.D. RADIODIAG. M.D., D.M.R.E D.M.R.D. F.R.C.R D.M.R.D. (D.N.B.) M.D. RADIODIAG. M.D. RADIODIAG.
CONS. RADIOLOGIST CONS. RADIOLOGIST CONS. RADIOLOGIST CONS. RADIOLOGIST CONS. RADIOLOGIST CONS. RADIOLOGIST

Note: This is only a radiological impression and not the final diagnosis. All diagnostic modalities have their own limitations. Therefore radiological modality report should be interpreted in correlation with clinical and pathological findings.

BI-RADS Assessment Categories: (0=Requires additional evaluation, 1=Negative, 2=Benign findings, 3=Probably benign findings, 4=Suspicious abnormality, 5=Highly suggestive of malignancy)

NOTE: False negative rate of mammography is approximately 10%. Management of a palpable abnormality must be based on clinical grounds. If you detect a lump or any other change in your breast before your next screening mammogram, consult your doctor immediately.

FOR RADIOLOGY REPORTS ONLY