



Swaminarayan Nagar, Off Mumbai-Agra Highway,  
Panchvati, Nashik - 422 003.

QFAHN/BILL/003/V1

+91- 253 - 2510250 / 350 / 450 / 550 / 750

apollonashik@apollohospitals.com

Date



Name

: Mr. ASHISH V SHEWALE (42/M)

Address

: AMRAVALI ROAD NEAR HANUMAN MANDIR SMRUTI NAGAR DATTAWADI  
ADOGAON NAGPUR, NAGPUR, NAGPUR, MAHARASHTRA, INDIA

Examined by:

UHID : MHN1.0000126030

Package

: MediWheel Full Body Health Checkup Male Above 40

AHC No : NSKAH27742



## CHIEF COMPLAINTS

For corporate health checkup  
No specific complaints

## PRESENT KNOWN ILLNESS

### Present known illness

No history of : - Diabetes mellitus, Thyroid disorder, Heart disease, Stroke, Asthma, COPD, Cancer



## DRUG ALLERGY

NO KNOWN ALLERGY

:26/09/2022



## SYSTEMIC REVIEW

### Cardiovascular system

- Nil Significant



## Past medical history

Do you have any allergies? - No  
Do you have any drug allergies? - No  
Past medical history - nil significant  
Covid 19 - No



## Surgical history

Surgical history - Nil

## Immunization history

- Covid Dose1, Covid Dose2



## Personal history

Marital status - Married  
Diet - Mixed Diet

### Alcohol

- consumes alcohol occasionally

### Smoking

- No

### Chews tobacco

- No

### Chews paan

- No

### Physical activity

- Active



## Family history

Father - has expired  
Aged - 61 YRS  
Mother - alive  
Aged - 70 YRS  
Brothers - 2  
Sisters - 1  
Hypertension - mother  
Coronary artery disease - none  
Cancer - None

## PHYSICAL EXAMINATION



### General

General appearance - normal  
Build - normal  
Height - 169  
Weight - 78  
BMI - 27.31  
Pallor - No



Swaminarayan Nagar, Off Mumbai-Agra Highway,  
Panchvati, Nashik - 422 003.

+91- 253 - 2510250 / 350 / 450 / 550 / 750

apollonashik@apollohospitals.com

www.askapollo.com

QFAHN/BILL/003/V1



Date : 24/09/2022

AHC No : NSKAH27742

Name : Mr. ASHISH V SHEWALE (42 /M)

Package : MediWheel Full Body Health Checkup Male Above 40

Oedema - no  
Temperature - 96.7  
SpO2 - 98



**Cardiovascular system**

Heart rate (Per minute) - 83  
Rhythm - Regular  
- B.P. Supine  
Systolic(mm of Hg) - 120  
Diastolic(mm of Hg) - 70  
Heart sounds - S1S2+


**Respiratory system**

Breath sounds - Normal vesicular breath sounds



**Abdomen**

Organomegaly - No  
Tenderness - No





H Swaminarayan Nagar, Off Mumbai-Agra Highway,  
Panchvati, Nashik - 422 003.

+91- 253 - 2510250 / 350 / 450 / 550 / 750

apollonashik@apollonashik.com

www.askapollo.com

QFAHN/BILL/003/V1



Name : Mr. ASHISH V SHEWALE (42 /M)

Package : MediWheel Full Body Health Checkup Male Above 40

Date : 24/09/2022

AHC No : NSKAH27742

### URINE ROUTINE (CUE)

Test Name	Result	Unit	Level	Range
Specific Gravity	1.020		●	1.016-1.026
Color,:	PALE YELLOW			
Transparency:	Clear			
Reaction:	Acidic			7.2-7.8
Protein :	1+			
Sugar:	Absent			
pH	5.5		●	4.6-8
Blood:	Absent			
Ketone	Absent			
Bile Pigments:	Absent			
Bile Salts :	Negative			
Urobilinogen	Normal			
Nitrite	Negative			
RBC	00	/hpf	●	0-2
WBC/Pus Cells	1-2	/hpf		
Tc/Sqc(Transitional/Squamous epithelial cells)	1-2	/hpf		

Lymphocytes	35	%	●	20-45
Eosinophils	01	%	●	1-6
Monocytes	05	%	●	1-10
Basophils	00	%	●	0-1
ERYTHROCYTE SEDIMENTATION RATE (ESR)	1.0	mm/1st hr	●	0-10

### BLOOD GROUPING AND TYPING (ABO and Rh)

Test Name	Result	Unit	Level	Range
ABO Group:	O			
Rh (D) Type:	POSITIVE			

### LIVER FUNCTION TEST (PACKAGE)

Test Name	Result	Unit	Level	Range
ALT(SGPT) - SERUM / PLASMA	30	U/L	●	30-65
ALBUMIN - SERUM	4.4	g/dL	●	3.5-5
GLOBULIN - SERUM: (Calculated)	3.7 *	g/dL	●	1.8-3.6
ALBUMIN:GLOBULIN - SERUM(RATIO) (Calculated)	1.2		●	1.1-1.8
ALKALINE PHOSPHATASE - SERUM/PLASMA	60	U/L	●	0-100
AST (SGOT) - SERUM	26	U/L	●	15-37
BILIRUBIN, TOTAL - SERUM	0.9	mg/dL	●	0.0-1.0

### C B C WITH ESR (AUTOMATION + STANDARD METHOD)

Test Name	Result	Unit	Level	Range
Hemoglobin	15.8	g/dl	●	13.0-18.0
Haematocrit	50.6	%	●	39.0-54.0
RBC COUNT	6.4	Million/ul	●	4.2-6.5
MCV	78.7	fl	●	75.0-95.0
MCH	24.6 *	pg	●	26.0-32.0
MCHC	31.2	g/dl	●	31.0-36.0
RDW	15.7	%	●	11-16
Platelet Count(Optical/Impedance)	262	10 <sup>3</sup> /m <sup>3</sup>	●	140-440
TLC Count	7.1	10 <sup>3</sup> /m <sup>3</sup>	●	4.0-11.0
Neutrophils	59	%	●	45-75

### LIPID PROFILE TEST (PACKAGE)

Test Name	Result	Unit	Level	Range
Total Cholesterol	198	mg/dL	●	0-200

### CREATININE - SERUM / PLASMA

Test Name	Result	Unit	Level	Range
CREATININE - SERUM / PLASMA	1.0	mg/dL	●	0.8-1.3

● Within Normal Range    ● Borderline High/Low    ● Out of Range



Swaminarayan Nagar, Off Mumbai-Agra Highway,  
Panchvati, Nashik - 422 003.

+91- 253 - 2510250 / 350 / 450 / 550 / 750

apollonashik@apollonashik.com

www.askapollo.com

QFAHN/BILL/003/V1



Date: 24/09/2022

AHC No : NSKAH27742

Name : Mr. ASHISH V SHEWALE (42 /M)

Package : MediWheel Full Body Health Checkup Male Above 40

LDL Cholesterol (Direct LDL) 142 mg/dL

**LIVER FUNCTION TEST (PACKAGE)**

Test Name	Result	Unit	Level	Range
GGTP: GAMMA GLUTAMYL TRANSPEPTIDASE - SERUM	38	U/L	●	0-50

**LIVER FUNCTION TEST (PACKAGE)**

Test Name	Result	Unit	Level	Range
PROTEIN, TOTAL - SERUM / PLASMA	8.1	g/dL	●	6.4-8.2

**GLUCOSE - SERUM / PLASMA (FASTING)**

Test Name	Result	Unit	Level	Range
Glucose - Plasma (Fasting)	92	mg/dL	●	70-100
URINE GLUCOSE(FASTING): (Strip Method)	Nil			

**THYROID PROFILE - I(T3,T4 AND TSH)**

Test Name	Result	Unit	Level	Range
TOTAL T3: TRI IODOTHYRONINE - SERUM	201	ng/dL	●	Healthy Adults: 69 - 215
TOTAL T4: THYROXINE - SERUM	10.5	µg/dL	●	Healthy Adults:5.2-12.7

**GLUCOSE - SERUM / PLASMA (POST PRANDIAL)**

Test Name	Result	Unit	Level	Range
Glucose - Plasma (POST PRANDIAL)	137	mg/dL	●	70-140
URINE GLUCOSE(POST PRANDIAL):(Strip Method)	Nil			

**LIPID PROFILE TEST (PACKAGE)**

Test Name	Result	Unit	Level	Range
Triglycerides - Serum	107	mg/dL	●	0-150

**THYROID PROFILE - I(T3,T4 AND TSH)**

Test Name	Result	Unit	Level	Range
TSH: THYROID STIMULATING HORMONE - SERUM	3.1	uIU/mL	●	Euthyroid: 0.3 - 4.5 Hypothyroid: 7.1 - >75

**GLYCOSYLATED HEMOGLOBIN (HbA1C) - WHOLE BLOOD**

Test Name	Result	Unit	Level	Range
Glycosylated Hemoglobin (HbA1c)	6.8 *	%	●	0.0-6.0
Mean Plasma Glucose (MPG) Estimate:	164.7800	mg/dL		

**UREA - SERUM / PLASMA**

Test Name	Result	Unit	Level	Range
UREA - SERUM / PLASMA	16	mg/dL	●	15-38
UREA NITROGEN SERUM/PLASMA: (Calculated)	7	mg/dL	●	7-18

**LIPID PROFILE TEST (PACKAGE)**

Test Name	Result	Unit	Level	Range
HDL CHOLESTEROL - SERUM / PLASMA	49	mg/dL	●	40-60
TOTAL CHOLESTEROL/HDL CHOLESTEROL RATIO(Calculated)	4.0		●	0.0-4.5

**URIC ACID - SERUM**

Test Name	Result	Unit	Level	Range
URIC ACID - SERUM	6.0	mg/dL	●	3.5-7.2

**LIVER FUNCTION TEST (PACKAGE)**

Test Name	Result	Unit	Level	Range
BILIRUBIN CONJUGATED (DIRECT) - SERUM	0.2	mg/dL	●	0.0-0.3

● Within Normal Range    ● Borderline High/Low    ● Out of Range



Swaminarayan Nagar, Off Mumbai-Agra Highway,  
Panchvati, Nashik - 422 003.

+91- 253 - 2510250 / 350 / 450 / 550 / 750

apollonashik@apollohospitals.com

www.askapollo.com

QFAHN/BILL/003/V1



Date : 24/09/2022

AHC No : NSKAH27742

Name : Mr. ASHISH V SHEWALE (42 /M)

Package : MediWheel Full Body Health Checkup Male Above 40

BILIRUBIN UNCONJUGATED - SERUM(Calculated) 0.7, mg/dL ● 0.0-0.7

PROSTATIC SPECIFIC ANTIGEN (PSA TOTAL)

Test Name	Result	Unit	Level	Range
PROSTATIC SPECIFIC ANTIGEN (PSA TOTAL)	0.33	ng/mL	●	0.16-1.7

CARDIAC STRESS TEST - (TMT)

ECG

ULTRASOUND - WHOLE ABDOMEN

Grade I fatty infiltration of liver.

No other significant abnormality is detected.


Suggest : Clinical correlation.

X-RAY CHEST PA

INVESTIGATIONS NOT DONE / NOT YET REPORTED / NOT PART OF PACKAGE(LAB,RADIOLOGY & CARDIOLOGY)

Haematology

STOOL ROUTINE



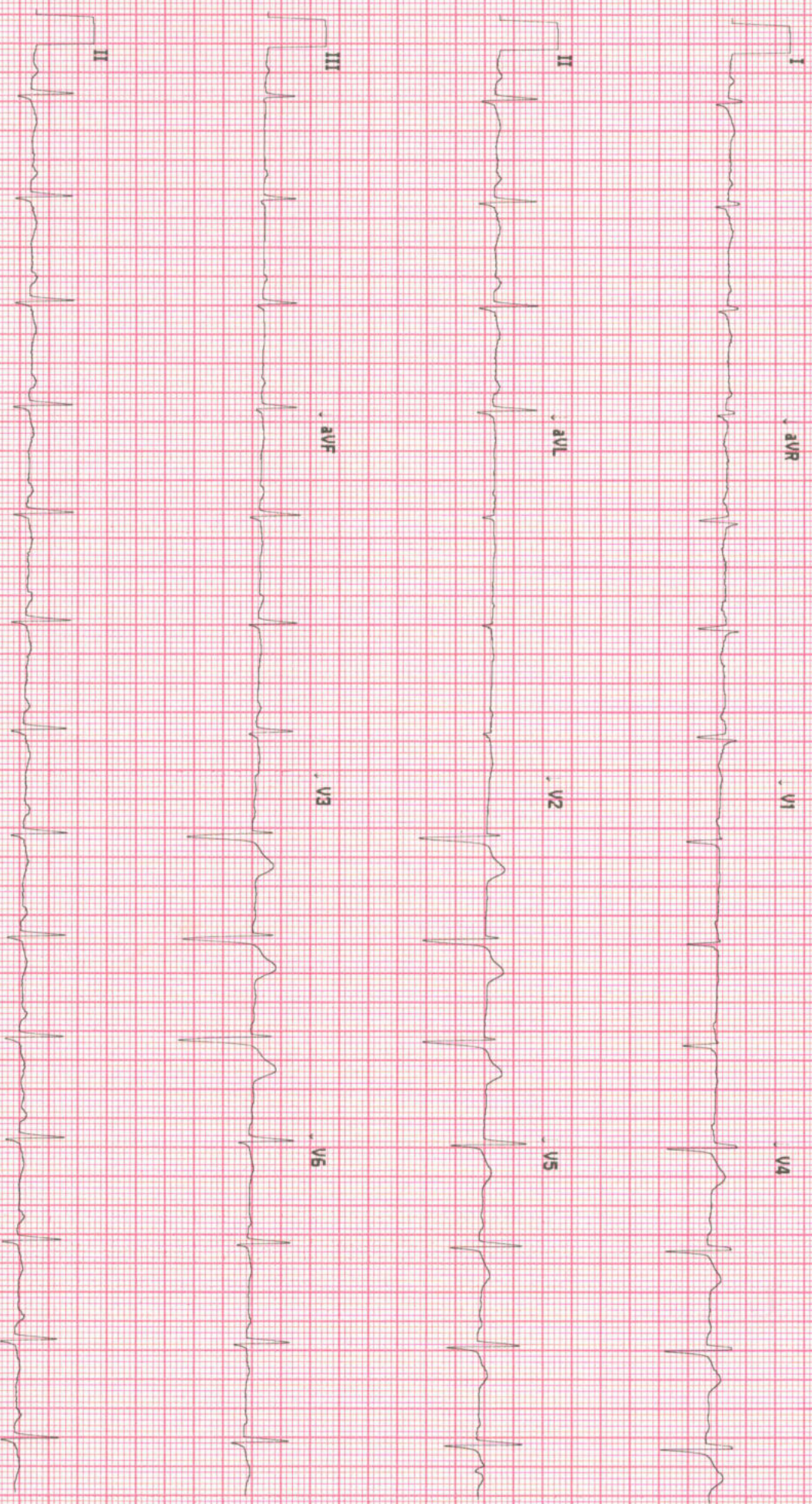
● Within Normal Range    ● Borderline High/Low    ● Out of Range

Shevale, Ashish  
ID:  
DOB:  
42yr, Male

24-Sep-2022 12:46:05

Vent rate: 83 BPM  
PR int: 174 ms  
QRS dur: 84 ms  
QT/QTc: 337/377 ms  
P-R-T axes: 59 90 32

SINUS RHYTHM  
NONSPECIFIC T-WAVE ABNORMALITY  
BORDERLINE ECG  
UNCONFIRMED REPORT



113500188213

No Site Name

Site # 0 Carl #

2 Version 2.0.4.0 Sequence #20298 25mm/c 10mm/mV 0 mS-AN v\*



Swaminarayan Nagar, Off Mumbai-Agra Highway,  
Panchvati, Nashik - 422 003.

+91- 253 - 2510250 / 350 / 450 / 550 / 750

apollonashik@apollohospitals.com


www.askapollo.com

QFAHN/BILL/003/V1



Apollo  
HOSPITALS  
NASHIK

## Radiology

**Patient Details** : Mr. ASHISH V SHEWALE | Male | 42Yr 0Mth 0Days  
**UHID** : MHN1.0000126030 **Patient Location:** AHC  
**Patient Identifier:** NSKAH27742   
**DRN** : 222022070 **Completed on :** 24-SEP-2022 16:52  
**Ref Doctor** : Dr. Rajashri Dhongade

### ULTRASOUND - WHOLE ABDOMEN

**LIVER** : Normal in size and measures 14cm. Diffuse increase in echogenicity of the liver parenchyma is suggestive of fatty infiltration.

A subcentimeter sized area of focal fat sparing is noted anterior to GB fossa. No I.H.B.D./ other focal lesions.

**PORTAL VEIN**: Normal in size.

**GALL BLADDER**: Minimally distended.

**COMMON BILE DUCT**: Normal in size.

**PANCREAS** : Visualized portion of head and body of pancreas appears normal in size and echotexture. Rest of the pancreas is obscured due to bowel gases.

**SPLEEN** : Normal in size (10.2cm) and echotexture.

**KIDNEYS**: Both kidneys are normal in site, size and echotexture.

No evidence of calculi/ hydronephrosis.

Right kidney measures: 11.6 x 5.2 cm.

Left kidney measures : 12.1 x 4.9 cm.

**URINARY BLADDER**: Well distended with normal walls.

No evidence of calculi/ growth/ diverticula .

**PROSTATE** : Normal in size with homogenous echogenicity. No evidence of calcification within.

Prostate measures :18.6gms.

Seminal vesicles are normal.



H Swaminarayan Nagar, Off Mumbai-Agra Highway,  
Panchvati, Nashik - 422 003.

+91- 253 - 2510250 / 350 / 450 / 550 / 750

apollonashik@apollohospitals.com

www.askapollo.com

QFAHN/BILL/003/V1



Mr. ASHISH V SHEWALE

MHN1.0000126030

NSKAH27742

**ULTRASOUND - WHOLE ABDOMEN**

Visualized bowel loops appear grossly normal.

No evidence of any free fluid in the peritoneal cavity.

**Impression**

Grade I fatty infiltration of liver.

No other significant abnormality is detected.

Suggest : Clinical correlation.

--- END OF THE REPORT ---

Dr. Samruddhi Sonawane

Consultant - Radiology








Swaminarayan Nagar, Off Mumbai-Agra Highway,  
Panchvati, Nashik - 422 003.  
+91- 253 - 2510250 / 350 / 450 / 550 / 750  
apollonashik@apollohospitals.com  
www.askapollo.com



### Radiology

**Patient Details :** Mr. ASHISH V SHEWALE | Male | 42Yr 0Mth 0Days  
**UHID :** MHN1.0000126030      **Patient Location:** AHC  
**Patient Identifier:** NSKAH27742        
**DRN :** 122036859      **Completed on :** 24-SEP-2022 10:10  
**Ref Doctor :** Dr. Rajashri Dhongade

### X-RAY CHEST PA

Moderate rotation.

Both lung fields are clear.

Costophrenic angles are clear.

Cardiac size and contour are within normal limits.


Rib cage is normal.

Soft tissues are normal.

Suggest : Clinical correlation and further evaluation.

### Impression

--- END OF THE REPORT ---

  
Dr. Gorakhnath T

CONSULTANT-RADIOLOGY



# OPHTHALMOLOGY



Name : Mr. Ashish chawale Date 24/6/20 UNIT \_\_\_\_\_  
 Occupation : \_\_\_\_\_ Room No. \_\_\_\_\_ Out Patient   
 Age : 41 Sex : Male  Female  S/M/W/D Ref. Physician : \_\_\_\_\_  
 Address : Nashik Copies to : \_\_\_\_\_  
 Tel. No. \_\_\_\_\_

## REPORT ON OPHTHALMIC EXAMINATION

HISTORY : \_\_\_\_\_

PRESENT COMPLAINT : \_\_\_\_\_

PAST HISTORY : DM / HTN / ALLERGY cholesterol borderline

### ON EXAMINATION

RE 6/18p LE 6/60p

VISION :

	RIGHT				LEFT				
	PGP	SPH	CYL	AXIS	VA	SPH	CYL	AXIS	VA
DIST									
NEAR									

AR / Retinoscopy :

	RIGHT			LEFT		
	SPH	CYL	AXIS	SPH	CYL	AXIS
	<u>1.0</u>	<u>0.75</u>	<u>20</u>	<u>5.75</u>	<u>2.25</u>	<u>81</u>

Refraction or Acceptance :


	RIGHT				LEFT			
	SPH	CYL	AXIS	VA	SPH	CYL	AXIS	VA
DIST	<u>1.0</u>	<u>0.75</u>	<u>20</u>	<u>6/6</u>	<u>5.0</u>	<u>2.0</u>	<u>81</u>	<u>6/60</u>
NEAR	<u>+1.0</u>			<u>M</u>	<u>+1.0</u>			<u>M</u>

*Handwritten signature/initials*

Anterior Segment :

RE

LE



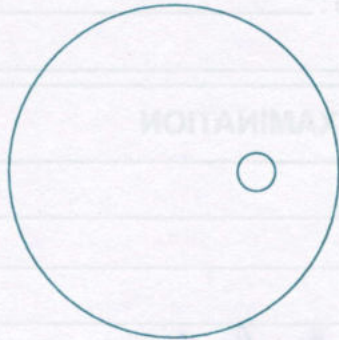① pupil exam  
② IOL exam



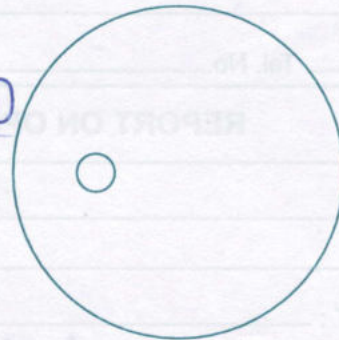
Fundus :

RE

LE



① IOL exam



Diagnosis :

① Myopia = Astigmatism = Presbyopia

Advise / Rx:

• Refresh Tears eye drops ① BID

LEFT			RIGHT		
SPH	CYL	AXIS	SPH	CYL	AXIS

LEFT			RIGHT		
SPH	CYL	AXIS	SPH	CYL	AXIS

CONSULTANT OPHTHALMOLOGIST



H Swaminarayan Nagar, Off Mumbai-Agra Highway,  
Panchvati, Nashik - 422 003.

+91- 253 - 2510250 / 350 / 450 / 550 / 750

apollonashik@apollohospitals.com

www.askapollo.com

QFAHN/BILL/003/V1



Apollo  
HOSPITALS  
NASHIK

24/9/22

Mr. Ashish. Shenale

Dr. Bijendra Patil

41/M.


9096986290.

- No H/O of DM & HTN.

- occlusal Caries present.

- No Plaque

Adv:- Fitting Reg.



*[Handwritten signature]*

ID: 000126030

Visit:

41 years

Asian

Male

BRUCE

Max HR: 148bpm 85% of max predicted 173bpm

Max BP: 120/80

Total Exercise time: 7:08

Maximum workload: 8.7 METS

8.7 METS

25.0 mm/s

10.0 mm/mV

100hz

24-Sep-2022

12:11:32

Referred by:

Test ind:

Reason for Termination:

Comments:

Phase Name	Stage Name	Time in Stage	Speed (mph)	Grade (%)	WorkLoad (METS)	HR (bpm)	BP (mmHg)	RPP (x100)
PRETEST	SUPINE	0:33	**.*	**.*	1.0	81	100/70	81
	STANDING	0:22	**.*	**.*	1.0	83	100/70	83
	HYPERVENT	0:14	0.8	0.0	1.0	84	100/70	84
EXERCISE	STAGE 1	3:00	1.7	10.0	4.6	120	120/80	164
	STAGE 2	3:00	2.5	12.0	7.0	137	120/80	176
	STAGE 3	1:08	3.4	14.0	8.7	147	120/80	176
RECOVERY	Post	3:02	**.*	**.*	1.0	102	120/80	122

TMT Negative for SII