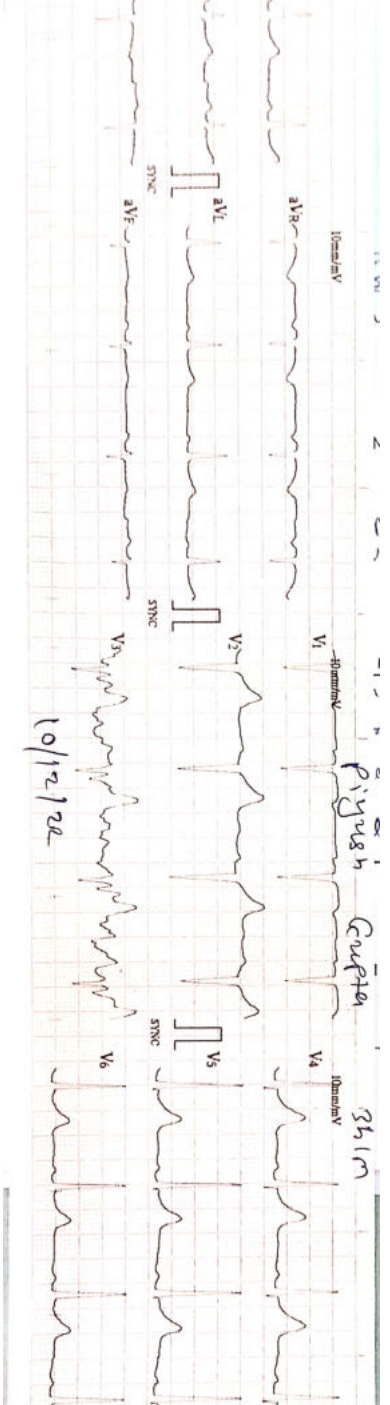

11/06/2011 11:01:00 2011-01-09 23:33
 11/06/2011 11:01:00 2011-01-09 23:33



Piyush Gupta
 3411
 10/12/20

HR : 67 bpm
 R-R : 883 ms
 P-R : 163 ms
 QRS : 97 ms
 QT/QTc : 402/427 ms
 P/QRST : 15/-10/15 mV
 RV5/SV1 : 1.860/1.200 mV
 RV5-SV1 : 3.060 mV

Sinus Rhythm
 Left Axis Deviation
 Dr. V. Vaidya
 Associate Consultant-Cardiology
 Reg. No. G-50910
 Inconframed report Verified by



Heart & General Clinic

Icure Heart & Diet Clinic, 402, Epsilon tower, opp Pasha bhai park, Race course, Vadodara

:: PERSONAL HEALTH REPORT ::

Name:- Piyush Gupta		DATE 10/12/22
		SR. NO.
		SEX. Male
		AGE 34 year
		HEIGHT 172 CM
		WEIGHT 79 kg.

HISTORY

Present History : No
 Past Hlness History : No Diabetes/Hypertension/Tuberculosis/Asthma/Epilepsy
 Past Occupational History :
 Family History : Father - HT & diabetic, mother - HT
 Personal History : No
 Addiction : No Tobacco/Gutkha/Smoking/Alcohol

GENERAL EXAMINATION

T.P.R. : 70/min B.P. : 124/80 mm Hg
 Pallor/Icterus/Cyanosis/Varicosity/Lymph Nodes/Thyroid/Oedema/NVE/Other :

SYSTEMIC EXAMINATION

R.S. : Normal
 C.V.S : Normal
 C.N.S : Normal
 A.S. : Normal
 Musculo-skelet System : Normal

E.N.T. Ex.	Normal	ACUITY OF VISION		RT EYE = 7.5	LT EYE = 3
		Without Glass	DISTANT	6/	6/
Dental Ex.	Normal		Near	6/	6/
		With Glass	DISTANT	6/ 6	6/ 6
Skin Ex.	Normal		Near	6/ 6	6/ 6
		Psychic Ex.	Normal	COLOUR BLINDNESS AAD	

REMARK

ADVICE

The Worker is FIT / UNFIT for the assigned job.



Dr. Krish P. Vaidya
 MD, FC, CC
 Associate Consultant-Cardiology
 Reg. No. G-50510

DR. KRISH VAIDYA

MD G-50510, CIH

भारत सरकार
GOVERNMENT OF INDIA



पियूष गुप्ता
Piyush Gupta
जन्म वर्ष/YoB:1988
पुरुष Male



6241 4715 1152

आधार - आम आदमी का अधिकार





नाम
Name **पियूष गुप्ता**
PIYUSH GUPTA

कार्यकारी क्र. ४
E.C. No. **115434**


आधिकारिक अधिकारी
Issuing Authority




हस्ताक्षर
Signature Holder's







BARODA DIAGNOSTIC LABORATORY

Name : PIYUSH GUPTA
Ref By : ICURE HEART & DIET CLINIC

Age/Sex : 34 Yrs./M
Date : 10/12/2022
Report ID. : 4

EXAMINATION OF URINE

TEST	RESULT	UNIT
Sample	: FASTING	
PHYSICAL EXAMINATION		
Quantity	: 20	mL
Colour	: COLOURLESS	
Transparency	: CLEAR	
Specific Gravity	: 1.003	
Reaction	: ACIDIC	
Deposits	: ABSENT	
CHEMICAL EXAMINATION		
Albumin	: NIL	
Sugar	: NIL	
Acetone	: ABSENT	
Bile Salts	: ABSENT	
Bile Pigments	: ABSENT	
Urobilinogen	: NORMAL : ~ < 1.0 mg/dL	
Occult Blood	: ABSENT	
Nitrate	: ABSENT	
MICROSCOPIC EXAMINATION		
Pus Cells	: 0-1 / hpf	
RBC	: NIL	
Epithelial Cells	: NIL	
Crystals	: NIL	
Amorphous Phosphate	: NIL	
Cusi	: NIL	

END OF REPORT



Dr. Nehal Tiwari
(MD)
Consultant Pathologist
(Reg. No. G-54530)

Dr. Priya Kiplani
(MD)
Consultant Pathologist
(Reg. No. G-46004)

302, Triva Complex, Natubhai Circle, Race Course, Vadodara. ☎ +91 8866009950 / 7405009950 ✉ bdl95950@gmail.com

Laboratory results serve as an aid to diagnosis & should be interpreted in relation to clinical findings. Please refer back to laboratory in case of any discrepancy



BARODA DIAGNOSTIC LABORATORY

Name : PIYUSH GUPTA
Ref By : ICURE HEART & DIET CLINIC

Age/Sex : 34 Yrs./M
Date : 10/12/2022
Report ID. : 4

HAEMOGRAM PROFILE

IESI

RESULT

Blood Group : " B "
Rh Factor : " POSITIVE "
(Anti D.)

BIOCHEMISTRY

FASTING (FBS)

Blood Glucose : 93.0 mg/dL 70 - 110 mg/dL

POST-PRANDIAL

Blood Glucose : 136.0 mg/dL 80 - 140 mg/dL

Done By Fully Auto Analyzer MIURA, A-1004

END OF REPORT



Dr. Nehal Tiwari
(MD)
Consultant Pathologist
(Reg. No. G-54530)



302, Trivya Complex, Natubhai Circle, Race Course, Vadodara. ☎ +91 8866009950 / 7405009950 📧 bdl95950@gmail.com

Laboratory results serve as an aid to diagnosis & should be interpreted in relation to clinical findings. Please refer back to laboratory in case of any discrepancy.





BARODA DIAGNOSTIC LABORATORY

302, Trivia Complex, Natubhai Circle, Race Course, Vadodara. ☎ +91 8866009950 / 7405009950 📧 bdl95950@gmail.com



Patient's name : Piyush Gupta
Age/Sex : 34 Years/Male
Referred by : C/o. I Cure Heart & Diet Clinic
Sample From : LAB
UHID :

Reg. ID : icure-329-19
Accession : 24302
Reg. Date : 10/12/2022
Collection Time : 10/12/2022 13:50

COMPLETE BLOOD COUNT

Sample Type: EDTA

Test Name	Result	Units	Biological Reference Interval
<u>Blood Counts</u>			
Haemoglobin :	15.4	Gms%	13.5 - 18.0
Total R.B.C. :	4.22	mill/c.mm	4.7 - 6.0
Total W. B. C. :	7300	/cu mm	4000 - 10500
Platelet Count :	416000	/cu.mm	1,50,000 - 4,50,000
<u>Differential Count</u>			
Neutrophils :	68	%	40 - 70
Lymphocytes :	30	%	20 - 40
Eosinophils :	00	%	1 - 4
Monocytes :	02	%	2 - 6
Basophils :	0	%	0 - 01
<u>Blood Indices</u>			
P. C. V. :	36.2	%	42 - 52
M. C. V. :	85.8	fl	78 - 100
M.C.H. :	36.5	pg	27 - 31
M. C. H. C. :	42.5	%	32 - 36
R.D.W. :	12.2	%	11.5 - 14.0

E.S.R.(Westergren Method)

After one hour : **8** mm 1 - 7



Page 1 of 6

LAB

LAB USE ONLY (Entered by :AP Enter Date/Time:10/12/2022 14:36:00) (Verify by :OP1 Verify Date/Time:10/12/2022 14:37:00)





BARODA DIAGNOSTIC LABORATORY

302, Trivia Complex, Natubhai Circle, Race Course, Vadodara. ☎ +91 8866009950 / 7405009950 📧 bdl95950@gmail.com



Patient's name : Piyush Gupta
Age/Sex : 34 Years/Male
Referred by : C/o. I Cure Heart & Diet Clinic
Sample From : LAB
UHID :

Reg. ID : icure-329-19
Accession : 24302
Reg. Date : 10/12/2022
Collection Time : 10/12/2022 13:50

HIV HBsAg

<u>Test</u>	<u>Result</u>	<u>Normal Range</u>
Test for HIV 1 Antibodies :	Non reactive	Non reactive
Test for HIV 2 Antibodies :	Non reactive	Non reactive
HBsAg : (Hepatitis B surface Antigen)	Negative	Negative

Note: The above tests are done as a screening procedure.
: If clinically suspected, confirmation by ELISA is recommended.
: Rarely false negativity/positivity may occur.



LAB
LAB USE ONLY (Entered by : AP Enter Date/Time: 10/12/2022 14:36:00) (Verify by : OP1 Verify Date/Time: 10/12/2022 14:38:00)





BARODA DIAGNOSTIC LABORATORY

302, Triva Complex, Natubhai Circle, Race Course, Vadodra. ☎ +91 8866009950 / 7405009950 📧 bdl95950@gmail.com



Patient's name : Piyush Gupta
Age/Sex : 34 Years/Male
Referred by : C/o. I Cure Heart & Diet Clinic
Sample From : LAB
UHID :
Reg. ID : icure-329-19
Accession : 24302
Reg. Date : 10/12/2022
Collection Time : 10/12/2022 13:50

RENAL FUNCTION TEST

Test Name	Result	Units	Biological Reference Interval
Urea :	15	mg/dl	10 - 50
Bun (Calculated) :	7	mg/dl	0 - 18
Creatinine :	0.83	mg/dl	0.4 - 1.5
Uricacid :	5.60	mg/dl	3.4 - 7.0
BUN CREAT RATIO :			10:1 - 20:1

Done on Fully automated biochemistry analyser - COBAS C 111



LAB
LAB USE ONLY (Entered by : AP Enter Date/Time: 10/12/2022 14:36:00) (Verify by : OP1 Verify Date/Time: 10/12/2022 14:38:00)



BARODA DIAGNOSTIC LABORATORY

302, Triva Complex, Natubhai Circle, Race Course, Vadodara. ☎ +91 8866009950 / 7405009950 📧 bdl95950@gmail.com



Patient's name : Piyush Gupta
Age/Sex : 34 Years/Male
Referred by : C/o. I Cure Heart & Diet Clinic
Sample From : LAB
UHID :

Reg. ID : icure-329-19
Accession : 24302
Reg. Date : 10/12/2022
Collection Time : 10/12/2022 13:50

LIPID PROFILE

Sample Type: Serum

Test Name	Result	Units	Biological Reference Interval
Cholesterol :	128	mg/dl	0 - 200
Triglyceride :	116	mg/dL	0 - 150
HDL - Cholesterol :	44	mg/dL	35 - 65
LDL - Cholesterol :	60.8	mg/dL	0 - 130
VLDL - Cholesterol :	23.2	mg/dL	0 - 30
Total Cholesterol/HDL Ratio :	2.91		1 - 6
LDL / HDL Cholesterol Ratio :	1.38		0 - 3.5

Done on Fully automated biochemistry analyser - COBAS C 111



LAB

LAB USE ONLY (Entered by : AP Enter Date/Time : 10/12/2022 14:36:00) (Verify by : OP1 Verify Date/Time : 10/12/2022 14:38:00)





BARODA DIAGNOSTIC LABORATORY

302, Triva Complex, Natubhai Circle, Race Course, Vadodara. ☎ +91 8866009950 / 7405009950 📧 bdi95950@gmail.com



Patient's name : Piyush Gupta
Age/Sex : 34 Years/Male
Referred by : C/o. I Cure Heart & Diet Clinic
Sample From : LAB
UHID :

Reg. ID : lcure-329-19
Accession : 24302
Reg. Date : 10/12/2022
Collection Time : 10/12/2022 13:50

LIVER FUNCTION TEST

Sample Type Serum

Test Name	Result	Units	Biological Reference Interval
S.G.P.T (ALT) :	13	U/L	0 - 40
S.G.O.T (AST) :	15	U/L	0 - 37
ALK.PHOSPHATASE :	50	U/L	40 - 130
G.G.T :	13.6	U/L	8 - 78
<u>Bilirubin</u>			
Total :	0.42	mg/dl	0.2 - 1.0
Direct :	0.27	mg/dl	0 - 0.6
Indirect :	0.15	mg/dl	0 - 0.5
<u>Serum Proteins</u>			
Total Protein :	7.23	gms/dl	6.4 - 8.3
Albumin :	4.16	gms/dl	3.8 - 4.4
Globulins :	3.07	gms/dl	2.3 - 3.5
A/G Ratio :	1.36		0.9 - 2.9

Done on Fully automated biochemistry analyser - COBAS C 111



Page 5 of 6

LAB
LAB USE ONLY (Entered by: AP Enter Date/Time: 10/12/2022 14:36:00) (Verify by: OP1 Verify Date/Time: 10/12/2022 14:39:00)





BARODA DIAGNOSTIC LABORATORY

302, Trivia Complex, Natubhai Circle, Race Course, Vadodara. ☎ +91 8866009950 / 7405009950 📧 bd195950@gmail.com



★ 2 4 3 0 2 ★

Patient's name	: Piyush Gupta	Reg. ID	: icure-329-19
Age/Sex	: 34 Years/Male	Accession	: 24302
Referred by	: C/o. I Cure Heart & Diet Clinic	Reg. Date	: 10/12/2022
Sample From	: LAB	Collection Time	: 10/12/2022 13:50
UHID	:		

HbA1C REPORT

Sample Type: EDTA

Test Name	Result	Units	Biological Reference Interval
HbA1C :	4.92	%	Excellent control: 4.2-6.2 Good Control : 6.3-7.2 Fair Control : 7.3-8.2 Poor Control : >8.3
Mean Blood Glucose levels : of last 03months	95	mg/dl	

NOTE

*As per the new 2009 update of American Diabetes Association regarding HbA1C & Mean Blood Glucose relationship.

This test is used to monitor diabetic patients compliance with the therapeutic regimen and long term blood glucose control. It's level is proportional to both the average blood glucose concentration and the life span of the red blood cells (RBC) in circulation. HbA1c values are free of day to day glucose fluctuations and are unaffected by exercise or recent food intake.



LAB
LAB USE ONLY (Entered by : AP Enter Date/Time:10/12/2022 14:36:00) (Verify by : OP1 Verify Date/Time:10/12/2022 14:39:00)



 **iCure™**
Heart & General Clinic

iCure Heart & Diet Clinic, 402, Epsilon tower, opp Pasha bhai park, Race course, Vadodara



Sunny K. Mochhi
+91 87985 30274
+91 83235 61561
sunny@icureheart.com

NAME	PIYUSH GUPTA	AGE/SEX	34/MALE
REF BY	I CURE HEART & DIET CLINIC	DATE	10-12-22

X-RAY CHEST PA VIEW (PORTABLE)

FINDING

BOTH LUNGS FIELDS ARE NORMAL .


REMAINING LUNG FIELDS ARE NORMAL.

BOTH COSTOPHRENIC RECESS ARE CLEAR.

CARDIAC SIZE WITHIN NORMAL LIMITS.

MEDIASTINUM AND BONY THORACIC CAGE REVEAL NO ABNORMALITY.

IMPRESSION : NORMAL LUNGS HEART AND MEDIASTUINUM..


DR.HIMANI VIRAPARA
Regn. No: G.28771
M.D. [Radiodiagnosis]
(CONSULTANT RADIOLOGIST)



2D Echocardiography & Color Doppler Report

iCure Hear care, 402, Epsilon tower, opp Pasha bhaj park, Race course, Vadodara

Patient Name: Mr Piyush Gupta

Date: 10 / 12 / 2022

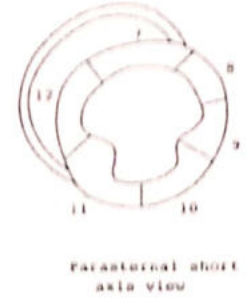
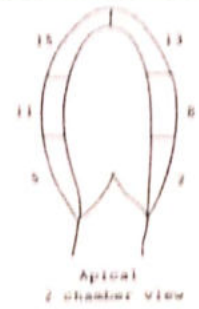
Age Gender: male - 34 Years

M. Mode Study:

LA	30	IVS	09	PWD	09
AO	25	LVDs	25	LVDd	44

Doppler Study:

Mitral Valve	E: 0.92 A: 0.56
Aortic Valve	Normal
Tricuspid Valve	Normal
Pulmonary Valve	Normal



Conclusion:

- Normal LV Systolic function
- LVEF: 58 % ,No RWMA
- Cardiac Chambers: Normal
- Diastolic function: Normal
- TR: Mild PAH: Mild RVSP: 35 mmhg
- No Ms , No MR
- Mild AR , No AS
- ASD/VSD/PDA/Co-A : No
- No Clots or vegetations found
- IVC: Normal

Note:

Normal 2D echo report does not rule out cardiac diseases
this report shall not be used for Medico legal purposes,
Clinical Correlation advisable.



Dr. Krish P. Vaidya
MD, PGCC
Associate Consultant-Cardiology
Reg.No.G-50510

Dr. Krish P Vaidya
Consultant Cardiologist, Diabetologist
& General Physician


Heart & General Clinic

iCure Heart & Diet Clinic, 402, Epsilon tower, opp Pasha bhai park, Race course, Vadodara

NAME : Mr Piyush Gupta	AGE: 34 Y/M	DATE : 10/12/2021
------------------------	-------------	-------------------

ULTRASOUND WHOLE ABDOMEN

(Screening Only)

Liver is normal in size and shows normal parenchymal reflectivity. No focal lesion is seen. Hepatic veins appear normal. There is no evidence of any dilated intra hepatic biliary radicals.

Portal Vein appears normal in diameter. **Common Bile Duct** is of normal diameter.

Gallbladder is distended with normal wall thickness. There is no evidence of gallstones. No evidence of peri-cholecystic fluid or probe tenderness.

Pancreas is normal in size and shows homogenous reflectivity. There is no evidence of any calcification or ductal dilatation.

Spleen is normal size and shows a homogenous echotexture. There is no evidence of any focal lesion.

Both Kidneys are normal in position and size. They show normal cortical reflectivity and cortico-medullary distinction. Right kidney measures 99x43mm. Left kidney measures 89x35mm. There is no evidence of renal calculi, hydronephrosis or mass seen.

Bladder is well distended and shows normal wall thickness. No evidence of intra-luminal mass or calculi.

Prostate gland is normal in size. It has smooth outlines and normal reflectivity. There is no evidence of ascites.

No evidence of any gross bowel mass seen.

No evidence of any aorto-caval or mesenteric root lymphadenopathy.

Appendix cannot be imaged. No mass or collection in right iliac fossa.

CONCLUSION: No sonographic abnormality is seen.



Mehul Prajapati

**DR. MEHUL PRAJAPATI
CONSULTANT RADIOLOGIST**