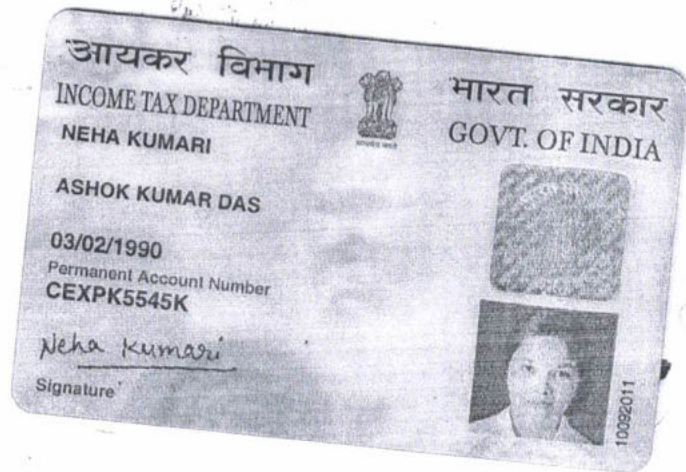


ONEPLUS ULTRASOUND LAB  
47, Harsh Vihar, Pitam Pura,  
Delhi-110034  
Ph. 011-42480101, 9599913051  
E-mail: oneplusul@gmail.com



Dr. NITIN AGARWAL  
MBBS, MD  
Regn. No. DMC-R-1436







Dr. NITIN AGARWAL  
MBBS, MD  
Regn. No. DMC-R-1435

ONEPLUS ULTRASOUND LAB  
47, Harsh Vihar, Pitam Pura,  
Delhi-110034  
Ph. 011-42480101, 9559913051  
E-mail: oneplusul@gmail.com

# ONEPLUS ULTRASOUND LAB

47, HARSH VIHAR, PITAMPURA, DELHI- 110034

Ms. NEHA KUMARI

Age : 33/F

Ref. by : MEDIWHEEL

Indication1 :

Indication2 :

Indication3 :

COMMENTS : Normal ECG.

ID : 2164

HWT : 161/59

Recorded : 25-3-2023 9:35

Medication1 :

Medication2 :

Medication3 :

BPM : 89

BP : 110/70

P Axis : 70 deg

QRS Axis : 82 deg

T Axis : 30 deg

P duration : 80 msec

PR duration : 123 msec

QRS duration : 100 msec

QT interval : 303 msec

QTc interval : 353 msec

Raw E.C.G. (Seq)

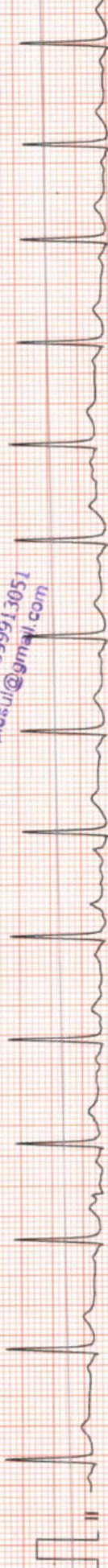
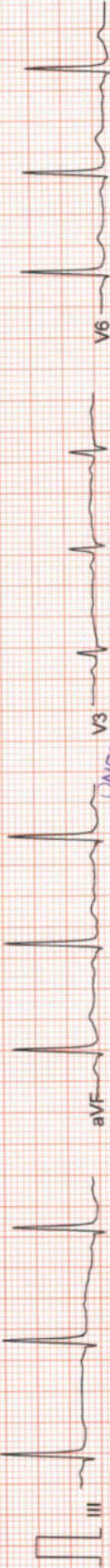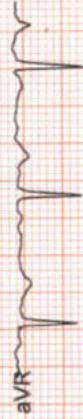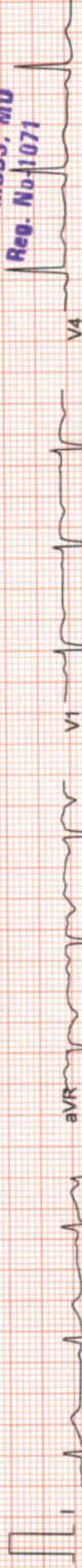Unconfirmed Report Reviewed By:

Cardiologist

*Dr. Ravi Gupta*  
**Dr. Ravi Gupta**

**M.B.B.S., MD**

**Reg. No. 1071**



**ONEPLUS ULTRASOUND LAB**  
47, Harsh Vihar, Pitam Pura,  
Delhi-110034  
Ph. 011-42480101, 9599913051  
E-mail: [oneplusul@gmail.com](mailto:oneplusul@gmail.com)

# ONEPLUS ULTRASOUND LAB

47, HARSH VIHAR PITAMPURA DELHI-110034

Ms. NEHA KUMARI  
 Age : 33/F  
 Ref. by : MED/WHEEL  
 Indication 1 :  
 Indication 2 :  
 Indication 3 :

ID : 992  
 Hi/Wt : 161/59  
 Recorded : 25-3-2023 9:37

TREADMILL TEST SUMMARY REPORT  
 Protocol: BRUCE  
 History :  
 Medication 1 :  
 Medication 2 :  
 Medication 3 :

PHASE	PHASE TIME	STAGE TIME	SPEED (Km./hr.)	GRADE (%)	H.R. (BPM)	B.P. (mmHg)	RPP X100	II	ST LEVEL (mm) V2	V5	METS
SUPINE					85	110/70	93	0.2	0.6	0.3	
STANDING					83	110/70	91	0.1	0.6	0.3	
STAGE 1	2:59	2:59	2.70	10.00	131	120/74	157	-0.7	0.3	-0.2	4.80
STAGE 2	5:59	2:59	4.00	12.00	137	130/78	178	-1.0	0.1	-0.7	7.10
STAGE 3	8:59	2:59	5.40	14.00	151	140/82	211	-2.1	0.6	-1.2	10.00
STAGE 4	9:29	0:29	6.70	16.00	172	150/90	258	-2.4	-1.5	-2.7	10.65
PEAK EXER	9:43	0:43			174	150/90	261	-0.9	-0.3	-2.5	10.96
PEAK EXER	9:44	0:44			174	150/90	261	-0.9	-0.3	-2.5	10.98
RECOVERY	2:59	2:59	0.00	0.00	104	110/72	114	-0.8	0.1	-0.7	

### RESULTS

Exercise Duration : 9.44 Minutes  
 Max Heart Rate : 174 bpm 93% of target heart rate 187 bpm  
 Max Blood Pressure : 150/90 mmHg  
 Max Work Load : 10.98 METS  
 Reason of Termination :

*Negative for ischemic change*

### IMPRESSIONS

ONEPLUS ULTRASOUND LAB  
 47, Harsh Vihar, Pitam Pura,  
 Delhi-110034  
 Ph. 011-42480101, 9599913051  
 E-mail: oneplusul@gmail.com

*[Signature]*  
**Dr. P.K. GUPTA**  
**MBBS, MD**  
**Cardiologist**

*[Signature]*

# ONEPLUS ULTRASOUND LAB

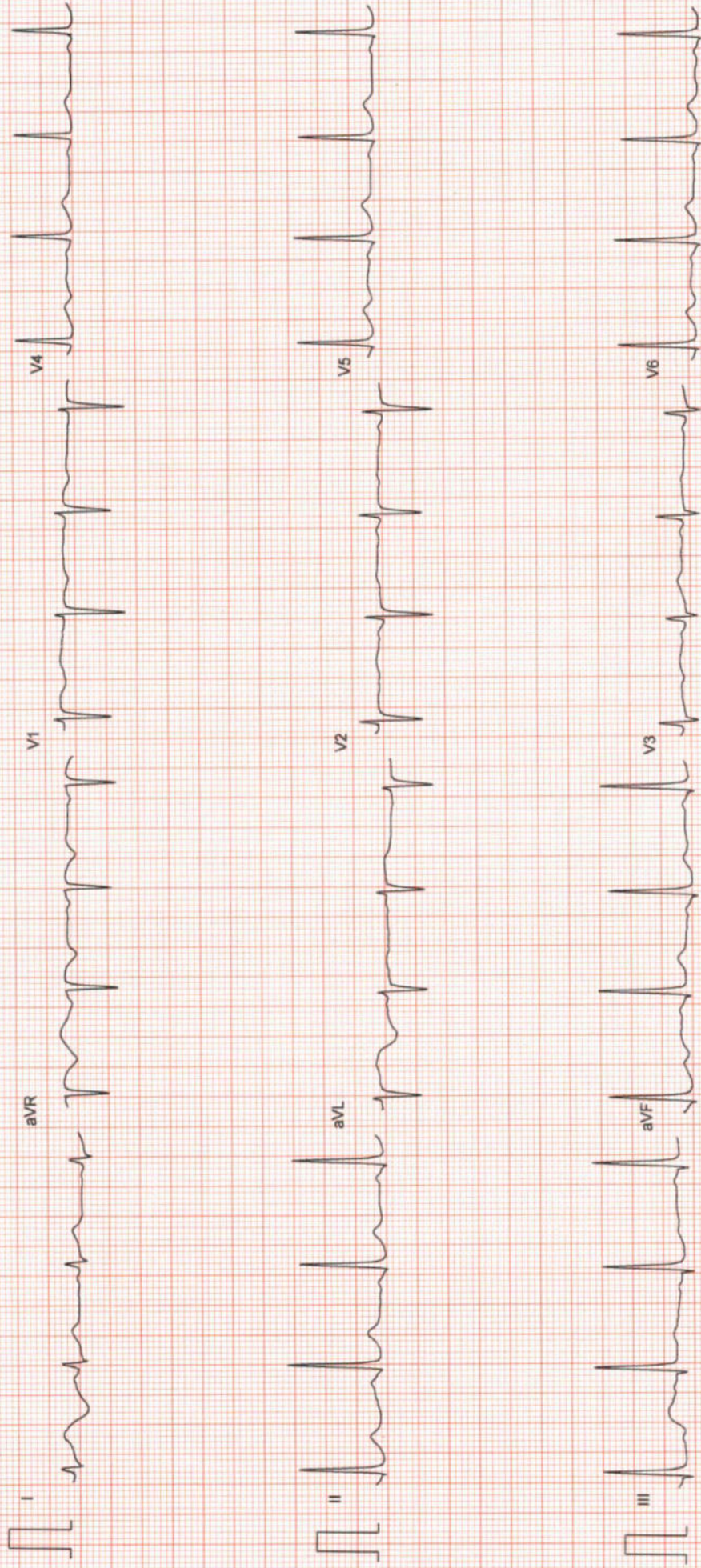
Ms. NEHA KUMARI  
I.D. : 992  
AGE/SEX : 33/F  
RECORDED : 25-3-2023 9:37

SUPINE  
PRETEST

RATE : 85 BPM  
B.P. : 110/70 mmHg

ST @ 10mm/mV  
80ms PostJ

RAW E.C.G.



ONEPLUS ULTRASOUND LAB  
47, Harsh Vihar, Pitam Pura  
Delhi-110034  
Ph: 011-42430101, 9599913051  
E-mail: onepplusul@gmail.com

# ONEPLUS ULTRASOUND LAB

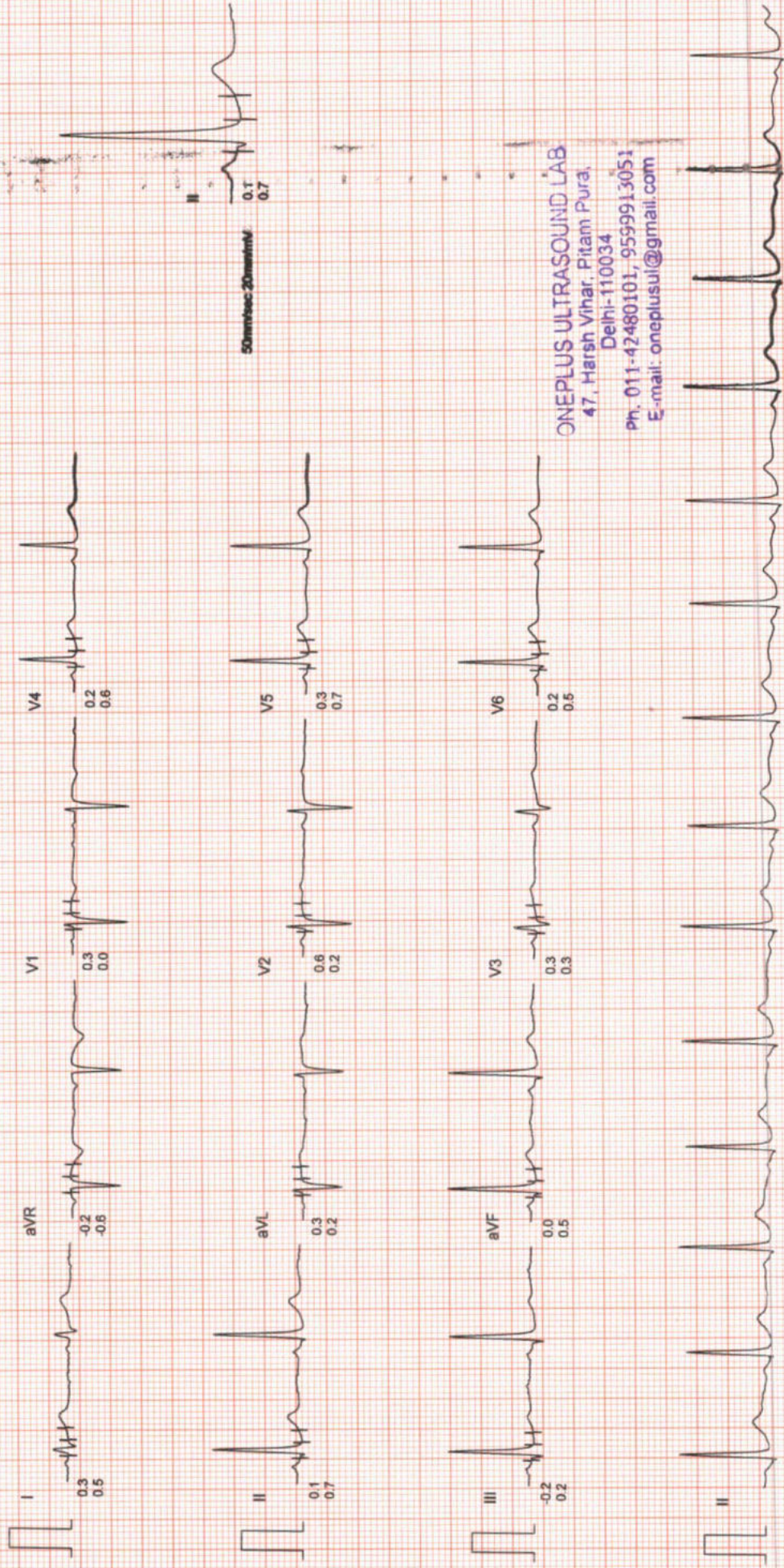
Ms. NEHA KUMARI  
I.D. : 992  
AGE/SEX : 33/F  
RECORDED : 25-3-2023 9:37

ST @ 10mm/mV  
80ms PostJ

STANDING  
PRETEST

RATE : 83 BPM  
B.P. : 110/70 mmHg

LINKED MEDIAN



50mm/sec 20mm/mV

ONEPLUS ULTRASOUND LAB  
47, Harsh Vihar, Pitam Pura,  
Delhi-110034  
Ph. 011-42480101, 9599913051  
E-mail: oneplusul@gmail.com

# ONEPLUS ULTRASOUND LAB

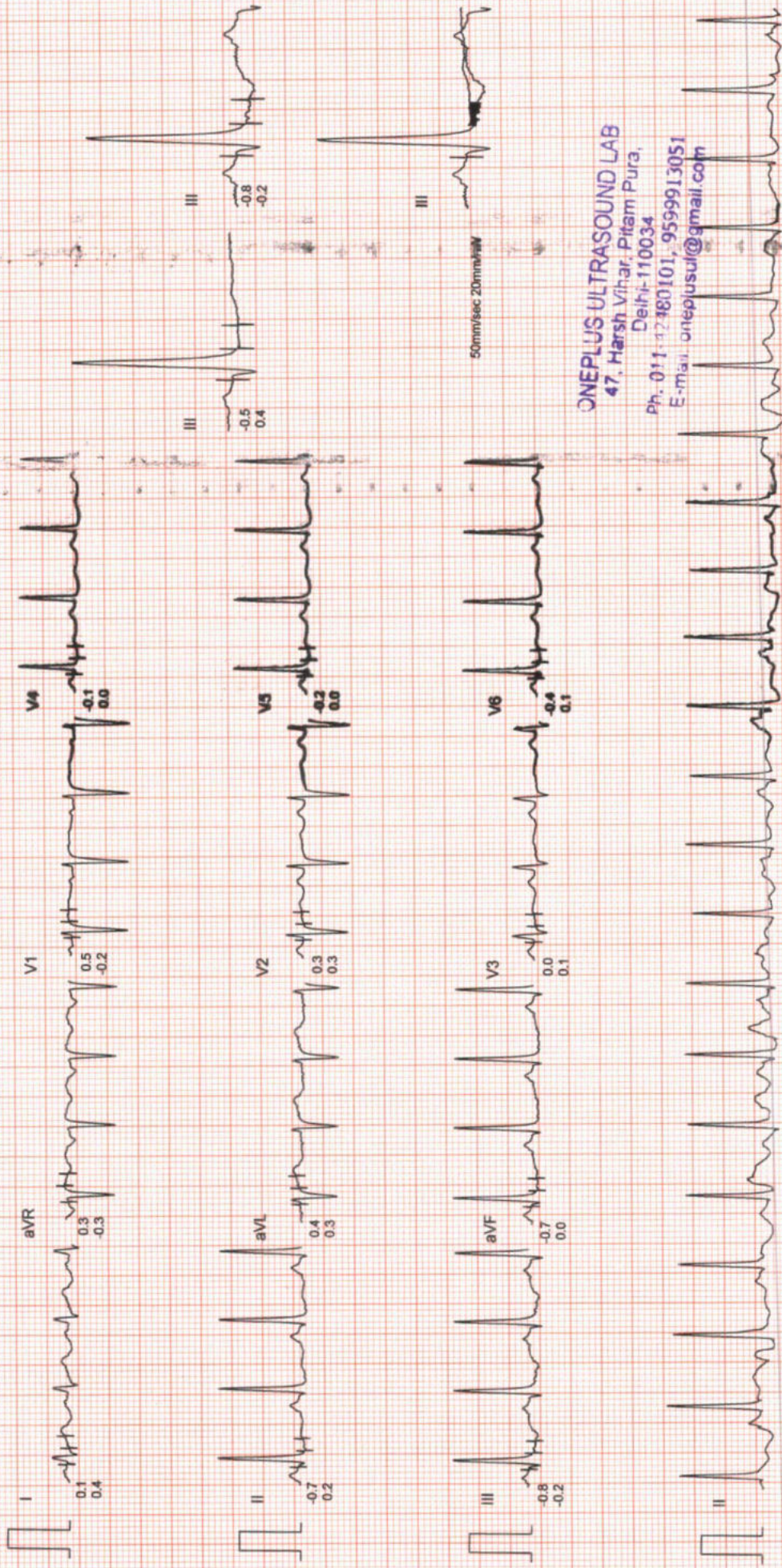
Ms. NEHA KUMARI  
I.D. : 992  
AGE/SEX : 33/F  
RECORDED : 25-3-2023 9:37

RATE : 131 BPM  
B.P. : 120/74 mmHg

BRUCE  
EXERCISE 1  
PHASE TIME : 2:59  
STAGE TIME : 2:59

ST @ 10mm/mV  
80ms PostJ  
SPEED : 2.7 Km./Hr.  
GRADE : 10.0 %

LINKED MEDIAN



ONEPLUS ULTRASOUND LAB  
47, Harsh Vihar, Pitam Pura,  
Delhi-110034  
Ph. 011-12180101, 9599913051  
E-mail: oneplusul@gmail.com



# ONEPLUS ULTRASOUND LAB

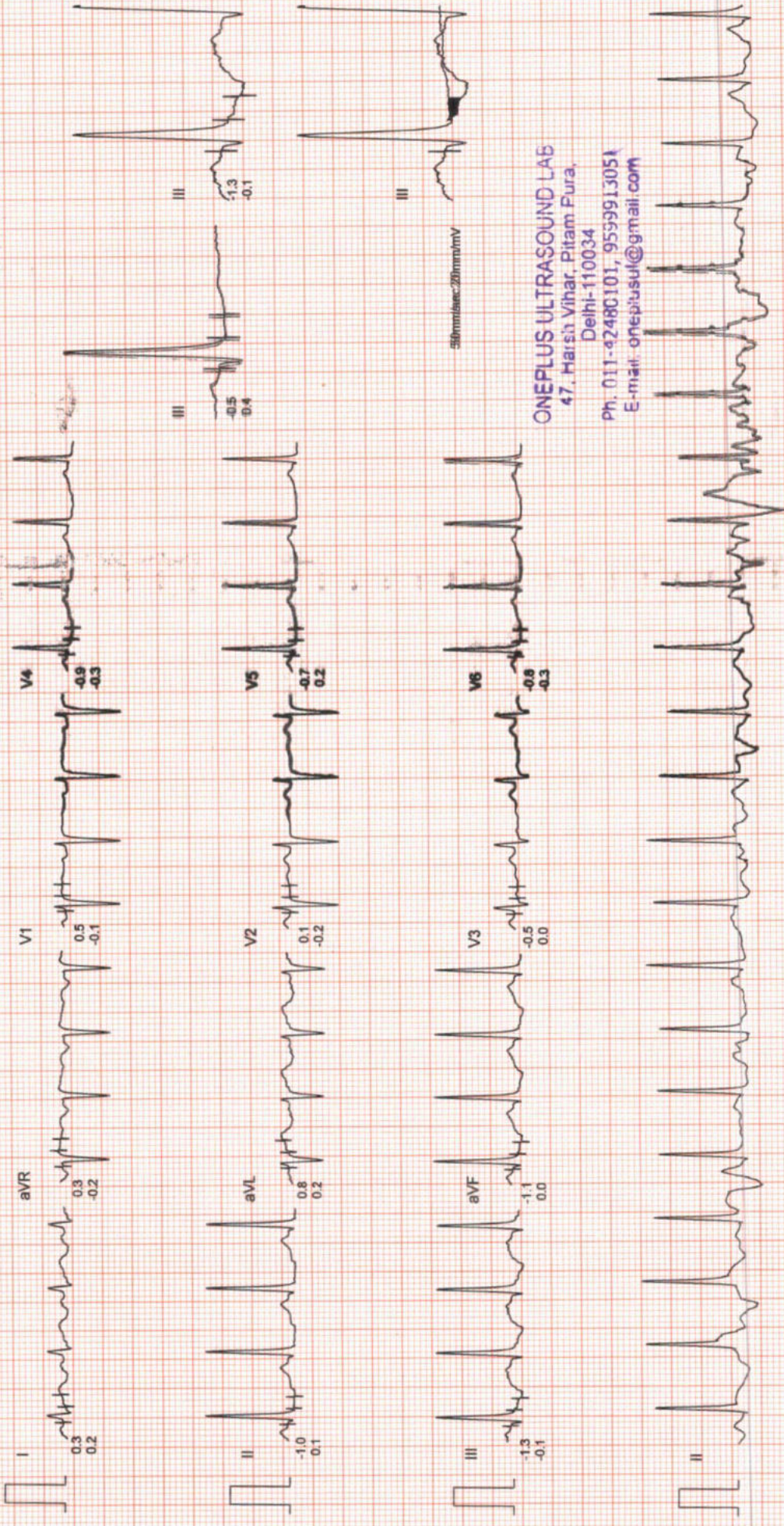
Ms. NEHA KUMARI  
I.D. : 992  
AGE/SEX : 33/F  
RECORDED : 25-3-2023 9:37

BRUCE  
EXERCISE 2  
PHASE TIME : 5:59  
STAGE TIME : 2:59

ST @ 10mm/mV  
60ms PostJ  
SPEED : 4.0 Km./Hr.  
GRADE : 12.0 %

RATE : 137 BPM  
B.P. : 130/78 mmHg

LINKED MEDIAN



ONEPLUS ULTRASOUND LAB  
47, Harsh Vihar, Pitam Pura,  
Delhi-110034  
Ph. 011-42480101, 9599913051  
E-mail: oneplusul@gmail.com

# ONEPLUS ULTRASOUND LAB

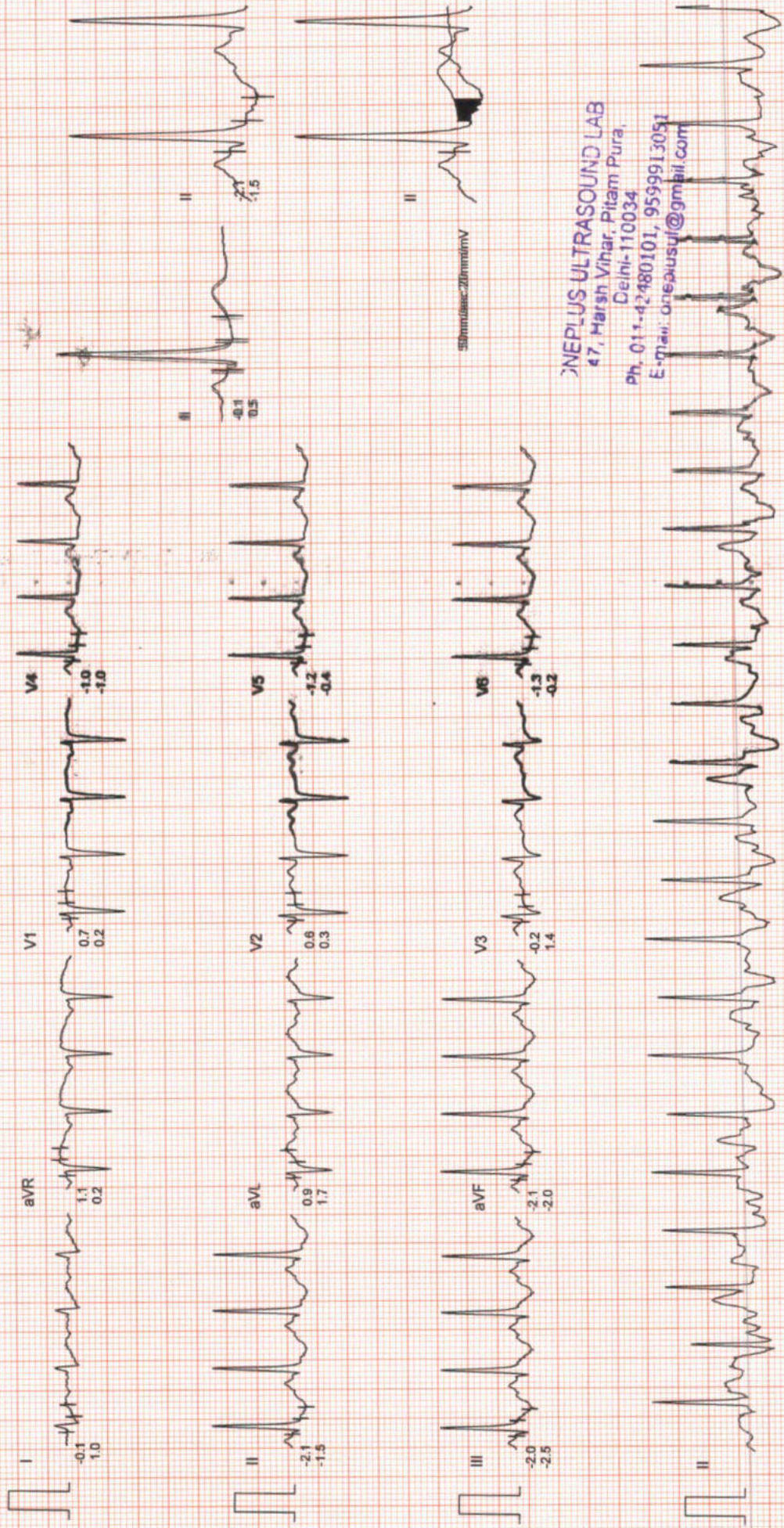
Ms. NEHA KUMARI  
I.D. : 992  
AGE/SEX : 33/F  
RECORDED : 25-3-2023 9:37

BRUCE  
EXERCISE 3  
PHASE TIME : 8:59  
STAGE TIME : 2:59

RATE : 151 BPM  
B.P. : 140/82 mmHg

ST @ 10mm/mV  
60ms PostJ  
SPEED : 5.4 Km./Hr.  
GRADE : 14.0 %

LINKED MEDIAN



ONEPLUS ULTRASOUND LAB  
47, Hrish Vihar, Pitam Pura,  
Delhi-110034  
Ph. 011-42480101, 9599913051  
E-Mail: [oneplusul@gmail.com](mailto:oneplusul@gmail.com)

# ONEPLUS ULTRASOUND LAB

Ms. NEHA KUMARI  
I.D. : 992  
AGE/SEX : 33/F

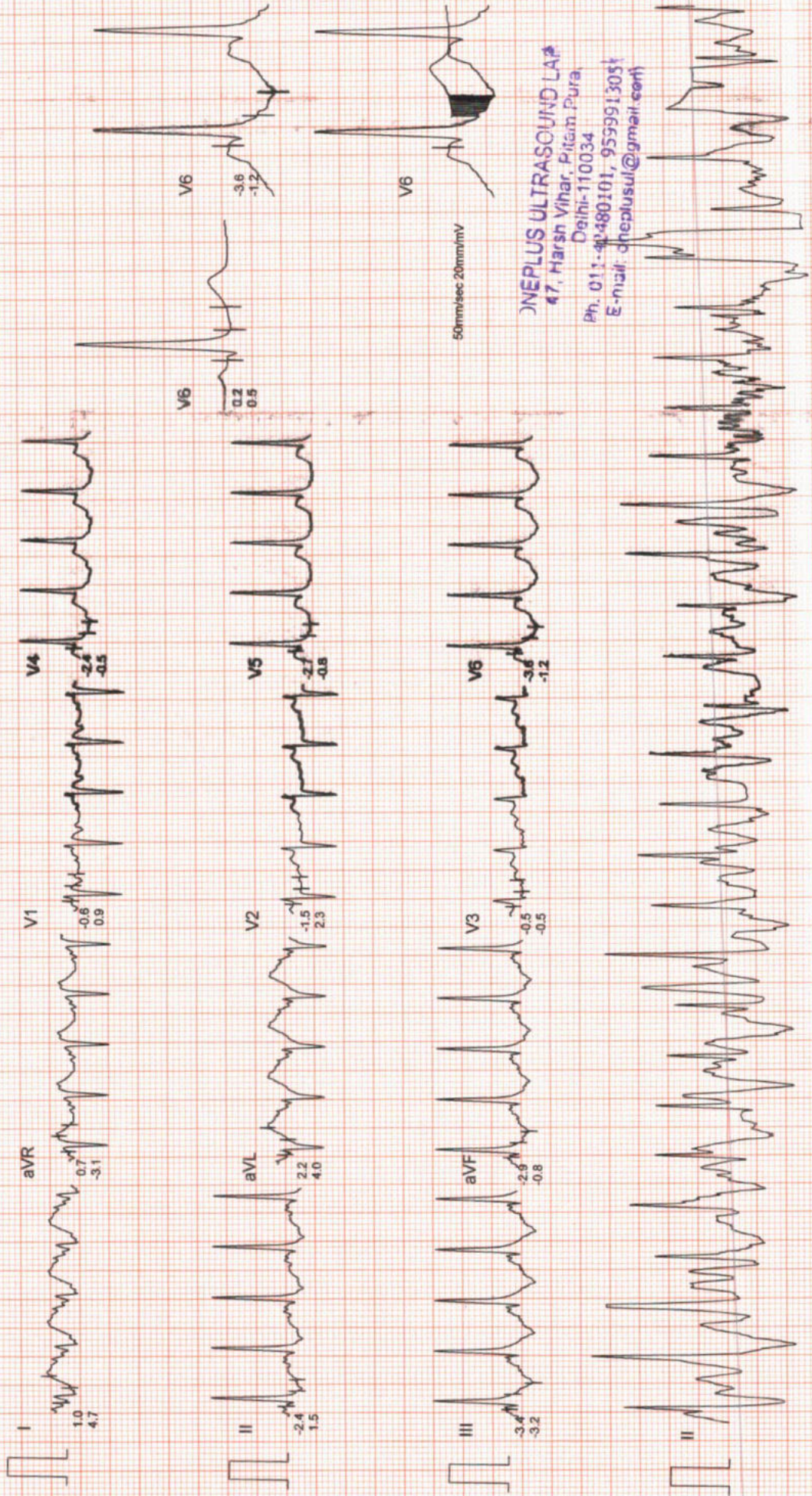
BRUCE  
EXERCISE 4

RECORDED : 25-3-2023 9:37  
RATE : 172 BPM  
B.P. : 150/90 mmHg

PHASE TIME : 9:29  
STAGE TIME : 0:29

ST @ 10mm/mV  
80ms PostJ  
SPEED : 6.7 Km/HR.  
GRADE : 16.0 %

LINKED MEDIAN



ONEPLUS ULTRASOUND LAB  
47, Harsh Vihar, Pitam Pura,  
Delhi-110034  
Ph. 011-48480101, 9599913054  
E-mail: dheplusul@gmail.com

# ONEPLUS ULTRASOUND LAB

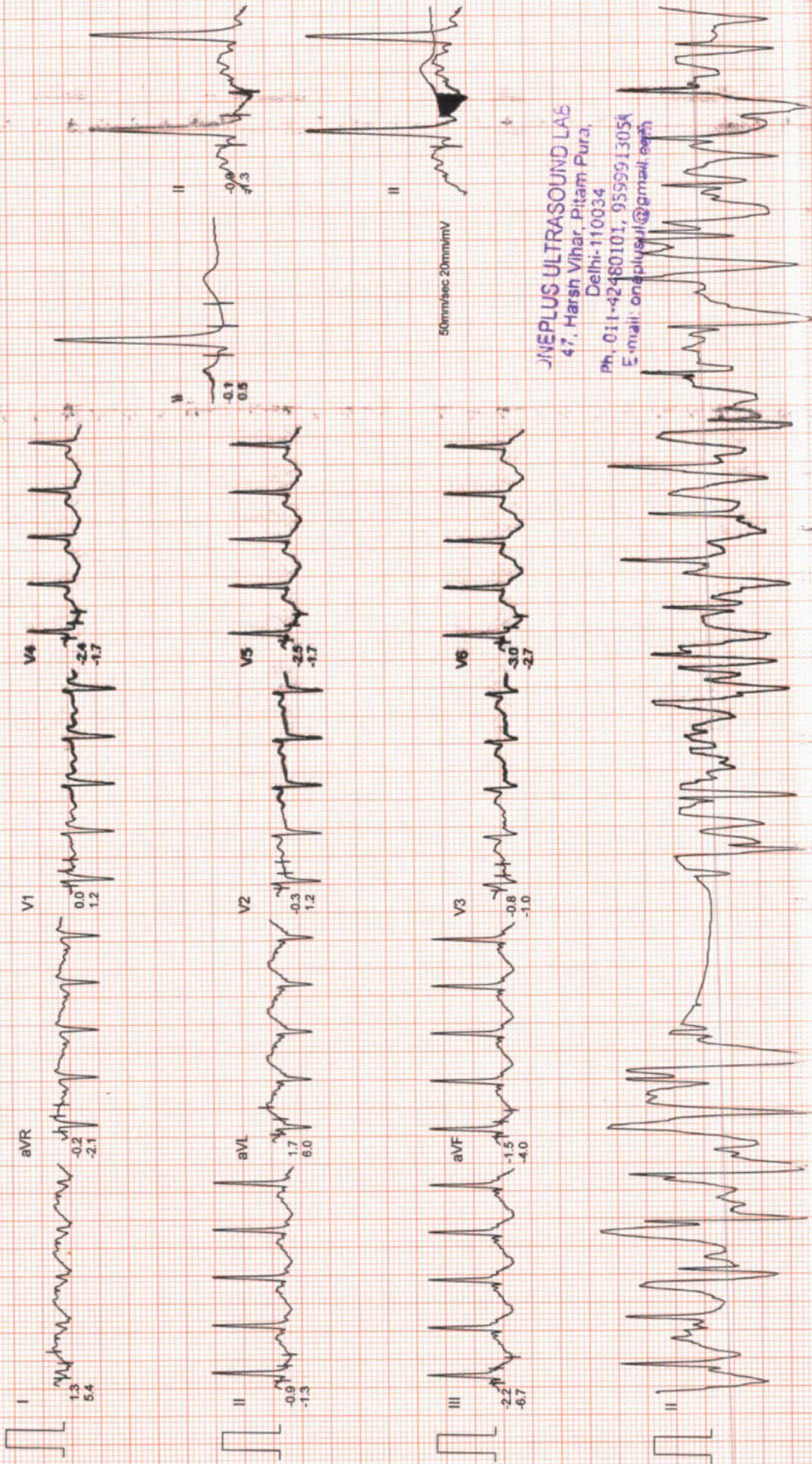Ms. NEHA KUMARI  
I.D. : 992  
AGE/SEX : 33/F  
RECORDED : 25-3-2023 9:37

RATE : 174 BPM  
B.P. : 150/90 mmHg

BRUCE  
PEAK EXER  
PHASE TIME : 9:43  
STAGE TIME : 0:43

ST @ 10mm/mV  
80ms PostJ  
SPEED : 6.7 Km/HR.  
GRADE : 16.0 %

LINKED MEDIUM



50mm/sec 20mm/mV

ONEPLUS ULTRASOUND LABS  
47, Harsh Vihar, Pitam Pura,  
Delhi-110034  
Ph. 011-42480101, 9599913054  
E-mail: onepplusul@gmail.com

Filtered

Computer Corrected Baseline

25mm/sec 10mm/mV

CardCom. INDIA Ph. 091-731-2620740 TeleFax: 091-731-2620740

# ONEPLUS ULTRASOUND LAB

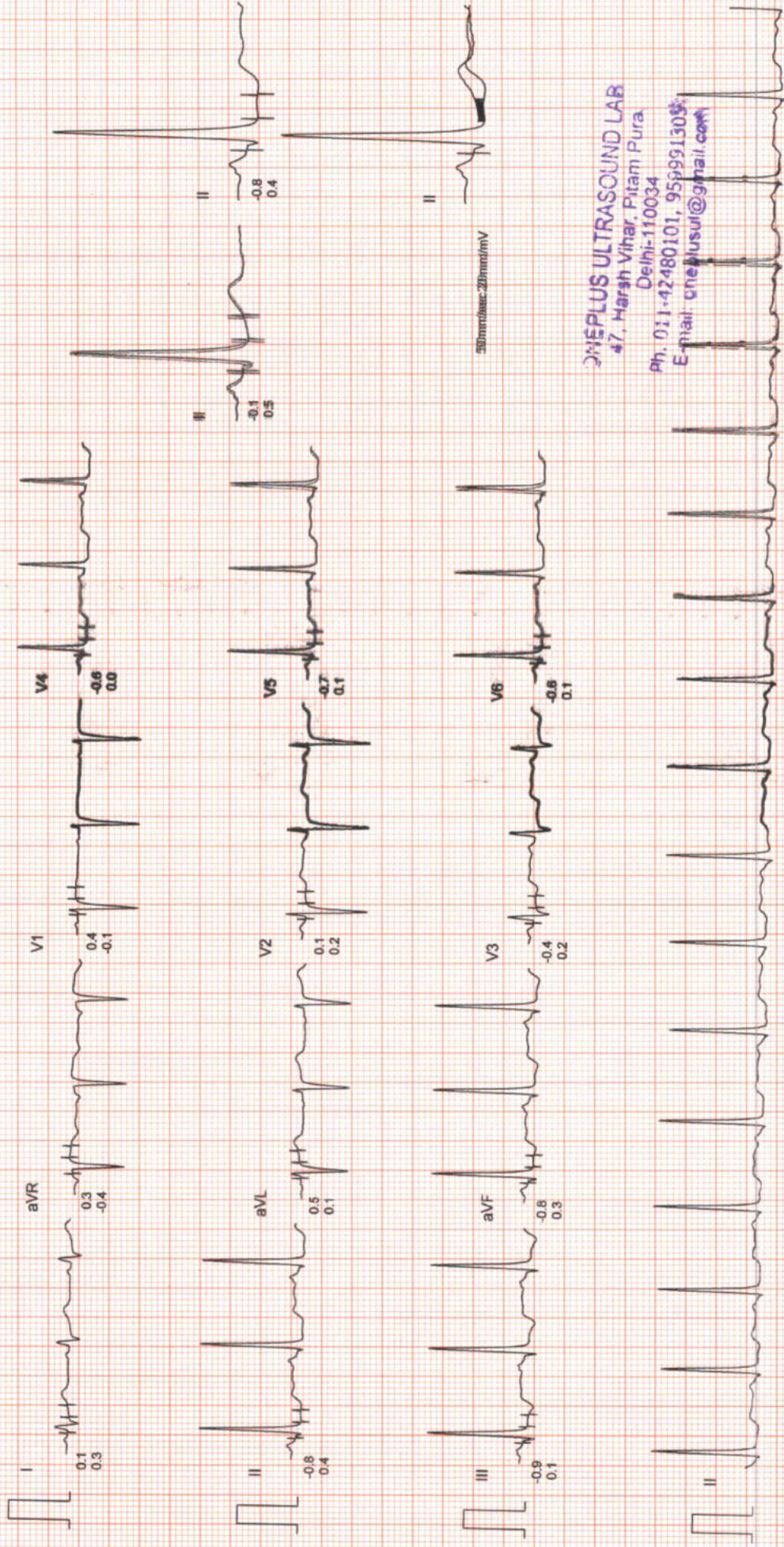
Ms. NEHA KUMARI  
I.D. : 992  
AGE/SEX : 33/F  
RECORDED : 25-3-2023 9:37

RATE : 104 BPM  
B.P. : 110/72 mmHg

BRUCE  
RECOVERY  
PHASE TIME: 2:59

ST @ 10mm/mV  
80ms PostJ  
SPEED : 0.0 Km./Hr.  
GRADE : 0.0 %

LINKED MEDIAN



ONEPLUS ULTRASOUND LAB  
47, Harsh Vihar, Pitam Pura  
Delhi-110034  
Ph. 011-42480101, 9599913034  
E-mail: [oneplusul@gmail.com](mailto:oneplusul@gmail.com)

# ONEPLUS ULTRASOUND LAB

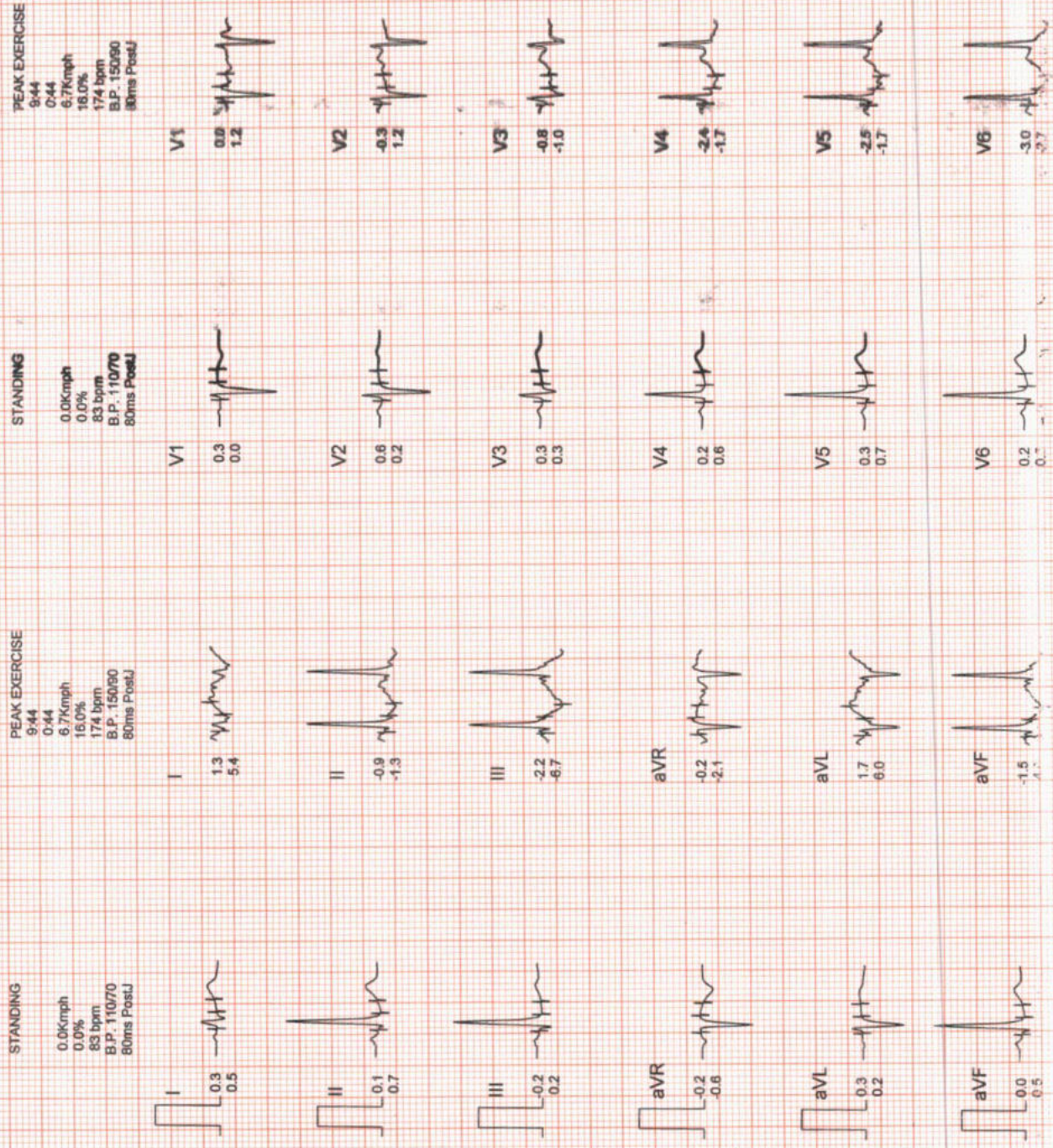
Ms. NEHA KUMARI

I.D. : 992

AGE/SEX : 33/F

RECORDED : 25-3-2023 9:37

## COMPARISON REPORT



ONEPLUS ULTRASOUND LAB  
 Dr. Harsh Vihar, Pitam Pura  
 Delhi-110034  
 Ph. 91-12-480101, 9559913854  
 E-mail: oneplusul@gmail.com

# ONEPLUS ULTRASOUND LAB

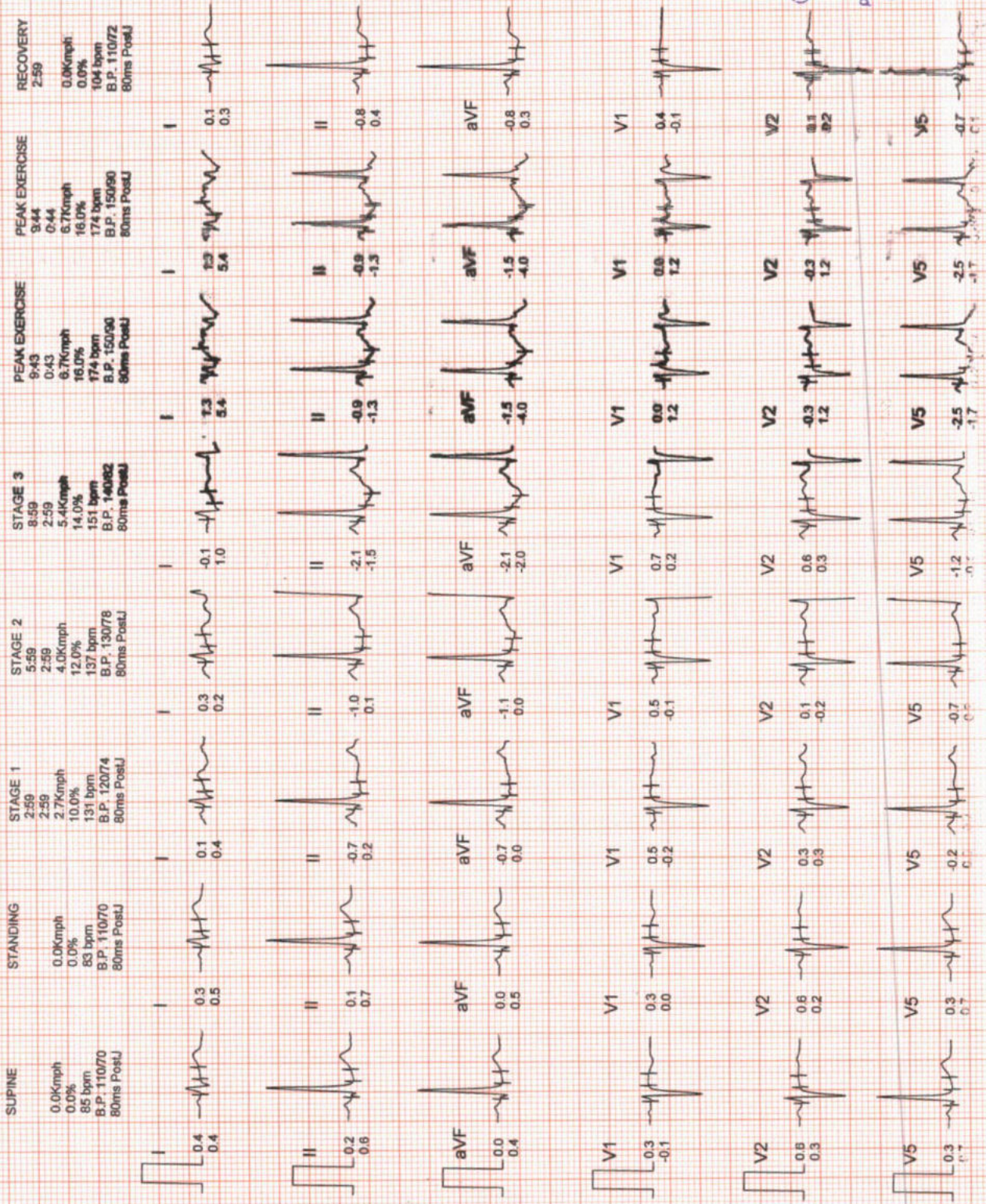
Ms. NEHA KUMARI

I.D. : 992

AGE/SEX : 33/F

RECORDED : 25-3-2023 9:37

AVG ECG.



ONEPLUS ULTRASOUND LAB  
47, Harsh Vihar, Pitam Pura  
Delhi-110034  
Ph. 011-42480101, 9599913059  
E-mail: onepplusul@gmail.com



# OnePLUS Ultrasound Lab

QUALITY FIRST... ALWAYS!

**Dr. Nitin Agarwal**  
Pathologist & Director  
Ex. Sr. Res. MAMC  
& Lok Nayak Hospital  
Ex. Chief of Lab Dr. Lal Path Labs.

**Dr. Pooja (Garg) Agarwal**  
Radiologist & Director  
MAMC & Lok Nayak Hospital



NAME	:Mrs. NEHA KUMARI	Barcode No	:10140824
AGE/GENDER	:33 YRS/Female	SPECIMEN DATE	:25/Mar/2023 08:27AM
PATIENT ID	:111314	SPECIMEN RECEIVED	:25/Mar/2023 08:36AM
REFERRED BY	:Dr. MEDIWHEEL	REPORT DATE	:25/Mar/2023 01:15PM
CENTRE NAME	:ONEPLUS ULTRASOUND LAB	LAB NO.	:012303250007

Test Name	Result	Unit	Ref. Range
-----------	--------	------	------------

## HAEMATOLOGY

### Medi Wheel Health checkup < 40 Female

<b>Glycosylated Hemoglobin (HbA1c)</b>	5.0	%	Non Diabetic adults <5.7 Prediabetic (at risk) 5.7-6.4 Diabetes >6.4
<b>Estimated average blood glucose (eag)</b>	97		

#### Reference range (mg/dl):

90 - 120:Excellent control, 121 - 150:Good Control, 151 - 180:Average Control, 181 - 210:Action Suggested

>211:Panic value

#### BLOOD GROUP (ABO)

A

#### Rh typing

POSITIVE

#### NOTE :

- \* Apart from major A,B,H antigens which are used for ABO grouping and Rh typing, many minor blood group antigens exist. Agglutination may also vary according to titre of antigen and antibody.
- \* So before transfusion, reconfirmation of blood group as well as cross-matching is needed.
- \* Presence of maternal antibodies in newborns, may interfere with blood grouping.
- \* Auto agglutination (due to cold antibody, falciparum malaria, sepsis, internal malignancy etc.) may also cause colorous result.

#### CBC

Haemoglobin	12.9	g/dl	11.5-15.0
Total Leucocyte Count	5500	/cumm	4000-10000
<b>Differential leucocyte count</b>			
Neutrophils	56.2	%	40-80
Lymphocyte	38.90	%	20-40
Monocytes	2.90	%	2-10
Eosinophils	1.2	%	1-6
Basophils	0.8	%	0-2
RBC Count	4.60	million/cumm	3.8-4.8

Checked By.

Dr. NITIN AGARWAL  
M B B S , MD (Pathology)  
DMC/R/01436

DR. NITIN AGARWAL  
M B B S , MD (PATHOLOGIST)

47, Harsh Vihar, Pitampura, New Delhi-110034 | Ph.: 011-42480101, 9599913051

E-mail: oneplusul@gmail.com | Web.: www.oneplusul.in

Page 1 of 7





# OnePLUS Ultrasound Lab

**Dr. Nitin Agarwal**  
Pathologist & Director  
Ex. Sr. Res. MAMC  
& Lok Nayak Hospital  
Ex. Chief of Lab Dr. Lal Path Labs.

**Dr. Pooja (Garg) Agarwal**  
Radiologist & Director  
MAMC & Lok Nayak Hospital



QUALITY FIRST... ALWAYS!

NAME	:Mrs. NEHA KUMARI	Barcode No	:10140824
AGE/GENDER	:33 YRS/Female	SPECIMEN DATE	:25/Mar/2023 08:27AM
PATIENT ID	:111314	SPECIMEN RECEIVED	:25/Mar/2023 08:36AM
REFERRED BY	:Dr. MEDIWHEEL	REPORT DATE	:25/Mar/2023 01:15PM
CENTRE NAME	:ONEPLUS ULTRASOUND LAB	LAB NO.	:012303250007

Test Name	Result	Unit	Ref. Range
PCV(Hematocrit)	41.9	%	36-46
MCV	90.8	fL	83-101
MCH	28.0	Pg	27-32
MCHC	<b>30.9</b>	G/dL	32-35
Platelet count	178000	/cumm	150000-450000
RDW-CV	13.5	%	11.4-14.0
ESR(WESTEGRENs METHOD)	05	mm/1hr	<20
<b>BIOCHEMISTRY</b>			
<b>Blood sugar fasting</b>	94	mg/dL	70-110

Checked By.

Dr NITIN AGARWAL  
M B B S , MD (Pathology)  
DMC/R/01436  
DR. NITIN AGARWAL  
MBBS,MD(PATHOLOGIST)

47, Harsh Vihar, Pitampura, New Delhi-110034 | Ph.: 011-42480101, 9599913051  
E-mail: [oneplusul@gmail.com](mailto:oneplusul@gmail.com) | Web.: [www.oneplusul.in](http://www.oneplusul.in)

Page 2 of 7

Clinical correlation is essential for final diagnosis. • If test results are unsatisfactory please contact personally or on phone. • This report is for perusal of doctors only.  
• All disputes Subject to Delhi Jurisdiction only. • Not for medicolegal purposes. • All congenital anomalies in a foetus may not be diagnosed in routine obstetric ultrasound.



# OnePLUS Ultrasound Lab

QUALITY FIRST... ALWAYS!

**Dr. Nitin Agarwal**  
Pathologist & Director  
Ex. Sr. Res. MAMC  
& Lok Nayak Hospital  
Ex. Chief of Lab Dr. Lal Path Labs.

**Dr. Pooja (Garg) Agarwal**  
Radiologist & Director  
MAMC & Lok Nayak Hospital



NAME	:Mrs. NEHA KUMARI	Barcode No	:10140824
AGE/GENDER	:33 YRS/Female	SPECIMEN DATE	:25/Mar/2023 08:27AM
PATIENT ID	:111314	SPECIMEN RECEIVED	:25/Mar/2023 12:43PM
REFERRED BY	:Dr. MEDIWHEEL	REPORT DATE	:25/Mar/2023 02:16PM
CENTRE NAME	:ONEPLUS ULTRASOUND LAB	LAB NO.	:012303250007

Test Name	Result	Unit	Ref. Range
<b><u>BIOCHEMISTRY</u></b>			
<b>Blood sugar pp</b>	99	mg/dL	70.0-140.0

Checked By.

Dr NITIN AGARWAL  
M B B S , MD  
DMC/R/01436  
DR. NITIN AGARWAL  
MBBS, MD (PATHOLOGIST)

47, Harsh Vihar, Pitampura, New Delhi-110034 | Ph.: 011-42480101, 9599913051  
E-mail: oneplusul@gmail.com | Web.: www.oneplusul.in

Page 3 of 7

Clinical correlation is essential for final diagnosis. • If test results are unsatisfactory please contact personally or on phone. • This report is for perusal of doctors only.  
• All disputes Subject to Delhi Jurisdiction only. • Not for medicolegal purposes. • All congenital anomalies in a foetus may not be diagnosed in routine obstetric ultrasound.



# OnePLUS

## Ultrasound Lab

— QUALITY FIRST... ALWAYS! —

**Dr. Nitin Agarwal**  
Pathologist & Director  
Ex. Sr. Res. MAMC  
& Lok Nayak Hospital  
Ex. Chief of Lab Dr. Lal Path Labs.

**Dr. Pooja (Garg) Agarwal**  
Radiologist & Director  
MAMC & Lok Nayak Hospital



NAME	:Mrs. NEHA KUMARI	Barcode No	:10140824
AGE/GENDER	:33 YRS/Female	SPECIMEN DATE	:25/Mar/2023 08:27AM
PATIENT ID	:111314	SPECIMEN RECEIVED	:25/Mar/2023 08:36AM
REFERRED BY	:Dr. MEDIWHEEL	REPORT DATE	:25/Mar/2023 01:15PM
CENTRE NAME	:ONEPLUS ULTRASOUND LAB	LAB NO.	:012303250007

Test Name	Result	Unit	Ref. Range
-----------	--------	------	------------

### BIOCHEMISTRY

<b>Bun (blood urea nitrogen )</b>	12.60	mg/dl	7-18.7
<b>Uric acid, serum</b>	4.9	mg/dl	2.6-6.0
<b>Creatinine, serum</b>	0.6	mg/dl	0.50-1.0

### LFT(LIVER FUNCTION TEST)

Bilirubin Total	0.42	mg/dl	0.1-1.2
Bilirubin Conjugated	0.20	mg/dl	0-0.4
Bilirubin Unconjugated	0.22	mg/dl	up to 0.7
SGOT (AST)	25	U/L	0-46
SGPT (ALT)	12	U/L	0-49
Alkaline phosphatase	95	U/L	35-104
Gamma glutamyl transpeptidase	29	U/L	5.0-32.0
Total Protein	7.2	gm/dl	6.60 - 8.70
Albumin serum	4.6	g/dL	3.0-5.2
Globulin	2.60	gm/dl	1.8-3.4
Albumin/Globulin Ratio	1.77		1.10 - 2.50

### LIPID PROFILE

Cholesterol	240	mg/dl	50-200
Triglycerides	71	mg/dL	25-150
HDL Cholesterol	48	mg/dL	40 - 60
LDL cholesterol	178	mg/dL	< 130
VLDL cholesterol	14.2	mg/dL	5-40
Cholesterol/HDL Ratio	5.0		Low Risk 3.3-4.97 Average Risk 4.4-7.1 Moderate Risk 7.1-11.0 High Risk >11.0
LDL/HDL Ratio	3.7		0 - 3.55

According to ATP III and NCEP guidelines

Checked By.

Dr. NITIN AGARWAL  
M B B S, MD (Path)  
DMC/R/014  
DR. NITIN AGARWAL  
MBBS,MD(PATHOLOGIST)

47, Harsh Vihar, Pitampura, New Delhi-110034 | Ph.: 011-42480101, 9599913051  
E-mail: oneplusul@gmail.com | Web.: www.oneplusul.in

Page 4 of 7

Clinical correlation is essential for final diagnosis. • If test results are unsatisfactory please contact personally or on phone. • This report is for perusal of doctors only.  
• All disputes Subject to Delhi Jurisdiction only. • Not for medicolegal purposes. • All congenital anomalies in a foetus may not be diagnosed in routine obstetric ultrasound.



# OnePLUS Ultrasound Lab

— QUALITY FIRST... ALWAYS! —

**Dr. Nitin Agarwal**  
Pathologist & Director  
Ex. Sr. Res. MAMC  
& Lok Nayak Hospital  
Ex. Chief of Lab Dr. Lal Path Labs.

**Dr. Pooja (Garg) Agarwal**  
Radiologist & Director  
MAMC & Lok Nayak Hospital



NAME	:Mrs. NEHA KUMARI	Barcode No	:10140824
AGE/GENDER	:33 YRS/Female	SPECIMEN DATE	:25/Mar/2023 08:27AM
PATIENT ID	:111314	SPECIMEN RECEIVED	:25/Mar/2023 08:36AM
REFERRED BY	:Dr. MEDIWHEEL	REPORT DATE	:25/Mar/2023 01:15PM
CENTRE NAME	:ONEPLUS ULTRASOUND LAB	LAB NO.	:012303250007

Test Name	Result	Unit	Ref. Range	
<b>Parameter</b>	<b>Normal</b>	<b>Desirable</b>	<b>Borderline</b>	<b>High</b>
Total cholesterol	<200		200-239	240
Triglycerides	<150	150-199	200-499	500
LDL	Optimal <100	130-159	160-180	190
	Near Optimal 100-129			
HDL	<40 : LOW 60 : HIGH			

### BUN/Creatinine ratio

Bun (blood urea nitrogen )	12.60	mg/dl	7-18.7
CREATININE	0.60	mg/dl	0.30-1.10
BUN/Creatinine ratio	21.00		10.0 - 20.0

### ENDOCRINOLOGY

#### THYROID PROFILE(T3,T4,TSH)

Triiodothyronine total [t3]	0.58	ng/dl	0.52-1.9
Thyroxine total [t4]	4.80	µg/dl	4.8-11.6
TSH (Thyroid Stimulating Hormone)	3.50	µIU/ml	0.25-5.0

#### AGE WISE VARIATION IN TSH

AGE	TSH(µIU/ml)	AGE	TSH(µIU/ml)
1-4 weeks	1.00 - 19.0	16-20 yrs	0.25 - 5.0
1-12 mths	1.70 - 9.1	21 - 80 yrs	0.25 - 5.0
1-5 yrs	0.80 - 8.2	I <sup>st</sup> trimester	0.25 - 5.0
6-10 yrs	0.25 - 5.0	II <sup>nd</sup> trimester	0.50 - 5.0
11-15 yrs	0.25 - 5.0	II <sup>rd</sup> trimester	0.4 - 6.0

#### Reference ranges - Interpretation of Diagnostic tests - (Jacques Wallach)

1. Primary hypothyroidism is accompanied by depressed serum T3 and T4 values and elevated serum TSH level.

Checked By.

Dr. NITIN AGARWAL  
M.B.B.S., MD (Path)  
DMC/R/01436  
DR. NITIN AGARWAL  
MBBS, MD (PATHOLOGIST)

47, Harsh Vihar, Pitampura, New Delhi-110034 | Ph.: 011-42480101, 9599913051

E-mail: oneplusul@gmail.com | Web.: www.oneplusul.in

Page 5 of 7



# OnePLUS

## Ultrasound Lab

— QUALITY FIRST... ALWAYS! —

**Dr. Nitin Agarwal**  
Pathologist & Director  
Ex. Sr. Res. MAMC  
& Lok Nayak Hospital  
Ex. Chief of Lab Dr. Lal Path Labs.

**Dr. Pooja (Garg) Agarwal**  
Radiologist & Director  
MAMC & Lok Nayak Hospital



NAME	:Mrs. NEHA KUMARI	Barcode No	:10140824
AGE/GENDER	:33 YRS/Female	SPECIMEN DATE	:25/Mar/2023 08:27AM
PATIENT ID	:111314	SPECIMEN RECEIVED	:25/Mar/2023 08:36AM
REFERRED BY	:Dr. MEDIWHEEL	REPORT DATE	:25/Mar/2023 01:15PM
CENTRE NAME	:ONEPLUS ULTRASOUND LAB	LAB NO.	:012303250007

Test Name	Result	Unit	Ref. Range
<p>2. Primary hyperthyroidism is accompanied by elevated serum T3 and T4 levels along with depressed TSH values.            3. Slightly elevated T3 levels may be found in pregnancy and estrogen therapy, while depressed levels may be encountered in severe illness, renal failure and during therapy with drugs like propranolol and propyl thiouracil.            4. Although elevated TSH levels are nearly always indicative of primary hypothyroidism, and may be seen in secondary thyrotoxicosis</p>			

### CLINICAL PATHOLOGY

#### URINE ROUTINE

##### Physical examination

Quantity	20		ML
Colour	PALE YELLOW		
Transparency	CLEAR		CLEAR
Sp.gravity	1.015		1.010-1.030
pH	6.00		
Reaction	ACIDIC		ACIDIC

##### Chemical examination

Urine protein	NIL		NIL
Urine sugar	NIL		NIL
Bilirubin, urine	NEGATIVE		NEGATIVE
Urobilinogen	NORMAL		NORMAL
Ketones	NEGATIVE		NEGATIVE

##### Microscopic examination

WBCs cells.	2-3	/HPF	1-2
Epithelial cells	6-8	/HPF	0-5
R.B.C.	NIL	/HPF	NIL
Casts	NIL	/HPF	NIL
Crystals	NIL	/HPF	NIL
Bacteria	NIL	/HPF	NIL
Others.	NIL		NIL

Checked By.

Dr. NITIN AGARWAL  
MBBS, MD (Path)  
DMC/R/01439  
DR. NITIN AGARWAL  
MBBS, MD (PATHOLOGIST)

47, Harsh Vihar, Pitampura, New Delhi-110034 | Ph.: 011-42480101, 9599913051

E-mail: oneplusul@gmail.com | Web.: www.oneplusul.in

Page 6 of 7



**OnePLUS**  
Ultrasound Lab

— QUALITY FIRST... ALWAYS! —

**Dr. Nitin Agarwal**  
Pathologist & Director  
Ex. Sr. Res. MAMC  
& Lok Nayak Hospital  
Ex. Chief of Lab Dr. Lal Path Labs.

**Dr. Pooja (Garg) Agarwal**  
Radiologist & Director  
MAMC & Lok Nayak Hospital



NAME	:Mrs. NEHA KUMARI	Barcode No	:10140824
AGE/GENDER	:33 YRS/Female	SPECIMEN DATE	:25/Mar/2023 08:27AM
PATIENT ID	:111314	SPECIMEN RECEIVED	:25/Mar/2023 12:43PM
REFERRED BY	:Dr. MEDIWHEEL	REPORT DATE	:25/Mar/2023 02:16PM
CENTRE NAME	:ONEPLUS ULTRASOUND LAB	LAB NO.	:012303250007

Test Name	Result	Unit	Ref. Range
-----------	--------	------	------------

**CLINICAL PATHOLOGY**

**STOOL ROUTINE**

**Physical examination**

Colour	BROWNISH		Brownish
Consistency	SEMI LOOSE		Semi Formed
Blood	ABSENT		Absent
Mucus	ABSENT		Absent

**Chemical examination, stool**

pH	6.00		
----	------	--	--

**Microscopic examination**

Pus cells	1-2	/HPF	10-11
R.B.C.	NIL	/HPF	NIL
Ova	ABSENT		NIL
Cysts	NIL		NIL
Bacteria	PRESENT	/HPF	NIL
Others	NIL		

\*\*\* End Of Report \*\*\*

Checked By.

Dr. NITIN AGARWAL  
MBBS, MD (PATH)  
DMC/R/01490  
DR. NITIN AGARWAL  
MBBS, MD (PATHOLOGIST)

47, Harsh Vihar, Pitampura, New Delhi-110034 | Ph.: 011-42480101, 9599913051

E-mail: [oneplusul@gmail.com](mailto:oneplusul@gmail.com) | Web.: [www.oneplusul.in](http://www.oneplusul.in)

Page 7 of 7



**OnePLUS**  
Ultrasound Lab  
— QUALITY FIRST... ALWAYS! —

**Dr. Nitin Agarwal**  
Pathologist & Director  
Ex. Sr. Res. MAMC  
& Lok Nayak Hospital  
Ex. Chief of Lab Dr. Lal Path Labs.

**Dr. Pooja (Garg) Agarwal**  
Radiologist & Director  
MAMC & Lok Nayak Hospital

<b>Name</b>	: Mrs. NEHA KUMARI	<b>Age/Sex</b>	: 33 YRS/Female
<b>Ref. By</b>	: Dr. MEDIWHEEL	<b>Lab No</b>	: 012303250007
<b>Date</b>	: 25-Mar-2023	<b>Patient ID</b>	: LSHHI111314

### ULTRASOUND EXAMINATION----WHOLE ABDOMEN

**Liver** is normal in size and outline with normal echopattern. No abscess or mass lesion seen. Hepatic veins, portal vein, IVC and aorta are normal. Intrahepatic biliary radicles are not dilated. CBD is normal in caliber.

**Gall bladder** is well distended with anechoic lumen. Wall thickness is normal.

**Both kidneys** are normal in size, shape, position, outline and echopattern. Corticomedullary differentiation is maintained. No pelvicalyceal dilation or calculus or mass lesion is seen.

**Spleen** is normal in size and echotexture. No mass lesion seen.

**Pancreas** is normal in size, outline and echotexture.

**Urinary bladder** is minimally distended (patient cannot hold urine further). It is grossly normal. However suboptimal pelvic evaluation is possible transabdominally.

**Uterus** is normal in size, shape, position and echopattern. No mass seen.

**Uterine cavity** is empty. **Endometrial thickness** is 8.0 mm.

No adnexal mass is seen on either side.

No abnormal bowel wall thickening seen in right iliac fossa.  
No free fluid seen anywhere in abdomen.

**Please correlate clinically**

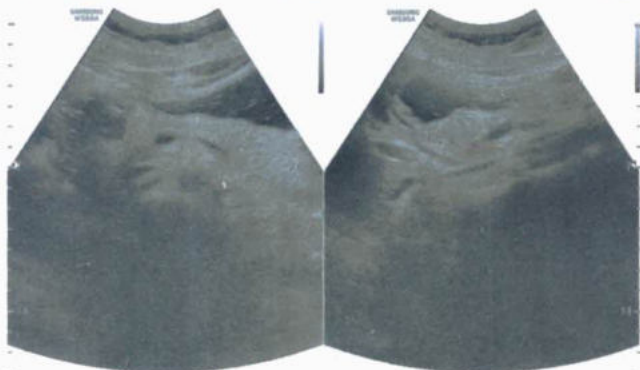
**Dr. POOJA GARG**  
M.B.B.S., D.M.B.D.  
Reg No. DMC/R/03398  
Radiologist  
**DR. POOJA GARG**  
RADIOLOGIST  
REG NO- DMC/R/03398

Type By : darshita

47, Harsh Vihar, Pitampura, New Delhi-110034 | Ph.: 011-42480101, 9599913051  
E-mail: oneplusul@gmail.com | Web.: www.oneplusul.in

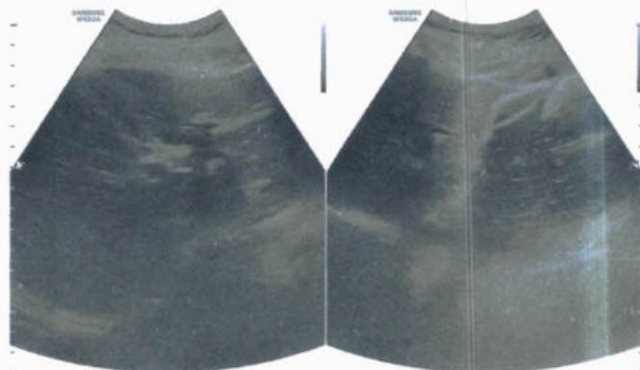W500A MRS NEHA 33/F OnePlus Ultrasound Lab MI 1.4 25-03-2023  
CA1-7A / Abdomen / FR 24Hz Tis 0.1 10:45:17 AM

20 G67 DR135-FAB P90 Frq Gen. 17.0cm 53% 50



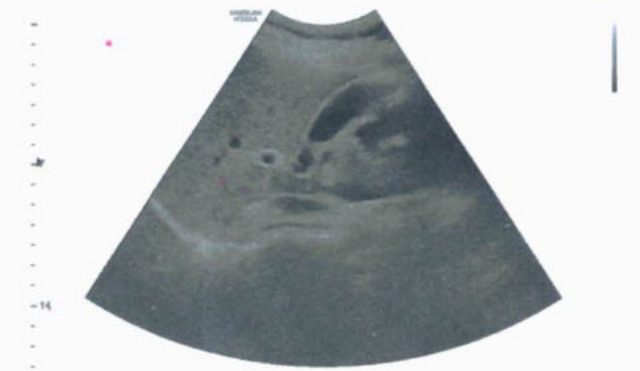W500A MRS NEHA 33/F OnePlus Ultrasound Lab MI 1.4 25-03-2023  
CA1-7A / Abdomen / FR 24Hz Tis 0.1 10:45:27 AM

20 G68 DR135-FAB P90 Frq Gen. 17.0cm 53% 50



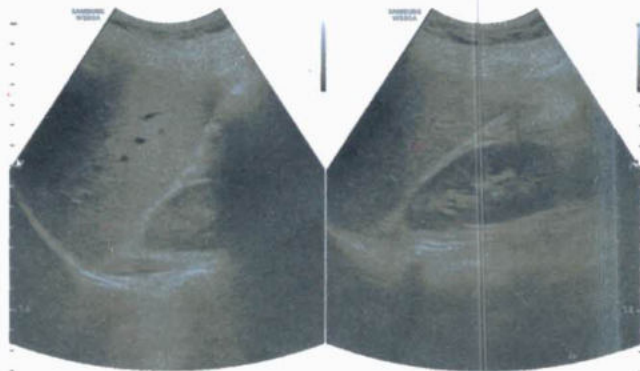W500A MRS NEHA 33/F OnePlus Ultrasound Lab MI 1.4 25-03-2023  
CA1-7A / Abdomen / FR 24Hz Tis 0.1 10:45:34 AM

20 G72 DR135-FAB P90 Frq Gen. 17.0cm 53% 50



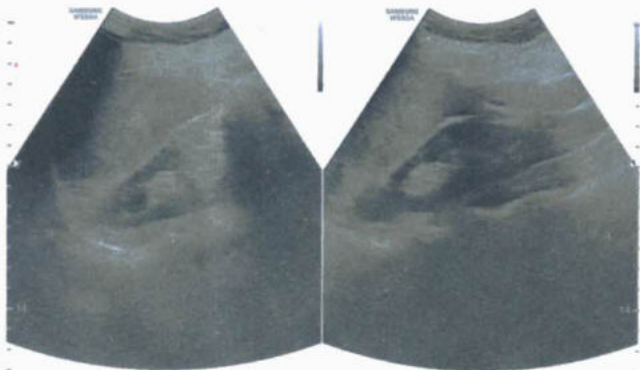W500A MRS NEHA 33/F OnePlus Ultrasound Lab MI 1.4 25-03-2023  
CA1-7A / Abdomen / FR 24Hz Tis 0.1 10:45:56 AM

20 G72 DR135-FAB P90 Frq Gen. 17.0cm 53% 50



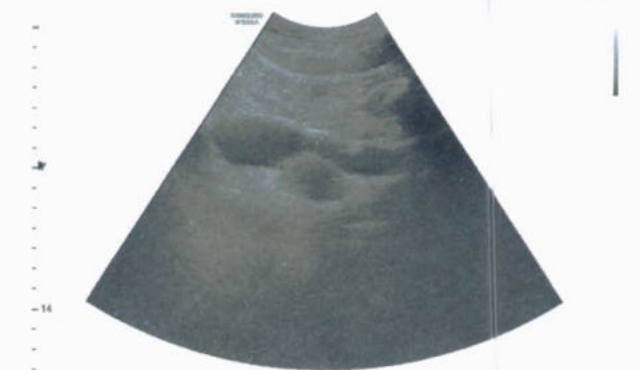W500A MRS NEHA 33/F OnePlus Ultrasound Lab MI 1.4 25-03-2023  
CA1-7A / Abdomen / FR 24Hz Tis 0.1 10:46:12 AM

20 G72 DR135-FAB P90 Frq Gen. 17.0cm 53% 50



W500A MRS NEHA 33/F OnePlus Ultrasound Lab MI 1.4 25-03-2023  
CA1-7A / Abdomen / FR 24Hz Tis 0.1 10:46:39 AM

20 G74 DR135-FAB P90 Frq Gen. 17.0cm 53% 50



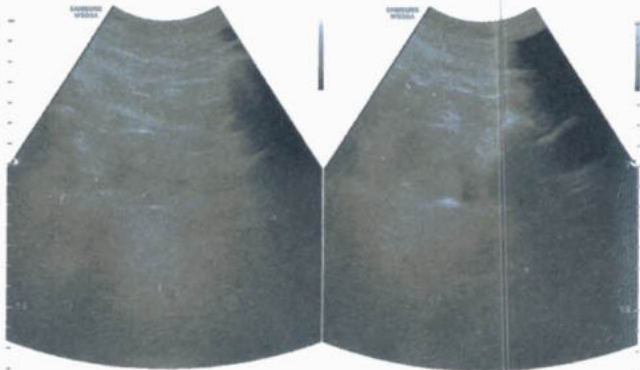W500A MRS NEHA 33/F OnePlus Ultrasound Lab MI 1.4 25-03-2023  
CA1-7A / Abdomen / FR 24Hz Tis 0.1 10:46:55 AM

20 G74 DR135-FAB P90 Frq Gen. 17.0cm 53% 50



W500A MRS NEHA 33/F OnePlus Ultrasound Lab MI 1.4 25-03-2023  
CA1-7A / Abdomen / FR 24Hz Tis 0.1 10:47:04 AM

20 G74 DR135-FAB P90 Frq Gen. 17.0cm 53% 50









**OnePLUS**  
Ultrasound Lab  
— QUALITY FIRST... ALWAYS! —

**Dr. Nitin Agarwal**  
Pathologist & Director  
Ex. Sr. Res. MAMC  
& Lok Nayak Hospital  
Ex. Chief of Lab Dr. Lal Path Labs.

**Dr. Pooja (Garg) Agarwal**  
Radiologist & Director  
MAMC & Lok Nayak Hospital

Name	: Mrs. NEHA KUMARI	Age/Sex	: 33 YRS/Female
Ref. By	: Dr. MEDIWHEEL	Lab No	: 012303250007
Date	: 25-Mar-2023	Patient ID	: LSHHI111314

### X-ray-Chest PA view

Bony cage and soft tissues are normal.  
Cardiothoracic ratio is normal.  
Mediastinum is normal.  
Both hila are normal.  
Both costophrenic angles are clear.  
Both domes of diaphragm are normal.  
Lung fields are clear. No parenchymal lesion seen.

**IMPRESSION: Normal Study.**

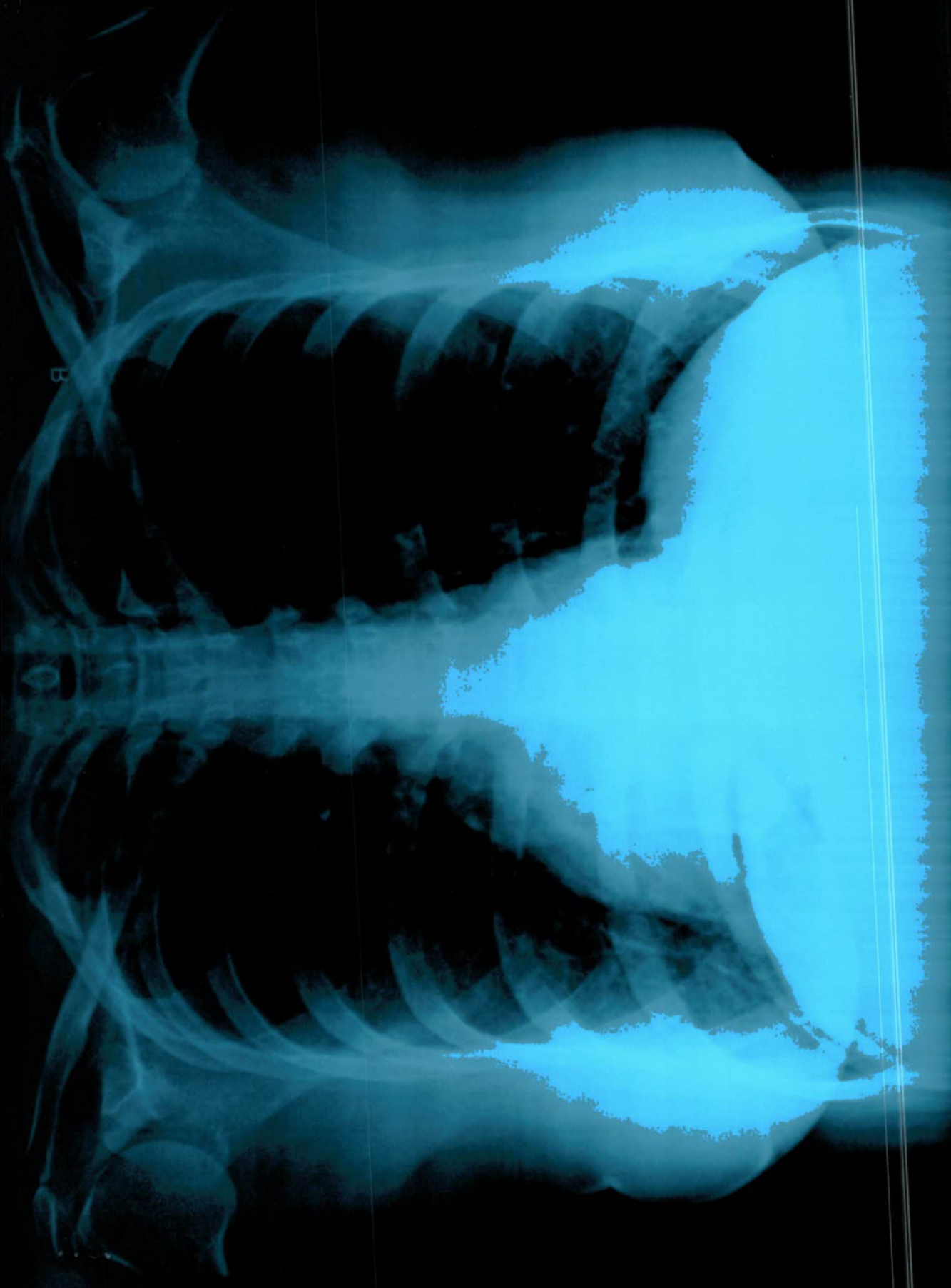
Dr. POOJA GARG  
M.B.B.S., D.M.R.D.  
RADIOLOGIST  
Reg No. DMC/R/03398  
REG NO- DMC/R/03398  
Radiologist

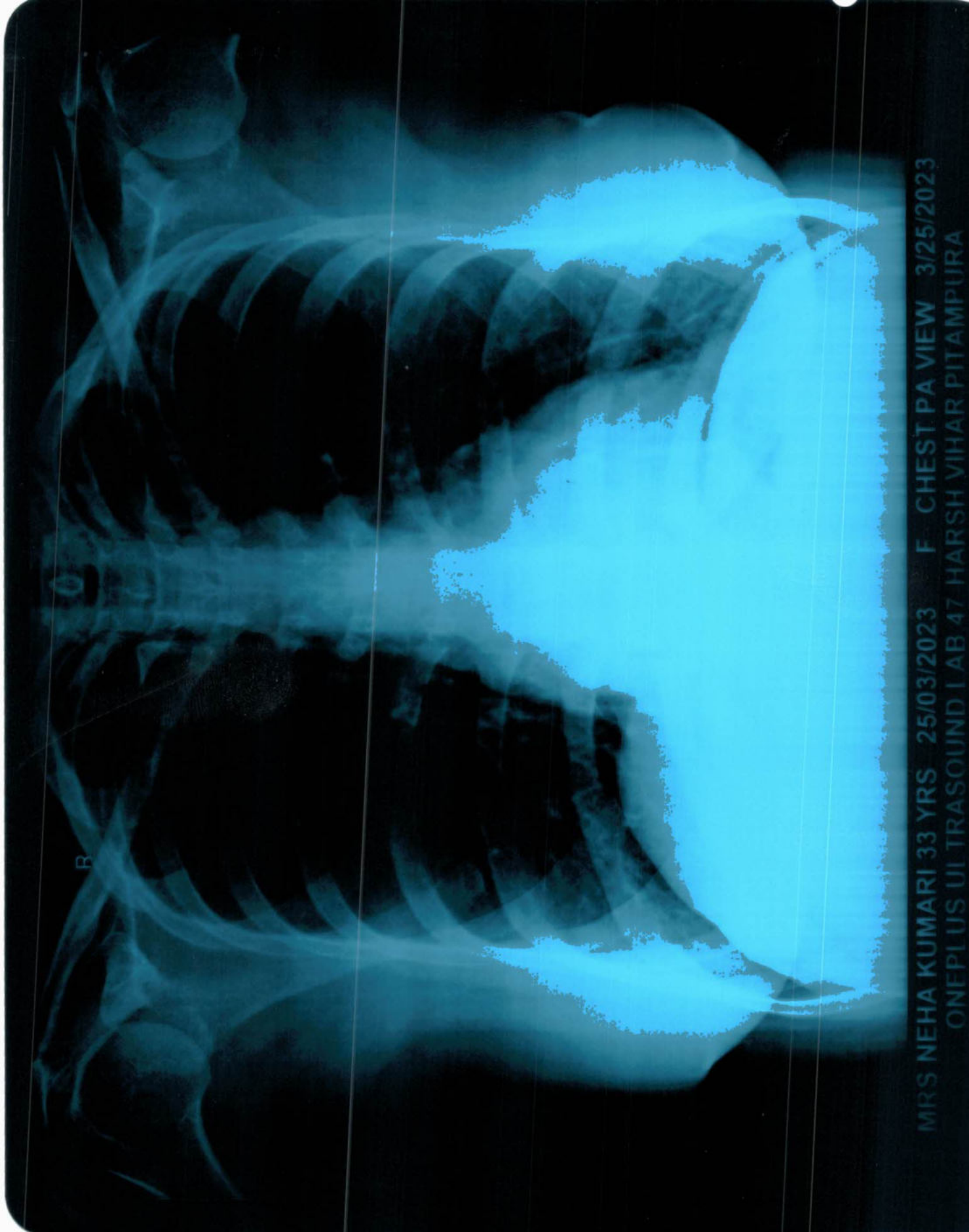
Type By : darshita

47, Harsh Vihar, Pitampura, New Delhi-110034 | Ph.: 011-42480101, 9599913051

E-mail: [oneplusul@gmail.com](mailto:oneplusul@gmail.com) | Web.: [www.oneplusul.in](http://www.oneplusul.in)

DR. P. US. M. TRASOUND I. ABA, HARSH AHWAR PITALMURU  
MRS. NEHA KUMARI 33 YRS. SP103/5053 F. CHEST PA VIEW 315215053





R

0

MRS NEHA KUMARI 33 YRS 25/03/2023 F CHEST PA VIEW 3/25/2023  
ONEPLUS UI TRASOUND LAB 47 HARSH VIHAR PITAMPURA