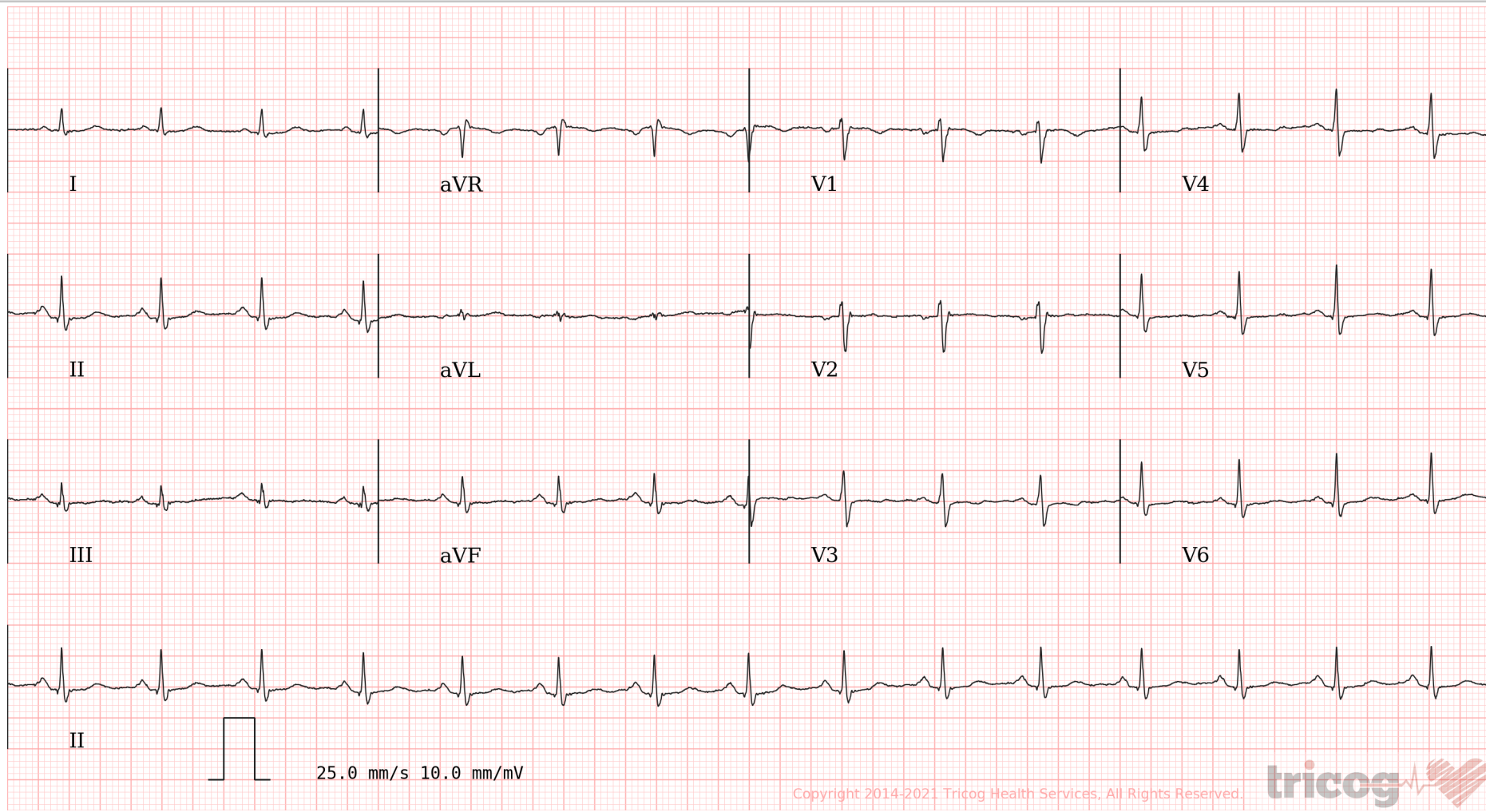


Patient Name: RUCHIKA BAKSHI

Date and Time: 30th Jul 21 9:30 AM

Patient ID: 2120214345



Age **29** **5** **2**  
years months days

Gender **Female**

Heart Rate **95 bpm**

**Patient Vitals**

BP: 110/80 mmHg

Weight: 63 kg

Height: 166 cm

Pulse: 95 bpm

Spo2: NA

Resp: NA

Others: \_\_\_\_\_

**Measurements**

QSRD: 84 ms


QT: 348 ms

QTc: 437 ms

PR: 140 ms

P-R-T: 69° 53° 54°

Copyright 2014-2021 Tricog Health Services, All Rights Reserved.



Sinus Rhythm, Normal Axis, Low Voltage QRS, Nonspecific T wave Abnormality. Adv: Clinical Correlation, 2D ECHO. Please correlate clinically.

REPORTED BY

*Adrita Banerjee*

Dr. Adrita Banerjee  
MBBS, MD (Medicine)

Reg.G-54078