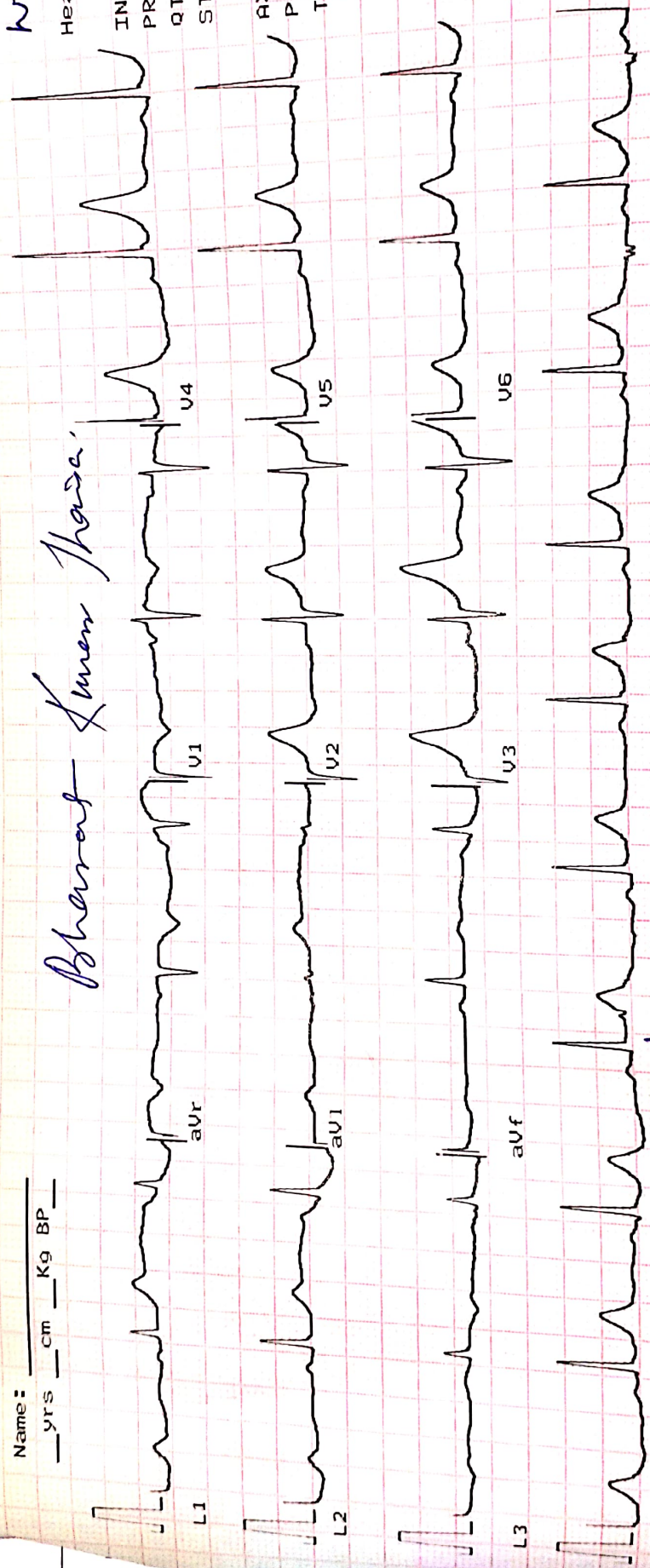


Name: _____
_ yrs _ cm _ Kg BP _____

Bharat Kumar Thapa

Heart Rate : 66 bpm
INTERVAL (ms)
PR: 147 QRS: 47
QT: 600 QTC: 635
ST: 40
AXIS (deg)
P : 60 QRS: 45
T : 22



23/01/20

Ver 10mm/mV Time:
1.9 25mm/sec Date:

Maestros



Heart & General Clinic

iCure Heart & Diet Clinic, 402, Epsilon tower, opp Pasha bhai park, Race course, Vadodara

:: PERSONAL HEALTH REPORT ::

NAME <u>Bharat kumars Jheriya.</u>	DATE <u>23/04/22</u>
	SR. NO. SEX. <u>male</u> AGE HEIGHT <u>173 cm.</u> WEIGHT <u>73 kg.</u>

HISTORY

Present History : NO
 Past Illness History : NO Diabetes/Hypertension/Tuberculosis/Asthma/Epilepsy
 Past Occupational History : NO
 Family History : Father - Hypertension
 Personal History : Person was operated for knee surgery in 2015
 Addiction : NO Tobacco/Gutkha/Smoking/Alcohol

GENERAL EXAMINATION

T.P.R. : 66/min B.P. : 130/90 mm Hg :
 Pallor/Icterus/Cyanosis/Varicosity/Lymph Nodes/Thyroid/Oedema/NVE/Other :

SYSTEMIC EXAMINATION

R.S. :
 C.V.S. :
 C.N.S. :
 A.S. :
 Musculo-skelet System :
] NAD

E.N.T. Ex. Dental Ex. Skin Ex. Psychic Ex.] <u>NAD</u>	ACUITY OF VISION		RT EYE	LT EYE
		Without Glass	DISTANT	6/	6/
			Near	6/	6/
		With Glass	DISTANT	6/ 6	6/ 6
Near	6/ 6		6/ 6		
COLOUR BLINDNESS					

REMARK

ADVICE

The Worker is FIT/UNFIT for the assigned job.



Dr. Krish P. Vaidya
 MBBS
 MD, DR. KRISH VAIDYA - Cardiology
 Reg. No. C 19510
 MD G-50510, CH



भारत सरकार
Government of India



Issue Date: 22/03/2013




भारत कुमार झरिया
Bharat Kumar Jharía
जन्म तिथि/DOB: 20/09/1982
पुरुष/ MALE

7950 3747 2087

VID : 9104 3799 4039 6695

मेरा आधार, मेरी पहचान

[Handwritten signature]



2D Echocardiography & Color Doppler Report

iCure Hear care, 402, Epsilon tower, opp Pasha bhai park, Race course, Vadodara

Patient Name: Mr Bharat Jhariya

Date: 23 / 04 / 2022

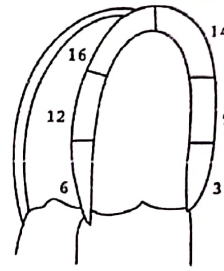
Age, Gender: male - 39 Years

M. Mode Study:

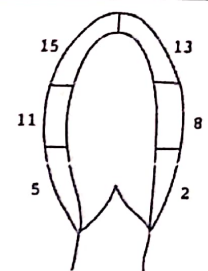
LA	30	IVS	08	PWD	09
AO	25	LVDs	27	LVDd	44

Doppler Study:

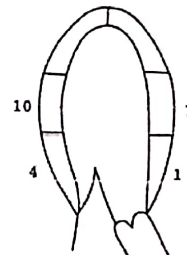
Mitral Valve	E: 1.42 A: 0.62
Aortic Valve	1.01
Tricuspid Valve	0.85
Pulmonary Valve	1.22



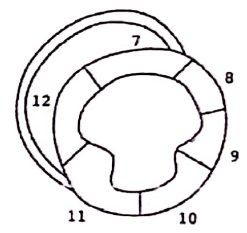
Apical
4 chamber view



Apical
2 chamber view



Apical
3 chamber view



Parasternal short
axis view

Conclusion:

- Normal LV Systolic function
- LVEF: 60 % ,No RWMA
- Cardiac Chambers: Normal
- Diastolic function: Normal
- TR: No PAH: No , RVSP: 11 mmhg
- No MR/MS
- No AR , No AS
- ASD/VSD/PDA/Co-A : No
- No Clots or vegetations found
- IVC: Normal



Dr. Krish P. Vaidya
MD, FCDC
Associate Consultant-Cardiology
Reg.No.G-50510

Dr. Krish P Vaidya

Consultant Cardiologist, Diabetologist
& General Physician

Note:

Normal 2D echo report does not rule out cardiac diseases
this report shall not be used for Medico legal purposes,
Clinical Correlation advisable.



JKV LABORATORY



FF-5, Pancham Elite, Khodiyar Nagar, New V.I.P. Road, Vadodara-390 022.
8320343731 / 9601969303M jkvlaboratory2021@gmail.com

Patient's Name : BHARATKUMAR JHARIA
Referred by : I Cure Heart & Diet Clinic
Date : 23/04/2022 16:08

Ref. No. : 1682
Age : 39 Years
Sex : Male

HBA1C [Glycosylated Haemoglobin]

Test Name	Result	Units	Biological Reference Interval
Glycosylated Haemoglobin : (HBA1C)	5.2	%	Excellent control: 4.2-6.2 Good Control : 6.3-7.2 Fair Control : 7.3-8.2 Poor Control : >8.3
Estimated Average glucose :	102.54	mg/dl	

Comment : *As per the new 2009 update of American Diabetes Association regarding HbA1C & Mean Blood Glucose relationship.

NOTE: This test is used to monitor diabetic patients compliance with the therapeutic regimen and long term blood glucose control. It's level is proportional to both the average blood glucose concentration and the life span of the red blood cells (RBC) in circulation. HbA1c values are free of day to day glucose fluctuations and are unaffected by exercise or recent food intake.


DR. K. K. PATEL
Reg. No. 93327
MD (G-20476)
CONSULTANT PATHOLOGIST
(Pathologist)



JKV LABORATORY



FF-5, Pancham Elite, Khodiyar Nagar, New V.I.P. Road, Vadodara-390 022.
8320343731 / 9601969303M jkvlaboratory2021@gmail.com

Patient's Name : BHARATKUMAR JHARIA
Referred by : I Cure Heart & Diet Clinic
Date : 23/04/2022 16:08

Ref. No. : 1682
Age : 39 Years
Sex : Male

LIVER FUNCTION TEST

Test Name	Result	Units	Biological Reference Interval
S.G.P.T. (ALT) :	26.0	U/L	30- 65
S.G.O.T. (AST) :	20.0	IU/L	[Female: 0 - 31] [Male: 0 - 35]
S. Alkaline Phosphatase :	91	IU/L	[upto 15 yrs Female 50-162] [>20 yrs Female 42 - 141] [>20 yrs Male 53 - 119]
S. Bilirubin (Total) :	1.06	mg/dl	[0.1 to 1.2]
S. Bilirubin (Direct) :	0.31	mg/dl	[0.0 to 0.3]
S. Bilirubin (Indirect) :	0.75	mg/dl	[0.0 to 0.9]
S. Proteins: (Total) :	7.60	gm/dl	[6.6 to 8.8]
S. Albumin :	4.22	gm/dl	[3.5 to 5.2]
S. Globulin :	3.38	gm/dl	[2.5 to 3.0]
A/G Ratio :	1.2		
G.G.T. : (Gamma-Glutamyl Transferase)	38.0	IU/L	[8 to 78]

DR K K PATEL
Reg. No. 23327
CONSULTANT PATHOLOGIST
(Pathologist)



JKV LABORATORY

FF-5, Pancham Elite, Khodiyar Nagar, New V.I.P. Road, Vadodara-390 022.
8320343731 / 9601969303M jkvlaboratory2021@gmail.com



Patient's Name : BHARATKUMAR JHARIA
Referred by : I Cure Heart & Diet Clinic
Date : 23/04/2022 16:08

Ref. No. : 1682
Age : 39 Years
Sex : Male


LIPID PROFILE

Test Name	Result	Units	Biological Reference Interval
Cholesterol :	<u>210.6</u>	mg/dl	Desirable level/low risk : < 200 Borderline level/moderate risk : 200-250 Elevated level/ high risk : > 250
Triglyceride :	134.5	mg/dl	Normal : <150 Borderline high :150-200 High : > 200
HDL Cholesterol :	48.9	mg/dl	Desirable level/low risk : >60 Borderline level/moderate risk : 35-60 Elevated level/ high risk : <35
LDL Cholesterol :	134.8	mg/dl	Desirable level/low risk : <130 Borderline level/moderate risk : 130-159 Elevated level/ high risk : >159
VLDL :	26.9	mg/dl	Upto 34
Chol./HDL Ratio :	4.3		
LDL/HDL Ratio :	2.8		Desirable level/low risk : 0.5-3.0 Borderline level/moderate risk : 3.0-6.0 Elevated level/ high risk : >6.0
Total Lipids :	755.7	mg/dl	400 - 1000

DR K K PATEL

MD (G-20476)

CONSULTANT PATHOLOGIST





JKV LABORATORY

FF-5, Pancham Elite, Khodiyar Nagar, New V.I.P. Road, Vadodara-390 022.
8320343731 / 9601969303M jkvlaboratory2021@gmail.com



Patient's Name : BHARATKUMAR JHARIA
Referred by : I Cure Heart & Diet Clinic
Date : 23/04/2022 16:08

Ref. No. : 1682
Age : 39 Years
Sex : Male

HEMOGRAM

Test Name	Result	Units	Biological Reference Interval
Hemoglobin :	13.4	g/dl	[13.0-18.0]
Total RBC Count :	4.49	mill/cmm	[4.7-6.0]
<u>Blood Indices</u>			
P.C.V :	39.6	%	[42-52]
M.C.V. :	88.2	femtolitre	[78-100]
M.C.H. :	29.84	pg	[27-31]
M.C.H.C. :	33.8	g/dl	[32-36]
R.D.W. :	12.9	%	[11.5-14.0]
Total WBC Count :	6510	/cmm	[4000-10000]
Platelet Count :	239000	/cmm	150000-450000
<u>Differential WBC Count</u>			
Polymorphs :	63	%	[60 - 70]
Lymphocytes :	30	%	[20 - 40]
Eosinophils :	03	%	[1 - 4]
Monocytes :	04	%	[2 - 6]
Basophils :	00	%	[0 - 1]
MPV :	11.2		
PDW-CV :	13.3		
PDW-SD :	14.3		
PCT :	0.26		
P-LCR :	36.2		
<u>Erythrocyte Sedimentation Rate</u> [Modified Westergren]			
After 1 hour :	05	mm	[M: 1 - 7 / F: 3 - 12]

DR K K PATEL

MD (G-20476)

CONSULTANT PATHOLOGIST



JKV LABORATORY



Name : BHARATKUMAR JHARIA
Ref By : ICURE HEART & DIET CLINIC

Age/Sex : 39 Yrs./M
Date : 23/04/2022
Report ID. : 13

EXAMINATION OF URINE

<u>TEST</u>	<u>RESULT</u>	<u>UNIT</u>
Sample	: FASTING	
<u>PHYSICAL EXAMINATION</u>		
Quantity	: 10	mL
Colour	: YELLOW	
Transperancy	: CLEAR	
Specific Gravity	: 1.030	
Reaction	: ACIDIC	
Deposits	: ABSENT	
<u>CHEMICAL EXAMINATION</u>		
Albumin	: NIL	
Sugar	: NIL	
Acetone	: ABSENT	
Bile Salts	: ABSENT	
Bile Pigments	: ABSENT	
Urobilinogen	: NORMAL : ~ < 1.0 mg/dL	
Occult Blood	: ABSENT	
Nitrate	: ABSENT	
<u>MICROSCOPIC EXAMINATION</u>		
Pus Cells	: 0-1 / hpf	
RBC	: NIL	
Epithelial Cells	: NIL	
Crystals	: NIL	
Amorphous Phosphate	: NIL	
Cast	: NIL	

END OF REPORT

DR JIGAR SHAH (G23327)
M.D. Pathologist

Time : 7 a.m. to 9.00 p.m. ● Emergency 24 Hrs.



JKV LABORATORY



Name : BHARATKUMAR JHARIA
Ref By : ICURE HEART & DIET CLINIC

Age/Sex : 39 Yrs./M
Date : 23/04/2022
Report ID. : 13

HAEMOGRAM PROFILE

TEST

RESULT

Blood Group : " B "
Rh Factor : " POSITIVE "
(Anti D.)

BIOCHEMISTRY

FASTING (FBS)

Blood Glucose : 86.0 mg/dL 70 - 110 mg/dL

POST-PRANDIAL

Blood Glucose : 103.0 mg/dL 80 - 140 mg/dL

Done By Fully Auto Analyzer MIURA, A-1004

END OF REPORT

DR JIGAR SHAH (G23327)
M.D. Pathologist

Time : 7 a.m. to 9.00 p.m. ● Emergency 24 Hrs.

FF-5, Pancham Elite, Khodiyar Nagar, New V.I.P. Road, Vadodara-390 022.

☎ 8320343731 / 9601969303 ✉ jkvlaboratory2021@gmail.com

Test Report are subject to technical limitations & should be clinically correlated. Laboratory may be contacted whenever required.

Free Home Service


Heart & General Clinic

iCure Heart & Diet Clinic, 402, Epsilon tower, opp Pasha bhai park, Race course, Vadodara

NAME : BHARATKUMAR JHARIA	AGE: 39 Y/M	DATE : 23/04/2022
---------------------------	-------------	-------------------

ULTRASOUND WHOLE ABDOMEN
(Screening Only)

Liver is normal in size and shows normal parenchymal reflectivity. No focal lesion is seen. Hepatic veins appear normal. There is no evidence of any dilated intra hepatic biliary radicals.

Portal Vein appears normal in diameter. **Common Bile Duct** is of normal diameter.

Gallbladder is distended with normal wall thickness. There is no evidence of gallstones. No evidence of peri-cholecystic fluid or probe tenderness.

Pancreas is normal in size and shows homogenous reflectivity. There is no evidence of any calcification or ductal dilatation.

Spleen is normal size and shows a homogenous echotexture. There is no evidence of any focal lesion.

Both Kidneys are normal in position and size. They show normal cortical reflectivity and cortico-medullary distinction. Right kidney measures 103x36mm. Left kidney measures 100x45mm. There is no evidence of renal calculi, hydronephrosis or mass seen.

Bladder is well distended and shows normal wall thickness. No evidence of intra-luminal mass or calculi.

Prostate gland is normal in size. It has smooth outlines and normal reflectivity.

There is no evidence of ascites.

No evidence of any gross bowel mass seen.

No evidence of any aorto-caval or mesenteric root lymphadenopathy.

Appendix cannot be imaged. No mass or collection in right iliac fossa.

CONCLUSION: No sonographic abnormality is seen.



DR. MEHUL PRAJAPATI
CONSULTANT RADIOLOGIST




Heart & General Clinic

iCure Heart & Diet Clinic, 402, Epsilon tower, opp Pasha bhai park, Race course, Vadodara

NAME : BHARATKUMAR JHARIA	AGE : 39 Y/M	DATE : 23/04/2022
---------------------------	--------------	-------------------

X RAY CHEST (PA)

OBSERVATIONS:

Both the lung fields and apices appear clear.
Both the hilar shadow appears normal.
Cardiac silhouette appears normal.
Both the costophrenic sinuses are clear.
Mediastinal and tracheal shadows are normal.
Both the domes of diaphragm are normal.
Visualized rib cage and right clavicle are normal.
Old fracture at left clavicle

COMMENTS:

- **No significant abnormality is seen.**



Mehul Prajapati

**DR. MEHUL PRAJAPATI
CONSULTANT RADIOLOGIST**



J K V LABORATORY



FF-5, Pancham Elite, Khodiyar Nagar, New V.I.P. Road, Vadodara-390 022.
8320343731 / 9601969303M jkvlaboratory2021@gmail.com

Patient's Name : BHARATKUMAR JHARIA
Referred by : I Cure Heart & Diet Clinic
Date : 23/04/2022 21:59

Ref. No. : 1682
Age : 39 Years
Sex : Male

THYROID FUNCTION TEST

Test Name	Result	Units	Biological Reference Interval
Serum T3 :	0.68	ng/ml	[0.60 - 1.81]
Serum T4 :	6.91	µg/dl	[4.50 - 12.6]
Serum TSH : (CHEMILUMINESCENCE)	1.338	µIU/ml	[0.55 - 4.78]

Thyroid stimulating hormone (TSH) is synthesized and secreted by the anterior pituitary in response to a negative feedback mechanism involving concentrations of FT3 (free T3) and FT4 (free T4). Additionally, the hypothalamic tripeptide, thyrotropin-releasing hormone (TRH), directly stimulates TSH production. TSH stimulates thyroid cell production and hypertrophy, also stimulate the thyroid gland to synthesize and secrete T3 and T4.

Quantification of TSH is significant to differentiate primary (thyroid) from secondary (pituitary) and tertiary (hypothalamus) hypothyroidism. In primary hypothyroidism, TSH levels are significantly elevated, while in secondary and tertiary hypothyroidism, TSH levels are low.

TSH levels During Pregnancy :

- First Trimester : 0.1 to 2.5 µIU/mL
- Second Trimester : 0.2 to 3.0 µIU/mL
- Third trimester : 0.3 to 3.0 µIU/mL

Reference : Carl A.Burtis,Edward R.Ashwood,David E.Bruns. Tietz Textbook of Clinical Chemistry and Molecular Diagnostics. 5th Edition. Philadelphia: WB Saunders,2012:2170


DR. K. K. PATEL
 MD (G-20476)
 G-23327
 CONSULTANT PATHOLOGIST
 M.D. (Pathology)



JKV LABORATORY



FF-5, Pancham Elite, Khodiyar Nagar, New V.I.P. Road, Vadodara-390 022.
8320343731 / 9601969303 | jkvlaboratory2021@gmail.com

Patient's Name : BHARATKUMAR JHARIA
Referred by : I Cure Heart & Diet Clinic
Date : 23/04/2022 21:59

Ref. No. : 1682
Age : 39 Years
Sex : Male

BIOCHEMICAL TESTS

Test Name	Result	Units	Biological Reference Interval
Blood Urea :	30.1	mg/dl	10 - 50
Creatinine :	1.03	mg/dl	0.4 - 1.5
Blood Urea Nitrogen :	14	mg/dl	0 - 18
Uric Acid :	5.01	mg/dl	3.4 - 7.0


DR K K PATEL
MD (G-20476)
CONSULTANT PATHOLOGIST
D. (Pathology)