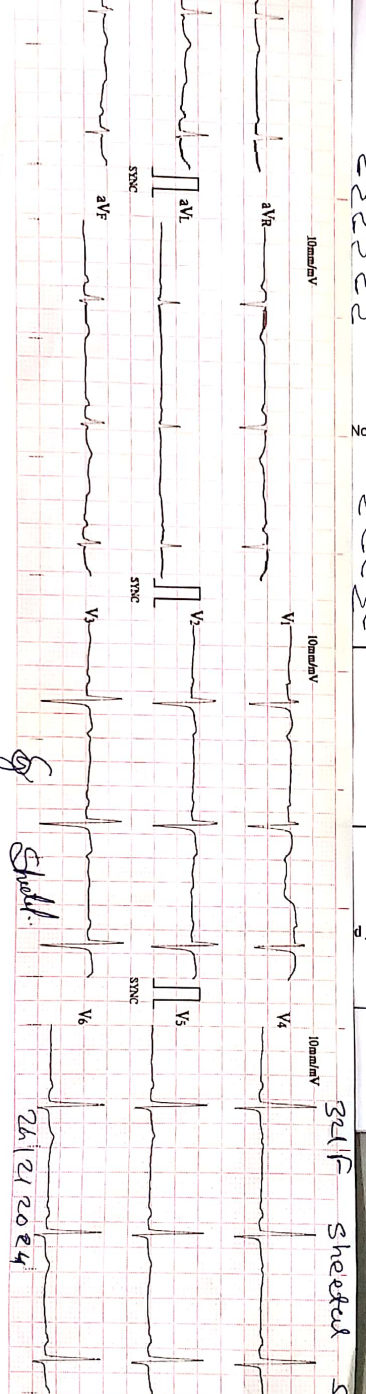


Standard 12-lead ECG  
 I II III  
 aVR aVL aVF  
 V1 V2 V3 V4 V5 V6



HR : 64 bpm  
 RR : 927 ms  
 P-R : 176 ms  
 QRS : 94 ms  
 QT/QTc : 377/391 ms  
 P/QRS/T : 62/36/54 ms  
 HV3/SV1 : 1.190/0.830 mV  
 RV3-SV1 : 2.010 mV

Unconfirmed Report Verified by: \_\_\_\_\_

Dr. P. Vaidya  
 Associate Consultant-Cardiology  
 Reg.No. G-50510



# Heart & General Clinic

Icure Heart & Diet Clinic, 402, Epsilon tower, opp Pasha bhai park, Race course, Vadodar

## :: PERSONAL HEALTH REPORT ::

Sheetal Sosa		V 24/2/2024
		SR. NO. SEX. Female AGE 32 years HEIGHT 154 cm WEIGHT 58 kg.

### HISTORY

Present History : No  
 Past Illness History : No Diabetes/Hypertension/Tuberculosis/Asthma/Epilepsy  
 Past Occupational History : No  
 Family History : No  
 Personal History : No  
 Addiction : No Tobacco/Gutkha/Smoking/Alcohol

### GENERAL EXAMINATION

T.P.R. : 68/min B.P. : 120/80 mm Hg  
 Pallor/Icterus/Cyanosis/Varicosity/Lymph Nodes/Thyroid/Oedema/NVE/Other :

### SYSTEMIC EXAMINATION

R.S. : NAD  
 C.V.S : NAD  
 C.N.S : NAD  
 A.S. : NAD  
 Musculo-skelet System : NAD

E.N.T. Ex.	NAD	ACUITY OF VISION		RT EYE	LT EYE
		Without Glass	DISTANT	6/	6/
Dental Ex.	NAD	With Glass	DISTANT	6/ 6	6/ 6
		Near	Near	6/ 6	6/ 6
Skin Ex.	NAD	COLOUR BLINDNESS			
Psychic Ex.	NAD	NAD			

### REMARK

### ADVICE

The Worker is FIT/UNFIT for the assigned job.



Dr. Krish P. Vaidya  
 MD, PCC  
 Associate Consultant-Cardiology  
 Reg. No. G-50510  
 DR. KRISH VAIDYA

MD G-50510, CIH



ભારતીય વિશિષ્ટ ઓળખાણ પ્રાધિકરણ

ભારત સરકાર  
Unique Identification Authority of India  
Government of India

નોંધણીની ઓળખ / Enrollment No.: 1308/00313/86825

To  
સોસા શીતલ  
Sosa Sheetal  
D/O: Gircharbhai  
68, omkar Society-2 weir cum causeway road  
near D mart singarpore  
Surat City  
Katarpam  
Surat City Surat  
Gujarat 395004  
7405075178

12/12/2013

88508357



MN855063678FT



તમારો આધાર નંબર / Your Aadhaar No. :

**7559 6232 3154**

આધાર - સામાન્ય માણસનો અધિકાર



ભારત સરકાર

Government of India

સોસા શીતલ  
Sosa Sheetal  
જન્મ તારીખ / DOB : 16/03/1991  
સ્ત્રી / Female



**7559 6232 3154**



આધાર - સામાન્ય માણસનો અધિકાર



Sheetal.



**301 Trivia complex, near Natubhai circle, Racecourse Road**

**Name** : SHEETAL SOSA  
**Ref By** : ICURE HEART & DIET CLINIC

**Age/Sex** : 32 Yrs./F  
**Date** : 24/02/2024  
**Report ID.** : 4

**HAEMOGRAM PROFILE**

<u>TEST</u>	<u>RESULT</u>	<u>UNIT</u>	<u>METHOD</u>	<u>REFERENCE INTERVAL</u>
<b><u>BLOOD COUNTS &amp; INDICES</u></b>				
Haemoglobin	: 12.90	gm%		12.0 - 16.0 gm%
Total RBC	: 4.79	mill/cmm		4.2 - 5.4 mill/cmm
PCV	: 45.00	%		37 - 47 %
MCV	: 93.94	fL		80 - 96 fL
MCH	: <b>26.93</b>	pg		27 - 31 pg
MCHC	: <b>28.66</b>	%		32 - 36 %
RDW	: 13.00	%		10 - 15 %
Total WBC	: 7,100	/cmm		4,000 - 11,000/cmm
Platelet Count	: 2,98,000	/cmm		1.5 - 4.0 Lac/cmm.
<b><u>DIFFERENTIAL LEUCOCYTES COUNT</u></b>				
Band Cells	: 00	%		00 - 06 %
Neutrophils	: 60	%		55 - 70 %
Lymphocytes	: 39	%		20 - 40 %
Eosinophils	: <b>00</b>	%		01 - 06 %
Monocytes	: <b>01</b>	%		02 - 08 %
Basophils	: 00	%		00 - 01 %
Platelet In Smear	: ADEQUATE			
<b><u>ERYTHROCYTES SEDIMENTATION RATE</u></b>				
ESR After 1st Hour	: <b>22</b>	mm	Westergren	03 - 12 mm
Blood Group	: " B "			
Rh Factor (Anti D.)	: " POSITIVE "			

*(By Fully Automated Cell Counter Sysmex KX - 21, Japan)*

END OF REPORT



**301 Trivia complex, near Natubhai circle, Racecourse Road**

**Name** : SHEETAL SOSA  
**Ref By** : ICURE HEART & DIET CLINIC

**Age/Sex** : 32 Yrs./F  
**Date** : 24/02/2024  
**Report ID.** : 4

**BIOCHEMISTRY**

<u>TEST</u>	<u>RESULT</u>	<u>UNIT</u>	<u>REFERENCE INTERVAL</u>
Blood Urea	: 17.00	mg/dL	10 - 50 mg/dL
Blood Urea Nitrogen - BUN	: 7.90	mg/dL	4.5 - 19.0 mg/dL
Serum Creatinine	: 0.61	mg/dL	0.6 - 1.4 mg/dL
Serum Uric Acid	: 4.98	mg/dL	2.4 - 5.7 mg/dL
<b><u>SERUM PROTEIN</u></b>			
Serum Protein Total	: 7.00	g/dL	6.6 - 8.3 g/dL
Albumin	: 4.20	g/dL	3.50 - 5.00 g/dL
Globulin	: 2.80	g/dL	2.3 - 3.5 g/dL
A/G Ratio	: 1.5	: 1	1.5 - 2.5 : 1
Bilirubin - Total	: 0.2	mg/dL	0.00 - 1.00 mg/dL
Bilirubin - Direct	: 0.1	mg/dL	Upto 0.30 mg/dL
Bilirubin - Indirect	: 0.1	mg/dL	0.1 - 1.0 mg/dL
SGPT	: 19.0	IU/L	10 - 40 IU/L
SGOT	: 27.0	IU/L	Upto 40 IU/L
Serum Alkaline Phosphatase	: 94.0	U/L	37 - 147 U/L
<b><u>FASTING (FBS)</u></b>			
Blood Glucose	: 98.0	mg/dL	70.00 - 110.00 mg/dL
<b><u>POST-PRANDIAL</u></b>			
Blood Glucose	: 105.0	mg/dL	80 - 140 mg/dL
<b><u>SPECIAL TESTS</u></b>			
GGT	: 18	U/L	05 - 85 U/L
Gamma Glutamyltransferase			

*Done By Fully Auto Analyzer MIURA, A-1004*

END OF REPORT

**301 Trivia complex, near Natubhai circle, Racecourse Road**

**Name** : SHEETAL SOSA  
**Ref By** : ICURE HEART & DIET CLINIC

**Age/Sex** : 32 Yrs./F  
**Date** : 24/02/2024  
**Report ID.** : 4

**LIPID PROFILE**

TEST	RESULT	UNIT	REFERENCE INTERVAL
Total Lipid (Calculated)	: 570	mg/dL	350 - 750 mg/dL
Serum Cholesterol	: 161.0	mg/dL	130 - 200 mg/dL
Serum Triglyceride	: 139.0	mg/dL	60 - 165 mg/dL
HDL Cholesterol	: 43.0	mg/dL	30 - 70 mg/dL
LDL Cholesterol	: 90.2	mg/dL	Upto 160 mg/dL
LDL Cholesterol - Direct	: 118.0	mg/dL	Upto 160 mg/dL
CHOL./HDL Chol. Ratio	: 3.74	: 1	Less than 5
LDL Chol/HDL Chol Ratio	: 2.10	: 1	Less than 3.5
VLDL (Calculated)	: 27.80	mg/dL	Upto 30 mg/dL

**Hb A1C REPORT**

Hb A1C - Glycated Hb Glycated Haemoglobin	: 6.3	%	Non Diabetic : 4.3 - 6.3 % Good Control : 6.4 - 7.5 % Moderate Control : 7.5 - 9.0 % Poor Control : 9.0 % & Above
Avg. Blood Glucose Level	: 147	mg/dL	
Estimated Average Glucose eAG	: 134	mg%	

END OF REPORT

301 Trivia complex, near Natubhai circle, Racecourse Road

**Name** : SHEETAL SOSA  
**Ref By** : ICURE HEART & DIET CLINIC

**Age/Sex** : 32 Yrs./F  
**Date** : 24/02/2024  
**Report ID.** : 4

**EXAMINATION OF URINE**

TEST	RESULT	UNIT
Sample	: FASTING	
<b><u>PHYSICAL EXAMINATION</u></b>		
Quantity	: 10	ml
Colour	: PALE YELLOW	
Transparency	: CLEAR	
Specific Gravity	: 1.030	
Reaction	: ACIDIC	
Deposits	: ABSENT	
<b><u>CHEMICAL EXAMINATION</u></b>		
Albumin	: NIL	
Sugar	: NIL	
Acetone	: ABSENT	
Bile Salts	: ABSENT	
Bile Pigments	: ABSENT	
Urobilinogen	: NORMAL : ~ < 1.0 mg/dL	
Occult Blood	: ABSENT	
Nitrate	: ABSENT	
<b><u>MICROSCOPIC EXAMINATION</u></b>		
Pus Cells	: 0-1 / hpf	
RBC	: NIL	
Epithelial Cells	: NIL	
Crystals	: NIL	
Amorphous Phosphate	: NIL	
Cast	: NIL	

**THYROID FUNCTIONS**

Total Triiodothyronine - T3	: <b>2.01</b>	ng/mL	0.58 - 1.59 ng/mL
Total Thyroxine - T4	: 8.95	ng/mL	4.87 - 11.72 microgram%
Thyroid Sti. Hormone -TSH	: 1.98	ng/mL	0.49 to 4.67 IU/mL

END OF REPORT

# Echocardiography & Color Doppler Report

Patient Name: Sheetal Sosa

Date: 24/02/2024

Age/ Gender: /female

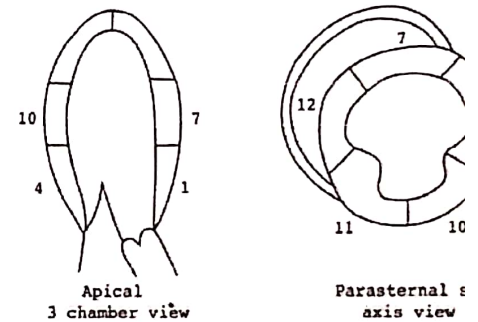
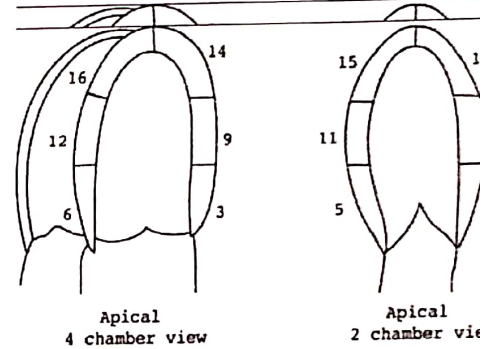
LA	37	IVS	10	PWD	10
AO	25	LVDs	32	LVDd	45

**M.**

**Mode**

**Study:**

Mitral Valve	E: 0.92 A:0.68
Aortic Valve	Normal
Tricuspid Valve	Normal
Pulmonary Valve	Normal



## Doppler Study:

## Conclusion:

- LV Function: Normal LV Systolic Function
- LVEF: 60%
- RWMA: No RWMA at Rest
- Cardiac Chambers: Normal
- Diastolic function: Normal
- TR: No PAH: No      RVSP: 23mmhg
- MR/ MS: No
- AR/ AS: No
- ASD/VSD/PDA/Co-A: No
- No clot or vegetation seen
- IVC: 12mm &>50% collapsing with Respiration







# PARAMOUNT DIAGNOSTIC & RESEARCH CENTRE

(A Unit of Paramount Charity Trust)

Radiology ■ Pathology ■ Histopathology ■ Molecular Biology

NAME : SHEETAL SOSA

AGE : 32 Y/F

DATE : 24/02/2024

## X RAY CHEST (PA)

### OBSERVATIONS:

Both the lung fields and apices appear clear.

Both the hilar shadow appears normal.

Cardiac silhouette appears normal.

Both the costophrenic sinuses are clear.

Mediastinal and tracheal shadows are normal.

Both the domes of diaphragm are normal.

Visualized rib cage and clavicle are normal.

### COMMENTS:

No significant abnormality is seen.



DR. HENY GANDHI  
CONSULTANT RADIOLOGIST



24 hours Emergency Service Available for CT Scan / MRI / Pathology AMBULANCE SERVICE AVAILABLE

Main Branch : Paramount Complex, Gotri Road, Race Course, Vadodra, Ph. : 0265-2395772, 2397438, 6647222, +91 - 9352731483,

Path. Lab : 0265 - 6603900/901/902/903, +91 - 8160225911, +91 - 9099066029

City Branch : Opp. Brahman Sabha Hall, Pratap Road, Dandlabazar, Vadodra. Ph.: 0265 - 2423233, +91 - 9352734810



# Heart & General Clinic Heart & General Clinic

icure Heart & Diet Clinic, 402 Epsilon Tower, opp. Pashabhai Park, Nr. Natubhai Circle, Race course, Vadodra, 390097  
301 Trivia complex, near Natubhai circle, Racecourse Road

Name: SHEETAL SOSA	Date:24/02/2024	
Age / Sex : 32yrs/ Female		

## PAP SMEAR CYTOLOGY(CONVENTIONAL)

### Specimen

Pap smear for cytology(conventional)

### Gross Description

Received one unstained smear.  
Smear-1[PAP]

### Microscopic Description

See below in diagnosis.

### Diagnosis

Satisfactory for evaluation.  
PAP Smears is negative for intra-epithelial lesion or malignancy.  
Trichomonasormonilia are not seen.  
Endo cervical cells are not seen.

PAP test is a screening test for cervical cancer with inherent false negative results.

----- EndOf Report-----

All cytology tests reveal only cytological characteristics of individual cells and not architectural details which are very important in morphological diagnosis. All cytology methods have their own inherent limitations of false positive and false negative results due to variabilities related to sample collection methods, smear preparation, fixation and staining along with microscopic interpretation, hence whenever required tissue diagnosis and/or immunohistochemistry study after correlation with clinical and radiological findings should be done for further confirmation before any definitive medical or surgical treatment.



**Dr. Krish P Vaidya**  
MD G-50510

