

| | | | |
|--------------|-----------------------|---------------------|---------------------|
| Patient Name | : Ms. Srishti Pandey | Age | : 16Yrs 1Mths 2Days |
| UHID | : CSAR.0000145943 | OP Visit No. | : CSAROPV359798 |
| Printed On | : 22-10-2024 12:41 PM | Advised/Pres Doctor | : -- |
| Department | : Radiology | Qualification | : -- |
| Referred By | : Self | Registration No. | : -- |
| Employer Id | : 22D36457 | | |

DEPARTMENT OF RADIOLOGY

ULTRASONOGRAPHY OF ABDOMEN &

PELVIS

LIVER : Normal in size & echotexture normal. No focal lesion. No intra hepatic biliary duct dilatation. Portal & hepatic veins appear normal. PV: Normal. CBD: Normal.

GALL BLADDER : Minimally distended.

PANCREAS : Obscured by bowel gas. However the visualized parts of the pancreas appear grossly normal. Para-Aortic areas could not be seen.

SPLEEN : Normal in size & echotexture normal. No focal / diffuse lesions.

KIDNEYS : RIGHT KIDNEY : 9.8 x 4.2cms, LEFT KIDNEY : 10.3 x 5.6cms, normal parenchymal thickness. Both kidneys are normal in size and echotexture. No calculi. No pelvicalyceal dilatation on both sides. Corticomedullary differentiation is well maintained.

URINARY BLADDER : Normal in wall thickness and lumen are normal. Contents clear. No calculus seen.

UTERUS : Anteverted. Normal in size and echotexture. Endometrial and myometrium appears normal. Endometrial thickness:7.8mm.

POD – clear.

OVARIES : Right ovary- 3.9 x 2.2 x 2.2cm (volume- 10cc).


Left ovary- 4.0 x 1.6 x 2.7cm (volume- 10cc).

IMPRESSION : Multiple small cysts are seen in the periphery of both ovaries measuring 3 x 3 mm (PCOD).

(The sonography findings should always be considered in correlation with the clinical and other investigation findings where applicable).It is only a professional opinion.Not valid for medico-legal purpose) Higher imaging techniques to be done, depending on

the condition of the patient, if clinically needed.

---End Of The Report---



Dr. RAMESH G
MBBS, DMRD
27462
Radiology

| | | | |
|--------------|-----------------------|---------------------|---------------------|
| Patient Name | : Ms. Srishti Pandey | Age | : 16Yrs 1Mths 3Days |
| UHID | : CSAR.0000145943 | OP Visit No. | : CSAROPV359798 |
| Printed On | : 23-10-2024 03:02 AM | Advised/Pres Doctor | : -- |
| Department | : Cardiology | Qualification | : -- |
| Referred By | : Self | Registration No. | : -- |
| Employer Id | : 22D36457 | | |

DEPARTMENT OF CARDIOLOGY

Observation :-

1. Normal Sinus Rhythm.
2. Heart rate is Normal
3. No pathological Q wave or ST-T changes seen.
4. Normal P,QRS,T waves and axis.
5. No evidence of chamber, hypertrophy or enlargement seen.

Impression:-

NORMAL RESTING ECG.

NOTE:-KINDLY TAKE A PHOTOCOPY OF THE GRAPH FOR FUTURE REFERENCE IF NEEDED

---End Of The Report---



Dr. SUMANJITA BORA
MBBS, PGDCC
MCI-IMR-13/903
Cardiology

| | | | |
|--------------|-----------------------|---------------------|---------------------|
| Patient Name | : Ms. Srishti Pandey | Age | : 16Yrs 1Mths 2Days |
| UHID | : CSAR.0000145943 | OP Visit No. | : CSAROPV359798 |
| Printed On | : 22-10-2024 12:03 PM | Advised/Pres Doctor | : -- |
| Department | : Cardiology | Qualification | : -- |
| Referred By | : Self | Registration No. | : -- |
| Employee Id | : 22D36457 | | |

DEPARTMENT OF CARDIOLOGY

2D ECHO CARDIOGRAPHY REPORT

M-MODE MEASUREMENTS

AORTA : 2.3cm LV (D) 4.0cm IVS (D) : 0.8cm
LA : 3.4cm LV (S) : 2.5cm PW (S) : 0.8cm
EF : 62%

VALVES

MITRAL VALVE : NORMAL
AORTIC VALVE : NORMAL
TRICUSPID VALVE : NORMAL
PULMONARY VALVE : NORMAL

CHAMBERS

LEFT ATRIUM : NORMAL SIZED
RIGHT ATRIUM : NORMAL SIZED
LEFT VENTRICLE : NORMAL SIZED, NORMAL LV SYSTOLIC FUNCTION
RIGHT VENTRICLE : NORMAL SIZED, TAPSE-19 MM, NORMAL RV FUNCTION

SEPTAE

IAS : INTACT
IVS : INTACT

GREAT ARTERIES

AORTA : NORMAL
PULMONARY ARTERY : NORMAL

PERICARDIUM :NORMAL

DOPPLER FLOW VELOCITIES

MITRAL FLOW - E/A 0.6/0.4 m/sec, Normal LV Diastolic function, MR- Trivial

AORTIC FLOW PG-06 mmHg

TRICUSPID FLOW PASP -21 mmHg, TR-Trivial

PULMONARY FLOW PG-04 mmHg

REGIONAL WALL MOTION: NO RWMA

OTHER FINDINGS

IVC -13 MM, NORMAL SIZED, COLLAPSING, NORMAL RA PRESSURE

IMPRESSION

NORMAL CHAMBER DIMENSIONS

NORMAL VALVES

NORMAL PA PRESSURE

NO REGIONAL WALL MOTION ABNORMALITY

NORMAL LV SYSTOLIC FUNCTION

NO EVIDENCE OF ASD/VSD/PDA/COA/ CLOT / EFFUSION / VEGETATION

DR .SAIKAT KANJILAL

CONSULTANT INTERVENTIONAL CARDIOLOGY

PRASAD.B

CARDIAC SONOGRAPHER

Note: investigations have their limitations solitary pathological/ Radiological and investigations never confirm the final diagnosis they are help in diagnosing the disease in correlation to clinical symptoms and other related tests. Please interpret accordingly ,this report is not for medico-legal Purpose

---End Of The Report---



Mr.PRASAD BOODUGURI
BSC, DIP IN CARDIO TECH
19XXMCC04712/TSPMB
Cardiology

| | | | |
|--------------|-----------------------|---------------------|---------------------|
| Patient Name | : Ms. Srishti Pandey | Age | : 16Yrs 1Mths 2Days |
| UHID | : CSAR.0000145943 | OP Visit No. | : CSAROPV359798 |
| Printed On | : 22-10-2024 12:42 PM | Advised/Pres Doctor | : -- |
| Department | : Radiology | Qualification | : -- |
| Referred By | : Self | Registration No. | : -- |
| Employeer Id | : 22D36457 | | |

DEPARTMENT OF RADIOLOGY


CHEST PA VIEW

Trachea central.
Mediastinum is central.
Cardiac silhouette appear normal.
visualized lung fields appear normal.
Bilateral hilum appear normal.
CP angles are clear.

IMPRESSION : No obvious gross abnormality noted in the x-ray.

ADVICE : Higher imaging techniques to be done, if clinically needed, depending on the clinical condition of the patient for further evaluation.

---End Of The Report---



Dr. RAMESH G
MBBS, DMRD
27462
Radiology

**APOLLO CLINIC
CONSENT FORM**

Patient name Swasti Pandey Age 16 y/p

UHID Number 145948 Company Name Mediwheel

Company want to inform u that I am not interested in getting optical, gynaecology

Diet.....LBC.Pap..... fitness by g.p, ENT, dental And I claim the above statement in my full Consciousness.

Patient signature Rishav Date 22/10/24

Name : Ms. Srishti Pandey

Age : 16Y 1M 1D

UHID : CSAR.0000145943

Address : Carmelaram Bangalore Rural Karnataka INDIA 560035

sex : Female



CSAR.0000145943

Plan : ARCOFEMI MEDIWHEEL FEMALE AHC
CREDIT PAN INDIA OP AGREEMENT

OP No: CSAROPV359798

Bill No: CSAR-OCR-49293

Date: Oct 22nd, 2024, 8:49 AM

| Sno. | Service Type/Service Name | Department |
|------|---|----------------------|
| 1 | ARCOFEMI - MEDIWHEEL - FULL BODY HEALTH ANNUAL PLUS CHECK - FEMALE - 2D ECHO - PAN INDIA - FY2324 | |
| 1 | ULTRASOUND - WHOLE ABDOMEN - 18 by 12:30 | Ultrasound Radiology |
| 2 | OPHTHAL BY GENERAL PHYSICIAN | Consultation |
| 3 | URINE GLUCOSE(POST PRANDIAL) | Clinical Pathology |
| 4 | GAMMA GLUTAMYL TRANSFERASE (GGT) | Biochemistry |
| 5 | HbA1c, GLYCATED HEMOGLOBIN | Biochemistry |
| 6 | GYNAECOLOGY CONSULTATION | Consultation |
| 7 | DIET CONSULTATION | General |
| 8 | BODY MASS INDEX (BMI) | General |
| 9 | EKG - 10 | Cardiology |
| 10 | THYROID PROFILE (TOTAL T3, TOTAL T4, TSH) | Biochemistry |
| 11 | 2D ECHO - 18 by 9:30 | Cardiology |
| 12 | BLOOD GROUP ABO AND RH FACTOR | Blood Bank |
| 13 | X-RAY CHEST PA - 9 | X Ray Radiology |
| 14 | URINE GLUCOSE, FASTING | Clinical Pathology |
| 15 | LBC PAP TEST- PAPSURE Slip - 6 by 12:30 | Histopathology |
| 16 | FITNESS BY GENERAL PHYSICIAN | Consultation |
| 17 | GLUCOSE, POST PRANDIAL (PP), 2 HOURS (POST MEAL) - 8 | Biochemistry |
| 18 | GLUCOSE, FASTING | Biochemistry |
| 19 | ENT CONSULTATION - 3 by 10:30 | Consultation |
| 20 | LIPID PROFILE | Biochemistry |
| 21 | DENTAL CONSULTATION - 15 | Consultation |
| 22 | HEMOGRAM + PERIPHERAL SMEAR | Haematology |
| 23 | PERIPHERAL SMEAR | Haematology |
| 24 | COMPLETE URINE EXAMINATION | Clinical Pathology |
| 25 | RENAL PROFILE/RENAL FUNCTION TEST (RFT/KFT) | Biochemistry |
| 26 | LIVER FUNCTION TEST (LFT) | Biochemistry |

Physio-2

Wt - 75.5kg

Ht - 170cm

BP - 109/66mmHg

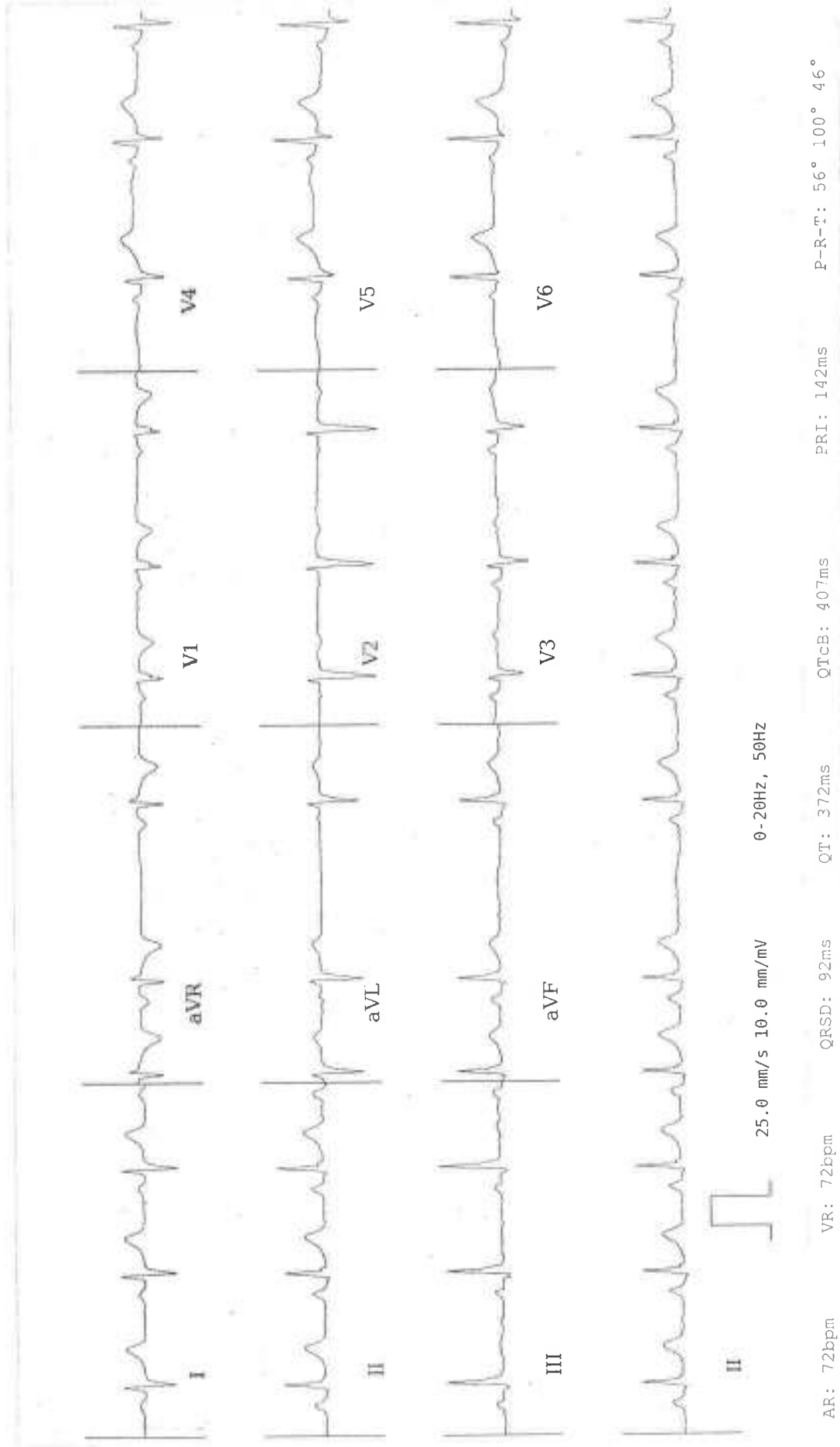
P - 79 bpm

BMI - 26.4 kg/m²



Age / Gender: 16/Female
Patient ID: SRISHTI

Date and Time: 22nd Oct 24 10:18 AM



REPORTED BY
[Signature]

ECG Within Normal Limits: Sinus Rhythm, Sinus Arrhythmia Seen. Please correlate clinically.

Dr Devendra Muratidhar Dhande

Disclaimer: Analysis in this report is based on ECG alone and should only be used as an adjunct to clinical history, symptoms and results of other invasive and non-invasive tests and must be interpreted by a qualified physician

2D ECHO CARDIOGRAPHY REPORT

PATIENT NAME: Ms.SRISHTI PANDEY

AGE :16 YEARS/FEMALE

Date:22/10/2024

M-MODE MEASUREMENTS

AORTA : 2.3cm LV (D) 4.0cm IVS (D) : 0.8cm
LA : 3.4cm LV (S) : 2.5cm PW (S): 0.8cm
EF :62%

VALVES

MITRAL VALVE : NORMAL
AORTIC VALVE : NORMAL
TRICUSPID VALVE : NORMAL
PULMONARY VALVE : NORMAL

CHAMBERS

LEFT ATRIUM : NORMAL SIZED
RIGHT ATRIUM : NORMAL SIZED
LEFT VENTRICLE : NORMAL SIZED, NORMAL LV SYSTOLIC FUNCTION
RIGHT VENTRICLE : NORMAL SIZED, TAPSE-19 MM, NORMAL RV FUNCTION

SEPTAE

IAS : INTACT
IVS : INTACT

GREAT ARTERIES

AORTA : NORMAL
PULMONARY ARTERY : NORMAL

PERICARDIUM :NORMAL

DOPPLER FLOW VELOCITIES

MITRAL FLOW - E/A 0.6/0.4 m/sec, Normal LV Diastolic function, MR- Trivial
AORTIC FLOW PG-06 mmHg
TRICUSPID FLOW PASP -21 mmHg, TR-Trivial
PULMONARY FLOW PG-04 mmHg

REGIONAL WALL MOTION: NO RWMA

Apollo Health and Lifestyle Limited

(CIN - U85110TG2000PLC115819)

Regd. Office: 1-10-60/62, Ashoka Raghupathi Chambers, 5th Floor, Begumpet, Hyderabad, Telangana - 500 016.

Ph No: 040-4904 7777, Fax No: 4904 7744 | Email ID: enquiry@apollohl.com | www.apollohl.com

APOLLO CLINICS NETWORK KARNATAKA

Bangalore (Basavanagudi | Bellandur | Electronic City | Fraser Town | HSR Layout | Indira Nagar | JP Nagar | Kundalahalli | Koramangala | Sarjapur Road) **Mysore** (VV Mohalla)

Online appointments: www.apolloclinic.com

TO BOOK AN APPOINTMENT

 **1860 500 7788**

OTHER FINDINGS

IVC -13 MM, NORMAL SIZED, COLLAPSING, NORMAL RA PRESSURE

IMPRESSION

NORMAL CHAMBER DIMENSIONS

NORMAL VALVES

NORMAL PA PRESSURE

NO REGIONAL WALL MOTION ABNORMALITY

NORMAL LV SYSTOLIC FUNCTION

NO EVIDENCE OF ASD/VSD/PDA/COA/ CLOT / EFFUSION / VEGETATION

DR .SAIKAT KANJILAL

CONSULTANT INTERVENTIONAL CARDIOLOGY

PRASAD.B
CARDIAC SONOGRAPHER

Note: investigations have their limitations solitary pathological/ Radiological and investigations never confirm the final diagnosis they are help in diagnosing the disease in correlation to clinical symptoms and other related tests. Please interpret accordingly ,this report is not for medico-legal Purpose

Apollo Health and Lifestyle Limited

(CIN - U85110TG2000PLC115819)


Regd. Office: 1-10-60/62, Ashoka Raghupathi Chambers, 5th Floor, Begumpet, Hyderabad, Telangana - 500 016.
Ph No: 040-4904 7777, Fax No: 4904 7744 | Email ID: enquiry@apoloh.com | www.apolloh.com

APOLLO CLINICS NETWORK KARNATAKA

Bangalore (Basavanagudi | Bellandur | Electronic City | Fraser Town | HSR Layout | Indira Nagar | JP Nagar | Kundalahalli | Koramangala | Sarjapur Road) **Mysore** (VV Mohalla)

Online appointments: www.apolloclinic.com

TO BOOK AN APPOINTMENT

 **1860 500 7788**



भारत सरकार
GOVERNMENT OF INDIA

नाम: Srishti Pandey
जन्म तिथि/ DOB: 21/09/2008
लिंग: FEMALE



5870 5305 7462

श्री अक्षय, मेरी पहचान

Outlook

Fwd: Fw: Health Check up Booking Confirmed Request(22D36457),Package Code-PKG10000376, Beneficiary Code-248556

From Rishav Pandey <contactrishavpandey@gmail.com>

Date Tue 22-10-2024 08:55

To Sarjapur Apolloclinic <sarjapur@apolloclinic.com>

----- Forwarded message -----

From: **RAHUL PANDEY** <RAHUL.PANDEY2@bankofbaroda.com>

Date: Tue, Oct 22, 2024, 8:53 AM

Subject: Fw: Health Check up Booking Confirmed Request(22D36457),Package Code-PKG10000376, Beneficiary Code-248556

To: Rishav Pandey <contactrishavpandey@gmail.com>

Get [Outlook for Android](#)

From: Mediwheel <wellness@mediwheel.in>

Sent: Monday, October 21, 2024 4:09:37 PM

To: RAHUL PANDEY <RAHUL.PANDEY2@bankofbaroda.com>

Cc: [customercare@mediwheel.in](#) <customercare@mediwheel.in>

Subject: Health Check up Booking Confirmed Request(22D36457),Package Code-PKG10000376, Beneficiary Code-248556

****सावधान:** यह मेल बैंक डोमेन के बाहर से आया है. अगर आप प्रेषक को नहीं जानते तो मेल में दी गयी लिंक पर क्लिक ना करें या अटैचमेंट ना खोलें.

****CAUTION:** THIS MAIL IS ORIGINATED FROM OUTSIDE OF THE BANK'S DOMAIN. DO NOT CLICK ON LINKS OR OPEN ATTACHMENTS UNLESS YOU KNOW THE SENDER.

011-41195959

Dear **Rahul Pandey**,

We are pleased to confirm your health checkup booking request with the following details.

Hospital Package Name : Mediwheel Full Body Annual Plus Check Advanced - Female

Name of Diagnostic/Hospital : Apollo Clinic - Sarjapur Road

Address of Diagnostic/Hospital : Apollo Clinic, #769, GYR Chambers, Opp South Indian Bank, Kaikondanahalli, Sarjapur Road -560034

City : Bangalore