




# PANACEA HOSPITAL

B 36/44 F.K KABIR NAGAR, DURGAKUND  
TOLLFREE NO-18001233070. Whatsapp No - 8795832852  
www.piire.org  
panaceaquery@gmail.com|panceahospitalit@gmail.com



## OP Slip

Print Date : 13-Apr-2024 12:01PM



<b>UHID No</b> :- UD-24250000244	<b>OP No</b> :- OP-24250000846	<b>OP Date</b> :- 13 Apr 2024 10:58AM
<b>Patient Name</b> :- Mr PRASHANT KUMAR	<b>Age/Sex</b> :- 33 Y/Male	<b>Mobile No</b> :- 9386223378
<b>Father</b> :- DINESHWAR SHUKLA	<b>Department</b> :- GENERAL MEDICINE	
<b>Pay Type</b> :- Cr	<b>Consultant</b> :- Dr Pallavi Mishra (MBBS,MD,MBBS)	
<b>Token No</b> :- NOR. - 9	<b>Paid/Bal</b> :- 0.00 /630.00	
<b>Patient Type</b> :- Normal		
<b>Address</b> :- SHUKLAPURA POST DARIYAPUR DHAMAR BHOJPUR,802156,BIHAR		

BP :- 130/90 **Rx**  
 height :- 180  
 Weight (kg) :- 83  
 BMI :-  
 MC - 37  
 WC - ~~92~~ 92  
 CH - 105  
 SpO2 - 98  
 PR - 92  
 PEFr - 300

*Handwritten notes:*  
 Rotable - Simvastatin 20mg  
 Ts. Dabigatran 150mg  
 Ts. Metformin 1000mg  
 All OK (SST 100)  
 Cap. Metformin 1000mg

*Signature:*  
**DR. Pallavi Misra**  
 MBBS, MD(GENERAL MEDICINE)  
 MCI Reg. No.52033

Printed By : Mr Nitin Kumar Yadav  
 Created By : Mr Nitin Kumar Yadav



# PANACEA HOSPITAL

B 36/44 F.K KABIR NAGAR, DURGAKUND  
TOLLFREE NO-18001233070. Whatsapp No - 8795832852  
www.piire.org  
panaceaquery@gmail.com|panceahospitalit@gmail.com



## OP Slip

Print Date : 13-Apr-2024 12:43PM



<b>UHID No</b> :- UD-24250000244	<b>OP No</b> :- OP-24250000889	<b>OP Date</b> :- 13 Apr 2024 12:43PM
<b>Patient Name</b> :- Mr PRASHANT KUMAR	<b>Age/Sex</b> :- 33 Y/Male	<b>Mobile No</b> :- 9386223378
<b>Father</b> :- DINESHWAR SHUKLA	<b>Department</b> :- OPHTHALMOLOGY	
<b>Pay Type</b> :- Cr	<b>Consultant</b> :- Dr SANTOSH VERMA (MBBS,MS)	
<b>Token No</b> :- NOR. - 9	<b>Paid</b> :- 0.00	
<b>Patient Type</b> :- Normal		
<b>Address</b> :- SHUKLAPURA POST DARIYAPUR DHAMAR BHOJPUR,802156,BIHAR		

BP :- 130/90  
height :- 180  
Weight (kg) :- 83  
BMI :-

Rx

6/6  
6/6

NE - 37  
WE - 92  
CH - 105  
SPOL - 98  
PR - 92  
PEFR - 300

ADU  
- Dilated fundus  
exam  
- OCT (MD) BE  
- Refraction

BE anti-segment: normal  
BE - Central fundus: normal

Cap 2 RITE PWS 1050/10dys  
A/E  
G. CUBSTADONE ULTRA 10F

ADU: 2/7 mm - 1 Refr

Printed By : Mr Nitin Kumar Yadav

Created By : Mr Nitin Kumar Yadav

**Dr. SANTOSH VERMA**  
MBBS, MS (Ophthalmologist)  
MCI Reg. No. 09-34327



# PANACEA HOSPITAL

B 36/44 F.K KABIR NAGAR, DURGAKUND  
TOLLFREE NO-18001233070. Whatsapp No - 8795832852  
www.piire.org  
panaceaquery@gmail.com|panceahospitalit@gmail.com



## OP Slip

Print Date : 13-Apr-2024 12:43PM



<b>UHID No</b> :- UD-24250000244	<b>OP No</b> :- OP-24250000888	<b>OP Date</b> :- 13 Apr 2024 12:42PM
<b>Patient Name</b> :- Mr PRASHANT KUMAR	<b>Age/Sex</b> :- 33 Y/Male	<b>Mobile No</b> :- 9386223378
<b>Father</b> :- DINESHWAR SHUKLA	<b>Department</b> :- DERMATOLOGY	
<b>Pay Type</b> :- Cr	<b>Consultant</b> :- Dr DR ASHUTOSH MISHRA (MBBS,MD)	
<b>Token No</b> :- NOR. - 7	<b>Paid</b> :- 0.00	
<b>Patient Type</b> :- Normal		
<b>Address</b> :- SHUKLAPURA POST DARIYAPUR DHAMAR BHOJPUR,802156,BIHAR		

BP :- 130/90  
 height :- 180  
 Weight (kg) :- 83  
 BMI :-  
 Mc - 37  
 Wc - 92  
 CH - 105  
 SpO2 - 98  
 PR - 92  
 PEFr - 300

Rx

Rx

*Ad*  
 Dr. Tejpal Singh  
 Resident Surgeon  
 Surgent



Printed By : Mr Nitin Kumar Yadav  
Created By : Mr Nitin Kumar Yadav




# PANACEA HOSPITAL

B 36/44 F.K KABIR NAGAR, DURGAKUND  
TOLLFREE NO-18001233070. Whatsapp No - 8795832852  
www.piire.org  
panaceaquery@gmail.com|panceahospitalit@gmail.com



## OP Slip

Print Date : 13-Apr-2024 12:42PM



<b>UHID No</b>	:- UD-24250000244	<b>OP No</b>	:- OP-24250000887	<b>OP Date</b>	:- 13 Apr 2024 12:40PM
<b>Patient Name</b>	:- Mr PRASHANT KUMAR	<b>Age/Sex</b>	:- 33 Y/Male	<b>Mobile No</b>	:- 9386223378
<b>Father</b>	:- DINESHWAR SHUKLA	<b>Department</b>	:- DENTAL		
<b>Pay Type</b>	:- Cr	<b>Consultant</b>	:- Dr SHRUTI MISHRA (AA)		
<b>Token No</b>	:- NOR. - 7	<b>Paid</b>	:- 0.00		
<b>Patient Type</b>	:- Normal				
<b>Address</b>	:- SHUKLAPURA POST DARIYAPUR DHAMAR BHOJPUR,802156,BIHAR				

BP :- 130/90  
height :- 180  
Weight (kg) :- 83  
BMI :-

MC - 37  
WC - 92  
CH - 105  
SpR - 98  
PR - 92  
PEFR - 300

### Rx

(c) patient came for routine dental check up

O/E => stain/calculus - ++/++

P/D => chronic gen gingivitis

T/A => Scaling & polishing

Printed By : Mr Nitin Kumar Yadav  
Created By : Mr Nitin Kumar Yadav

*Shruti*  
**Dr. SHRUTI MISHRA**  
BDS, (DENTIST)  
MCI Reg. No. (A-09784)

**Facilities:**

All clinical Biomedical & Hematology Investigations including Bone Marrow Examination  
VPT, Podiascan & Complete Foot Care (First Time in Purvanchal)  
All Hormonal Investigation by Chemiluminescent Method  
Visceral Fat by (AB-140) Ambulatory BP Monitoring  
CGMS & Insulin Pump Available  
PFT, 2D-ECHO (Color Doppler), Holter, TMT, Cardiac-3 available  
VIA, VILI, Colposcopy available  
Special Endocrinological Investigation Protocols.

ISO 9001:2008 Certified

Mobile: 9389994334, 9554572190, 9453837595

**Panacea Pathology****Clinical Reference Lab**

Persistence, Preparedness and Precision  
EQAS (CMC Vellore Attached) & IQAS System  
पूर्वांचल की सर्वोत्तम गुणवत्ता वाली पैथोलॉजी

**UHID No** :- UD-24250000244 **Booking No/Date** :- 44 / 13-Apr-2024 12:51 PM  
**Patient Name** :- Mr PRASHANT KUMAR **Age/Sex** :- 33 Y/M  
**Father** :- DINESHWAR SHUKLA **OP No** :- OP-24250000846  
**Address** :- SHUKLAPURA POST DARIYAPUR DHAMAR BHOJPUR,802156 , BIHAR **Mobile No** :- 9386223378  
**Consultant** :- Dr Pallavi Mishra (MBBS,MD)

Investigations	Observations	Biological Ref. Interval	Unit
<b>HAEMATOLOGY</b>			
<b>CBC</b>			
HAEMOGLOBIN <i>DefaultMethod / test Machine</i>	<b>11.6</b>	13.00 - 16.00	gm/dl
TLC <i>Methology / Carm</i>	9,800	4000.00 - 11000.00	Cells/cumm.
DLC DIFFERENTIAL LEUCOCYTE COUNT			
NEUTROPHILS	69	40.00 - 75.00	%
LYMPHOCYTES	26	20.00 - 45.00	%
EOSINOPHILS	02	1.00 - 6.00	%
MONOCYTES	03	2.00 - 10.00	%
BASOPHILS	00	&lt;1-2	%
PLATELET COUNT	1.97	1.50 - 4.10	lacs /cumm
PCV	39.6	33.00 - 42.00	%
RBC <i>Methology / Carm</i>	<b>5.89</b>	4.50 - 5.50	million/cumm
MCV(MEAN CELL VOLUME)	<b>67.3</b>	83.00 - 101.00	fl
MCH(MEAN CELL HAEMOGLOBIN)	<b>19.7</b>	27.00 - 32.00	pg
MCHC	<b>29.3</b>	31.50 - 35.00	gm%
RDW-CV	15.8	11.00 - 16.00	%
RDW-SD	42.6	37.00 - 57.00	fl

Consulting Pathologist

DR. UMESH KUMAR  
MBBS, MD (PATHOLOGIST)  
MCI Reg. No. 41413

Lab Technician

Timing : 24/7 hrs

This Report is not valid for medico legal purpose

Note: These tests have technical limitations. Clinico-pathological interpretation is necessary. In case of any disparity test may be repeated immediately.

Address : 36/44 FK Kabir Nagar, Durgakund, Varanasi – 221005

Email: [dramishra@gmail.com](mailto:dramishra@gmail.com), [drpallaviojha@gmail.com](mailto:drpallaviojha@gmail.com) Website: [panaceahospital.org](http://panaceahospital.org)

**Facilities:**

All clinical Biomedical & Hematology Investigations including Bone Marrow Examination  
 VPT, Podiascan & Complete Foot Care (First Time in Purvanchal)  
 All Hormonal Investigation by Chemiluminescent Method  
 Visceral Fat by (AB-140) Ambulatory BP Monitoring  
 CGMS & Insulin Pump Available  
 PFT, 2D-ECHO (Color Doppler), Holter, TMT, Cardiac-3 available  
 VIA, VILI, Colposcopy available  
 Special Endocrinological Investigation Protocols.

ISO 9001:2008 Certified  
 Mobile: 9389994334, 9554572190, 9453837595



# Panacea Pathology

## Clinical Reference Lab

Persistence, Preparedness and Precision  
 EQAS (CMC Vellore Attached) & IQAS System  
 पूर्वांचल की सर्वोत्तम गुणवत्ता वाली पैथोलॉजी

**UHID No** :- UD-24250000244 **Booking No/Date** :- 44 / 13-Apr-2024 12:51 PM  
**Patient Name** :- Mr PRASHANT KUMAR **Age/Sex** :- 33 Y/M  
**Father** :- DINESHWAR SHUKLA **OP No** :- OP-24250000846  
**Address** :- SHUKLAPURA POST DARIYAPUR **Mobile No** :- 9386223378  
 DHAMAR BHOJPUR,802156 , BIHAR  
**Consultant** :- Dr Pallavi Mishra (MBBS,MD)

Investigations	Observations	Biological Ref. Interval	Unit
----------------	--------------	--------------------------	------

### URINE EXAMINATION

#### URINE ROUTINE EXAMINATION

##### PHYSICAL EXAMINATION

QUANTITY	25		ml
COLOR <i>Methology</i>	STRAW	CLEAR YELLOW	
APPEARANCE <i>DefaultMethod</i>	CLEAR	CLEAR	

##### CHEMICAL EXAMINATION

SPECIFIC GRAVITY	1.025	1.01 - 1.03	
PH	6.5	4.60 - 8.00	
GLUCOSE	NIL	60.00 - 100.00	mg/dl
PROTEIN-	NIL		

##### MICROSCOPIC EXAMINATION

PUS CELLS	01-02	2.00 - 3.00	/HPF
RBCS ( RED BLOOD CELLS)	NIL	4.50 - 5.50	/HPF
EPITHELIAL CELLS	NIL		/HPF
CASTS	ABSENT	ABSENT	
CRYSTALS	ABSENT	ABSENT	

  
 Consulting Pathologist

Dr. UMESH KUMAR  
 MBBS,MD (PATHOLOGIST)  
 M.D. Pathology  
 MCI Reg. No. 41413

Lab Technician

Timing : 24/7 hrs

This Report is not valid for medico legal purpose

Note: These tests have technical limitations. Clinico-pathological interpretation is necessary. In case of any disparity test may be repeated immediately.

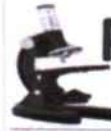Address : 36/44 FK Kabir Nagar, Durgakund, Varanasi – 221005

Email: [dramishra@gmail.com](mailto:dramishra@gmail.com), [drpallaviojha@gmail.com](mailto:drpallaviojha@gmail.com) Website: [panaceahospital.org](http://panaceahospital.org)

**Facilities:**

All clinical Biomedical & Hematology Investigations including Bone Marrow Examination  
 VPT, Podiascan & Complete Foot Care (First Time in Purvanchal)  
 All Hormonal Investigation by Chemiluminescent Method  
 Visceral Fat by (AB-140) Ambulatory BP Monitoring  
 CGMS & Insulin Pump Available  
 PFT, 2D-ECHO (Color Doppler), Holter, TMT, Cardiac-3 available  
 ViA, VILI, Colposcopy available  
 Special Endocrinological Investigation Protocols.

ISO 9001:2008 Certified  
 Mobile: 9389994334, 9554572190, 9453837595



# Panacea Pathology

## Clinical Reference Lab

Persistence, Preparedness and Precision  
 EQAS (CMC Vellore Attached) & IQAS System  
 पूर्वांचल की सर्वोत्तम गुणवत्ता वाली पैथोलॉजी

<b>UHID No</b>	:- UD-24250000244	<b>Booking No/Date</b>	:- 44 / 13-Apr-2024 12:51 PM
<b>Patient Name</b>	:- Mr PRASHANT KUMAR	<b>Age/Sex</b>	:- 33 Y/M
<b>Father</b>	:- DINESHWAR SHUKLA	<b>OP No</b>	:- OP-24250000846
<b>Address</b>	:- SHUKLAPURA POST DARIYAPUR DHAMAR BHOJPUR,802156 , BIHAR	<b>Mobile No</b>	:- 9386223378
<b>Consultant</b>	:- Dr Pallavi Mishra (MBBS,MD)		

Investigations	Observations	Biological Ref. Interval	Unit
----------------	--------------	--------------------------	------

### HAEMATOLOGY

<b>ESR</b>	22.0	0.00 - 15.00	mm at 1 hr
<b>BLOOD GROUP ABO &amp; RH FACTOR</b>			
BLOOD GROUP	"A"		
RH FACTOR	POSITIVE		
<b>HBA1C -(BY GOLD STANDARD METHOD :HPLC)</b>	5.3	Normal: 4.0 - 5.4 Prediabetic : 5.5 -6.3 Diabetes mellitus := 6.4	%

### BIOCHEMISTRY

#### BLOOD SUGAR FASTING

GLUCOSE	79.0	60.00 - 100.00	mg/dl
PRE-DIABETICS(IMPAIRED FASTING TOLER)	-	100.00 - 125.00	mg/dl
DIABETICS	-	upto 126	mg/dl
TARGET IN DM	-	80.00 - 130.00	mg/dl

### BIOCHEMISTRY

#### PPBS(POST PRANDIAL BLOOD SUGAR)

POST PRANDIAL BLOOD GLUCOSE(2 HR AFTER MEAL)	192.0	110.00 - 150.00	mg/dl
IGT(2 HR 75GM GLUCOSE)	-	140.00 - 199.00	mg/dl
DIABETES	-	upto200	mg/dl

  
 Consulting Pathologist

DR. UMESH KUMAR  
 MBBS, MD (PATHOLOGIST)  
 MCI Reg. No. 41413

Lab Technician

Timing : 24/7 hrs

This Report is not valid for medico legal purpose

Note: These tests have technical limitations. Clinico-pathological interpretation is necessary. In case of any disparity test may be repeated immediately.

Address : 36/44 FK Kabir Nagar, Durgakund, Varanasi - 221005

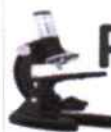Email: [dramishra@gmail.com](mailto:dramishra@gmail.com), [drpallaviojha@gmail.com](mailto:drpallaviojha@gmail.com) Website: [panaceahospital.org](http://panaceahospital.org)

**Facilities:**

All clinical Biomedical & Hematology Investigations including Bone Marrow Examination VPT, Podiascan & Complete Foot Care (First Time in Purvanchal) All Hormonal Investigation by Chemiluminescent Method Visceral Fat by (AB-140) Ambulatory BP Monitoring CGMS & Insulin Pump Available PFT, 2D-ECHO (Color Doppler), Holter, TMT, Cardiac-3 available VIA, VILI, Colposcopy available Special Endocrinological Investigation Protocols.

ISO 9001:2008 Certified

Mobile: 9389994334, 9554572190, 9453837595



# Panacea Pathology

## Clinical Reference Lab

Persistence, Preparedness and Precision  
EQAS (CMC Vellore Attached) & IQAS System  
पूर्वांचल की सर्वोत्तम गुणवत्ता वाली पैथोलॉजी

**UHID No** :- UD-24250000244 **Booking No/Date** :- 44 / 13-Apr-2024 12:51 PM  
**Patient Name** :- Mr PRASHANT KUMAR **Age/Sex** :- 33 Y/M  
**Father** :- DINESHWAR SHUKLA **OP No** :- OP-24250000846  
**Address** :- SHUKLAPURA POST DARIYAPUR DHAMAR BHOJPUR,802156 , BIHAR **Mobile No** :- 9386223378  
**Consultant** :- Dr Pallavi Mishra (MBBS,MD)

Investigations	Observations	Biological Ref. Interval	Unit
TARGET IN DM	-	80.00 - 130.00	mg/dl
<b>BIOCHEMISTRY</b>			
<b>LIPID PROFILE</b>			
TOTAL CHOLESTROL	168.0	Desirable : - &lt; 200 mg/dL Borderline: - 200 - 239 mg/dL High : - &gt; 240mg/dL	mg/dl
TRIGLYCERIDES	149.0	35.00 - 160.00	mg/dl
HDL CHOLESTROL	43.0	35.30 - 79.50	mg/dl
LDL CHOLESTROL	95.2	&lt;130	mg/dl
VLDL	29.80	&lt;40	mg/dl
CHOLESTROL/ HDL RATIO	3.91	&lt;3.0 LOW RISK, 3.0-5.0 AVG RISK, &gt;5.0 HIGH RISK	ratio
LDL/HDL RATIO	2.21	&lt;3	ratio
<b>LFT (LIVER FUNCTION TESTS)</b>			
TOTAL BILIRUBIN	0.69	0.00 - 1.20	mg/dl
DIRECT BILIRUBIN	0.24	0.00 - 0.30	
INDIRECT BILIRUBIN	0.45	0.20 - 0.70	mg/dl
SGOT	28.0	2.00 - 31.00	U/L
SGPT	30.0	10.00 - 45.00	U/L

Lab Technician

Timing : 24/7 hrs

Consulting Pathologist

Dr. Umesh Kumar

DR. UMESH KUMAR

MBBS, MD (PATHOLOGIST)

MCL Reg. No. 1119

This Report is not valid for medico legal purpose

Note: These tests have technical limitations. Clinico-pathological interpretation is necessary. In case of any disparity test may be repeated immediately.

Address : 36/44 FK Kabir Nagar, Durgakund, Varanasi - 221005

Email: [dramishra@gmail.com](mailto:dramishra@gmail.com), [drpallaviojha@gmail.com](mailto:drpallaviojha@gmail.com) Website: [panaceahospital.org](http://panaceahospital.org)



**Facilities:**

All clinical Biomedical & Hematology Investigations including Bone Marrow Examination  
 VPT, Podiascan & Complete Foot Care (First Time in Purvanchal)  
 All Hormonal Investigation by Chemiluminescent Method  
 Visceral Fat by (AB-140) Ambulatory BP Monitoring  
 CGMS & Insulin Pump Available  
 PFT, 2D-ECHO (Color Doppler), Holter, TMT, Cardiac-3 available  
 VIA, VILI, Colposcopy available  
 Special Endocrinological Investigation Protocols.

ISO 9001:2008 Certified  
 Mobile: 9389994334, 9554572190, 9453837595



# Panacea Pathology

## Clinical Reference Lab

Persistence, Preparedness and Precision  
 EQAS (CMC Vellore Attached) & IQAS System  
 पूर्वांचल की सर्वोत्तम गुणवत्ता वाली पैथोलॉजी

**UHID No** :- UD-24250000244  
**Booking No/Date** :- 44 / 13-Apr-2024 12:51 PM  
**Patient Name** :- Mr PRASHANT KUMAR  
**Age/Sex** :- 33 Y/M  
**Father** :- DINESHWAR SHUKLA  
**OP No** :- OP-24250000846  
**Address** :- SHUKLAPURA POST DARIYAPUR  
 DHAMAR BHOJPUR,802156 , BIHAR  
**Mobile No** :- 9386223378  
**Consultant** :- Dr Pallavi Mishra (MBBS,MD)

Investigations	Observations	Biological Ref. Interval	Unit
ALKALINE PHOSPHATASE	74.0	25.00 - 140.00	U/L
TOTAL PROTIENS	6.95	6.60 - 8.70	g/dl
ALBUMIN	3.70	3.50 - 5.20	gm%
GLOBULIN	3.25	1.50 - 3.60	gms/dl
A/G RATIO	1.13	2:1	RATIO
<b>YGGT</b>	21.0	10.00 - 50.00	U/L
<b>RFT (RENAL FUNCTION TESTS)</b>			
SERUM CREATININE	0.98	0.60 - 1.60	mg/dl
URIC ACID	<b>10.0</b>	3.60 - 7.70	mg/dl

### IMMUNOLOGY

#### **THYROID PROFILE (T3,T4,TSH)**

T3	0.92	0.60 - 1.81	ng/ml
T4	7.2	4.50 - 10.90	ug/dl
TSH	1.61	0.39 - 6.10	uIU/mL

### PARASITOLOGY

#### **STOOL ROUTINE**

Consulting Pathologist

Dr. Umesh Kumar  
 DR. UMESH KUMAR  
 M.D. Pathology  
 MBBS, MD (PATHOLOGIST)  
 MCI Reg. No. 41413

Lab Technician

Timing : 24/7 hrs

This Report is not valid for medico legal purpose

Note: These tests have technical limitations. Clinico-pathological interpretation is necessary. In case of any disparity test may be repeated immediately.

Address : 36/44 FK Kabir Nagar, Durgakund, Varanasi – 221005

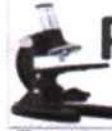Email: [dramishra@gmail.com](mailto:dramishra@gmail.com), [drpallaviojha@gmail.com](mailto:drpallaviojha@gmail.com) Website: [panaceahospital.org](http://panaceahospital.org)

**Facilities:**

All clinical Biomedical & Hematology Investigations including Bone Marrow Examination  
 VPT, Podiascan & Complete Foot Care (First Time in Purvanchal)  
 All Hormonal Investigation by Chemiluminescent Method  
 Visceral Fat by (AB-140) Ambulatory BP Monitoring  
 CGMS & Insulin Pump Available  
 PFT, 2D-ECHO (Color Doppler), Holter, TMT, Cardiac-3 available  
 ViA, VILI, Colposcopy available  
 Special Endocrinological Investigation Protocols.

ISO 9001:2008 Certified

Mobile: 9389994334, 9554572190, 9453837595

**Panacea Pathology****Clinical Reference Lab**

Persistence, Preparedness and Precision  
 EQAS (CMC Vellore Attached) & IQAS System  
 पूर्वांचल की सर्वोत्तम गुणवत्ता वाली पैथोलॉजी

**UHID No** :- UD-24250000244 **Booking No/Date** :- 44 / 13-Apr-2024 12:51 PM  
**Patient Name** :- Mr PRASHANT KUMAR **Age/Sex** :- 33 Y/M  
**Father** :- DINESHWAR SHUKLA **OP No** :- OP-24250000846  
**Address** :- SHUKLAPURA POST DARIYAPUR DHAMAR BHOJPUR,802156 , BIHAR **Mobile No** :- 9386223378  
**Consultant** :- Dr Pallavi Mishra (MBBS,MD)

Investigations	Observations	Biological Ref. Interval	Unit
<b>GROSS EXAMINATON</b>			
COLOR <i>Methology</i>	YELLOW	CLEAR YELLOW	
CONSISTANCY	NORMAL		
BLOOD	ABSENT		
MUCUS	ABSENT		
<b>MICROSCOPIC EXAMINATON</b>			
OVA OR EGGS OF HELMINTHS	ABSENT		
PUS CELLS	02-03	2.00 - 3.00	/HPF
RBC <i>Methology / Carm</i>	NIL	4.50 - 5.50	million/cumm

\* END OF REPORT \*

Consulting Pathologist

DR. UMESH KUMAR  
 MBBS, MD (PATHOLOGIST)  
 MCI Reg. No. 41413

Lab Technician

Timing : 24/7 hrs

This Report is not valid for medico legal purpose

Note: These tests have technical limitations. Clinico-pathological interpretation is necessary. In case of any disparity test may be repeated immediately.

Address : 36/44 FK Kabir Nagar, Durgakund, Varanasi – 221005

Email: [dramishra@gmail.com](mailto:dramishra@gmail.com), [drpallaviojha@gmail.com](mailto:drpallaviojha@gmail.com) Website: [panaceahospital.org](http://panaceahospital.org)



# PANACEA HOSPITAL



*A shelter for many hearts A Home for many lives*

(An ISO 9001:2008 Certified Organisation)  
Lab Attached with CMC Under EQAS Scheme

Dept. of Radiodiagnosis - 32 Slice CT Scan, 3D/4D USG, 2D ECHO, Colour Doppler, Intervention Procedures, Digital X-Ray

**NAME: MR.KUMAR PRASHANT**  
**REF BY: DR. ASHUTOSH MISHRA (MD)**

**AGE/SEX: 33 YRS / MALE**  
**DATE: 13/04/2024**

### Echo - Cardiography

MITRAL VALVE Doppler	AML - normal morphology MV Flow - E - 0.7 A-0.8 E/A=1.24	PML - normal morphology MVA - 3.0 cm2 Mitral Regurgitation - No
TRICUSPID VALVE Doppler	Normal TV Flow -No	Tricuspid Regurgitation -No
PULMONARY VALVE Doppler	Normal PV Flow -No	Pulmonary Regurgitation - No
AORTIC VALVE Doppler	Trileaflet- No AV Flow - no	Aortic Regurgitation - No
MEASUREMENT	Aorta - 32.6 (20-38) mm IVS ed - 9.7 (6-12) mm LVID ed - 49.7 (35-55) mm LVPW ed - 14.6 (6-12) mm OA - 7 (> 5) mm	LA -35.4 (24-32) mm IVS es -14.8 (6-12) mm LVID es - 34.3 (24-40) mm LVPW es - 16.6 (6-12) mm EPSS - 6 (< 9) mm

**CONCLUSION** All cardiac chamber dimensions are WNL  
 No valvular abnormalities  
 Good LV systolic dysfunction present Modified Simpson's method (4C, 2C) (LVEF-59%)  
 No diastolic dysfunction present (E/A = 1.24)  
 No RWMA  
 No pericardial effusion  
 Intact IAS / IV  
 No PAH  
 No intra cardiac mass /thrombus /vegetation

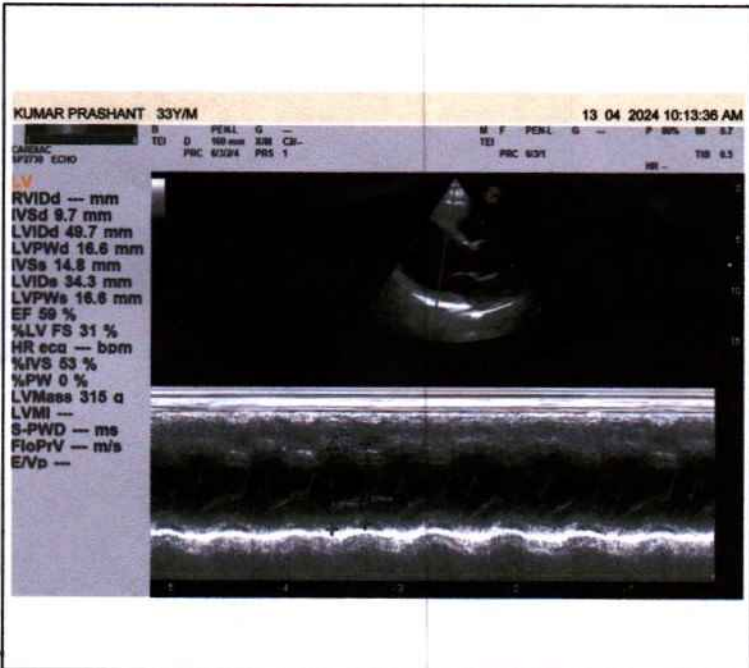
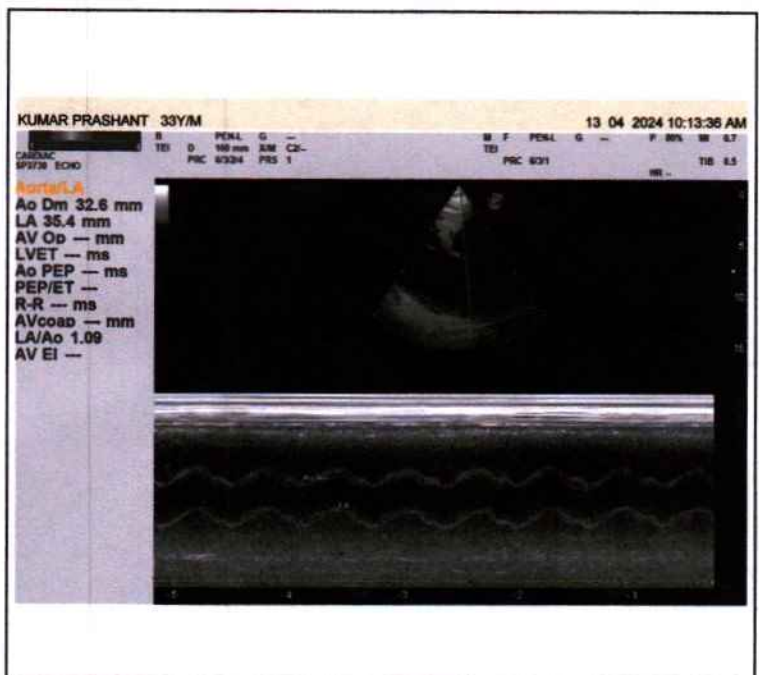
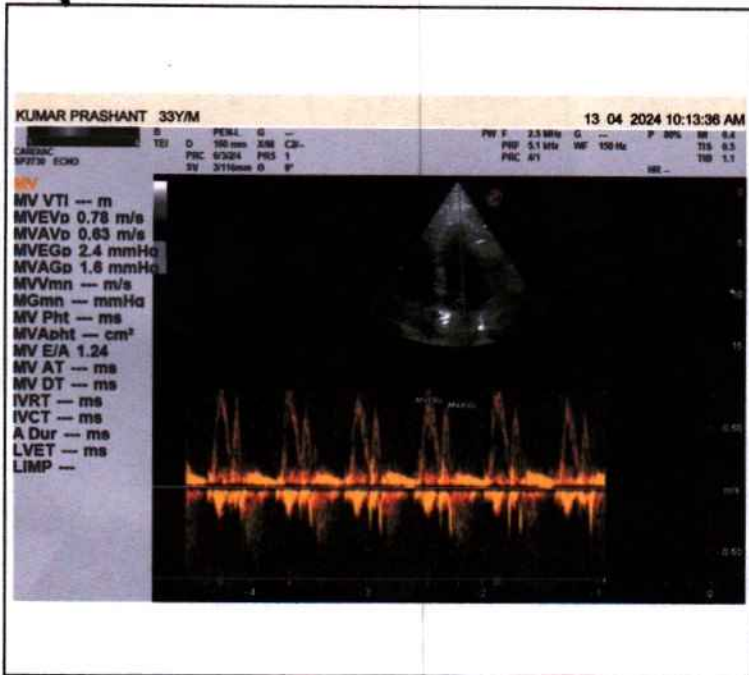
**IMPRESSION** Normal Echocardiogram

  
 Niraj Mishra  
 Physician Assistant  
 (PIIRE)

  
 Dr. Pallavi Misra  
 MBBS, MD (MED), Lucknow  
 Echocardiography Specialist, JIAB  
 Non-invasive Cardiologist  
 Women Cardiologist  
 Diabetocardiologist  
**MBBS, MD (GENERAL MEDICINE)**  
**MCI Reg. No. 52033**

Disclaimer: This report is not valid for Madicolegal or Judicial Purpose. Radiological diagnosis is solely interpretation of images produced by tissue & may not be always conclusive.

Address : B36/44 B4 Kabir Nagar (Near Sanjay Shiksha Niketan), Durgakund, Varanasi  
 Mobile : 9554572190 / 9453837595 / Recpn, 9389994334  
 Email : dramishra@gmail.com, drpallaviojha@gmail.com, Website : www.piiire.org





Call Now - 1800-123-3070

# PANACEA HOSPITAL



*A shelter for many hearts A Home for many lives*

(An ISO 9001:2008 Certified Organisation)  
Lab Attached with CMC Under EQAS Scheme

Dept. of Radiodiagnosis - 32 Slice CT Scan, 3D/4D USG, 2D ECHO, Colour Doppler, Intervention Procedures, Digital X-Ray

PATIENT'S NAME : PRASHANT KUMAR

AGE/SEX:33Y/M

REF. BY : Dr. ASHUTOSH MISHRA(MD)

DATE 13-04-2024

## X-RAY CHEST (AP VIEW)

- Lung fields show hazy opacities in both parahilar, basal zone with mild prominent brochopulmonary markings findings suggestive of MILD BRONCHITIS.
- Rest visualized lung fields appear normal.
- Trachea appear normal in position and course.
- Bony rib cage and soft tissue shadows appear normal.

*Thanks for reference.*

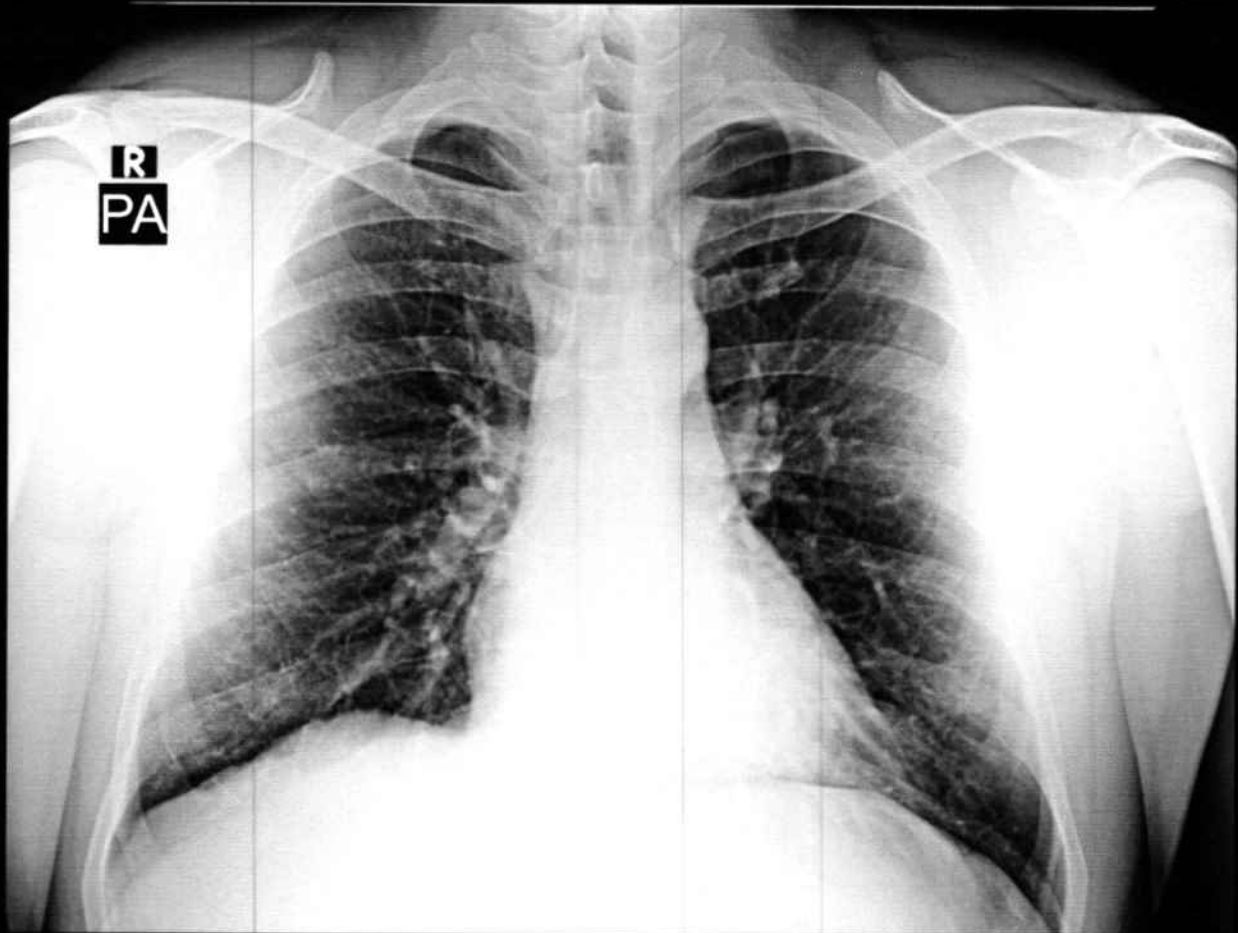
*Radiologist*  
Dr. Rahul Kumar Tiwan  
MBBS, MD (Radio Diagonosis)  
Reg. No. 57557

Disclaimer: This report is not valid for Madicolegal or Judicial Purpose. Radiological diagnosis is solely interpretation of images produced by tissue & may not be always conclusive.

Address : B36/44 B4 Kabir Nagar (Near Sanjay Shiksha Niketan), Durgakund, Varanasi

Mobile : 9554572190 / 9453837595 / Recpn, 9389994334

Email : dramishra@gmail.com, drpallaviojha@gmail.com, Website : www.piire.org



PRASHANT KUMAR 33Y/M 0244 M CHEST P.A. 13-Apr-24 10:41 AM

PANACEA HOSPITAL, KABIR NAGAR, DURGAKUND, VARANASI



# PANACEA HOSPITAL



*A shelter for many hearts A Home for many lives*  
(An ISO 9001:2008 Certified Organisation)  
Lab Attached with CMC Under EQAS Scheme

Dept. of Radiodiagnosis - 32 Slice CT Scan, 3D/4D USG, 2D ECHO, Colour Doppler, Intervention Procedures, Digital X-Ray

NAME: KUMAR PRASHANT  
REF.DR. DR.ASHUTOSH MISHRA(MD)

AGE/SEX: 33YRS/MALE  
DATE: 13/04/2024

## ULTRA SOUND WHOLE ABDOMEN REPORT

**Liver:** Liver is normal in size measuring approx 153mm with **diffuse increased echogenicity of liver parenchyma – Grade I fatty liver.** Intra hepatic biliary radicals are normal. Portal venous channels are normal.

**Gall bladder:** Normally distended with echo free lumen.

**Portal vein:** Normal in course and caliber.

**CBD diameter:** Visualized part normal in course & caliber.

**Pancreas:** Normal in size, shape & echogenicity. Margins are smooth & regular. No diffuse/ focal lesion seen. Pancreatic duct not visualized.

**Spleen:** Normal in size, shape & echogenicity. Margins are smooth & regular.  
No diffuse / focal lesion seen. Splenic vessels at hilum is normal.

**Kidney:** Right kidney: 9.5x4.5cm, Left kidney: 9.0x4.3 cm.  
Both normal in size, shape echogenicity & position. Cortical-medullary differentiation is maintained. Pelvicalyceal system normal. No evidence of any calculus/mass lesion seen  
No hydronephrosis/ hydroureter seen. No suprarenal mass lesion

**Urinary bladder:** Normally distended with normal wall thickness. No echogenic foci lumen or diverticula seen.  
Both VUJ appears normal. No evidence of calculus / mass lesion seen.

**Prostate:** Normal in size, shape & echogenicity.

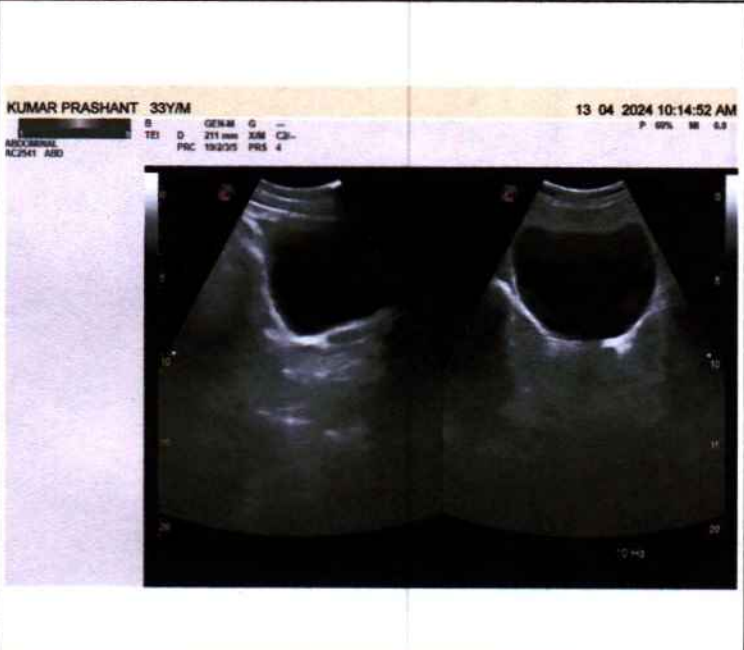
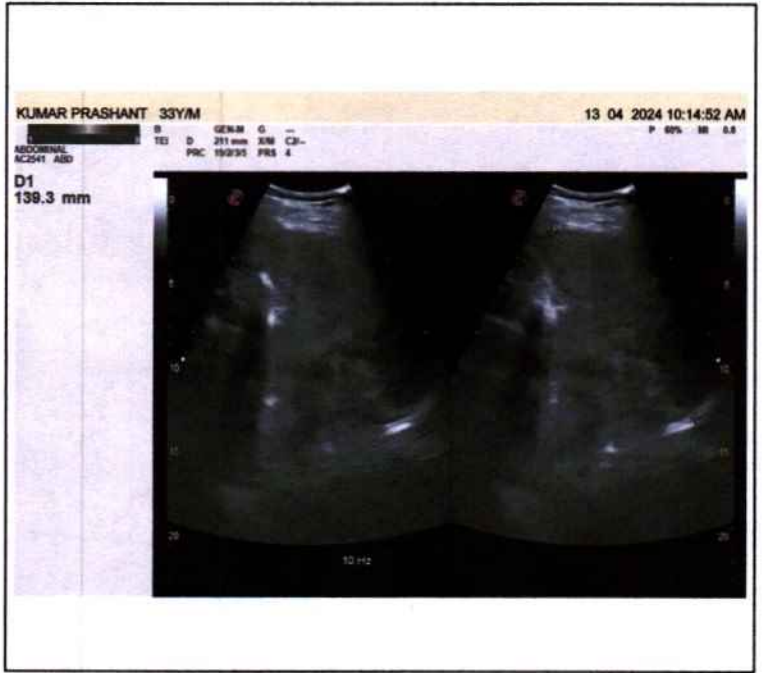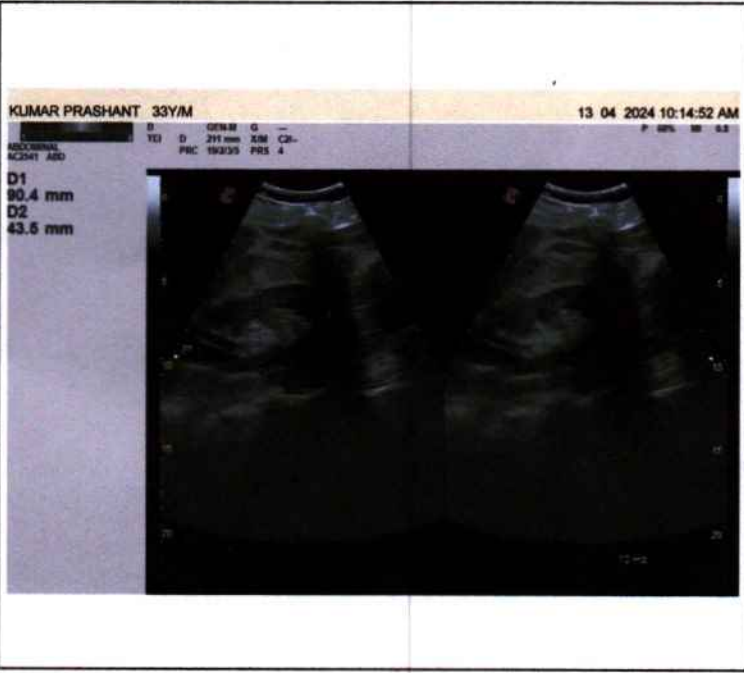
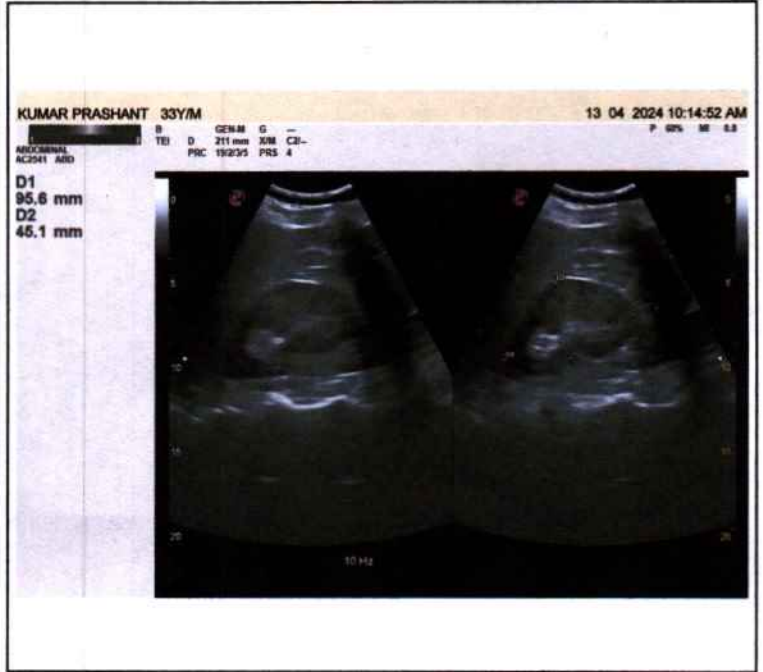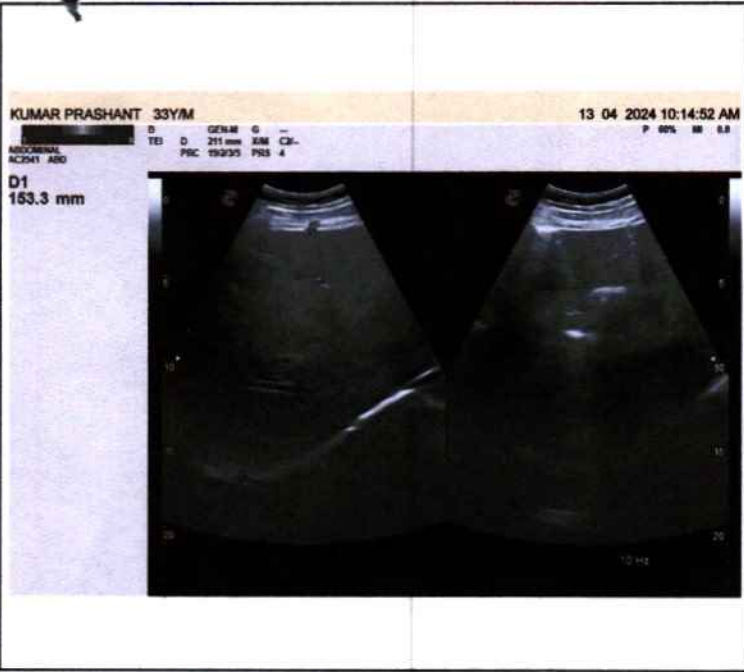**Others:** No free fluid in peritoneal cavity.  
No free fluid in bilateral pleural cavity.  
No evidence of significantly enlarged retroperitoneal/ mesenteric lymph nodes noted.

**IMPRESSION: - GRADE I FATTY LIVER**

Please correlate clinically and further investigations.

Signologist

Dr. Rahul Kumar Tiwari  
MBBS, MD (Radio Diagonosis)  
Reg. No. 57557





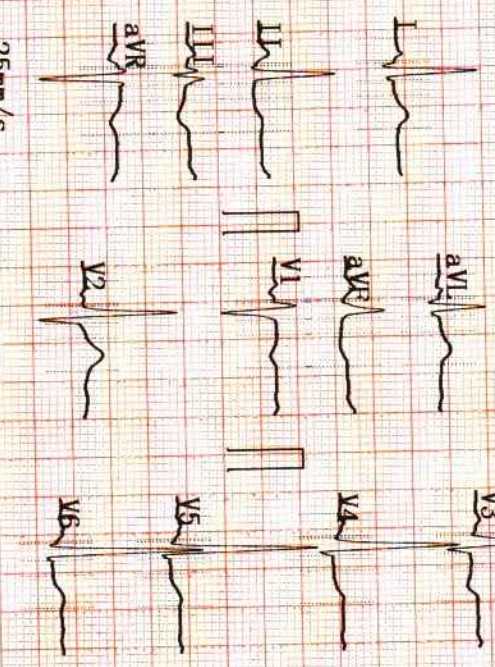
10mm/mV

10mm/mV

10mm/mV

1970-01-01 23:22

<< Conclusions >>



ID :  
 Name : Bashant Kumar  
 Sex : M Age : 33  
 Height : 180 Weight : 83 kg  
 SYS :  
 DIA :  
 HR : 90 bpm  
 PR Interval : 132 ms  
 P Duration : 117 ms  
 QRS Duration : 93 ms  
 T Duration : 174 ms  
 QT/QTc : 349/427 ms  
 P/QRS/T Axis : 63.0/39.7/-19.0 deg  
 R(V5)/S(V1) : 1.88/0.71 mV  
 R(V5)+S(V1) : 2.59 mV

Normal Sinus Rhythm;  
 Cardiac electric axis normal;  
 ST depression, mild opical myocardial ischemia;  
 ST depression, possible mild anterolateral myocardial ischemia;  
 ST depression, possible mild anterolateral myocardial ischemia;  
 II III aVF V3 V4 V5 V6 Abnormal T wave;

\*\*Report need physician confirm\*\*

Physician \_\_\_\_\_

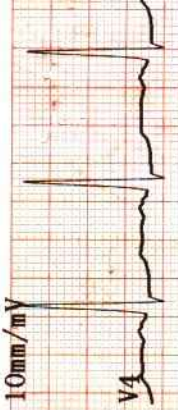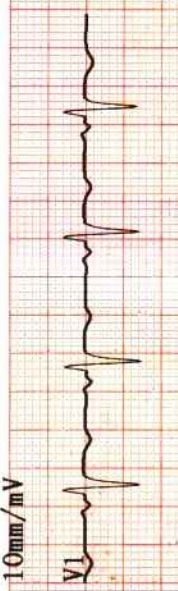
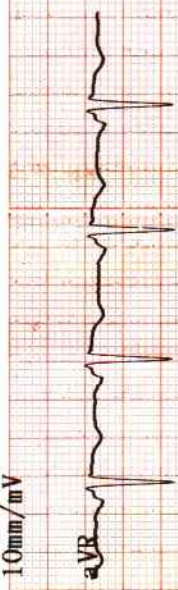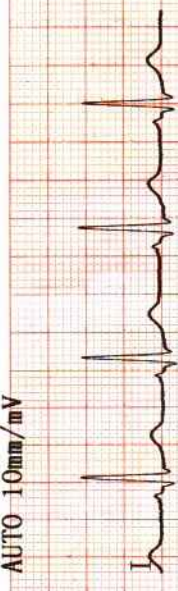**DR. Paltavi Misra**  
 (GENERAL MEDICINE)  
 MBBS, MD  
 MCI Reg. No.52033

AUTO 10mm/mV

10mm/mV

10mm/mV

10mm/mV



25mm/s AC50Hz +EMG35Hz +DFT