


CERTIFICATE OF MEDICAL FITNESS

This is to certify that I have conducted the clinical examination

of Vandana Patil on 26/08/2023

After reviewing the medical history and on clinical examination it has been found that he/she is

| | Tick |
|--|-------------------------------------|
| <ul style="list-style-type: none">• Medically Fit | <input checked="" type="checkbox"/> |
| <ul style="list-style-type: none">• Fit with restrictions/recommendations <p>Though following restrictions have been revealed, in my opinion, these are not impediments to the job.</p> <p>1.....</p> <p>2.....</p> <p>3.....</p> <p>However the employee should follow the advice/medication that has been communicated to him/her.</p> <p>Review after _____</p> | <input type="checkbox"/> |
| <ul style="list-style-type: none">• Currently Unfit. Review after _____ recommended | <input type="checkbox"/> |
| <ul style="list-style-type: none">• Unfit | <input type="checkbox"/> |


Dr. 
Medical Officer
The Apollo Clinic, (Location)
Dr. Sunil Suryawanshi
M.D. (Medicine)
Reg. No. 2223

This certificate is not meant for medico-legal purposes

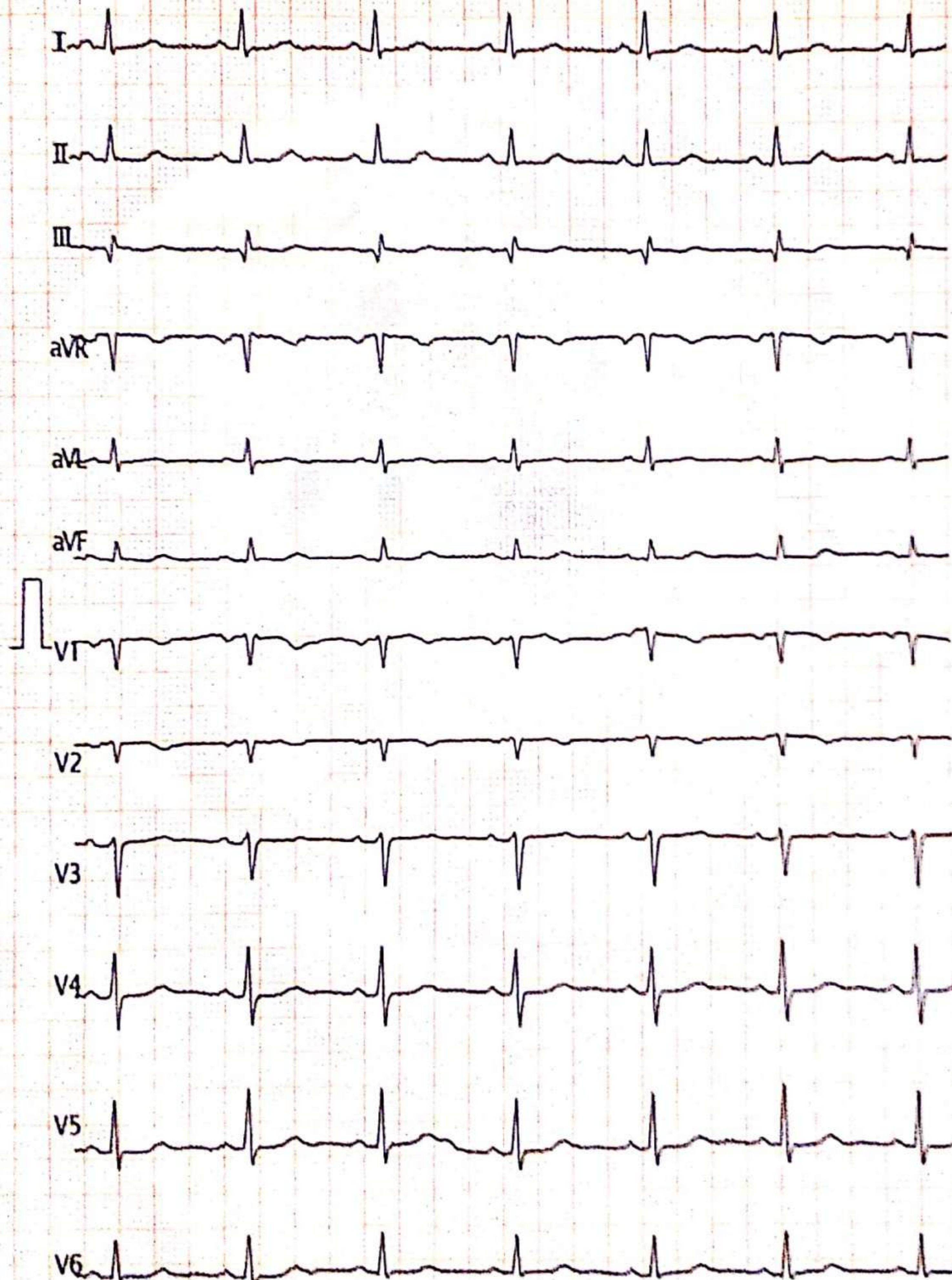
MER- MEDICAL EXAMINATION REPORT

| | | |
|---|---------------|--|
| Date of Examination | 26/08/2023 | |
| NAME | Vandana Patil | |
| AGE | 51 years | Gender: Female |
| HEIGHT(cm) | 165 | WEIGHT (kg): 82 |
| B.P. | 120/80 | |
| ECCG | | ✓ |
| X Ray | | ✓ |
| Vision Checkup | | Color Vision : normal/normal } with Far Vision Ratio : 6/6 / 6/6 } specs Near Vision Ratio : normal/normal } |
| Present Ailments | | No any. |
| Details of Past ailments (If Any) | | Diabetes & Hypertension : 11 years, Hysterectomy done in 2016. |
| Comments / Advice : She /He is Physically Fit | | Fit. |
| On Tab. Zoyal m 4 100 Tab. Napavel md 500 100 Tab pregabid CR 100 | | |

BMI => 30.37


 Signature with Stamp of Medical Examiner
 Dr. Sunil Suryawanshi
 M.D.(Medicine)
 Reg.No.2223

10mm/mV



Vent. Rate(BPM) : 78

PR Int.(ms) : 138

P/QRS/T Int.(ms) : 101 93 173

QT/QTc Int.(ms) : 406 466

P/QRS/T Axis(Deg.) : 31 35 83

RV1/SV5 Amp.(mV) : 0.00 0.23

RV5/SV1 Amp.(mV) : 0.78 0.36

<ECG Analysis Result>:

800 Normal Sinus Rhythm

421 Electronic Pacemaker?

861 Premature Ventricular Complexes

701 Poor R Progression

*** Abnormal ECG ***

Normal

Signature

V2.35 Technician :

Note : Unconfirmed Report Need to Review.

Dr. Sunil Suryawanshi
M.D.(Medicine)
Reg.No.2223

ST LEVEL(mV)

| | | | | | |
|-------|-------|-------|-------|-------|-------|
| I | II | III | aVR | aVL | aVF |
| +0.01 | +0.00 | +0.00 | -0.01 | +0.00 | +0.00 |
| VI | V2 | V3 | V4 | V5 | V6 |
| +0.00 | -0.00 | +0.03 | +0.01 | -0.01 | +0.02 |

24 अंश 41

51 years

<VANDANA PATIL > 774000002490 F 59 / 64 cm/Kg 2 / 5 m/s

डॉ. सौ. जयश्री सुर्यवंशी
एम.डी.
(स्त्रीरोग व प्रसूतीशास्त्र तज्ञ)
रजि.नं. 3712

डॉ. सुनिल सुर्यवंशी
एम.डी.(मेडीसीन) पुणे
कन्सल्टिंग फिजिशियन
रजि.नं. 2223

पत्ता : मेन टेलिफोन एक्सचेंज समोर, पारिख
पार्क जवळ, नविन बस स्टॅन्डच्या मागे,
जळगांव. फोन : (0257) 2227821

उपलब्ध सुविधा : • एक्स-रे • सोनोग्राफी • इकोकार्डिओग्राफी • सुसज्ज ऑपरेशन थिएटर • कॉम्प्युटराईज्ड इ.सी.जी. • स्ट्रेस टेस्ट • पल्मोनरी फंक्शन टेस्ट

Rx

दि / / २०

X-RAY CHEST PA VIEW

NAME- VANDANA PATIL

AGE- 51 YRS / FEMALE DATE-26.08.23

SOFT TISSUE AND SKELETON NORMAL.

NORMAL CARDIAC SIZE .

BOTH HILA ARTE NORMAL IN SIZE AND HAVE EQUAL DENSITY.

PROMINENT BRONCHOVASCULAR MARKINGS .


COSTOPHRENIC AND CARDIOPHRENIC ANGLES ARE CLEAR.

THE DOMES OF DIAPHRAGMS ARE NORMAL IN POSITION AND SHOW
SMOOTH OUTLINE.

THE PLURAL SPACES ARE NORMAL.

IMPRESSION –

NORMAL XYAY CHEST


Dr. Sunil Suryawanshi
M.D.(Medicine)
Reg.No.2223

परत येतांना कागद सोबत आणावा.

डॉ. सौ. जयश्री सुर्यवंशी
एम.डी.
(स्त्रीरोग व प्रसुतीशास्त्र तज्ञ)
रजि.नं. 3712

डॉ. सुनिल सुर्यवंशी
एम.डी. (मेडीसीन) पुणे
कन्सल्टिंग फिजिशियन
रजि.नं. 2223

पत्ता : मेन टेलिफोन एक्सचेंज समोर, पारिख
पार्क जवळ, नविन बस स्टॅण्डच्या मागे,
जळगांव. फोन : (0257) 2227821

उपलब्ध सुविधा : • एक्स-रे • सोनोग्राफी • इकोकार्डिओग्राफी • सुसज्ज ऑपरेशन थिएटर • कॉम्प्युटाईज्ड इ.सी.जी. • स्ट्रेस टेस्ट • पल्मोनरी फंक्शन टेस्ट

R

दि / / 20

2D – Echocardiograph

Name – VANDANA ARUN PATIL

Age- 49 Yrs FEMALE

Date – 26/08/2023

IMPRESSION –

NORMAL SIZE CARDIAC CHAMBERS.

STRUCTURALLY NORMAL CARDIAC VALVES

NORMAL LV SYSTOLIC FUNCTION , EF- 60 %.

NORMAL LV DIASTOLIC FUNCTION .

NO RWMA.

NO CLOTS OR VEGETATION.

IAS AND IVS INTACT.

NORMAL PERICARDIUM.G

Dr Sunil Suryawanshi

M D medicine.

Dr. Sunil Suryawanshi
M.D.(Medicine)
Reg.No.2223

परत येतांना कागद सोबत आणावा.

Cardiac Func. Exam.

<M mode LV Function>

| | Pombo | Teichholz |
|-----|---------|-----------|
| EDV | 102ml | 101ml |
| ESV | 23ml | 37ml |
| SV | 73ml | 64ml |
| CO | 5.60l/m | 4.82l/m |
| EF | 72.0% | 63.7% |
| FS | 34.0% | |
| HR | 76BPM | |

| | Diaatole | Systole |
|------|----------|---------|
| LVID | 47mm | 31mm |
| IVS | 8mm | 10mm |
| LVPW | 7mm | 11mm |

| <LA/AO> | Diaatole | Systole |
|---------|----------|---------|
| LA Diam | | 33mm |
| AO Diam | 29mm | |
| AV Diam | | 20mm |

| | | |
|-----------|------|-----|
| LADa/AOcd | 1.12 | AVA |
|-----------|------|-----|

<Mitral Valve>

| | | | |
|-----------|--------|---------|------|
| C-E amp | 16mm | C-A amp | 12mm |
| E-F slope | 58mm/s | EPSS | 4mm |

| | |
|-----|------|
| E/A | 1.31 |
| MVA | |

<Aortic Stenosis Flow Doppler>

| | | | |
|--------|-----------|------------|----------|
| Peak V | 119.2cm/s | Mean V | 83.8cm/s |
| VTI | 24.8cm | VTI (LVOT) | |
| LVOT | | CSA (LVOT) | |

| | | | |
|---------|---------|---------|---------|
| AVA | | | |
| Peak PG | 5.7mmHg | Mean PG | 3.1mmHg |

<Trans Mitral Flow Doppler>

| | | | |
|--------|----------|-------|------|
| Peak E | 72.9cm/s | | |
| Peak A | 67.6cm/s | Adur | |
| PVAdur | | | |
| VTI | | | |
| DecT | | P1/2T | 50ms |

| | | | |
|-------------|---------------------|-----|--|
| MVA(P1/2T) | 3.76cm ² | MVA | |
| E/A | 1.08 | | |
| PVAdur-Adur | | | |

<Pulmonary Stenosis Flow Doppler>

| | | | |
|---------|-----------|---------|----------|
| Peak V | 101.4cm/s | Mean V | 69.5cm/s |
| Peak PG | 4.1mmHg | Mean PG | 2.1mmHg |

<Tricuspid Stenosis Flow Doppler>

| | | | |
|---------|-----------|---------|----------|
| Peak V | 108.5cm/s | Mean V | 40.3cm/s |
| P1/2T | 8ms | | |
| Peak PG | 4.7mmHg | Mean PG | 0.7mmHg |

<Comments>

Physician's SIGNATURE :

[Signature]
Dr. Sunil Suryawanshi
 M.D. (Medicine)
 Reg. No. 2223

DR. CHETAN S. KAKLIYA

M.B.B.S., D.M.R.D. (Sion Hospital, Mumbai University)

• Ex-Consultant Radiologist In Asian Heart Hospital (Mumbai)

• Ex - Radiologist Wockhardt Hospital (Mulund)



SAGAR IMAGING CENTRE

• Whole body sonography • Colour doppler • Digital X-ray

54-B, Onkar Nagar, Near Parikhpark, Jalgaon - 425001. Phone : 0257-2237634, e-mail : drchetanjj@rediffmail.com

| | | | |
|--------|------------------------------|---------|--------------|
| Name | : VANDANA PATIL | Date | : 26-08-2023 |
| Ref By | : DR. SUNIL SURYAWANSHI M.D. | Age/Sex | : - / Female |

SONOGRAPHY OF ABDOMEN AND PELVIS

The liver is normal in size, shape and has smooth margins. No focal lesion. The portal vein appears normal.

The gall bladder is physiologically distended. No evidence of calculus, wall thickening or mass lesion.

The common bile duct is normal in caliber. No evidence of calculus is noted in common bile duct.

The pancreas is normal in size, shape, contours and echo texture. No evidence of focal lesion is noted.

The spleen is normal in size and shape. No evidence of focal lesion is noted.

There is no evidence of enlarged coeliac, mesentric, portal pre or para aortic lymph nodes.

The great vessels namely aorta and IVC and its visualized branches are normal. No evidence of ascitis or pleural effusion.

Both kidneys are normal in size and echotexture. No evidence of calculus, hydronephrosis or cortical scarring.

Right kidney measures - 9.0 x 4.5 cms.

Left kidney measures - 9.5 x 4.8 cms.

The urinary bladder is well distended. No evidence of calculus, wall thickening or mass lesion.

Uterus is not visualized (post op status).

No gross pelvic pathology is noted.

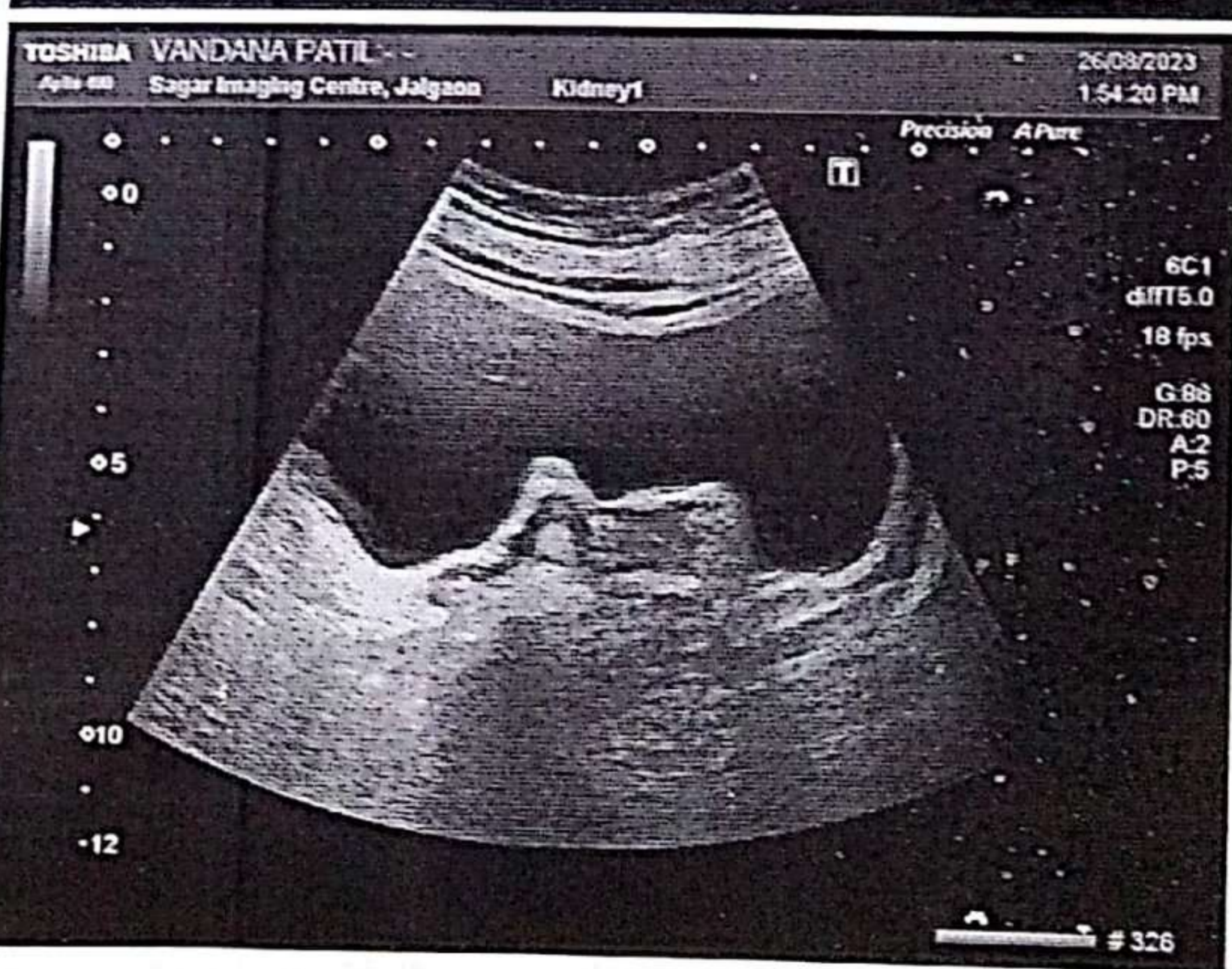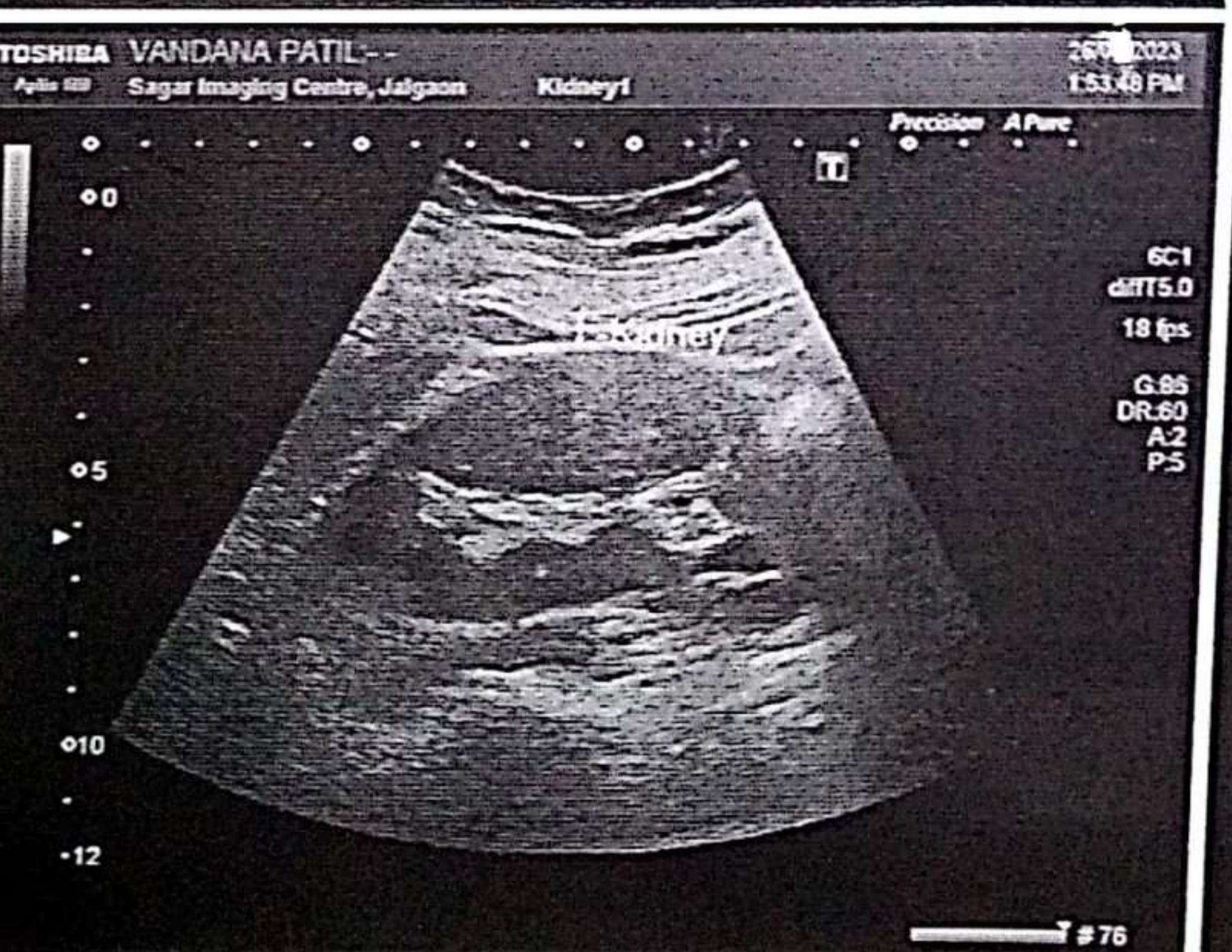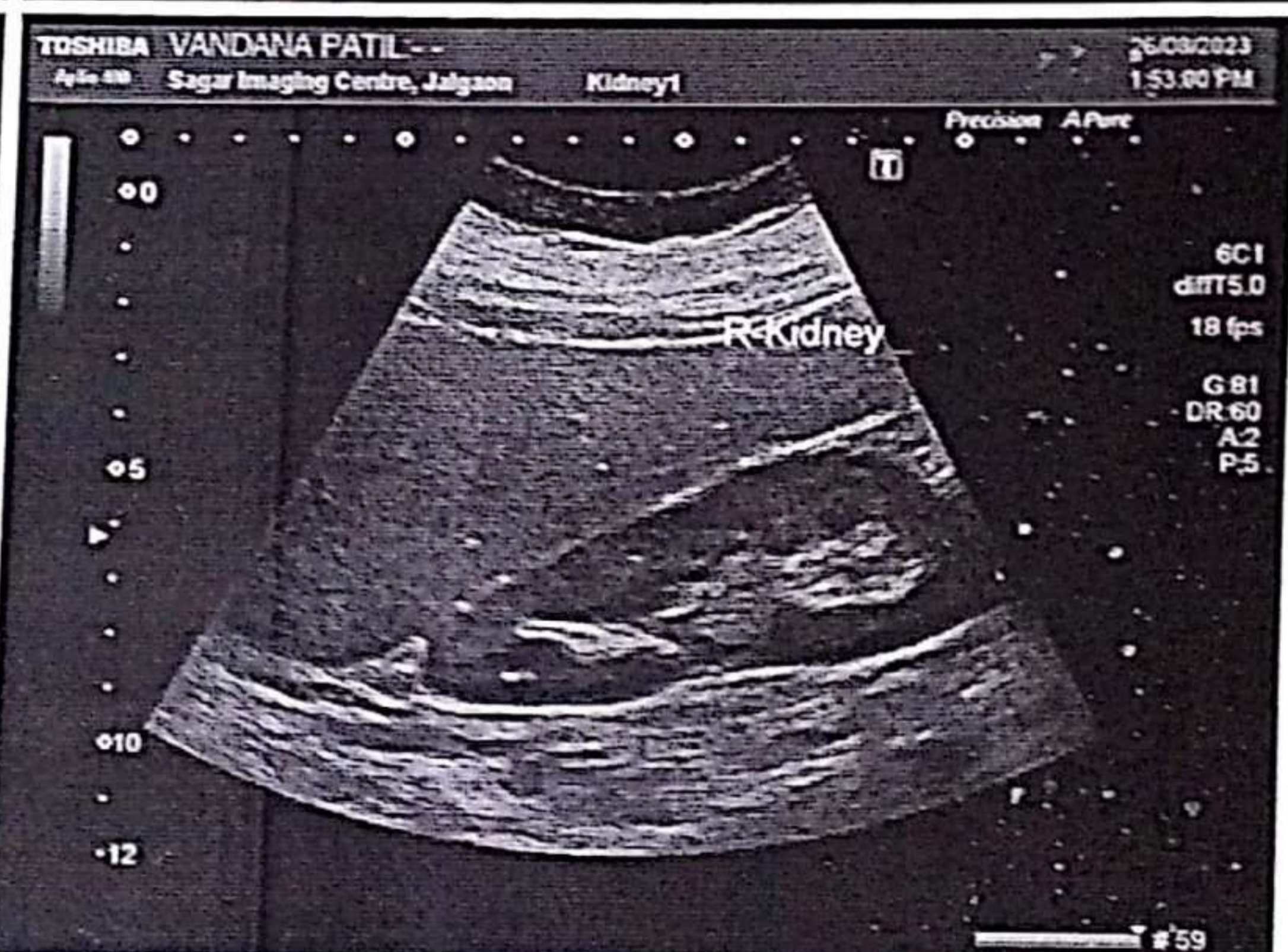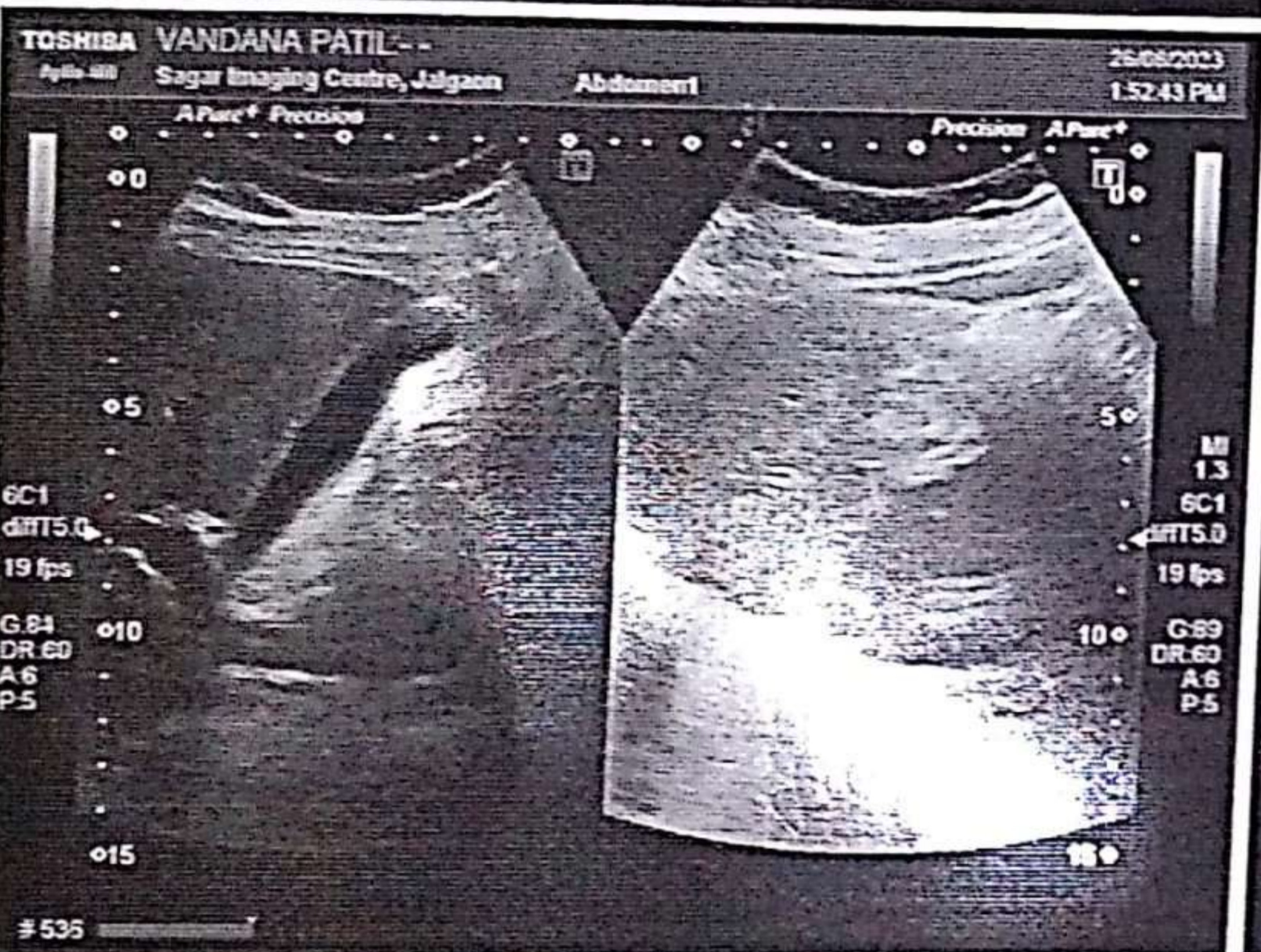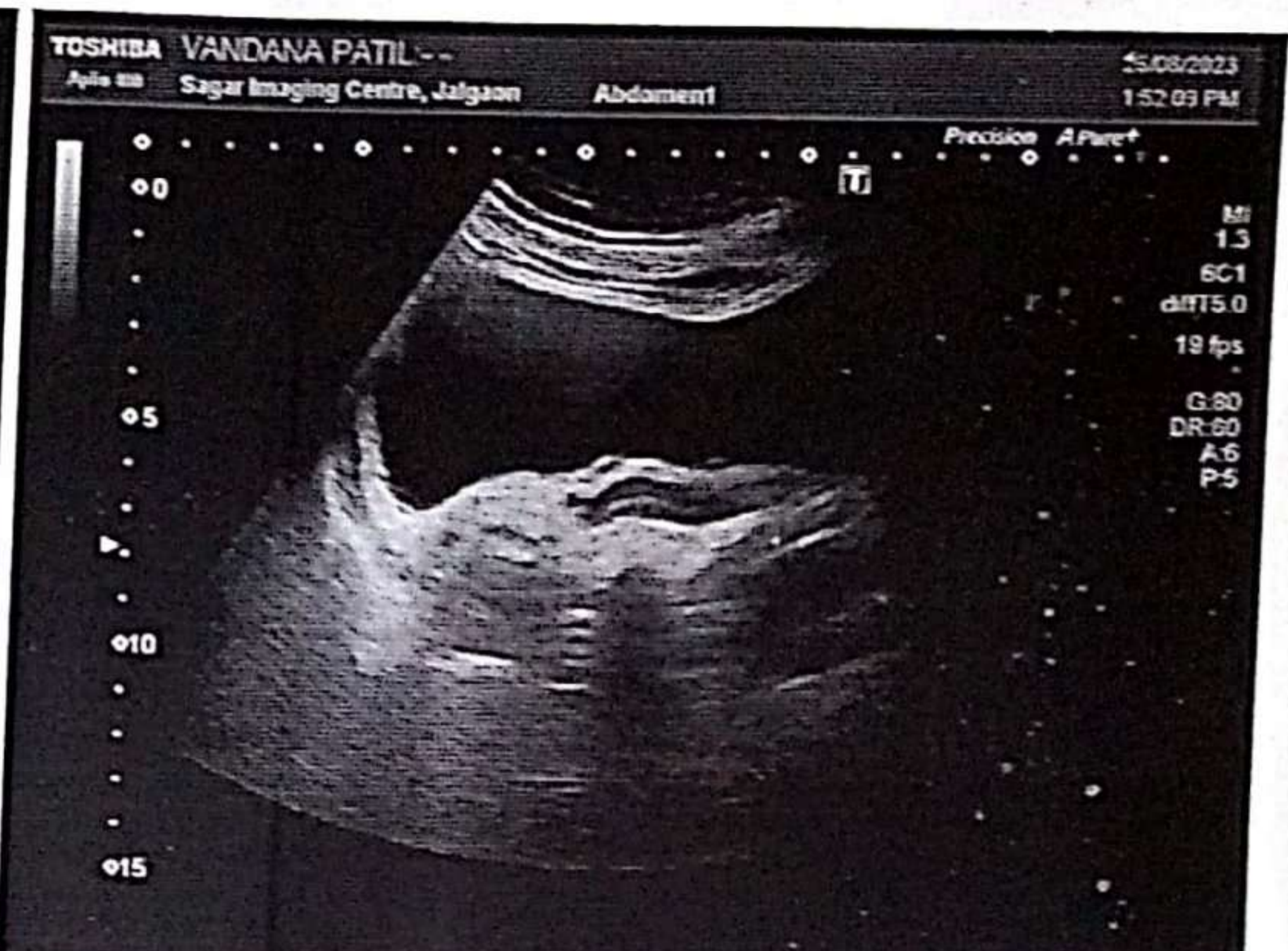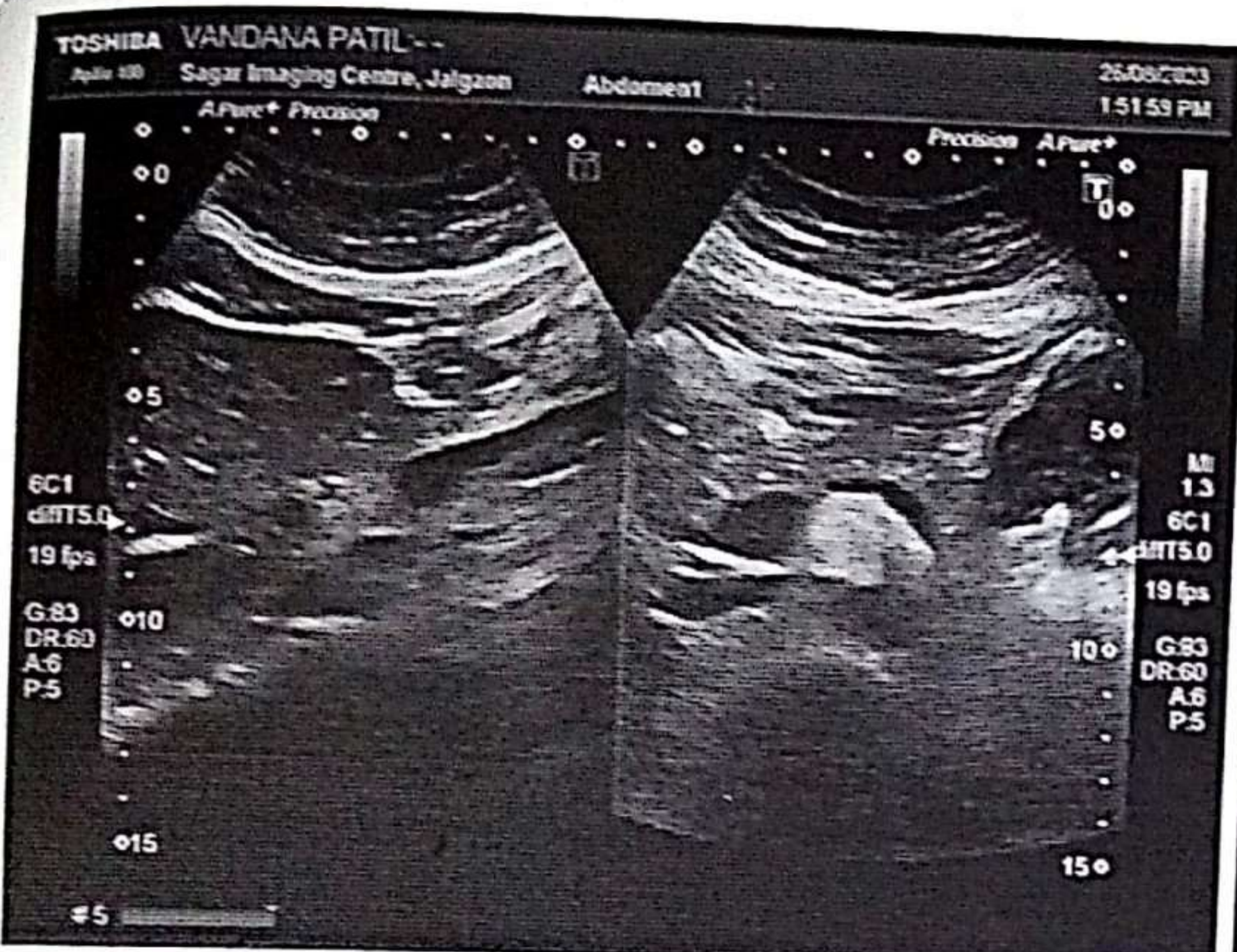IMPRESSION :

No significant abnormality is noted.

REPORT WITH THANKS.

Clinico pathological correlation is suggested.

DR. CHETAN KAKLIYA





भारत सरकार

Government of India



वंदना अरुण पाटिल

Vandana Arun Patil

जन्म तारीख/DOB: 28/04/1972

महिলা/ FEMALE

Issue Date: 26/11/2013

Download Date: 22/11/2019


6891 0520 7840

VID : 9149 4505 3242 0271

भारत सरकार, भारत की ओर



 **GPS Map Camera**



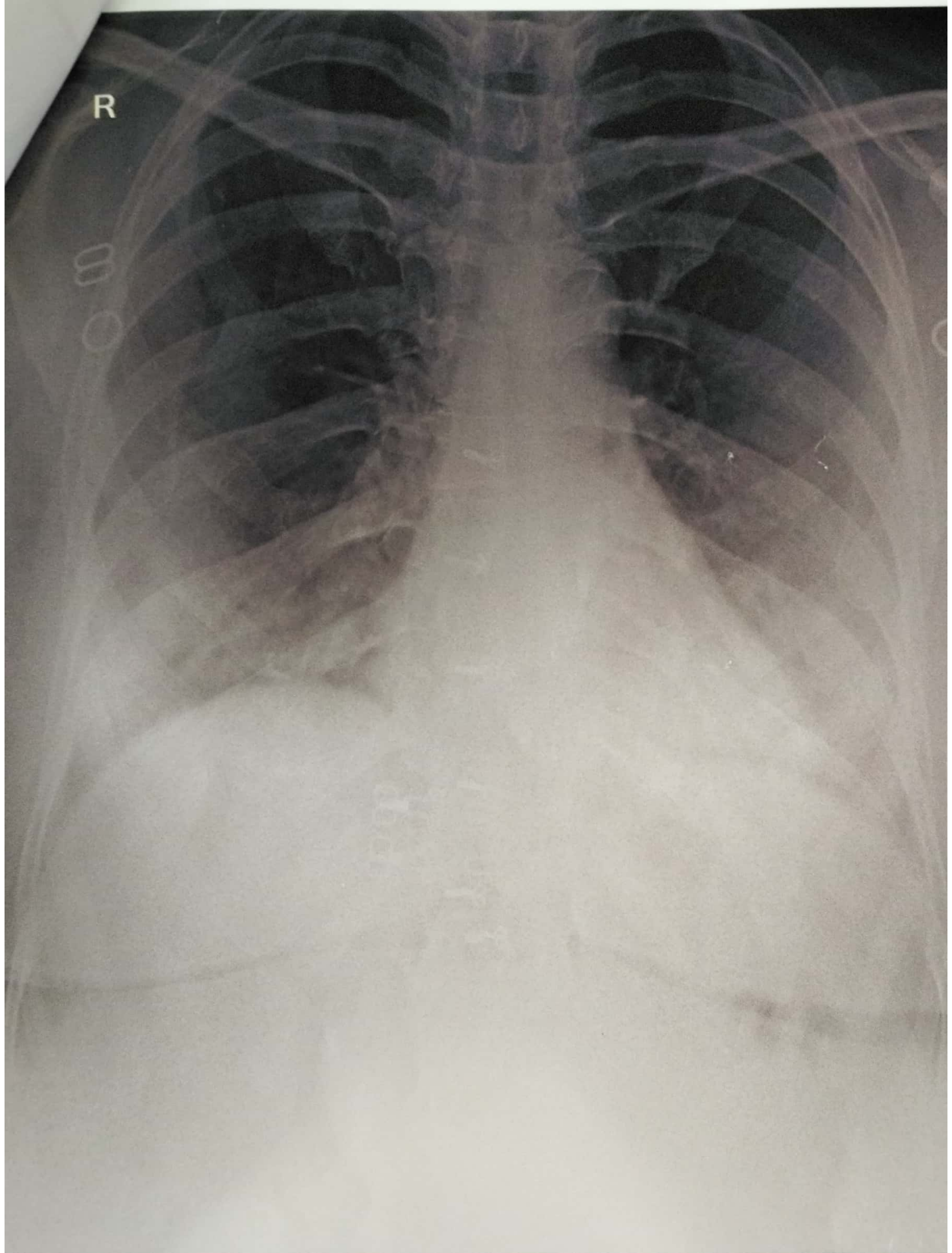
Jalgaon, Maharashtra, India

2H48+677, Swatantrya Chowk - Pande Chowk Rd, Patrakar Colony, Jaikisan Wadi, Jalgaon, Maharashtra 425001, India

Lat 21.005922°

Long 75.565696°

26/08/23 09:27 AM GMT +05:30



R

VANDANA PATIL 45 Y 268202302 CHEST PA 26-Aug-23

SUJAY HOSPITAL AND MATERNITY HOME, JALGAON

सुजय हॉस्पिटल व मॅटर्निटी होम

अतिदक्षता विभाग

डॉ.सौ. जयश्री सुर्यवंशी

एम.डी.
(स्त्रीरोग व प्रसूतीशास्त्र तज्ञ)
रजि.नं.३७९२

डॉ.सुनिल सुर्यवंशी

एम.डी.(मेडीसीन) पुणे
कन्सल्टिंग फिजिशियन हृदयरोग व मधुमेह तज्ञ
रजि.नं.२२२३

मेन टेलिफोन एक्सचेंज समोर, पारिक पार्क, नविन बस स्टॅन्डच्या मागे,
जळगांव. फोन:(०२५७) २२२७८२९

Rx

दि. 26/08/20 23

Vandana Arun Patil

Apollo, Clinic

ENT - normal

Dental - normal

Gynaec. checkup - Hysterectomy done in
2016 for excessive bleeding

G2L2L2
All FND.

Sunil

Dr. Sunil Suryawanshi

M.D.(Medicine)

Reg. No. 2223