

## Mumbai, Maharashtra, India

Nathani Height Belasid Road, Shop Number 41, Jehangir Boman Behram Rd, Opposite Mumbai Central Station, Marzban Parsi Colony, Dalal Estate, Mumbai Central, Mumbai, Maharashtra 400008, India


Lat 18.968771°

Long 72.819952°


09/10/21 09:22 AM

medishree

भारत सरकार  
GOVERNMENT OF INDIA




राजेंद्र बाबाजी चांदे  
Rajendra Babaji Chande  
जन्म तारीख/ DOB: 03/01/1968  
पुल्ल / MALE



5773 5605 0301

आधार-सामान्य माणसाचा अधिकार



'DR. PLUS HEALTHCARE CENTRE'  
NATHANI HEIGHTS', B-WING,  
42, MUMBAI CENTRAL (EAST)

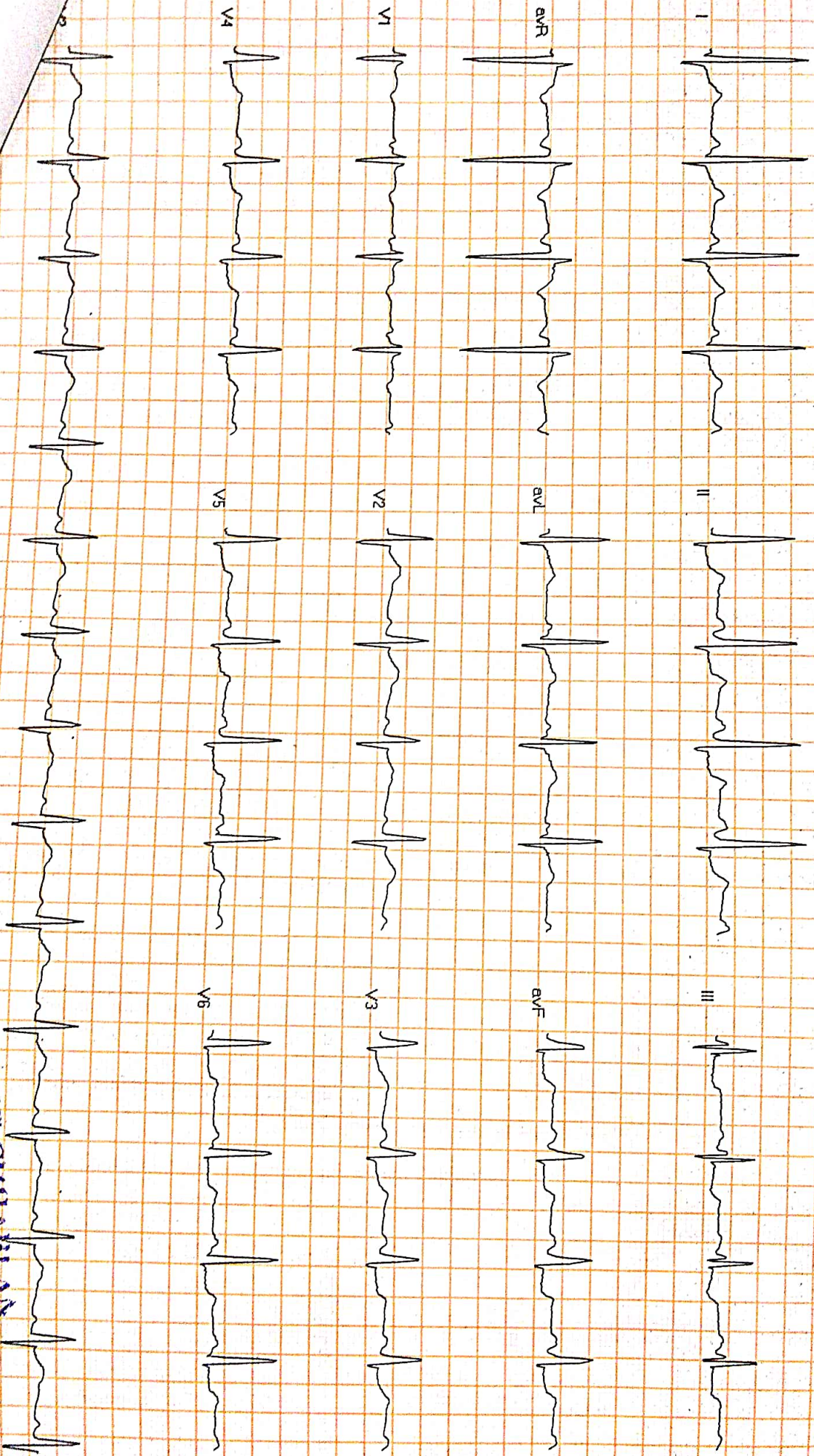
DR. HARI CHHABLANI  
M.B.B.S. (D. RESP. MEDICINE) PGDHM, PGDMLS  
FELLOW INTENSIVE CARE  
MMC REG. NO. - 91702

DR PLUS HEALTHCARE CENTRE- MUMBAI CENTRAL

ECG

1136 / RAJENDRA BABAJI CHANDE / 58 YRS / M

Heart Rate : 86 bpm / Tested On : 09-Oct-21 13:34:55 / HF 0.05 Hz - LF 100 Hz / Notch 50 Hz / Sn 1.00 Cm/mV / Sw 25 mm/s  
/ Refd By: DR. HARI CHHABLANI



DR. PURVI CHHABLAN

MBBS DNB (Medicine)  
Consultant Physician And Intensivist  
Reported By: DR. PURVI CHHABLANI

20  
risk of alcohol

# Dr-Plus Healthcare Centre

NATHANI HEIGHTS, B-Wing, Shop No. 42, Ground Floor, Opp. Mumbai Central Station (East), Mumbai - 400 008.

Patient Name	: RAJENDRA CHANDE	Sex:	Male
Doctor's Name	: SELF	Age:	53 Years
Date	: 09/10/2021		

## ULTRASONOGRAPHY OF THE ABDOMEN AND THE PELVIS:

The relevant sonographic findings include the following:

### HEPATOBIILIARY APPARATUS

The liver is normal in size and echogenicity. No obvious focal parenchymal lesion is seen. Extrahepatic biliary radicals are not dilated. The portal vein and the common bile duct are normal.

### GALL BLADDER

The gall bladder is adequately distended. The wall thickness is normal. No echogenic contents are noted in its lumen. There is no pericholecystic collection noted.

### PANCREAS

The pancreas shows normal echogenicity and size. No focal or diffuse lesions are noted. No evidence of calcification is noted.

### SPLEEN

The spleen appears normal in size and echogenicity. No focal or diffuse lesions are noted. No evidence of calcification is noted.

### KIDNEYS

Right Kidney measure: 10.92 x 4.01 cm, Left kidney measure: 10.33 x 4.49 cm  
Both the kidneys appear normal in size, shape and echogenicity. Both the pelvicalyceal system is normal and both corticomedullary differentiations are well maintained. There is no obvious focal or diffuse lesion noted. No evidence of any calculus seen in either kidney.

### URINARY BLADDER

The urinary bladder shows anechoic contents. Its wall thickness appears normal.

### PROSTATE

Prostate measures: 3.10 x 3.25 x 3.20 cm. Volume = 19 cc  
The Prostate appears normal and shows a normal echogenicity.

No evidence of calcification is seen.

There is no obvious evidence of abdominal or pelvic lymphadenopathy or ascites noted.

**IMPRESSION:** No significant abnormality is detected.

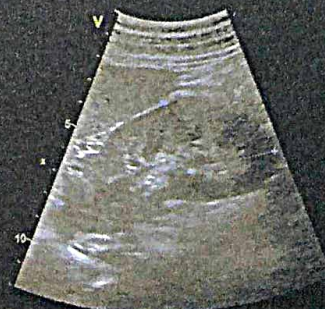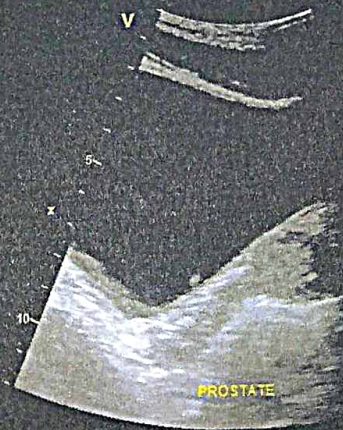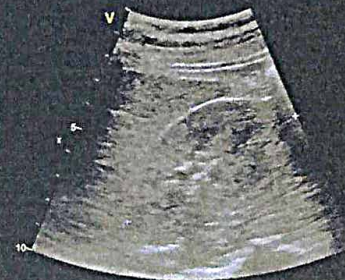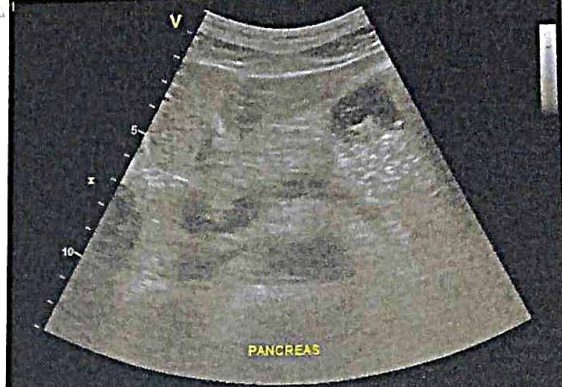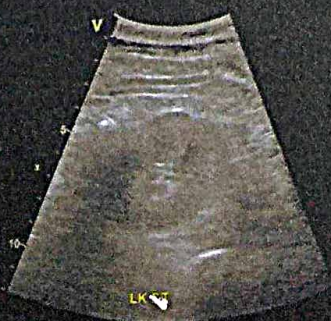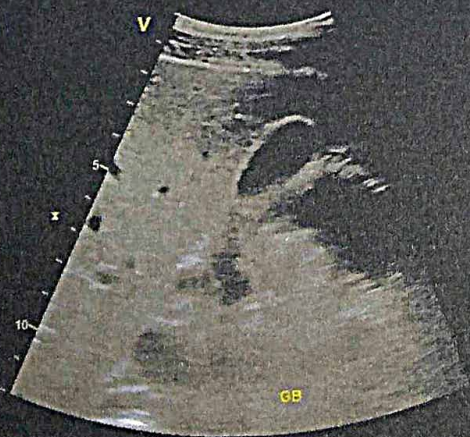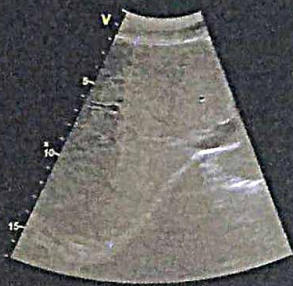
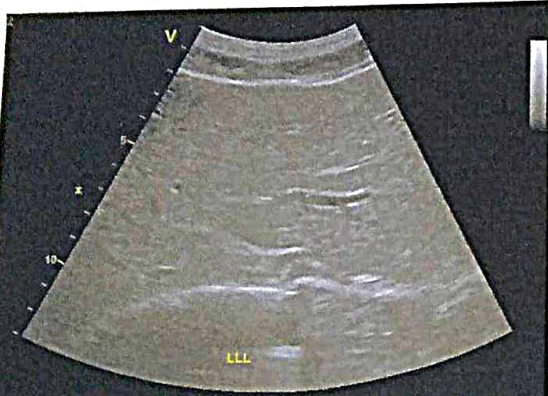Dr. Parag Jhaveri  
MBBS (BOM), DMRE (BOM)  
Radio-Sonologist

"DR. PLUS HEALTHCARE CENTRE"  
NATHANI HEIGHTS', B-WING  
42, MUMBAI CENTRAL (EAST)

Name **RAJENDRA CHANDE**

Sex **Male**

Age **53**



# Dr-Plus Healthcare Centre

NATHANI HEIGHTS, B-Wing, Shop No. 42, Ground Floor, Opp. Mumbai Central Station (East), Mumbai - 400 008.

Patient's Name : RAJENDRA CHANDE

Report Date :09/10/2021

Referred By : SELF

Age : 53 Years

Sex : MALE

## X- RAY CHEST PA

- No active pulmonary lesion seen.
- Trachea and mediastinum are in midline .
- Cardiac size and configuration are within normal limits .
- Pleural cavities are clear .
- Domes of diaphragm are smooth in outline.
- Bony thorax is normal .

Radiologist

DR. A. J. MAZUMDAR

MD. DMRE,MDRD

"DR. PLUS HEALTHCARE CENTRE"  
NATHANI HEIGHTS', B-WING,  
42, MUMBAI CENTRAL (EAST)

R-6

RAJENDRA CHANDE 53/M 09/10/2021

# Dr-Plus Healthcare Centre

NATHANI HEIGHTS, B-Wing, Shop No. 42, Ground Floor, Opp. Mumbai Central Station (East), Mumbai - 400 008.

Full Name of life to be assured:

RAJENDRA CHANDE

53/M

DATE:09/10/2021

## HAEMOGRAM

		Normal Range	
1.	Red Blood Cell Count	5.0	[M : 4.5 - 5.6 / F : 3.5 - 5.5/cu.mm]
2.	Hb%	14.8	[M: 14-18 / F : 11-16%]
3.	Hematocrit	46	[M : 40-53 / F : 30-47 %]
4.	Indices:		
(a)	MCV(Mean Corpuscular Volume)	89	[79-101 cu.mi.]
(b)	MCH(Mean Corpuscular Hb)	30	[27-32 pg]
(c)	MCHC(Mean Corpuscular Hb Concentration)	36	[32-38%]
5.	Morphology		
	Macrocytes :	--	Microcytes: --
	Piokilocytosis:	--	Anisocytosis: --
	Target cells:	--	Hypochromia: --
	Spherocytes:	--	Elliptocytes: --
7.	<b>TOTAL W.B.C.Count</b>	8,500	{4000-11000/cu.mm}
Differential Count 0			
a)	Neutrophils :	66	[45 -70%]
b)	Lymphocytes :	23	[20 - 45%]
c)	Eosinophils:	06	[01 - 06%]
d)	Monocytes:	05	[00 - 08%]
e)	Basophils :	00	[00 - 01%]
8.	<b>Platelets : 3.2</b>	1.5-4.5 Lacks/cu.mm	
9.	<b>Erythrocyte Sedimentation Rate:09</b>	20 mm at end of 1 hour	
		Method : Westergrens	

## ROUTINE URINE EXAMINATION (RUA)

### 1. Physical Examination:

(i)	Colour:	PLAN YELLOW	(ii)	Sediment:	CLEAR
(iii)	Transparency:	ABSENT	(iv)	Reaction:	ACIDIC
(v)	Specific gravity	1.015			

### 2. Chemical Examination:

(i)	Protein :	ABSENT	(ii)	Sugar:	ABSENT
(iii)	Bile salt:	ABSENT	(iv)	Bile pigment:	ABSENT

### 3. Microscopic Examination:

(i)	Red Blood Cells:	ABSENT	(ii)	Epithelial Cells:	ABSENT
(iii)	Crystals:	ABSENT	(iv)	Pus Cells:	02 TO 03/HPF
(v)	Casts:	ABSENT	(vi)	Deposits:	ABSENT
(vii)	Bacteria's :	ABSENT			

**DR. RAKESH PATKAR**  
M.D., D.N.B. (Pathology)  
Reg. No. 2013/05/1660



# Dr-Plus Healthcare Centre

NATHANI HEIGHTS, B-Wing, Shop No. 42, Ground Floor, Opp. Mumbai Central Station (East), Mumbai - 400 008.

Full Name

RAJENDRA CHANDE

53/M

DATE:09/10/2021

	Type of Test	Actual Reading	Normal Range
1	Fasting Blood Sugar	94	70-100 mg%
2	PPBS	132	110 TO 140 mg%
3	Total Cholesterol	187	120-200 mg%
4	VERY LOW DENSINTY LEVEL(VLDL)	12	10-30 mg/dl
5	High Density Lipid (HDL)	56	40-60 mg%
6	Low Density Lipid (LDL)	119	<u>Upto 150</u>
7	S. Triglycerides	138	50-150 mg%
8	CHOL/HDL	3.3	Upto 5
9	HDL/LDL	0.4	
10	S. Creatinine	0.7	0.5-1.2 mg%
11	Blood Urea Nitrogen (BUN)	14	7-21 mg%
12	BUN/CREAT RATIO	20	
13	S. Proteins	7.1	6.0-7.9 mg%
14	(a) Albumin	4.0	3.5-5.5 mg%
15	(b) Globulin	3.1	2.0-3.5 mg%
16	A/G RATIO	1.2	
17	S. Bilirubin	1.1	0.3-1.3mg%
18	(a) Direct	0.6	0.0-0.8 mg%
19	(b) Indirect	0.5	0.0-0.5 mg%
20	SGOT (AST)	33	05-34 IU
21	SGPT (ALT)	27	05-40 IU
22	GGTP (GGT)	38	05-50 IU
23	SGOT/SGPT	1.2	
24	HBA1C	5.3	UPTO 6.5
25	S. Alkaline Phosphatase	96	30-115 IU
26	T3	176	80-180ng/dl
27	T4	5.1	4.6-12 ug/dl
28	TSH	3.9	0.4-4.0 mIU/L
29	SERUM URIC ACID	6.6	2.5-7.2mg/dl
30	URINE SUGAR PP	ABSENT	
31	URINE SUGAR FASTING	ABSENT	
32	BLOOD GROUP	"B" POSITIVE"	

DR. RAKESH PATKAR  
M.D. (N.B. (P) (1997))  
Reg. No. 2013/05/1660