



இந்திய அரசாங்கம்
Unique Identification Authority of India
Government of India

பதிவேட்டு எண்/ Enrolment No.: 2040/20513/10087

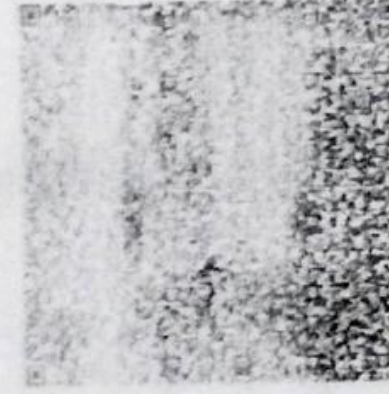
To
பவித்ரா ரா
Bavithra R
D/O: Ramachandran
14 B
SENGUNTHAR NORTH STREET
AMBASAMUDARAM
Ambasamudram
Ambasamudram
Tirunelveli Tamil Nadu - 627401
9443086729

Download Date: 22/08/2018

Generation Date: 06/09/2014

Signature valid

Digital Signature
UNIQUE IDENTIFICATION
AUTHORITY OF INDIA
Date: 2014.09.06 12:08:55
IST



QR Code with Photograph

உங்கள் ஆதார் எண் / Your Aadhaar No. :

2324 7964 6613

VID : 9136 2932 0514 9162

எனது ஆதார், எனது அடையாளம்



இந்திய அரசாங்கம்
Government of India



பவித்ரா ரா
Bavithra R
பிறந்த நாள்/DOB: 28/11/1993
பெண்/ FEMALE

2324 7964 6613

VID : 9136 2932 0514 9162

எனது ஆதார், எனது அடையாளம்

Bavithra




தகவல்

- ஆதார் அடையாளத்திற்கான சான்று, குடியுரிமைக்கு அல்ல
- அடையாள சான்றை ஆன்லைன் ஆதன்கேஷன் மூலமாக பெறவும்.
- இது எலக்ட்ரானிக் செயல்முறை மூலம் தயாரிக்கப்பட்ட கடிதமாகும்.

INFORMATION

- Aadhaar is a proof of identity, not of citizenship.
- To establish identity, authenticate online.
- This is electronically generated letter.


- ஆதார் நாடு முழுவதிலும் செல்லுபடியாகும்.
- வருங்காலத்தில் அரசு மற்றும் அரசு சாரா சேவைகளை பயன்படுத்திக் கொள்ள ஆதார் உதவிகரமாக இருக்கும்.
- Aadhaar is valid throughout the country.
- Aadhaar will be helpful in availing Government and Non-Government services in future.



இந்திய அடையாள அமைப்பு
Unique Identification Authority of India

முகவரி:
த/பெ: ராமச்சந்திரன், 14 பி, செங்குந்தர் வடக்கு தெரு, அம்பாசமுத்திரம், அம்பாசமுத்திரம், திருநெல்வேலி, தமிழ் நாடு - 627401

Address:
D/O: Ramachandran, 14 B, SENGUNTHAR NORTH STREET, AMBASAMUDARAM, Ambasamudram, Tirunelveli, Tamil Nadu - 627401



2324 7964 6613

VID : 9136 2932 0514 9162



LAB REPORT

Patient Name : Mrs. BAVITHRA.R
 Age / Gender : 28-Years / Female
 UHID ID : MH20220041277
 Doctor Name : Dr. ARUN PRAKASH
 OP Report No. : INVA2107629
 Bill No. : INV2205113
 Sample Date : 06/11/2022 - 09:30 AM
 Report Date : 06/11/2022 - 02:26 PM

| Test Name | Result | Units | Reference Interval |
|---------------------------------------|-------------|----------------------|--|
| HAEMATOLOGY | | | |
| Complete Blood Cell Count(CBC) | | | |
| HAEMOGLOBIN | 13.2 | gms/dl | male :13.0 - 17.0 female :12.0 - 15.0 |
| PACKED CELL VOLUME | 41.4 | % | male : 40 - 50 female : 36 - 46 |
| RBC COUNT | 4.97 | millions cells/cu.mm | female: 3.8 - 4.8 male : 4.5 - 5.5 |
| TOTAL WBC | 8,000 | Cells/Cumm | 4,000 - 11,000 |
| Differential Count | | | |
| NEUTROPHILS | 62 | % | 40 - 65 |
| LYMPHOCYTES | 32 | % | 30-50 |
| EOSINOPHILS | 06 | % | 01-06 |
| MONOCYTES | <u>00</u> | % | 1-10 |
| BASOPHILS | 00 | % | 0-2 |
| ESR 60 MTS | 10 | mm | 5 - 20 |
| PLATELET COUNT | 3.71 | Lakhs/cumm | 1.5 - 4.5 |
| MCV | 83.4 | fL | 76 - 96 |
| MCH | <u>26.5</u> | pg | 27 - 32 |
| MCHC | 31.8 | gms/dl | 30 - 36 |

INTERPRETATION: Test done on automated three part cell counter ,all abnormal results are reviewed and confirmed microscopically

BLOOD GROUPING & RH TYPING " O " POSITIVE

Healing Hearts and Lives

264/125, Kilpauk Garden Road, Kilpauk, Chennai - 600 010.
 Phone : +91 44 4644 8989 / 75500 53335 | Email : muruganhosp@gmail.com
 Website : www.muruganhospitals.in



LAB REPORT

Patient Name : Mrs. BAVITHRA.R
Age / Gender : 28-Years / Female
UHID ID : MH20220041277
Doctor Name : Dr. ARUN PRAKASH

OP Report No. : INVA2107629
Bill No. : INV2205113
Sample Date : 06/11/2022 - 09:30 AM
Report Date : 06/11/2022 - 02:26 PM

| Test Name | Result | Units | Reference Interval |
|---------------------------|--------|-------|----------------------------------|
| BIO CHEMISTRY | | | |
| BLOOD SUGAR FASTING | 96 | mg/dl | 70-110 |
| BLOOD SUGAR POST PRANDIAL | 120 | mg/dl | 80- 160 |
| SERUM URIC ACID | 3.9 | mg/dl | male 3.1-7.0 , female 2.5-5.6 |
| SERUM CREATININE | 0.8 | mg/dl | 0.6-1.4 |
| LIPID PROFILE | | | |
| TOTALCHOLESTEROL | 175 | mg/dl | < 200 |
| TRIGLYCERIDE | 140 | mg/dl | < 150 |
| HDL | 44 | mg/dl | 35 - 80 |
| VLDL | 28 | mg/dl | 2 to 30 |
| LDL | 103 | mg/dl | <130 |
| CHOLESTEROL/ HDL RATIO | 3.9 | mg/dl | |



LAB REPORT

Patient Name : Mrs. BAVITHRA.R
Age / Gender : 28-Years / Female
UHID ID : MH20220041277
Doctor Name : Dr. ARUN PRAKASH

OP Report No. : INVA2107629
Bill No. : INV2205113
Sample Date : 06/11/2022 - 09:30 AM
Report Date : 06/11/2022 - 02:26 PM

| Test Name | Result | Units | Reference Interval |
|----------------------------|--------|-------|--|
| LIVER FUNCTION TEST | | | |
| BILLIRUBIN(TOTAL) | 0.4 | mg/dl | 0.0 -1.0 |
| BILLIRUBIN(DIRECT) | 0.1 | mg/dl | 0.1- 0.30 |
| BILLIRUBIN(INDIRECT) | 0.3 | mg/dl | 0.2-0.8 |
| SGOT | 14 | IU/L | 0-38 |
| SGPT | 20 | IU/L | 0.0-40 |
| ALKALINE PHOSPHATASE | 112 | IU/L | 40-140 4-6Years 93-309 13-15Years 74-390 |
| TOTAL PROTEIN | 7.2 | gm/dl | 6.6-8.7 |
| ALBUMIN | 4.2 | gm/dl | 3.5 - 5.5 |
| GLOBULIN | 3.0 | gm/dl | 2.0-3.5 |
| AG RATIO | 1.4 | | |
| GAMMA G T | 17 | U/L | male<49 female<32 |
| BLOOD UREA NITROGEN | 7.4 | mg/dl | 7-21 |
| HBA1C | 5.5 | % | normal: <6.0 good control: 6.1-7.0 fair control: 7.1- 8.0 poor control:8.1 -10.0 unsatisfactory: >10.0 |



MURUGAN HOSPITALS

HEALING HANDS



LAB REPORT

Patient Name : Mrs. BAVITHRA.R
 Age / Gender : 28-Years / Female
 UHID ID : MH20220041277
 Doctor Name : Dr. ARUN PRAKASH

OP Report No. : INVA2107629
 Bill No. : INV2205113
 Sample Date : 06/11/2022 - 09:30 AM
 Report Date : 06/11/2022 - 02:26 PM

| Test Name | Result | Units | Reference Interval |
|---------------------------|-------------|-------|--------------------|
| CLINICAL PATHOLOGY | | | |
| URINE SUGAR (F) | NIL | | |
| URINE SUGAR (PP) | NIL | | |
| URINE ROUTINE | | | |
| COLOUR | PALE YELLOW | | |
| APPEARANCE | CLEAR | | |
| REACTION | ACIDIC | | |
| SUGAR | NIL | | |
| ALBUMIN | NIL | | |
| DEPOSITES | | | |
| PUS CELLS | 1 - 2 | / HPF | |
| EPI CELLS | 2 - 4 | / HPF | |
| RBC COUNT | NIL | / HPF | |
| CAST | NIL | | |
| CRYSTALS | NIL | | |
| OTHERS | NIL | | |

SHENBAGAVALLI
 Verified by

*** End of Report ***



Healing Hearts and Lives

264/125, Kilpauk Garden Road, Kilpauk, Chennai - 600 010.
 Phone : +91 44 4644 8989 / 75500 53335 | Email : muruganhosp@gmail.com
 Website : www.muruganhospitals.in

Scanned by TapScanner



LAB REPORT

| | | | |
|---------------|-------------------|----------------|---------------------|
| NAME : | MRS. BAVITHRA R | SAMPLE NO : | 3822107565 |
| PIN : | AND22380162805 | COLLECTED ON : | 06/11/2022 03:00 PM |
| AGE/GENDER : | 28 Year(s)/Female | RECEIVED ON : | 06/11/2022 03:01 PM |
| REFERRED BY : | Dr.ARUN PRAKASH | REPORTED ON : | 08/11/2022 11:21 AM |
| CLIENT NAME : | MURUGAN HOSPITAL | REPRINT DATE : | 08/11/2022 11:21 AM |

Liquid PAP smear (by Liquid Based Cytology)

CYTOLOGY NO.

C 15256 / 2022

SPECIMEN

Liquid based pap smear

MICROSCOPIC FINDINGS

Moderately cellular smear showing scattered superficial squamous cells, intermediate squamous cells and admixed with inflammatory cells in the background.

INTERPRETATION :


Adequacy of the Smear - Satisfactory for evaluation.
Cellular components of transformation zone are - Absent.
Reactive cellular changes - Absent.
Infective organisms - Absent.
Squamous cell abnormalities - Nil.
Other cells (Endometrial & mesenchymal) - Nil.

IMPRESSION

Inflammatory smear. Negative for intraepithelial lesion or malignancy (Mode of reporting : Bethesda system 2014)

-- End of Report --

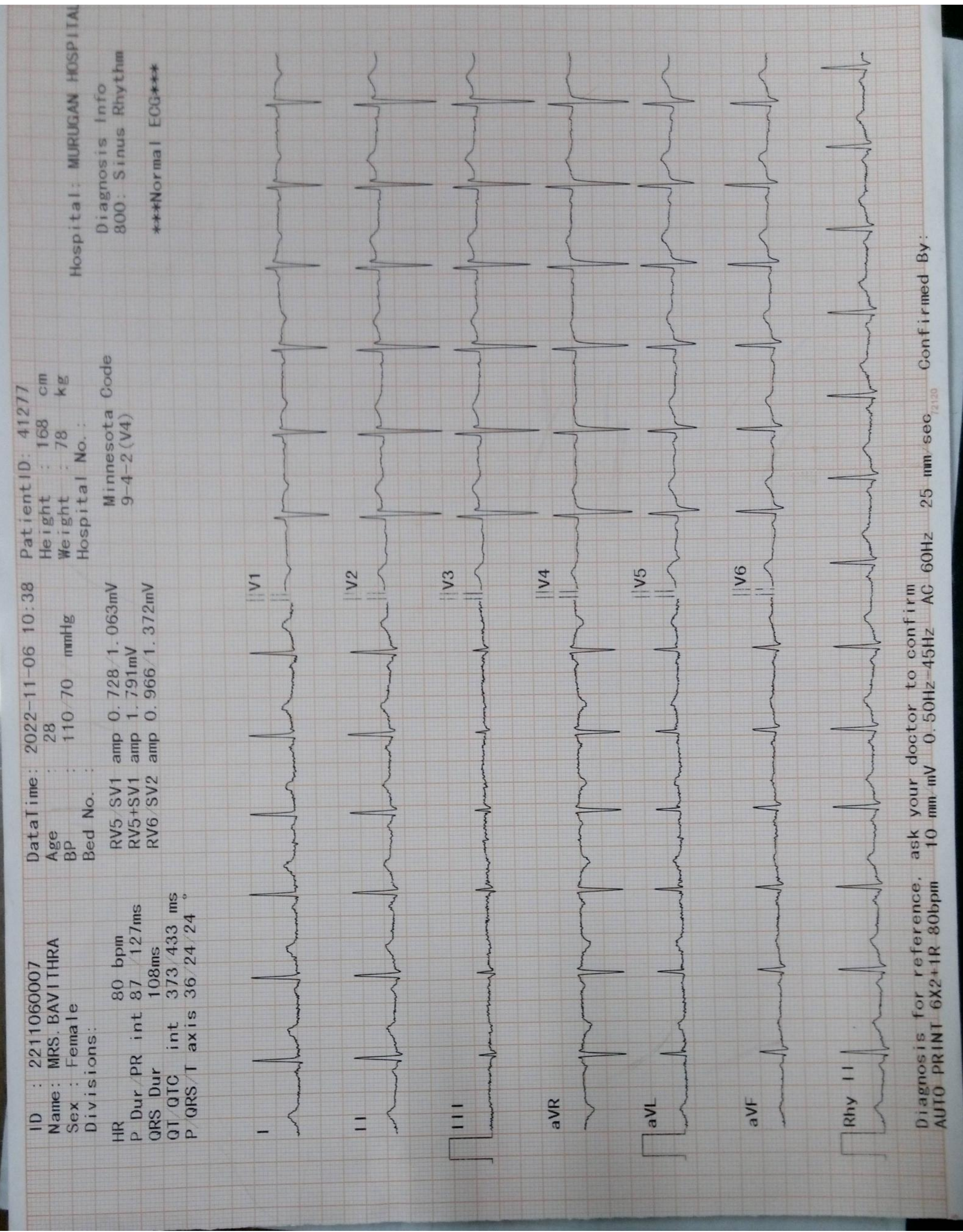
Prof. Geetha Devadas DCP, MD path
Prof. Chandramouleeswari MD path
Dr. Indumathi DCP, MD path, DNB path
Dr. Arun Prabhakaran MD
Dr. Varsha DCP., DNB (Pathology)
Dr. Anshulekha patel, M.D.,PDF (Oncopathology)


Dr. Kavvya R
M.D Pathology

Page 1 / 1

Healing Hearts and Lives

264/125, Kilpauk Garden Road, Kilpauk, Chennai - 600 010.
Phone : +91 44 4644 8989 / 75500 53335 | Email : muruganhosp@gmail.com
Website : www.muruganhospitals.in





SCAN REPORT

NAME : MRS.BAVITHRA
AGE / SEX : 28YR/FEMALE
CONSULTANT: DR. ARUN PRAKASH

UHID NO : MH20220041277
IP / OP NO: OUT PATIENT
DATE : 11.11.2022

ULTRA SOUND SCAN OF ABDOMEN

LIVER: Normal in size and measures 14.6 cm **increased** in echotexture. No focal lesions are seen. No dilatation of intra-hepatic biliary radicals present. Hepatic veins and IVC appear normal. Portal vein is normal in caliber. Common bile duct is normal in caliber.

GALL BLADDER: Contracted.

PANCREAS: Normal in size and echotexture. No focal lesions are seen. No evidence of calculi or calcifications. No evidence of pancreatic duct dilation.

PARA AORTIC AREAS: Aorta and IVC appear normal. No evidence of para aortic lymphadenopathy.

SPLEEN: Normal in size and measures- 9.6 cm. Normal in echotexture. No evidence of focal lesions.

RIGHT KIDNEY: Measures 6.9 x 4.9 cm and is normal in size and echotexture. Cortico medullary differentiation is well maintained. There is no calculus or hydronephrosis or mass.

LEFT KIDNEY: Measures 10.2 x 5.2 cm and is normal in size and echotexture. Cortico medullary differentiation is well maintained. There is no calculus or hydronephrosis or mass.

Healing Hearts and Lives

264/125, Kilpauk Garden Road, Kilpauk, Chennai - 600 010. Phone : +91 44 4644 8989 / 75500 53335
Email : muruganhosp@gmail.com | Website : www.muruganhospitals.in



MURUGAN HOSPITALS
HEALING HANDS



LAB REPORT

Patient Name : Mrs. BAVITHRA.R
Age / Gender : 28-Years / Female
UHID ID : MH20220041277
Doctor Name : Dr. ARUN PRAKASH

OP Report No. : INVA2107629
Bill No. : INV2205113
Sample Date : 06/11/2022 - 09:30 AM
Report Date : 07/11/2022 - 12:12 AM


| Test Name | Result | Units | Reference Interval |
|----------------------|--------|--------|--------------------|
| ENDOCRINOLOGY | | | |
| T3 | 1.377 | ng/ml | 0.52-1.85 |
| T4 | 7.172 | ug/dl | 5.0 -13.0 ug/dl |
| TSH | 1.679 | uIU/ml | 0.39 - 6.16 uiu/ml |

KAVIYARASAN
Verified by

*** End of Report ***



Authorized Signature



Healing Hearts and Lives

264/125, Kilpauk Garden Road, Kilpauk, Chennai - 600 010.
Phone : +91 44 4644 8989 / 75500 53335 | Email : muruganhosp@gmail.com
Website : www.muruganhospitals.in

URINARY BLADDER: Empty

UTERUS : Normal in size and measures- 7.3 x 3.6 cm echotexture

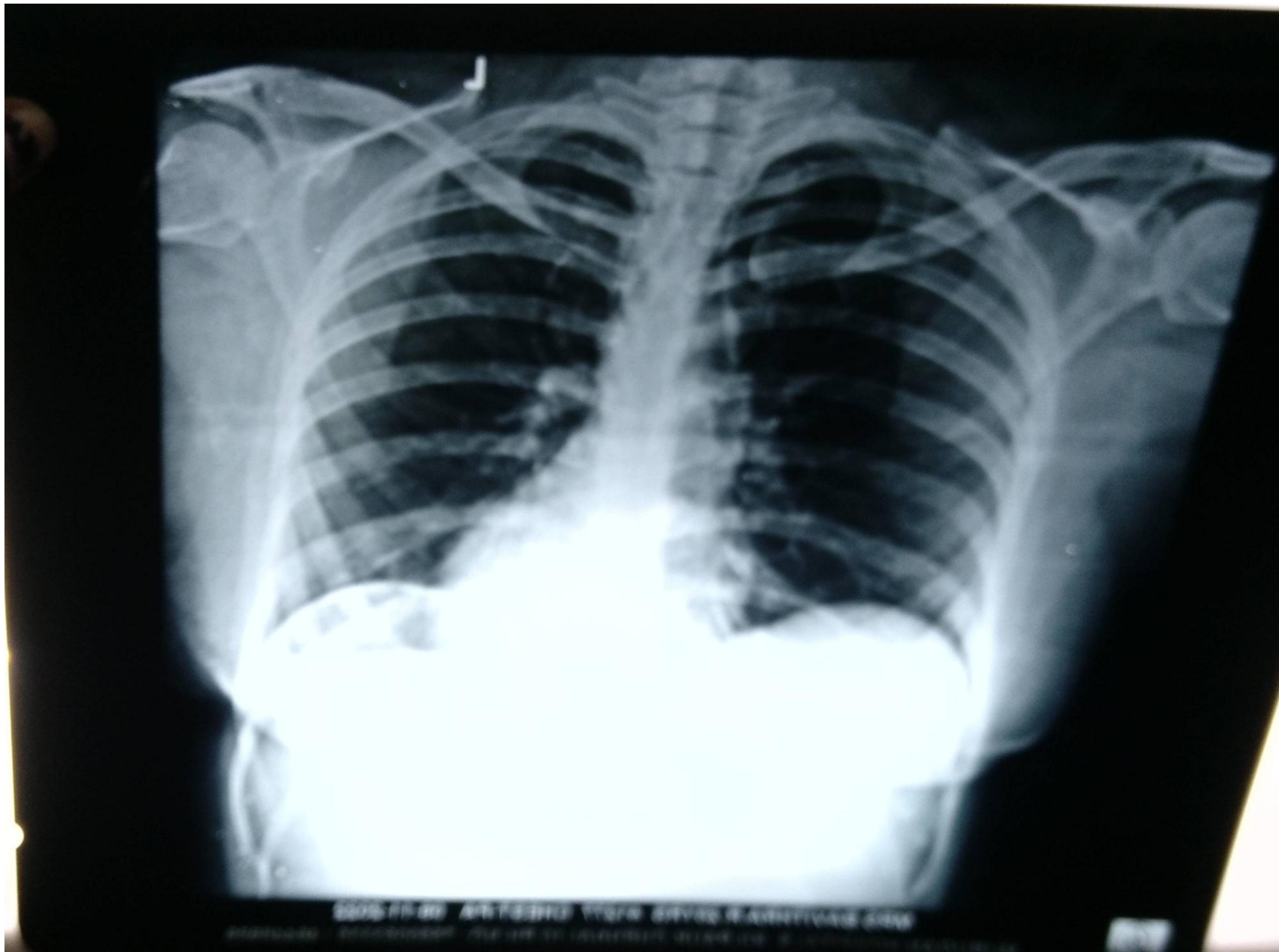
RIGHT OVARY : Measures 3.2 x 2.3 cm

LEFT OVARY : could not be assessed.

IMPRESSION:

- ❖ *Fatty liver grade I*
- ❖ *No other significant abnormality*


Dr. SAKTHI.M.D.R.D.
Consultant Radiologist.



Scanned by TapScanner



