

भारत सरकार
GOVERNMENT OF INDIA

भारतीय पहचान प्राधिकरण
National Identification Authority of India

व्यक्तिगत पहचान कार्ड
Personal Identification Card

व्यक्तिगत पहचान कार्ड
Personal Identification Card

नाम: रवि कौर
Date of Birth: 02/03/1987
पैसा: TEVALE

8528 0110 9416
VIO: 9140 4130 4756 7945
भारत सरकार भारत सरकार

R Kaur

7006590387



*Ms. Munir Ahmad Gillani
12/12/2017
Ludhiana, Punjab, India*

भारत सरकार
GOVERNMENT OF INDIA

भारतीय पहचान प्राधिकरण
National Identification Authority of India

व्यक्तिगत पहचान कार्ड
Personal Identification Card

व्यक्तिगत पहचान कार्ड
Personal Identification Card

नाम: रवि कौर
Date of Birth: 02/03/1987
पैसा: TEVALE

8528 0110 9416
VIO: 9140 4130 4756 7945



GILLANI'S DIAGNOSTIC CENTRE



MUNICIPALITY ROAD, OPP. POLICE HEADQUARTERS, KARAN NAGAR, SRINAGAR-190010, KMR.

B/O.: PEERWARI COMPLEX, OPP. SHIRAZ CINEMA, KHANYAR, SRINAGAR CELL: 9906476734

ID :- AHCN-32730112301000

Gender :- Female

Client Name:- Rubi Kour.

Cell :- 7006590387

Provider :- Apollo

Dated: 09/Dec/2023

URINE COTININE

ANALYTE	RESULT
* Urine cotinine	"Negative"/below 200ml

URINE ANALYSIS

Physical Examination

Colour	:-	Yellowish.
PH/Reaction	:-	Acidic.
Transparency	:-	Clear.
Sp. Gravity	:-	ONS.

Chemical Examination

Sugar	:-	NIL
Albumin	:-	NIL

MICROSCOPY :-

Fus Cells.	(Nil)
RBC Cells.	(Nil)
Sq. Epithelial.	(2+)
Calcium Oxalates.	(1+)
Amorphous Phosphates.	(1+)
Mucus.	(1+)
Others.	(Nil)



IMPORTANT

- AS PER UNIVERSAL ACCEPTANCE, ALL ORIGINALS MAY NOT BE APPARENT DURING SCANNING.
- NOT FOR PRENATAL SEX DETERMINATION OF FETUS UNDER PMDT AT MEDICAL LEGAL PURPOSE.
- THE INVESTIGATION FINDING SHOULD ALWAYS BE CONSIDERED IN CORRELATION WITH THE CLINICAL AND OTHER INVESTIGATION FINDING WHERE APPLICABLE.

mail: gdc.0786@yahoo.com

(Tawakul-tu-Allah Fahuwa Hasbi)

Cell: 9419011263, 9622870021

Phone: 0194-2478012



GILLANI'S DIAGNOSTIC CENTRE



MUNICIPALITY ROAD, OPP. POLICE HEADQUARTERS, KARAN NAGAR, SRINAGAR-190010, KMR.

B/O.: PEERWARI COMPLEX, OPP. SHIRAZ CINEMA, KHANYAR, SRINAGAR CELL: 9906476734

ID :- AHCN-32730112301000

Gender :- Female

Client Name:- Rubi Kour.

Cell :- 7006590387

Provider :- Apollo

Dated: 09/Dec/2023

TO WHOME IT MAY CONCERN

This is to certify that Rubi Kour is physically/Mentally fit to join the Organization.

Her: Vision/colour is good.

Her: Dental Shape & Condition is good.

Her: BMI=30, BP recumbent=120/80mm/Hg.

Her: D.O.B is 10/03/1953.

Her: Height is 155cms & weight is 85kgs

Her: Chest expiration is 103cms & chest inspiration is 105cms

Her: Abdomen is 102cms.



Dr. M. J. Khan
19/12/2023

Physical/ Medical Examiner

IMPORTANT

- AS PER UNIVERSAL ACCEPTANCE, ALL ANOMALIES MAY NOT BE APPARENT DURING SCANNING.
- NOT FOR PRENATAL SEX DETERMINATION OF FOETUS UNDER PNPT AT/MEDIAL LEGAL PURPOSE.
- THE INVESTIGATION FINDING SHOULD ALWAYS BE CONSIDERED IN CORRELATION WITH THE CLINICAL AND OTHER INVESTIGATION FINDING WHERE APPLICABLE.



GILLANI'S DIAGNOSTIC CENTRE



MUNICIPALITY ROAD, OPP. POLICE HEADQUARTERS, KARAN NAGAR, SRINAGAR-190010, KMR.

B/O.: PEERWARI COMPLEX, OPP. SHIRAZ CINEMA, KHANYAR, SRINAGAR CELL: 9906476734

ID :- AHCN-32730112301000

Client Name:- Rubi Kour.

Provider :- Apollo

Gender :- Female

Cell :- 7006590387

Dated: 09/Dec/2023

BIO-CHEMISTRY/IMMUNO-REPORT

Test Required	Result	Units	Normal Value
Blood Sugar (Fasting)	(95)	mg/dl	(70-110)
Blood Sugar (p.p)	(131)	mg/dl	(80-140)
K. F. T.			
Blood Urea	(42)	mg/dl	(10-46)
BUN	(17)	mg/dl	(06-20)
Serum Creatinine	(1.00)	mg/dl	(0.6-1.2)
Serum Uric Acid	(6.8)	mg/dl	(3.0-7.0)
Serum Calcium.	(10.0)	mg/dl	(8.4-10.5)
Serum Phosphorus.	(3.9)	mg/dl	(2.5-4.8)
Serum Sodium.	(149)	mmol/L	(135-155)
Serum Potassium.	(5.0)	mmol/L	(3.5-5.5)
Serum Chloride.	(102.3)	mmol/L	(98.0-107.0)
L. F. T.			
Serum Bilirubin	(1.0)	mg/dl	(UP TO 1.2)
Direct Bilirubin	(0.5)	mg/dl	(0-5)
Indirect Bilirubin	(0.5)	mg/dl	(0-7)
Serum Total Protein	(7.5)	G/dl	(6.0-8.0)
Serum Albumin	(4.9)	G/dl	(3.7-5.3)
Serum Globulin	(3.2)	G/dl	(2.3-3.6)
Serum Alk. Phosphate	(122)	U/l	(56-130)
A/G RATIO	(1.51)	***	(1.0-2.0)
SG (OT)	(37)	Units/L	(5-40)
SG (PT)	(34)	Units/L	(5-35)
Gamma GTT	(39)	Units/L	(> 40)
Lipid Profile:-			
TRIGLYCERIDES	(166)	mg/dl	(40-165)
CHOLESTEROL	(200)	mg/dl	(50-200)
H.D.L - CHOLESTEROL	(49)	mg/dl	(40-60)
L.D.L - CHOLESTEROL	(187)	mg/dl	(50-190)
V.L.D.L - CHOLESTEROL	(35)	mg/dl	(10-40)
Ratio	(1.83)	mg/dl	

End of Report

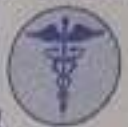IMPORTANT

- AS PER UNIVERSAL ACCEPTANCE, ALL ANOMALIES MAY NOT BE APPARENT DURING SCANNING.
- NOT FOR PRENATAL SEX DETERMINATION OF FOETUS UNDER PHOT AT MEDICAL LEGAL PURPOSE.
- THE INVESTIGATION FINDING SHOULD ALWAYS BE CONSIDERED IN CORRELATION WITH THE CLINICAL AND OTHER INVESTIGATION FINDING WHERE APPLICABLE.





GILLANI'S DIAGNOSTIC CENTRE



MUNICIPALITY ROAD, OPP. POLICE HEADQUARTERS, KARAN NAGAR, SRINAGAR-190010, KMR.

B/O.: PEERWARI COMPLEX, OPP. SHIRAZ CINEMA, KHANYAR, SRINAGAR CELL: 9906476734

ID :- AHCN-32730112301000

Gender :- Female

Client Name:- Rubi Kour.

Cell :- 7006590387

Provider :- Apollo

Dated: 09/Dec/2023

Haemotology Report

Test Required	Results	Units	Ref. Range
Haemoglobin Value (HB)	15.8	gm/dl	13.00-17.00
PCV/Haematocrit	44	%	40-50
M C V	89.5	fL	80-100
M C H	29.4	pg	27-32
M C H C	34.9	%	32-36
R D W - C V	13.2	%	11.5-14.5
Platelet Count	300	thousand	150-450
RBC Count	5.02	million/Cmm	4.50-5.50
Total Leucocyte Count	10.24	*10 ³ Cell/ul	4.0-11.0
<u>D L C (by Flow cytometry / Microscopy)</u>			
Neutrophil	72.8	%	40-75
Lymphocyte	27.2	%	20-40
Eosinophil	0.0	%	1-5
Monocyte	0.0	%	2-10
Basophil	0.0	%	0-2
RDW - SD	40.6	fL	35-46
PDW	19.3	fL	8.30-25.0
MPV	12.1	fL	8.60-15.5
PCT	0.49	%	0.15-0.62
Absolute Neutrophil Count	6.2	*10 ³ /UL	2-7
Absolute Lymphocyte Count	2.1	*10 ³ /UL	1-3
Absolute Monocyte Count	0.9	*10 ³ /UL	0.2-1.0
Absolute Basophil Count	0.08	*10 ³ /UL	0.02-0.1
Absolute Eosinophil Count	0.4	*10 ³ /UL	0.2-0.5
E.S.R.	07	mm	(M 0-9)
(Wintrob Method)			(F 0-20)
Blood Group	"A"		
Rh. Typing	(Positive)		

End Of Report

IMPORTANT

- AS PER UNIVERSAL ACCEPTANCE, ALL ANOMALIES MAY NOT BE APPARENT DURING SCANNING.
- NOT FOR PRENATAL SEX DETERMINATION OF FOETUS UNDER PNBT AT MEDICAL LEGAL PURPOSE.
- THE INVESTIGATION FINDING SHOULD ALWAYS BE CONSIDERED IN CORRELATION WITH THE CLINICAL AND OTHER INVESTIGATION FINDING WHERE APPLICABLE.





GILLANI'S DIAGNOSTIC CENTRE



MUNICIPALITY ROAD, OPP. POLICE HEADQUARTERS, KARAN NAGAR, SRINAGAR-190010, KMR.

B/O.: PEERWARI COMPLEX, OPP. SHIRAZ CINEMA, KHANYAR, SRINAGAR CELL: 9906476734

ID :- AHCN-32730112301000

Gender :- Female

Client Name:- Rubi Kour.

Cell :- 7006590387

Provider :- Apollo

Dated: 09/Dec/2023

IMMUNO-REPORT

Test Required	Result	Units	Normal Value
TOTAL TRIIODOTHYRONINE (T3)	(1.54)	ng/dl.	0.87 - 1.78
TOTAL THYROXINE (T4)	(09.44)	ng/dl.	3.06 - 12.54
THYROID STIMULATING HORMONE (TSH)	(5.00)	uIU/ML	0.34 - 5.60
Glycosylated Hemoglobin (Ghb/HbA1c)	(5.6)	%	<6: Non Diabetic

End Of Report



IMPORTANT

- AS PER UNIVERSAL ACCEPTANCE, ALL ANOMALIES MAY NOT BE APPARENT DURING SCANNING.
- NOT FOR PRENATAL SEX DETERMINATION OF FOETUS UNDER PNDT AT MEDICAL LEGAL PURPOSE.
- THE INVESTIGATION FINDING SHOULD ALWAYS BE CONSIDERED IN CORRELATION WITH THE CLINICAL AND OTHER INVESTIGATION FINDING WHERE APPLICABLE.



GILLANI'S DIAGNOSTIC CENTRE



MUNICIPALITY ROAD, OPP. POLICE HEADQUARTERS, KARAN NAGAR, SRINAGAR-190010, KMR.

B/O.: PEERWARI COMPLEX, OPP. SHIRAZ CINEMA, KHANYAR, SRINAGAR CELL: 9906476734

ID :- AHCN-32730112301000

Client Name:- Rubi Kour.

Provider :- Apollo

Gender :- Female

Cell :- 7006590387

Dated: 09/Dec/2023

X-RAY CHEST P.A VIEW

No evidence of any active lung Parenchymal lesion detected.

Apices and C.P. Angles are clear.

Cardiac size is with in normal range.



Rubi Kour
Radiologist

IMPORTANT

- AS PER UNIVERSAL ACCEPTANCE, ALL ANOMALIES MAY NOT BE APPARENT DURING SCANNING.
- NOT FOR PRENATAL SEX DETERMINATION OF FOETUS UNDER PNPT AT MEDIAL LEGAL PURPOSE.
- THE INVESTIGATION FINDING SHOULD ALWAYS BE CONSIDERED IN CORRELATION WITH THE CLINICAL AND OTHER INVESTIGATION FINDING WHERE APPLICABLE.

GILLANI'S DIAGNOSTIC CENTRE



MUNICIPALITY ROAD, OPP. POLICE HEADQUARTERS, KARAN NAGAR, SRINAGAR-190010, XMR.

B/O.: PEERWARI COMPLEX, OPP. SHIRAZ CINEMA, KHANYAR, SRINAGAR CELL: 9906476734

ID :- AHCN-32730112301000
Client Name:- Rubi Kour.
Provider :- Apollo

Gender :- Female
Cell :- 7006590387
Dated: 09/Dec/2023

Ophthalmology Report

Eye (Ophthalmology) examination		Normal	Abnormal			
Lids, lacrimal apparatus, conjunctiva, cornea, pupils, lens, media, fund, tension		✓				
Visual fields (by confrontation method test)		✓				
Ocular motility (associated parallel movement, nystagmus)		✓				
Cover test, if applicable/necessary		✓				
Visual acuity tests						
Does the candidate possess glasses	Yes / No, if "YES" then - wears glasses (spectacles) / contact lenses / both					
Distance vision at 6 metres	Right Eye	Left Eye	Both Eyes			
Without glasses/contact lenses	6 / 6	6 / 6	6 / 6			
With glasses (spectacles)	6 /	6 /	6 /			
With contact lenses	6 /	6 /	6 /			
Near vision - 'N' type at 30-60 cm	Right Eye	Left Eye	Both Eyes			
Without glasses/contact lenses	N 6/6	N 6/6	N 6/6			
With glasses (spectacles)	N	N	N			
With contact lenses	N	N	N			
Prescription of corrective glasses and/or contact lenses, if applicable (as prescribed by ophthalmologist)						
Vision	Right Eye			Left Eye		Vision corrected to (visual acuity)
	S	C	A	S	C	
Distance						6 /
Near						N
Colour vision / perception - use Ishihara plates only, held at 75 cm distance for reading/hearing (preferably use 38 plate edition)						
No. of plates used	Ishihara's - 34 plates / 38 plates					
Result:	Normal / Abnormal (defective)					
	No. of errors =					
	Unread plate no.'s =					
	Misread plate no.'s =					
If Abnormal Colour Vision						
(mention those plates misread and numeral read by candidate respectively, e.g. misread plate no. 2 and read its numeral as 3 but still at no. 2, then write "plate no. 2" and "3")						

End Of Report

IMPORTANT

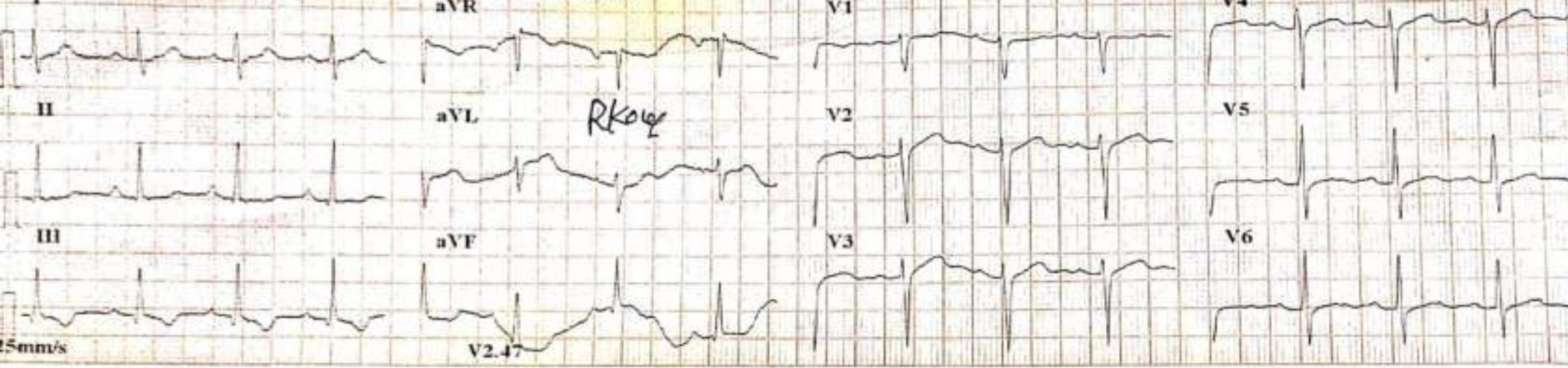
- AS PER UNIVERSAL ACCEPTANCE, ALL ANOMALIES MAY NOT BE APPARENT DURING SCANNING.
- NOT FOR PRENATAL SEX DETERMINATION OF FOETUS UNDER PNMT AT/MEDIAL LEGAL PURPOSE.
- THE INVESTIGATION FINDING SHOULD ALWAYS BE CONSIDERED IN CORRELATION WITH THE CLINICAL AND OTHER INVESTIGATION FINDING WHERE APPLICABLE.



10mm/mV 0.5-45Hz AC50

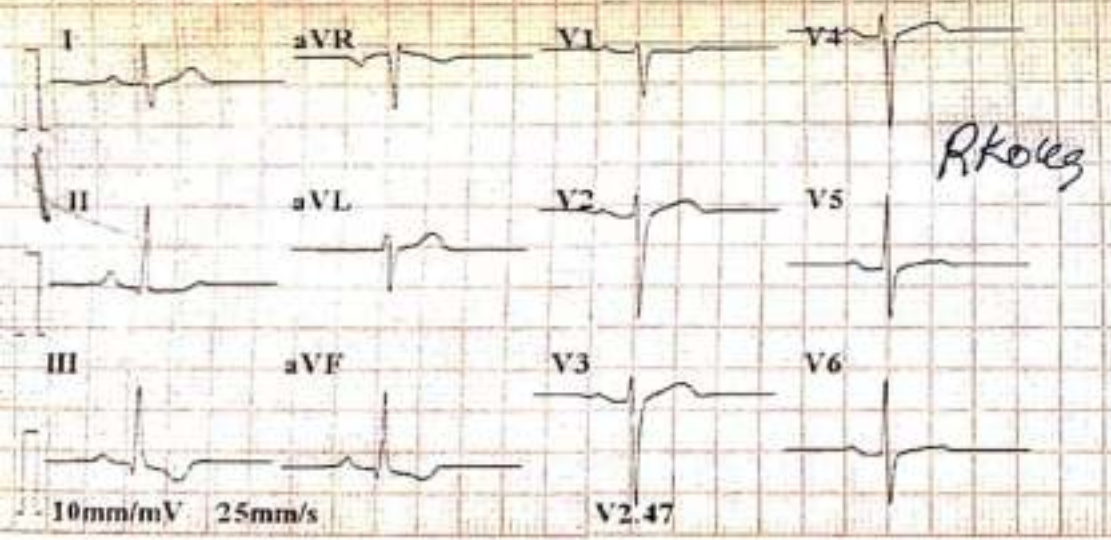
08-12-2023 12:30:17

RUBI KOUR.




Average Template:

08-12-2023 12:30:17

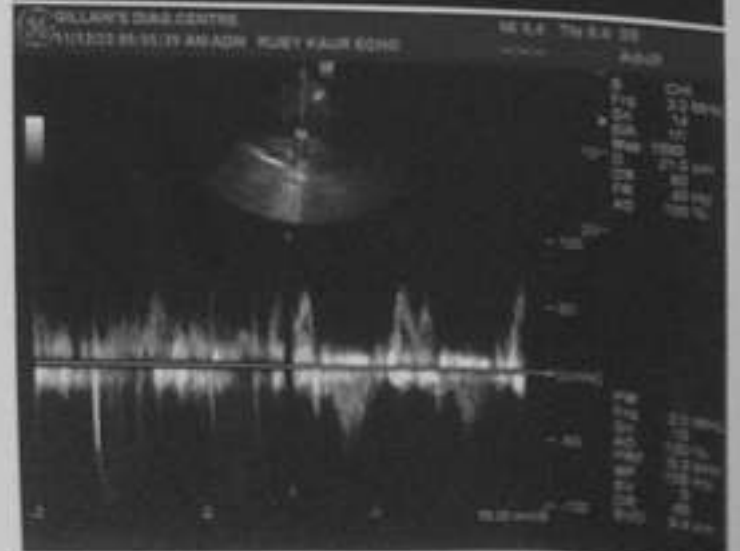
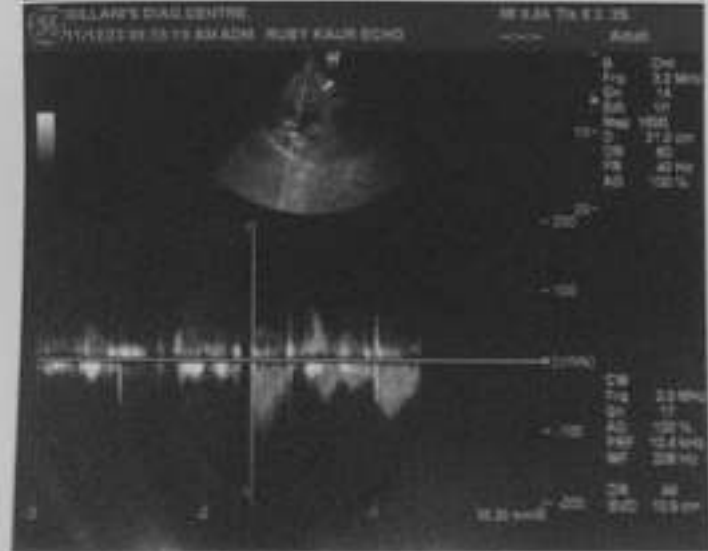
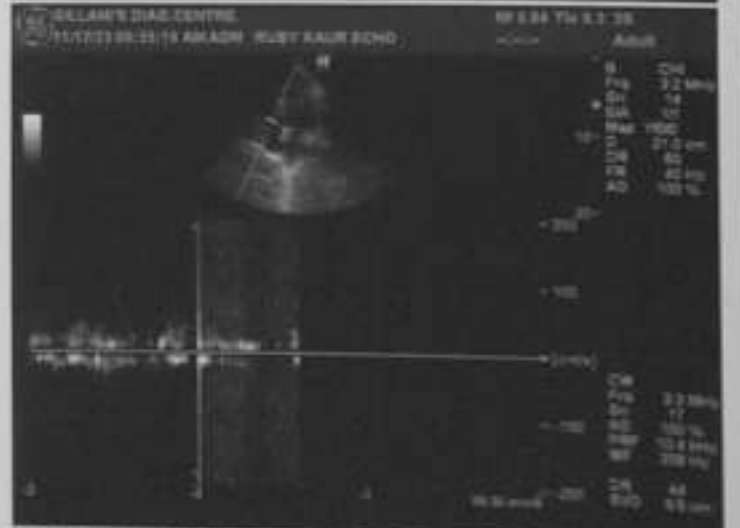
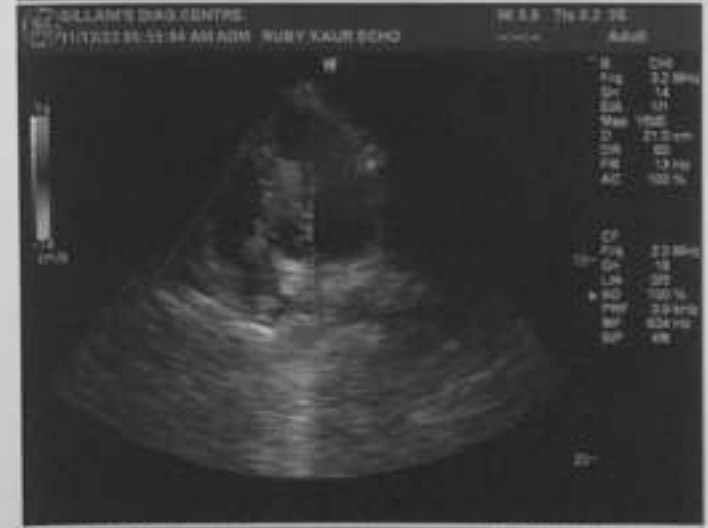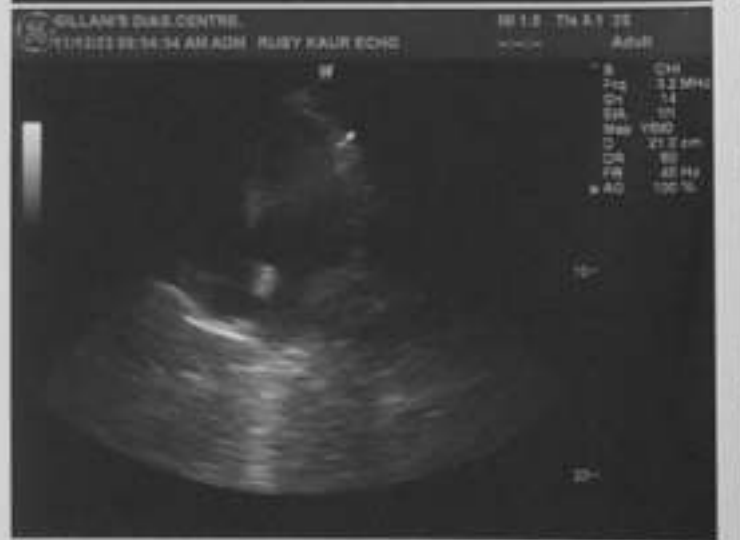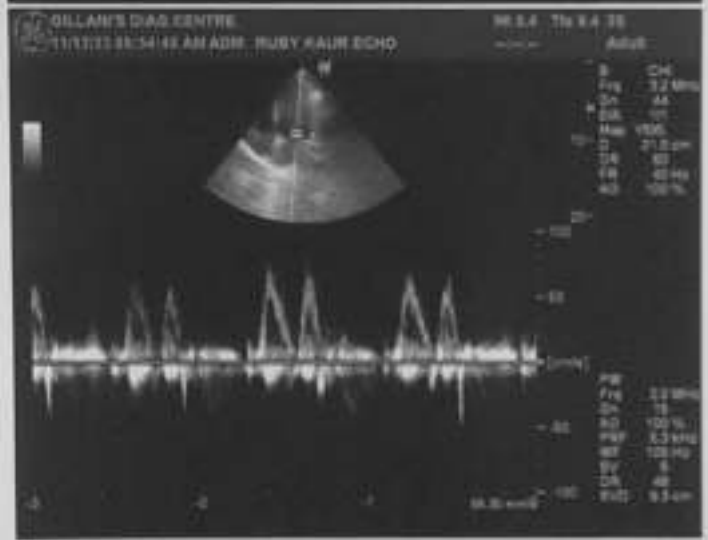
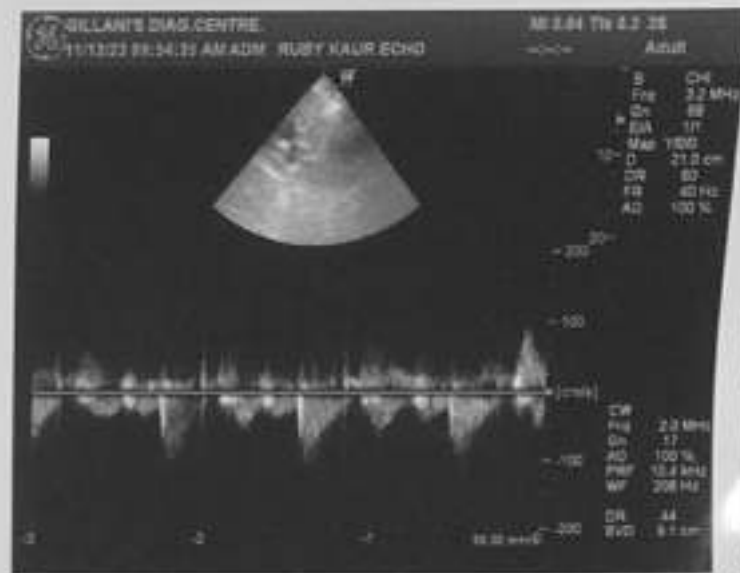


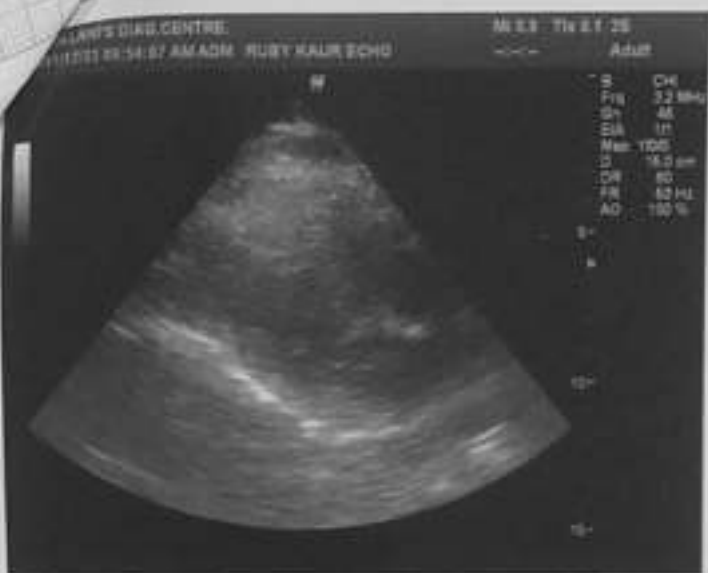ID : 231208-1230
 Name : RUBI KOUR.
 Age : 28 yr
 Sex :
 BP : mmHg
 Height : cm
 Weight : kg
 HR : 89 bpm
 P Dur : 103 ms
 PR int : 208 ms
 QRS Dur : 111 ms
 QT/QTc int : 356/434 ms
 P/QRS/T axis : 61/83/-18 °
 RV5/SV1 amp : 0.919/0.546 mV
 RV5+SV1 amp : 1.465 mV
 RV6/SV2 amp : 0.906/1.215 mV



Diagnosis Information:
 800: Sinus Rhythm
 621: Inverted T Wave(aVF)

Dr. [Signature]
 Report Confirmed by:





GILLANI'S DIAGNOSTIC CENTRE



MUNICIPALITY ROAD, OPP. POLICE HEADQUARTERS, KARAN NAGAR, SRINAGAR-190010, KMR.

B/O.: PEERWARI COMPLEX, OPP. SHIRAZ CINEMA, KHANYAR, SRINAGAR CELL: 9906476734

ID :- AHCN-32730112301000

Gender :- Female

Client Name:- Rubi Kour.

Cell :- 7006590387

Provider :- Apollo

Dated: 11/Dec/2023

MEASUREMENTS:-

AO Root:- 24 mm

LA :- 25 mm

AORTIC VALVE:- NORMAL

AR Grade :- _____

AV gradient:- _____ mmHg

Av Area :- _____ Cm²

LVOT Diam :- _____ Cm² VTI:- _____ cm/sec

SV :- _____ ml CO:- _____ L/min

LVEDD:- 42 mm IVSd:- 15mm

LVESD:- 28 mm PW:- 16mm

MITRAL VALVE:-

2D-Evaluation:- NORMAL

MR grade:- _____

Gradient:- _____ mmHg

PHT:- _____ Cm² VTI:- _____ CM² HR

2D _____ Cm² CE:- _____ Cm² PHT:- _____ Cm²

E.....cm/sA.....cm/s

DT.....ms.....IVRT.....ms

EF :- 68 %

TRICUPID VALVE:-

2D Evaluation :- NORMAL

TR grade:- _____

Gradient:- 08 mmHg

PHT:- _____ VTI

PULMONARY VALVE:-

2D Evaluation :- NORMAL

PR grade:- _____ pr ed Vel. -MS

Max. syst. Vel. :- MS

Page :- 1

P.T.O

IMPORTANT

- ★ AS PER UNIVERSAL ACCEPTANCE, ALL ANOMALIES MAY NOT BE APPAENT DURING SCANNING.
- ★ NOT FOR PRENATAL SEX DETERMINATION OF FOETUS UNDER PNDD AT/MEDIAL LEGAL PURPOSE.
- ★ THE INVESTIGATION FINDING SHOULD ALWAYS BE CONSIDERED IN CORRELATION WITH THE CLINICAL AND OTHER INVESTIGATION FINDING WHERE APPLICABLE.





GILLANI'S DIAGNOSTIC CENTRE



MUNICIPALITY ROAD, OPP. POLICE HEADQUARTERS, KARAN NAGAR, SRINAGAR-190010, KMR.

B/O.: PEERWARI COMPLEX, OPP. SHIRAZ CINEMA, KHANYAR, SRINAGAR CELL: 9906476734

ID :- AHCN-32730112301000

Gender :- Female

Client Name:- Rubi Kour.

Cell :- 7006590387

Provider :- Apollo

Dated: 11/Dec/2023

Impression

LV :- NO RWMA.

MV :- Normal

AV :- Normal

PV :- Normal

TV :- Normal.

RA,RV :- Normal

CONCLUSION :-

NORMAL CARDIAC CHAMBERS

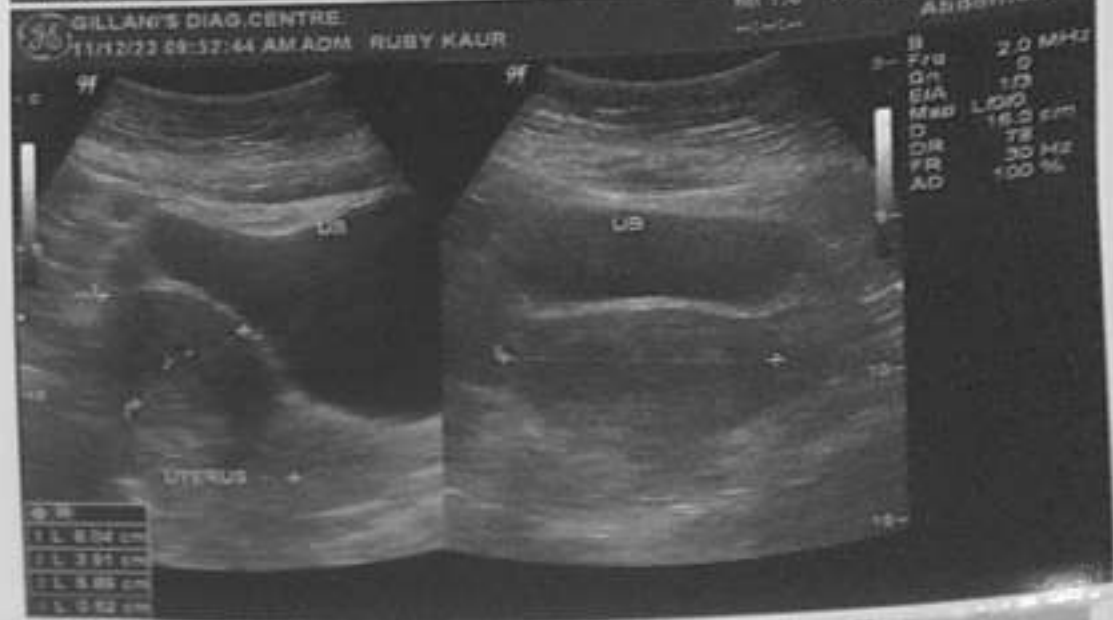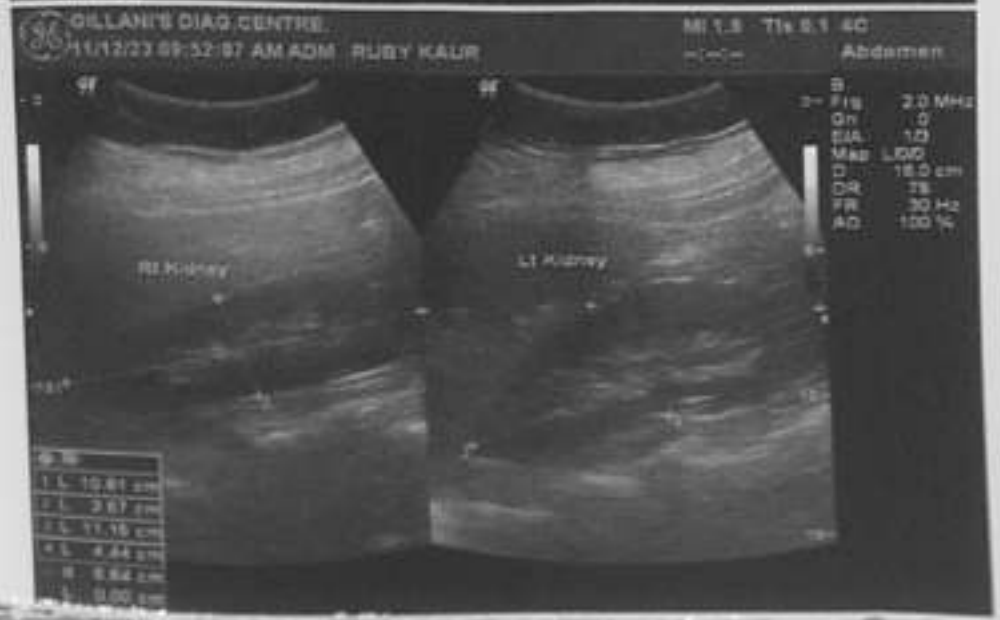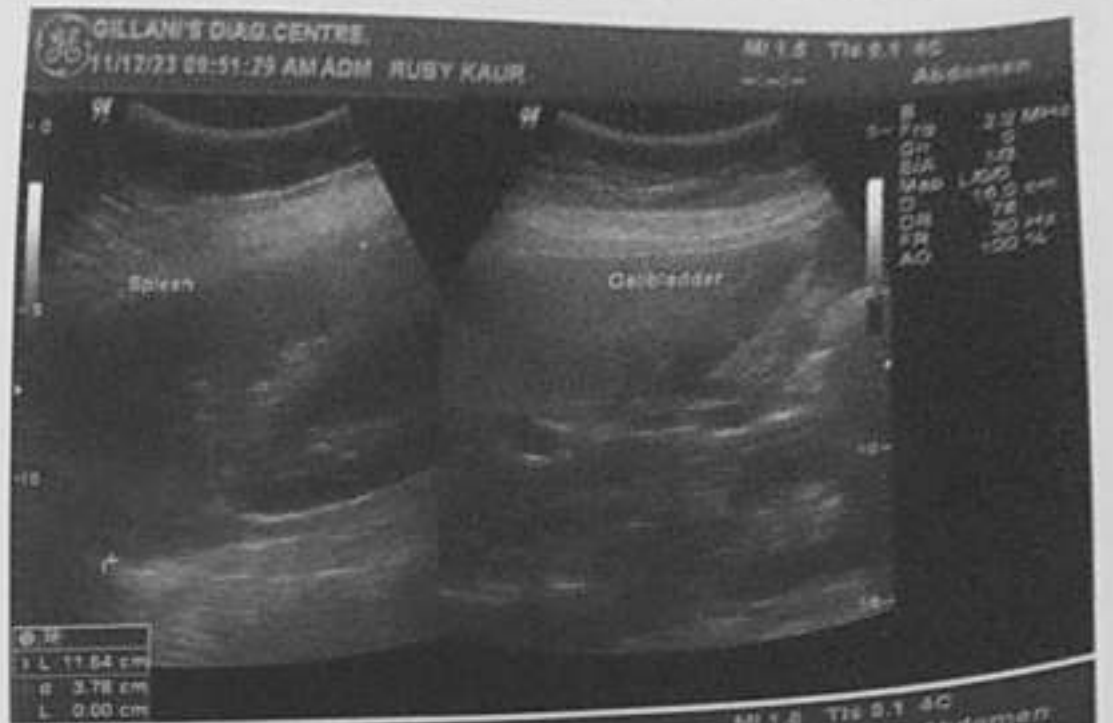
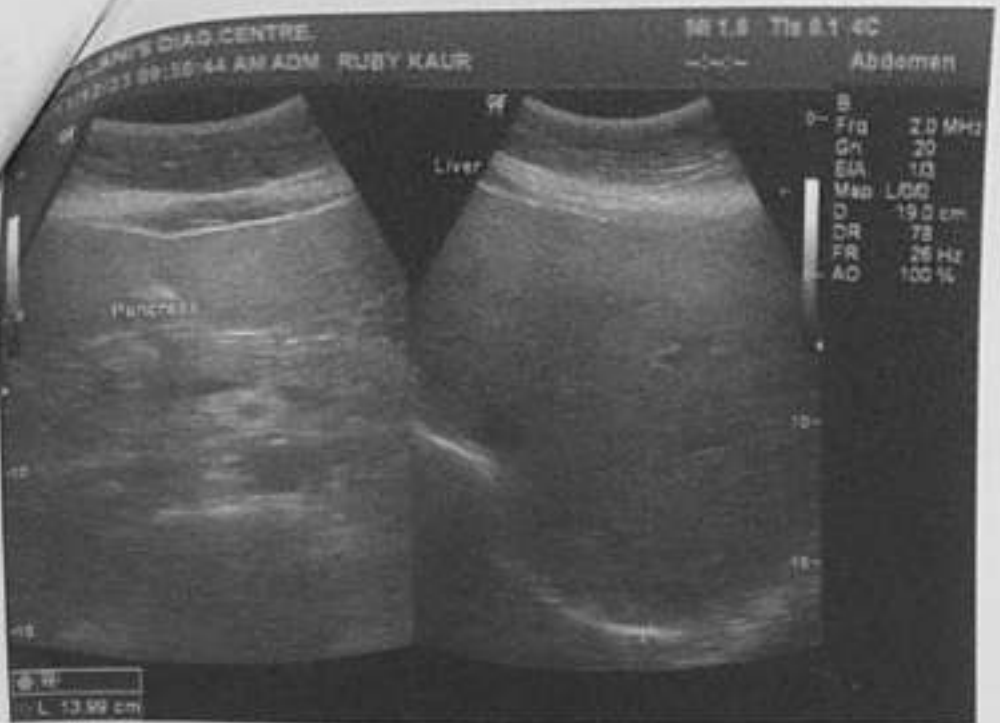
NORMAL LV SYSTOLIC / DYSYSTOLIC FUNCTION



Cardiologist

IMPORTANT

- * AS PER UNIVERSAL ACCEPTANCE, ALL ANOMALIES MAY NOT BE APPAENT DURING SCANNING.
- * NOT FOR PRENATAL SEX DETERMINATION OF FOETUS UNDER PNDT AT/MEDIAL LEGAL PURPOSE.
- * THE INVESTIGATION FINDING SHOULD ALWAYS BE CONSIDERED IN CORRELATION WITH THE CLINICAL AND OTHER INVESTIGATION FINDING WHERE APPLICABLE.





GILLANI'S DIAGNOSTIC CENTRE



MUNICIPALITY ROAD, OPP. POLICE HEADQUARTERS, KARAN NAGAR, SRINAGAR-190010, KMR.

B/O.: PEERWARI COMPLEX, OPP. SHIRAZ CINEMA, KHANYAR, SRINAGAR CELL: 9906476734

ID :- AHCN-32730112301000
Client Name:- Rubi Kour.

Gender :- Female
Cell :- 7006590387

Provider :- Apollo

Dated: 11/Dec/2023

U.S.G Abdomen & Pelvis

- Liver :-** Normal in size outline and shows bright echopattern.
Liver span is 140 mm
IHBR not dilated. PV is normal.
- Gall Bladder:-** Well distended. Wall thickness normal.
No calculus / Worm / pericholecystic collection.
- C.B.D :-** Common bile duct is not dilated .
No worm / calculus seen.
- Pancreas:-** Normal in size, outline and echopattern.
No focal / diffuse pathology. Pancreatic duct not dilated.
- Spleen:-** Normal size & echopattern, measuring 115 mm
No focal / diffuse pathology.
Normal spleno-portal axis.
- Retro peritoneum:-** No nodes / mass .
- Kidneys:-** Normal size, outline & echopattern. CMD maintained.
No calculus / hydronephrosis.
Rt.Kidney measures 108x 36 mm Lt.Kidney measures 111 x 44 mm
- Urinary Bladder:-** Normal in capacity & outline. Wall thickness normal.
No calculus / diverticulum.
- Uterus:-** Normal in size & outline. Measuring 80 x 39 x 58mm
No evidence of any fibroid.
Myometrium homogenous. EC is free.
Endometrial thickness is 5 mm
- Cervical :-** Normal in size, outline and echotexture
- Adnexa:-** Both ovaries are normal in size and echopattern ,
No mass or cyst seen .
No fluid in POD.

IMPRESSION :-

FATTY LIVER GRADE - I
Normal Kidneys
Normal Pelvic Organs



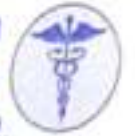Dr. Khalid Ahmad
Radiologist

IMPORTANT

- * AS PER UNIVERSAL ACCEPTANCE, ALL ANOMALIES MAY NOT BE APPARENT DURING SCANNING.
- * NOT FOR PRENATAL SEX DETERMINATION OF FOETUS UNDER PHDT FOR MEDICAL LEGAL PURPOSE.
- * THE INVESTIGATION FINDING SHOULD ALWAYS BE CONSIDERED IN CORRELATION WITH THE CLINICAL AND OTHER INVESTIGATION FINDING WHERE APPLICABLE.



GILLANI'S DIAGNOSTIC CENTRE




MUNICIPALITY ROAD, OPP. POLICE HEADQUARTERS, KARAN NAGAR, SRINAGAR-190010, KMR.

B/O.: PEERWARI COMPLEX, OPP. SHIRAZ CINEMA, KHANYAR, SRINAGAR CELL- 9906476734

ID :- AHCN-32730112301000
Client Name:- Rubi Kour.
Provider :- Apollo

Gender :- Female
Cell :- 7006590387
Dated: 09/Dec/2023

AUDIOMETERY REPORT



Add + 8.5+3.5+6.5+5.5+1.5 to convert HL to db SPL (in 200 couple)

TEST	Right Ear (dB)	Left Ear (dB)
OTOSCOPY	OK	OK
WEBER	ΔC	-
RINNE	>	>
SWING	<	>
HEARING AID	1	1
HEARING AID	15	15
UCL	4	15

OTOSCOPY



R
Weber
Rinne
ABC Diagnosis

[Signature]
Audiologist

IMPORTANT

- AS PER UNIVERSAL HEARING LOSS DEFINITIONS, HEARING LOSS MAY NOT BE APPARENT DURING SCANNING.
- NOT FOR PARENTAL OR OTHER INTERESTED PARTY'S STATUS UNDER PHOT AT MEDICAL LEGAL PURPOSE.
- THE INVESTIGATION FINDING SHOULD ALWAYS BE CONSIDERED IN CORRELATION WITH THE CLINICAL AND OTHER INVESTIGATION FINDING WHERE APPLICABLE.



09/12/2023 13:07

Email: gdc.0786@yahoo.com

(Tasbeel - in - Allah Jahaana Parak)

Cell: 9419011263, 9622870021
Phone: 0194-2478012



GILLANI'S DIAGNOSTIC CENTRE



MUNICIPALITY ROAD, OPP. POLICE HEADQUARTERS, KARAN NAGAR, SRINAGAR-190010, KMR.

B/O.: PEERWARI COMPLEX, OPP. SHIRAZ CINEMA, KHANYAR, SRINAGAR CELL: 9906476734

ID :- AHCN-32730112301000

Gender :- Female

Client Name:- Rubi Kour.

Cell :- 7006590387

Provider :- Apollo

Dated: 11/Dec/2023

H a e m o t o l o g y R e p o r t

Test Required

Results

Units

Ref. Range

Peripheral Smear.

Shows mild hypochromic RBC's with mild degree of anisocytosis.

End of Report



IMPORTANT

- ★ AS PER UNIVERSAL ACCEPTANCE, ALL ANOMALIES MAY NOT BE APPAENT DURING SCANNING.
- ★ NOT FOR PRENATAL SEX DETERMINATION OF FORTUS UNDER PNPT AT/MEDIAL LEGAL PURPOSE.
- ★ THE INVESTIGATION FINDING SHOULD ALWAYS BE CONSIDERED IN CORRELATION WITH THE CLINICAL AND OTHER INVESTIGATION FINDING WHERE APPLICABLE.