

Apollo Clinic

Consent Form

Patient Name: Smriti Jainedi Age: 36

UHID Number: Company Name:

I Mr/Mrs/Miss: Employee of

(Company) want to inform you that I am not getting the..... X-RAY & Urine

Test which is a part of health check package. Routine

Reason If any:

And I claim the above statement in my full consciousness.

Patient Signature: [Signature] Date: 11/11/23

Name : Mrs. Smriti Trivedi

Age: 36 Y

UHID:CKOR.0000171836

Sex: F

Address : bangalore

OP Number:CKOROPV387388

Plan : ARCOFEMI MEDIWHEEL FEMALE AHC CREDIT PAN
 INDIA OP AGREEMENT

Bill No :CKOR-OCR-78694

Date : 11.11.2023 09:55

Sno	Service Type/ServiceName	Department
1	ARCOFEMI - MEDIWHEEL - FULL BODY HEALTH ANNUAL PLUS CHECK - FEMALE - 2D ECHO - PAN INDIA - FY2324	
1	URINE GLUCOSE(FASTING)	
2	GAMMA GLUTAMYL TRANSFERASE (GGT)	
3	HbA1c, GLYCATED HEMOGLOBIN	
4	2D ECHO	
5	LIVER FUNCTION TEST (LFT)	
X 6	X-RAY CHEST PA	
7	GLUCOSE, FASTING	
8	HEMOGRAM + PERIPHERAL SMEAR	
9	ENT CONSULTATION	
10	FITNESS BY GENERAL PHYSICIAN	
11	GYNAECOLOGY CONSULTATION	
12	DIET CONSULTATION	
13	COMPLETE URINE EXAMINATION	
14	URINE GLUCOSE(POST PRANDIAL)	
15	PERIPHERAL SMEAR	
16	ECG	
17	BLOOD GROUP ABO AND RH FACTOR	
18	LIPID PROFILE	
19	BODY MASS INDEX (BMI)	
20	LBC PAP TEST- PAPSURE	
21	OPHTHAL BY GENERAL PHYSICIAN	
22	RENAL PROFILE/RENAL FUNCTION TEST (RFT/KFT)	
23	ULTRASOUND - WHOLE ABDOMEN	
24	THYROID PROFILE (TOTAL T3, TOTAL T4, TSH)	
25	DENTAL CONSULTATION	
26	GLUCOSE, POST PRANDIAL (PP), 2 HOURS (POST MEAL)	

 WT - 61.7 kg
 HT - 156 cm

Apollo Clinic

Consent Form

Patient Name: Smriti Jainedi Age: 36

UHID Number: Company Name:

I Mr/Mrs/Miss: Employee of

(Company) want to inform you that I am not getting the X-RAY

Test which is a part of health check package.

Reason If any:

And I claim the above statement in my full consciousness.

Patient Signature: [Signature] Date: 11/11/23

OPHTHAL REPORT

NAME: Smiti Tolvedi

AGE: 36

GENDER: MALE/FEMALE ✓

RIGHT EYE

	SPH	CYL	AXIS
DV	—	-0.50	90°
NV	N6		

LEFT EYE

	SPH	CYL	AXIS
DV	—	-0.50	90°
NV	N6		

REMARK: ^{sfg} blue black lens

DATE: 11/11/23

chand
OPTOMETRIST

BRING THIS PRESCRIPTION IN YOUR NEXT VISIT

Patient Name : Mrs Smriti Trivedi

Patient ID : 171836

Age : 36Year(s)

Sex : Female

Referring Doctor : H/C

Date : 11.11 .23

ULTRASOUND ABDOMEN AND PELVIS

Liver is normal in size and shows normal echo pattern. No biliary dilatation .No focal lesion

Portal vein is normal in size, course and caliber. CBD is not dilated.

Gall bladder contracted

Pancreas to the extent visualized, appears normal in size, contour and echogenicity

Spleen is normal in size, shape, contour and echopattern. No evidence of mass or focal lesion.

Right kidney is normal in size, position, shape and echopattern. Corticomedullary differentiation is maintained. No evidence of calculi or hydronephrosis.

Left kidney is normal in size, position, shape and echopattern.corticomedullary differentiation is maintained. No evidence of calculi or hydronephrosis.

Urinary Bladder is well distended. wall thickness is normal. No internal echoes.

Uterus: is anteverted and normal in size. Endometrial echoes are normal

Endometrium: measures ~ 5.0mm.

Right ovary:Normal

Left ovary:Not visualized

Both adnexa: Normal, no mass seen.

There is no ascites.

IMPRESSION:

- **NO SIGNIFICANT ABNORMALITY DETECTED**

DR VINOD JOSEPH DNB,DMRD
RADIOLOGIST

Date : 11/11/23
MRNO :
Name : *smriti*
Age/Gender: 36yo

MC
Department : OBSTETRICS & GYNAECOLOGY
Consultant : DR JYOTHI RAJESH
KMC NO-42823
Qualification : DGO (DNB)
Consultation Timings: 9.30pm to 12.00pm
PHONE NO: 9972044580

Height :	Weight :	BMI :	Waist Circum :
Temp :	Pulse :	Resp :	B.P :

General Examination / Allergies
History

Clinical Diagnosis & Management Plan

No gynae complaints
MM. BMC - regular cycle 18/10
OBH. PLS FTND 10-2yo
Post-Hypothyroid on 100mcg
Family H - Father - DM
Mother - HTN
OK. PLS soft
PLS - G needs on touch
LOC EDON
PLV. OK bulby

Follow up date:

exposed

Doctor Signature

✓

NAME: Mrs. SMRITI TRIVEDI

AGE: 36Y

SEX: FEMALE

DATE: 11/11/2023

ECHOCARDIOGRAPHY REPORT

MEASUREMENT

AO -26 (20 – 35)mm	LIVD d – 35(36-52)mm	IVS - 10 (06 - 11)mm
LA -28 (19- 40)mm	LVID s - 25 (23- 39)mm	PWD – 10(06- 11)mm
EF - 60% (>50%)	RVID-22	

VALVES

Mitral Valve : Normal
Aortic Valve : Normal
Tricuspid Valve : Normal
Pulmonary Valve : Normal

CHAMBERS

Left Atrium : Normal
Right Atrium : Normal
Left Ventricle : Normal
Right Ventricle : Normal

SEPTAE

IVS : Intact
IAS : Intact

GREAT ARTERIES

Aorta : Normal

Pulmonary Artery : Normal

DOPPLER DATA

Mitral : E > A

Aortic : Normal

Tricuspid : Normal

Pulmonary : Normal

WALL MOTION ABNORMALITIES : No RWMA

Pericardium : Normal

FINAL DIAGNOSIS

**NORMAL CHAMBERS and VALVES
NORMAL BIVENTRICULAR FUNCTION
NO RWMA AT REST, LV EF -60%**



**DR. MOHAN MURALI
CONSULTANT
CARDIOLOGIST**

HEALTH CHECK - ENT

NAME: *Smriti Trivedi*

AGE: *36/F*

EAR:

EXTERNAL EAR

MIDDLE EAR

INNER EAR (FN)

RE:

(N)

(N)

(N)

LE:

(N)

(N)

(N)

HEARING ASSESSMENT:

RHINNE

Positive

Positive

WEBER

↔ Equal

ABC

Same as examiner on both sides.

NOSE

AIRWAY

(N)

ORAL CAVITY

(N)

SEPTUM

(N)

OROPHARYNX

(N)

TURBINATES

B/L ITH ⊕

PHARYNX

(N)

OTHERS

—

LARYNX

—

NECK

NECK NODES

Not palpable

OTHER

—

AUDIOMETRY

—

IMPRESSION

—

Ananchal
SIGNATURE & Ananchal

DR. MAHABAI.ESHWAR.M
MBBS.(MYS), MD(AIIMS DELHI)FICS
D.O (JIPMER)
REG.NO:KMC:9748

DATE: 11/4/23
OP NO:

THE APOLLO MEDICAL CENTER KORAMANGALA

NAME: *Ponni Trivedi*
AGE : *32*
GENDER: *F*

OPHTHALMIC REPORT

RIGHT EYE

LEFT EYE

GENERAL APPEARANCE

VISION - DISTANCE

WITHOUT GLASS

6/6P

6/6

WITH GLASS

GLASS POWER

NEAR

WITHOUT GLASS

no

no

WITH GLASS

GLASS POWER

COLOUR

normal

ANTERIOR SEGMENT:-

> normal

FUNDUS

I.O.P: DIGITAL

[Signature]
DOCTOR SIGNATURE

Patient Name	: Mrs. Smriti Trivedi	Age	: 36 Y F
UHID	: CKOR.0000171836	OP Visit No	: CKOROPV387388
Reported on	: 11-11-2023 14:05	Printed on	: 11-11-2023 16:24
Adm/Consult Doctor	:	Ref Doctor	: SELF

DEPARTMENT OF RADIOLOGY

X-RAY CHEST PA

Both lungs fields appear normal.

Both hila are normal.

Both costophrenic and cardiophrenic angles are normal.

The cardiac and mediastinal shadows appear normal.

Bones and soft tissues appear normal.

IMPRESSION : NORMAL STUDY.

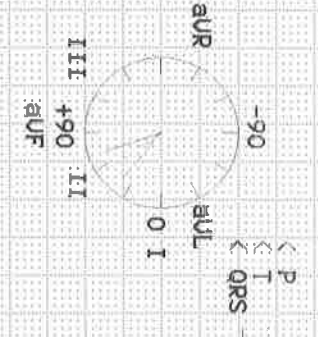


DR VINOD JOSEPH DNB,DMRD
RADIOLOGIST

Printed on: 11-11-2023 14:05

---End of the Report---

AGE: 36
 Measurement Results:
 QT/QTcB : 376 / 419 ms
 PR : 112 ms
 P : 80 ms
 RR/PP : 806 / 800 ms
 P/ORS/T : 55 / 70 / 40 degrees
 QTd/QTcBd : 50 / 56 ms
 Sokolow : 2.1 mV
 WK : 10

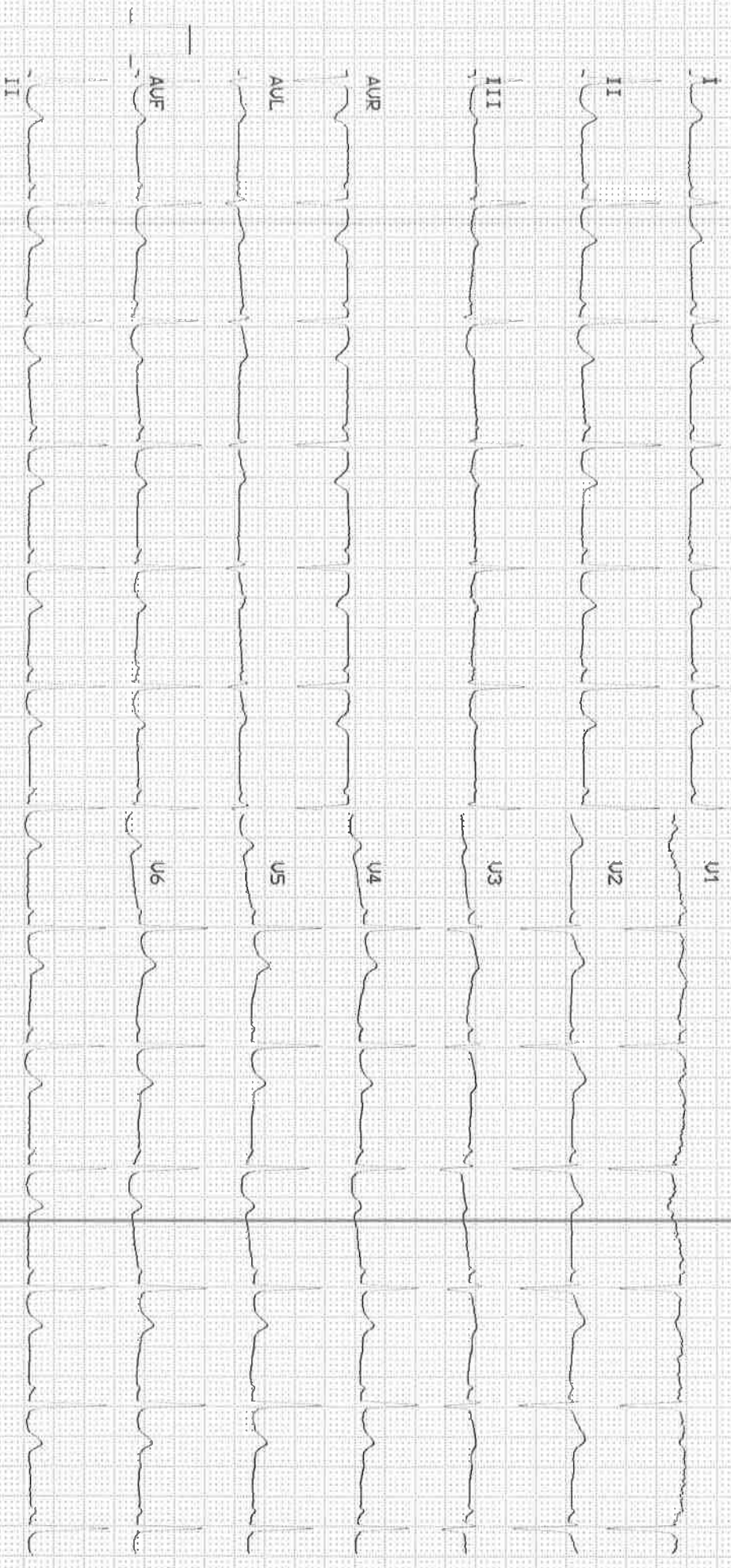


Interpretation:

Normal Sinus Rhythm

[Handwritten Signature]

Unconfirmed report.



11 Nov 2022 12:22:12 256x512 1000/400 256x512 1000/400 256x512 1000/400 256x512 1000/400

Patient Name	: Mrs. Smriti Trivedi	Age	: 36 Y/F
UHID	: CKOR.0000171836	OP Visit No	: CKOROPV387388
Reported By:	: Dr. TOBY ABRAHAM THOMAS	Conducted Date	: 12-11-2023 09:01
Referred By	: SELF		

ECG REPORT

Observation :-

1. Normal Sinus Rhythm.
2. Heart rate is 74 beats per minutes.
3. No pathological Q wave or S-T,T changes seen.
4. Normal P,Q,R,S,T waves and axis.
5. No evidence of chamber, hypertrophy or enlargement seen.

Impression:

NORMAL RESTING ECG.

Dr. TOBY ABRAHAM THOMAS
CONSULTANT

NOTE:KINDLY TAKE A PHOTOCOPY OF THE GRAPH
FOR FUTURE REFERENCE IF NEEDED.

----- END OF THE REPORT -----