

**DAKSH HOSPITAL**

396 - 397, Gandhi Nagar, Scheme No. 8, ALWAR -301001

Ref. No.

Date.....

MEDICAL EXAMINATION REPORT

Mediwheel (BOB)

Name: Mr. Manish Meena

Age: 30 yrs Sex: Male

Date: 06/03/2024

General Physical Examination


Height : 176 cm  
Pulse : 90 mt  
Respiration : 18/mt

Weight : 160 kg  
BP : 130/86 mm/hg  
BMI : 51.7 kg/m<sup>2</sup>

Systemic Exam:- NORMALDental Check up:- NORMALEye check-up:- NORMALSkin Check up:- NORMALENT Check up:- NORMAL

Impression:- O/GPT 45/51, RL/TG 190/220, TSH 5.69  
BME 51.7, Grade II Fatty Liver

Recommendation:- -Lifestyle Modification  
- Wt Reduction  
- Avoid Fatty (Carbohydrate Rich Food)

  
Dr. Mukesh Kumar Gupta  
MD Gen. Medicine  
Reg. No 5423/16262

डॉ० मुकुंश गुप्ता  
M.D.F.C.C.S.  
किजिशियन एवं फ्युजल रोग विशेषज्ञ  
दक्ष हॉस्पिटल, अलवर  
संवि० सं०-5423/16262

## Results

Run Date 06/04/2024 09:23:06 AM

Operator DAKSH

Last Name

Sample ID 2

First Name MR MANISH MEENA

Department

Gender Male Age

Physician DR. MUKESH GUPTA M.D

Patient ID AUTO\_PID20738

Type Man

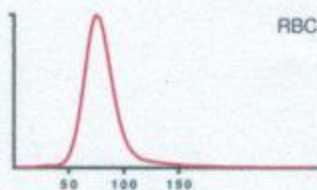
Date of birth

Sample comments

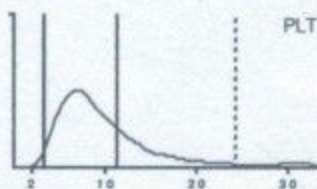
### Susp. Pathologies

Eosinophilia

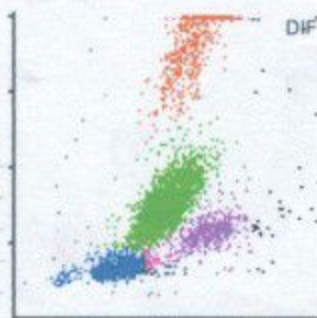
				Range
RBC	5.41	*	10 <sup>6</sup> /μL	3.80 - 5.50
HGB	13.6		g/dL	13.0 - 17.0
HCT	43.9	*	%	39.0 - 52.0
MCV	81.1	*	μm <sup>3</sup>	76.0 - 100.0
MCH	25.2	l	pg	26.0 - 34.0
MCHC	31.0	L	g/dL	32.0 - 35.0
RDW-CV	16.7	h	%	11.0 - 16.0
RDW-SD	52.1	h	μm <sup>3</sup>	37.0 - 49.0



				Range
PLT	386		10 <sup>3</sup> /μL	150 - 450
PCT	0.35		%	0.15 - 0.40
MPV	9.1		μm <sup>3</sup>	8.0 - 11.0
PDW	13.7		μm <sup>3</sup>	11.0 - 22.0
P-LCC	94		10 <sup>3</sup> /μL	44 - 140
P-LCR	24.4		%	18.0 - 50.0



				Range
WBC	10.76	h	10 <sup>3</sup> /μL	3.50 - 10.00
	#			
NEU	6.28		1.60 - 7.00	58.7
LYM	3.22	h	1.00 - 3.00	30.0
MON	0.23		0.20 - 0.80	2.2
EOS	0.89	H	0.00 - 0.50	8.3 h
BAS	0.09		0.00 - 0.15	0.8
LIC	0.05		0.00 - 0.10	0.5



*R.S. Gupta*  
**Dr. R.S. GUPTA**  
 MD (Pathology) (MAHE)  
 RMC No. 7924/19778

Date :-06/04/2024

Name :- MR MANISH MEENA

Age & Sex :- 30Yrs/ male

Refd. :- Dr Mukesh Gupta M.D.

	TEST NAME	RESULT	REFERENCE RANGE	
	ESR	10	00 -20 mm/hrs	
	Blood Group & Rh Factor	O <sup>+</sup> POSITIVE		
	HbA1C	4.9	4 - 5.6%	
	Blood Sugar (F)	86.5	< 70 - 100 mg/dl	
	Blood Sugar (PP)		< 140 mg/dl	
	Urine Sugar (F)	NIL	-	
	Urine Sugar (PP)	-	-	
<b>LIVER</b>	S.Bilirubin Total	0.80	0.30 - 1.20 mg/dl	
	S.Bilirubin Direct	0.20	0.10 - 0.30 mg/dl	
	S.Bilirubin Indirect	0.60	0.30 - 0.90 mg/dl	
	S.G.O.T.	45	> 37 u/l	
	S.G.P.T.	51	> 40 u/l	
	S.Alk. Phosp.	181	80 - 306 u/l	
	G.G.T.	28	5 -40 u/l	
	Total Protein	6.8	6.5 - 8.5 gm/dl	
	Albumin	3.7	3.8 - 5.4 gm/dl	
	Globulin	3.1	2.3 - 3.5 gm/dl	
	A/G Ratio	1.1	-	
AST/ALT Ratio	0.8	-		
<b>KIDNEY</b>	Blood Urea	27.2	15 -45 mg/dl	
	S.Creatinine	0.93	0.60 - 1.30 mg/dl	
	BUN	16.0	6 -24 mg/dl	
	S.Uric Acid	4.9	M 3.1 - 7.0, F 2.5 - 5.6 mg/dl	
	BUN/Creatinine Ratio	17	-	
<b>LIPID PROFILE</b>	Total Cholesterol	190.1	Up to 200 mg/dl	
	S.HDL	45.1	30 - 70 mg/dl	
	S.LDL	101	Up to 170 mg/dl	
	S.VLDL	44.1	5.0 - 40 mg/dl	
	S. Triglycerides	220.1	Up to 170 mg/dl	
	LDL/HDL Ratio	2.2	-	
	Total Cholesterol/ HDL Ratio	4.2	-	
<b>THYROID</b>	T3	75	40 - 181 ng/dl	
	T4	6.5	4.6 - 10.5 µg/dl	
	TSH	5.69	0.30 - 5.0 mIU/l	
<b>URINE EXAMINATION</b>			<b>Microscopic Examination :</b>	
<b>General/Chemical Examination:</b>	Colour	Pale Yellow	RBC	Absent
	Reaction	Acidic	WBC	1 - 2
	Specific Gravity	QNS	Epithelial Cells	0 - 1
	Appearance	S TURBID	Cast	Absent
	Albumin	Nil	Crystal	Absent
	Sugar	Nil	Spermatozoa	Absent
			Amorphous Sediments	Absent
			Other	Absent
<b>X-RAY CHEST</b>	NORMAL STUDY			
<b>STOOL EXAMINATION</b>			<b>Microscopic Examination :</b>	
<b>General/ Chemical Examination:</b>	Colour	-	RBC	-
	Consistency	-	WBC	-
	PH	-	Ova & Parasites	-
	Reducing Substances	-		

Dr. R.S. GUPTA  
MD (Pathology) (MAHE)  
R.M.No. 7924/19778

TECHNOLOGIST

All investigation have their own limitations regarding the sensitivity & specificity of individual assay procedures, Isolated laboratory investigations never confirm the final diagnosis of the disease. They only help in arriving at a diagnosis in conjunction with clinical presentation and other related investigations. Report is not valid for medico-legal purpose subject to ALWAR jurisdiction only.



# दक्ष हॉस्पिटल

396, गाँधी नगर स्कीम नं.8, अलवर (राज०) ☎ 0144-2703340

## Sonography / 2D Echo Cardiography / Doppler Report

### 2D/ ECHO REPORT

Name: MR. Manish Meena /M/30 YRS  
BOB HEALTH CHECH UP

Date: 6-Apr-24

PROCEDURES: M-MODE/2D/DOPPLER/COLOR/CONTRASTB.A.S. M<sup>2</sup>

Thick chest wall with poor echo window

- All cardiac chambers are normal.
- IAS & IVS appears normal
- No regional wall motion abnormality.
- LVEF 72 %
- All valves appears normal
- IVC appears normal with normal respiratory variation.
- No clot, vegetation and effusion.

Adv: - Follow up/ review at higher center for confirmation

Note:- Please Correlate clinically. Due to technical limitations as well as inaccuracies inherent in the laboratory and statistical analysis of biological process. Diagnostic accuracy of ECHO is up to 95% only.  
Report is not valid for medico-legal purpose.

  
Dr. Mukesh Kumar Gupta  
DR. MUKESH GUPTA  
Physician & Sonologist  
PHYSICIAN  
RM 5423/16262



भ्रूण लिंग परीक्षण की शिकायत  
104 टोल फ्री सेवा पर भी की

जा सकती है। भ्रूण लिंग परीक्षण की शिकायत 104 टोल फ्री सेवा पर भी की जा सकती है।



# दक्ष हॉस्पिटल

396, गाँधी नगर स्कीम नं.8, अलवर (राज०) ☎ 0144-2703340

## Sonography / 2D Echo Cardiography / Doppler Report

Name: MR. Manish Meena /M/30 YRS

Date: 6-Apr-24

BOB HEALTH CHECK UP

### U.S.G. OF ABDOMEN & PELVIS

#### LIVER

Liver **17.2 cm with moderate increase echogenicity**. Intra hepatic biliary radicals are not dilated.  
No evidence of focal or diffuse lesion.

#### GALL BLADDER

Gall bladder is normal dilated. Lumen clear. Wall thickness normal. CBD normal

#### PANCREAS

Pancreas is normal in size, shape & echo-texture.

#### SPLEEN

Normal in size with normal shape & echo- texture.

#### BOTH KIDNEY

Both kidney normal shape, size & echo texture. CMD maintained

PROSTATE is normal shape, size & echo texture..

URINARY BLADDER is normal shape, size & echo texture..

Impression:- Grade II fatty liver.

Please correlate clinically. USG accuracy is 95 % due to technical limitations as well as inaccuracies inherent in the laboratory and statistical analysis biological process.

This report is not valid for medico-legal cases.

  
Dr. Manish Gupta  
SONOLOGIST  
Physician & Sonologist  
RM 5423/16262



"भ्रूण लिंग परीक्षण की शिकायत  
104 टोल फ्री सेवा पर भी की  
जा सकती है"

भ्रूण लिंग परीक्षण की शिकायत 104 टोल फ्री सेवा पर भी की जा सकती है।

11-01-2024 07:22:51 PM

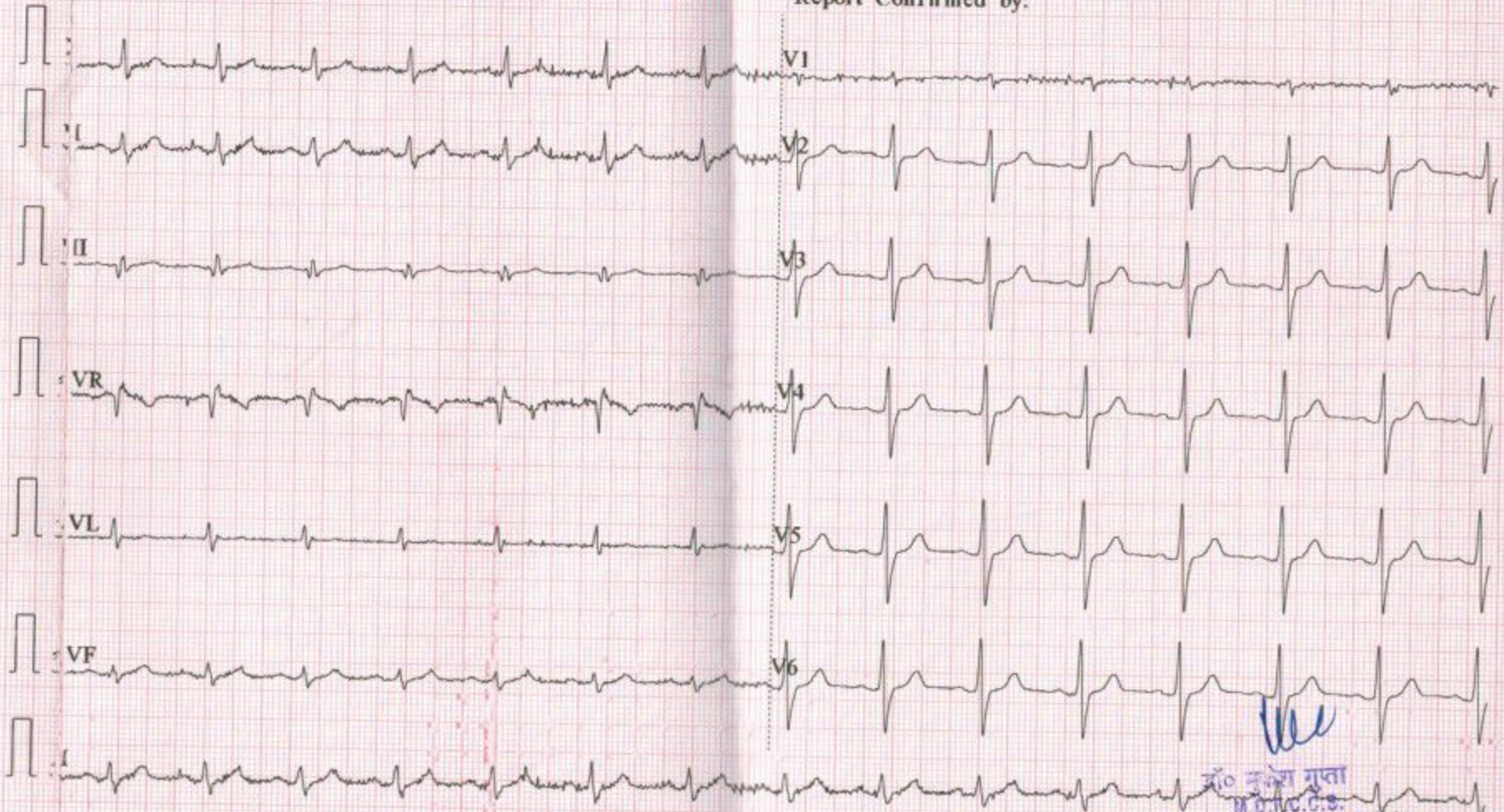
ID: Danish

Female      Years

HR	: 88	bpm
P	: 125	ms
PR	: 172	ms
QRS	: 115	ms
QT/QTc	: 342/415	ms
P/QRS/T	: 51/-4/51	°
RV5/SV1	: 0.927/0.141	mV

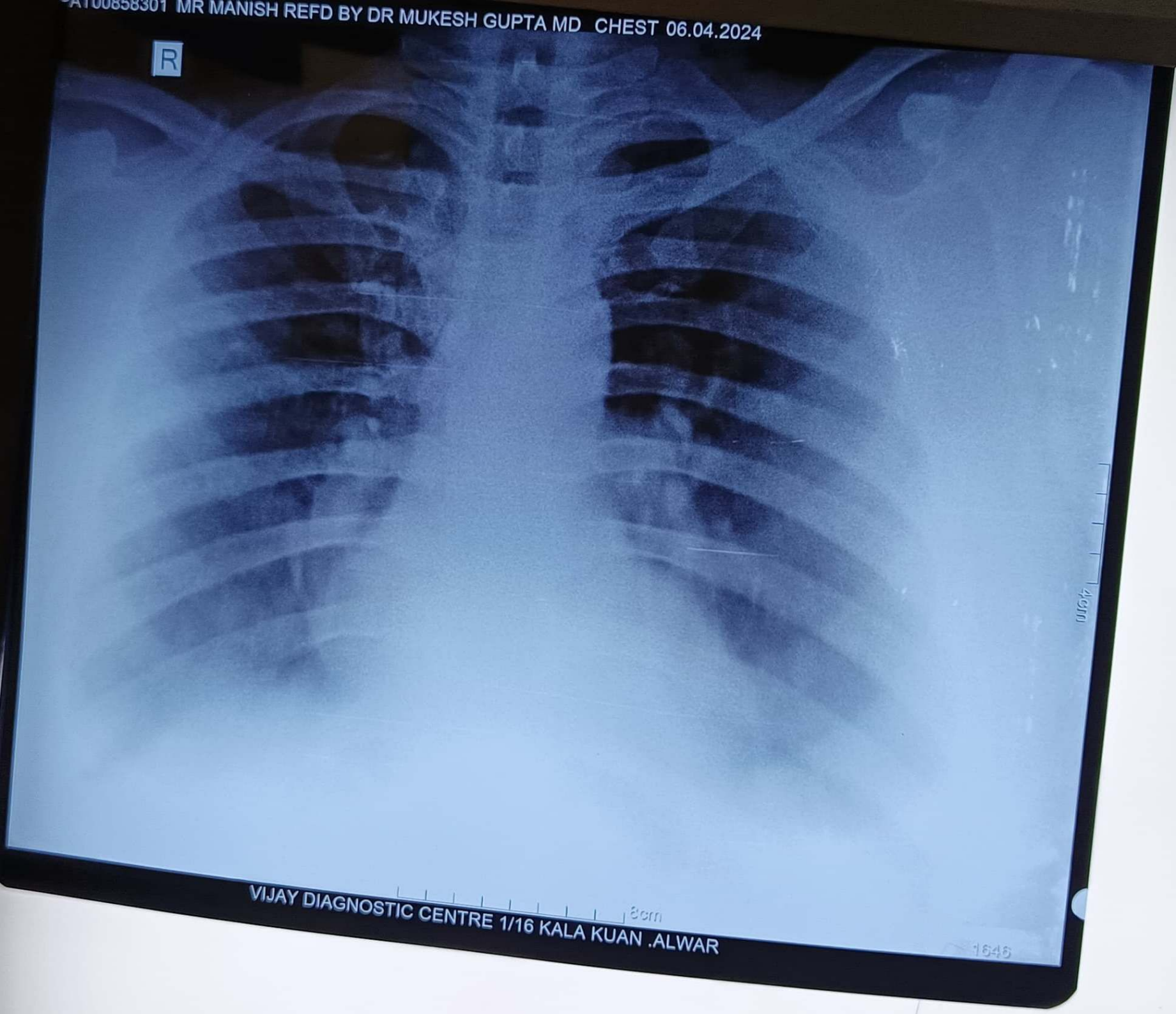
Diagnosis Information:  
 Sinus Rhythm  
 \*\*\*Normal ECG\*\*\*

Report Confirmed by:



डॉ० नरेश गुप्ता  
 M.D., D.C.C.S.  
 फिजिशियन एवं मधुमेह रोग विशेषज्ञ  
 दक्ष हॉस्पिटल, अलवर  
 रजि० नं०-5423/16262

R



4cm

VIJAY DIAGNOSTIC CENTRE 1/16 KALA KUAN .ALWAR

8cm

1646