

DAKSH HOSPITAL

396 - 397, Gandhi Nagar, Scheme No. 8, ALWAR -301001

Ref. No.

Date.....

MEDICAL EXAMINATION REPORT
Mediwheel (BOB)

Name: Mrs. Meena Kumari

Age: 31 yrs

Sex: Female

Date: 26/08/2023

General Physical ExaminationHeight : 147 cm
Pulse : 90 /mt
Respiration : 18 /mtWeight : 50 kg
BP : 110/70 mm/hg
BMI : 23.1 kg/m²Systemic Exam:-

NORMAL

Dental Check up :-

NORMAL

Eye check-up :-

NORMAL

Skin Check up:-

NORMAL

ENT Check up:-

NORMAL

Gynae Check up:-3/30 date on-P, F, L, N
AMP-7K 10-4yr -Impression:-

NORMAL

Recommendation:-

NO

Dr. Mukesh Kumar Gupta
MD Gen. Medicine
Reg. No 5423/16262डॉ० मुकेश गुप्ता
M.D.F.C.C.S.
फिजिशियन एवं मधुमेह रोग विशेषज्ञ
दक्ष हॉस्पिटल, अलवर
रजि० नं०-5423/16262

Results

Run Date 26/08/2023 09:54:04 AM

Operator DAKSH

Last Name

Sample ID 2

First Name MRS MEENA KUMARI

Department

Gender Female Age

Physician DR. MUKESH GUPTA M.D

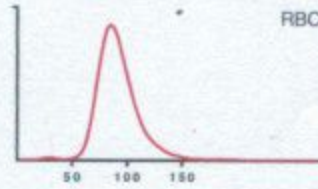
Patient ID AUTO_PID15542

Type Woman

Date of birth

Sample comments

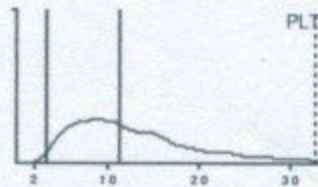
| | | | | Range |
|--------|------|----|---------------------|-------------|
| RBC | 3.80 | * | 10 ⁶ /μL | 3.80 - 5.50 |
| HGB | 11.6 | | g/dL | 11.5 - 15.2 |
| HCT | 37.5 | * | % | 35.0 - 46.0 |
| MCV | 98.6 | h* | μm ³ | 77.0 - 97.0 |
| MCH | 30.5 | | pg | 26.0 - 34.0 |
| MCHC | 30.9 | L | g/dL | 32.0 - 35.0 |
| RDW-CV | 17.5 | H | % | 11.0 - 17.0 |
| RDW-SD | 62.5 | H | μm ³ | 37.0 - 49.0 |



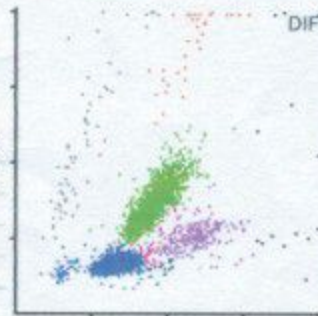
Susp. Pathologies

Anisocytosis
Macroplatelets

| | | | | Range |
|-------|------|---|---------------------|-------------|
| PLT | 233 | * | 10 ³ /μL | 150 - 450 |
| PCT | 0.29 | | % | 0.15 - 0.40 |
| MPV | 12.3 | H | μm ³ | 8.0 - 11.0 |
| PDW | 25.3 | H | μm ³ | 11.0 - 22.0 |
| P-LCC | 114 | | 10 ³ /μL | 44 - 140 |
| P-LCR | 48.9 | | % | 18.0 - 50.0 |



| | | | Range | | Range |
|-----|------|---|---------------------|--------------|---------------|
| WBC | 5.27 | | 10 ³ /μL | 3.50 - 10.00 | |
| | # | | Range | % | Range |
| NEU | 2.51 | | 1.60 - 7.00 | 48.0 | 40.0 - 75.0 |
| LYM | 2.48 | | 1.00 - 3.00 | 47.3 | h 20.0 - 45.0 |
| MON | 0.12 | l | 0.20 - 0.80 | 2.2 | 2.0 - 10.0 |
| EOS | 0.06 | | 0.00 - 0.50 | 1.1 | 1.0 - 6.0 |
| BAS | 0.07 | | 0.00 - 0.15 | 1.4 | h 0.0 - 1.0 |
| LIC | 0.03 | | 0.00 - 0.10 | 0.7 | 0.0 - 1.0 |



Dr. R.S. Gupta
Dr. R.S. GUPTA
 MD (Pathology) (MAHE)
 RMC No. 7924/19778

Dr. Mukesh Gupta

Date :- 26/08/2023

Name :- MRS. MEENA KUMARI JATAV

Age & Sex :- 31 Yrs/ Female

Refd. :- Dr Mukesh Gupta M.D.

| | TEST NAME | RESULT | REFERENCE RANGE |
|---------------|------------------------------|-------------------------|--------------------------------|
| | ESR | | 15 00 - 20 mm/hrs |
| | Blood Group & Rh Factor | B ⁺ POSITIVE | |
| | HbA1C | 4.5 | 4 - 5.6% |
| | Blood Sugar (F) | 80.2 | < 70 - 100 mg/dl |
| | Blood Sugar (PP) | 108.1 | < 140 mg/dl |
| | Urine Sugar (F) | NIL | - |
| | Urine Sugar (PP) | NIL | - |
| LIVER | S.Bilirubin Total | 1.00 | 0.30 - 1.20 mg/dl |
| | S.Bilirubin Direct | 0.30 | 0.10 - 0.30 mg/dl |
| | S.Bilirubin Indirect | 0.70 | 0.30 + 0.90 mg/dl |
| | S.G.O.T. | 21 | > 37 u/l |
| | S.G.P.T. | 29 | > 40 u/l |
| | S.Alk. Phosp. | 191 | 80 - 306 u/l |
| | G.G.T. | 30 | 5 - 40 u/l |
| | Total Protein | 6.7 | 6.5 - 8.5 gm/dl |
| | Albumin | 3.6 | 3.8 - 5.4 gm/dl |
| | Globulin | 3.1 | 2.3 - 3.5 gm/dl |
| | A/G Ratio | 1.1 | - |
| | AST/ALT Ratio | 0.7 | - |
| KIDNEY | Blood Urea | 25.1 | 15 - 45 mg/dl |
| | S.Creatinine | 0.71 | 0.60 - 1.30 mg/dl |
| | BUN | 17.0 | 6 - 24 mg/dl |
| | S.Uric Acid | 5.0 | M 3.1 - 7.0, F 2.5 - 5.6 mg/dl |
| | BUN/Creatinine Ratio | 0.6 | - |
| LIPID PROFILE | Total Cholesterol | 150.1 | Up to 200 mg/dl |
| | S.HDL | 42.1 | 30 - 70 mg/dl |
| | S.LDL | 74.1 | Up to 170 mg/dl |
| | S.VLDL | 24.1 | 5.0 - 40 mg/dl |
| | S. Triglycerides | 120.1 | Up to 170 mg/dl |
| | LDL/HDL Ratio | 1.7 | - |
| | Total Cholesterol/ HDL Ratio | 3.3 | - |
| THYROID | T3 | 65.1 | 40 - 181 ng/dl |
| | T4 | 6.0 | 4.6 - 10.5 µg/dl |
| | TSH | 4.63 | 0.30 - 5.0 mIU/l |

URINE EXAMINATION
Microscopic Examination :

| | | | | |
|-------------------------------|------------------|-------------|---------------------|--------|
| General/Chemical Examination: | | | RBC | Absent |
| | Colour | Pale Yellow | WBC | 5 - 7 |
| | Reaction | Acidic | Epithelial Cells | 2 - 3 |
| | Specific Gravity | QNS | Cast | Absent |
| | Appearance | Clear | Crystal | Absent |
| | Albumin | TRACE | Spermatozoa | Absent |
| | Sugar | Nil | Amorphous Sediments | Absent |
| | | | Other | Absent |

X-RAY CHEST
NORMAL STUDY
STOOL EXAMINATION
Microscopic Examination :

| | | | | |
|-------------------------------|----------------------|---|-----------------|---|
| General/Chemical Examination: | | | RBC | - |
| | Colour | - | WBC | - |
| | Consistency | - | Ova & Parasites | - |
| | PH | - | | |
| | Blanching Substances | - | | |

Dr. R.S. GUPTA
MD (Pathology) (MAHE)
Ph.D. No. 7924/19778

TECHNOLOGIST

Date :- 26/08/2023

Name :- Mrs. Meena Kumari

Refd. :- Dr Mukesh Gupta MD


Age & Sex :- 31Yrs/ Female

CYTO-PATHOLOGY

PAP SMEAR

| | |
|------------------------|---|
| 1. Specimen type | Received two conventional smears. |
| 2. Specimen adequacy | Smears are satisfactory for evaluation. |
| 3. Microscopic finding | Smears are moderately cellular comprises of predominantly intermediate with mature superficial squamous epithelial cells arranged in clusters & scattered singly. |
| 4. Inflammation | Not seen |
| 5. Bacilli | Not seen |
| 6. Endocervical cells | Not seen |
| 7. Koilocytic changes | Not seen |
| 8. Trichomonas | Not seen |
| 9. Dysplasia | Nil |
| 10. Neoplasia | Nil |
| 11. Endometrial cells | Nil |

Impression:- Negative for intraepithelial lesion or malignancy


Dr. R.S. GUPTA
MD (Pathology) (MAHE)
RMC No. 7924/19778

Doctor


TECHNOLOGIST



दक्ष हॉस्पिटल

396, गाँधी नगर स्कीम नं.8, अलवर (राज०) ☎ 0144-2703340

NAME :- MRS MEENA KUMAR 41 YRS

26-Aug-23

BOB HEALTH CHECKUP

Sonography / 2D Echo Cardiography / Doppler Report

U.S.G. OF ABDOMEN & PELVIS

LIVER

Liver is 12.8 cm vertically with normal echo-texture. Intra hepatic biliary radicals Are not dilated. No evidence of focal or diffuse lesion.

GALL BLADDER

Gall bladder is normal.

PANCREAS

Pancreas is normal in size, shape & echo-texture. No evidence of focal or diffuse lesion. MPD not dilated.

SPLEEN

Normal in size with normal shape & echo- texture. Spleen vein is normal. No evidence of focal or diffuse lesion

KIDNEY

Both kidneys are normal.

URINARY BLADDER

UB is normal.

UTERUS:

Uterus is normal in size (8.3x3.1x3.8cm) with homogenous echo-texture. Endometrial 8 mm in thickness & echo genicity

OVARIES:

Both ovaries are normal.

Advice- follow up/ hormonal study review at higher center for confirmation

Please correlate clinically: USG accuracy is 95 % due to technical limitations as well as inaccuracies inherent in the laboratory and statistical analysis biological process.
This report is not valid for medico-legal cases


DR. MUKESH GUPTA
SONOLOGIST

Dr. Mukesh Kumar Gupta
Physician & Sonologist
RM 5423/16262



भ्रूण लिंग परीक्षण की शिकायत
104 टोल फ्री सेवा पर भी की
जा सकती है।

भ्रूण लिंग परीक्षण की शिकायत 104 टोल फ्री सेवा पर भी की जा सकती है।



दक्ष हॉस्पिटल

396, गाँधी नगर स्कीम नं.8, अलवर (राज०) ☎ 0144-2703340

Sonography / 2D Echo Cardiography / Doppler Report

2D/ ECHO REPORT

Name: - Mrs Meena Kumari

Age: - 31 Yrs

Date: - 26-Aug-23

Reg. No.:- Alw/2009/04
BOB health checkup

PROCEDURES:

M-MODE/2D/DOPPLER/COLOR/CONTRAST B.A.S. M²

| MEASUREMENT: | | DOPPLER: | |
|----------------------|------|---------------------|-------------------------|
| AOD | 18 | NORMAL | NORMAL (cm/sec.) |
| LA | 24 | (20- 37mm) | MV 0.6 (0.8- 1.3) MR No |
| AVO | 15 | (19- 40mm) | AV 1.9 (1.2- 1.8) AR No |
| RVDd. | 11 | (12- 25mm) | TV 0.6 (0.3- 0.8) TR No |
| | | (03- 09mm) | PV 0.8 (0.7- 1.1) PR No |
| LVDd | 45 | (37- 56mm) | MITRAL VALVE- |
| LVDs | 27.8 | (22- 40mm) | AML Normal |
| IVS d | 7.8 | (06- 12mm) | PML Normal |
| IVS s | 10 | | |
| PWd | 3.9 | (05- 10mm) | AORTIC VALVE Normal |
| LV FUNCTION | | TV & PV are normal. | |
| M- E- S Separation | | <0.9cm | |
| Minor | | 24.42% | |
| LV Ejection Fraction | 69% | 65 +/- 12% | |

LV WALL MOTION: NO RWMA
ALL CARDIAC CHAMBERS ARE NORMAL
ALL VALVES ARE NORMAL
NO CLOT, VEGETATION, PERICARDIAL EFFUSION

FINAL DIAGNOSIS: NORMAL STUDY

Adv: - Follow up/ review at higher center for confirmation

Note:- Please Correlate clinically. Due to technical limitations as well as inaccuracies inherent in the laboratory and statistical analysis of biological process. Diagnostic accuracy of ECHO is up to 95% only.
Report is not valid for medico-legal purpose.


Dr. Mukesh Kumar Gupta
DR. MUKESH GUPTA
Physician
RM 5423/16262



"भ्रूण लिंग परीक्षण की शिकायत
104 टोल फ्री सेवा पर भी की
जा सकती है"

भ्रूण लिंग परीक्षण की शिकायत 104 टोल फ्री सेवा पर भी की जा सकती है।

ID: 903

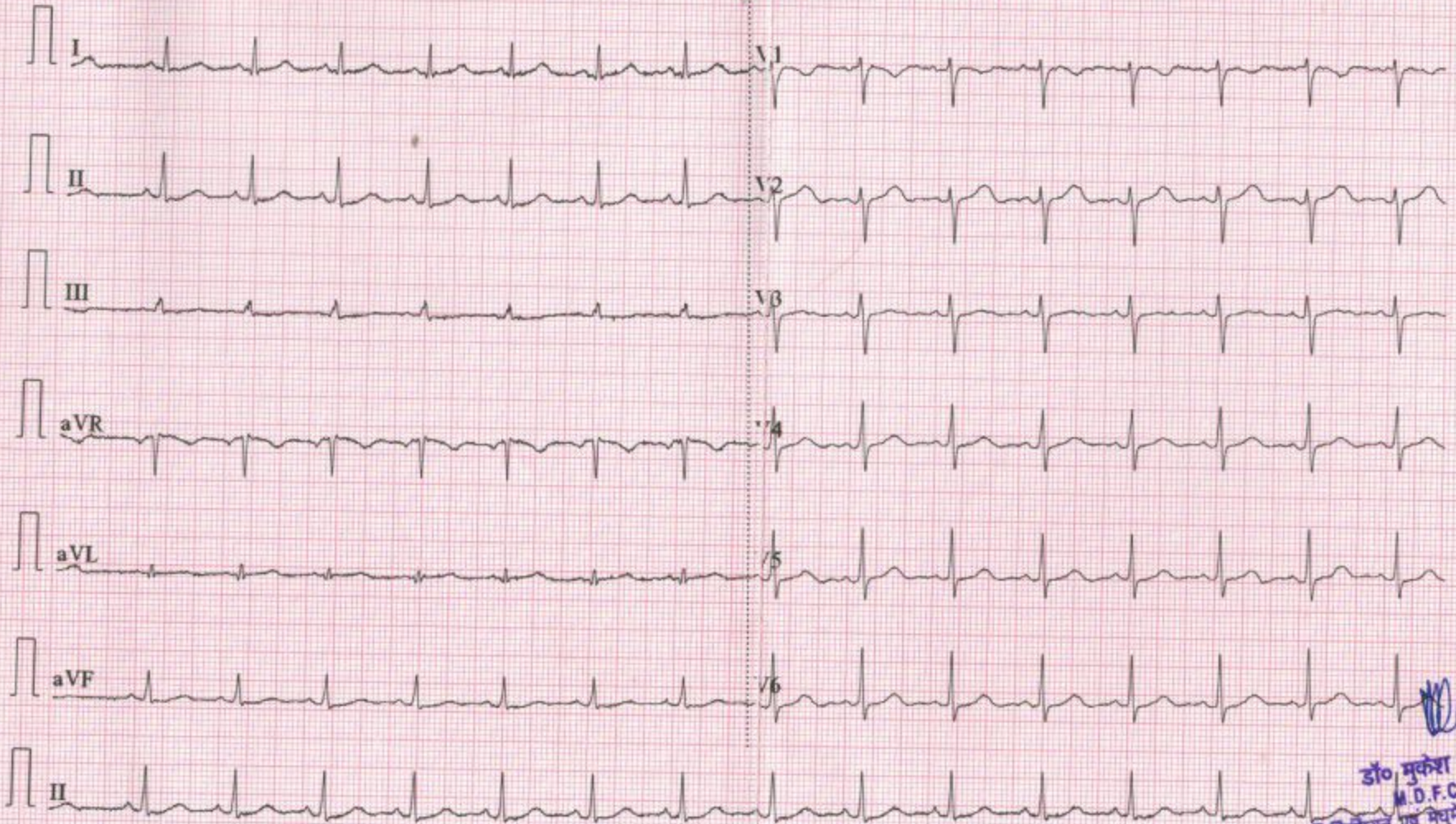
26-08-2023 12:04:20

Female Years
Req. No. :

HR : 93 bpm
 P : 92 ms
 PR : 126 ms
 QRS : 88 ms
 QT/QTcBz : 368/458 ms
 P/QRS/T : 47/52/26 °
 RV5/SV1 : 0.854/0.669 mV

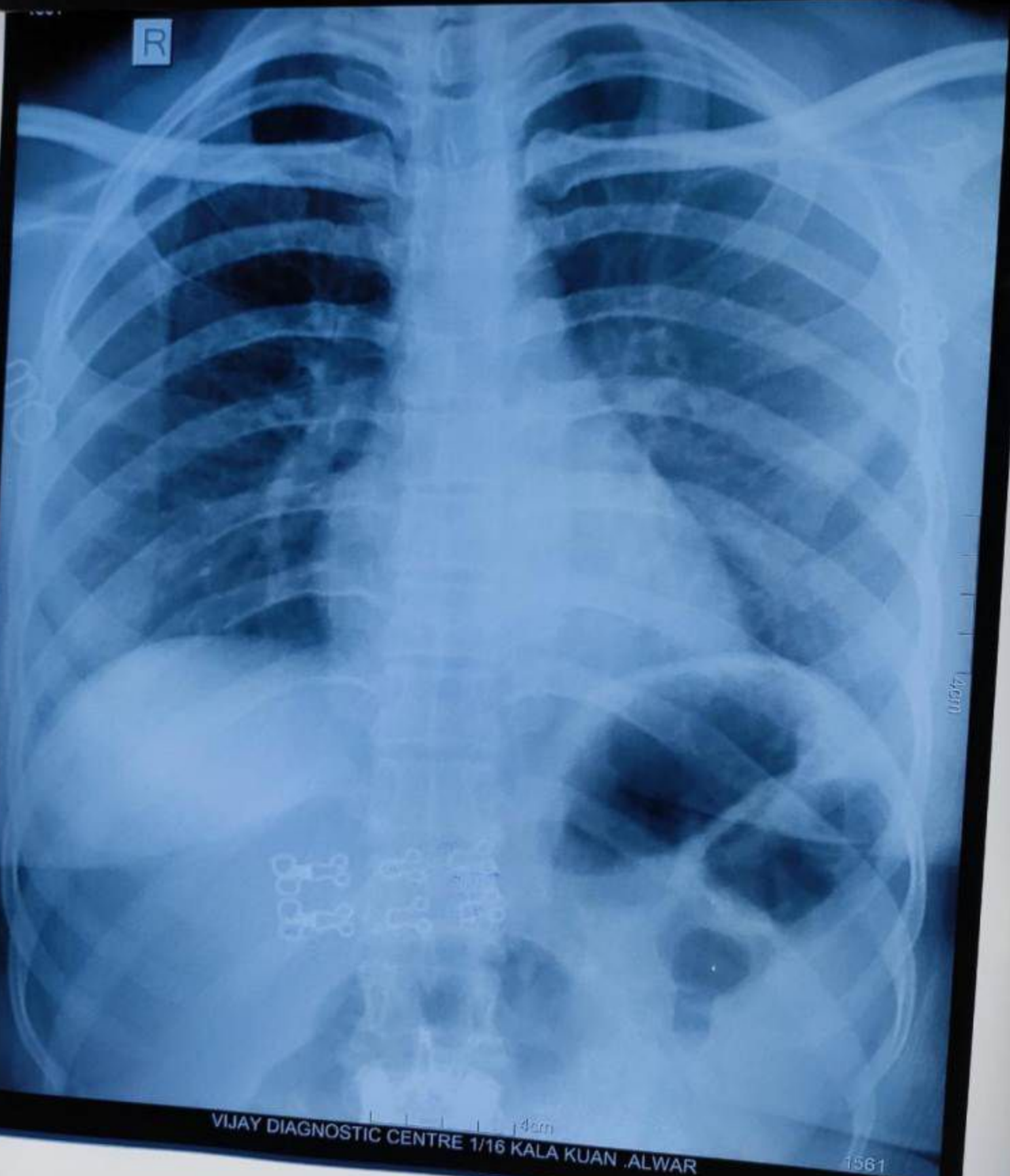
Diagnosis Information:
 Sinus rhythm
 Normal ECG

Report Confirmed by:



डॉ० मुकेश गुप्ता
 M.D.F.C.C.S.
 फिजिशियन एवं मेडिकल रोग विशेषज्ञ
 दक्ष हॉस्पिटल, अलवर
 रजि० नं०-5423/16262

R



VIJAY DIAGNOSTIC CENTRE 1/16 KALA KUAN .ALWAR

1561