


Name : Mr. S SHIVA KUMAR	Age : 51 Y	UHID :CKOR.0000248455
	Sex : M	
Address : kmg		OP Number :CKOROPV390252
Plan : ARCOFEMI MEDIWHEEL MALE AHC CREDIT PAN INDIA OP AGREEMENT		Bill No :CKOR-OCR-79338
		Date : 04.12.2023 09:51

Sno	Service Type/ServiceName	Department
1	ARCOFEMI - MEDIWHEEL - FULL BODY ANNUAL PLUS ABOVE 50Y MALE - 2D ECHO - PAN INDIA - FY2324	
1	URINE GLUCOSE(FASTING)	
2	GAMMA GLUTAMYL TRANSFERASE (GGT)	
3	PROSTATIC SPECIFIC ANTIGEN (PSA TOTAL)	
4	HbA1c, GLYCATED HEMOGLOBIN	
5	2 D ECHO → (10)	
6	LIVER FUNCTION TEST (LFT)	
7	X-RAY CHEST PA → (11)	
8	GLUCOSE, FASTING	
9	HEMOGRAM + PERIPHERAL SMEAR	
10	ENT CONSULTATION	11 (23) Dr. Nijar
11	FITNESS BY GENERAL PHYSICIAN	
12	DIET CONSULTATION	
13	COMPLETE URINE EXAMINATION	
14	URINE GLUCOSE(POST PRANDIAL)	
15	PERIPHERAL SMEAR	
16	ECG	
17	BLOOD GROUP ABO AND RH FACTOR	
18	LIPID PROFILE	
19	BODY MASS INDEX (BMI)	
20	OPHTHAL BY GENERAL PHYSICIAN	opp Rm (1)
21	RENAL PROFILE/RENAL FUNCTION TEST (RFT/KFT)	
22	ULTRASOUND - WHOLE ABDOMEN → (17)	
23	THYROID PROFILE (TOTAL T3, TOTAL T4, TSH)	
24	DENTAL CONSULTATION	
25	GLUCOSE, POST PRANDIAL (PP), 2 HOURS (POST MEAL)	

26 physio - (10)

wt 77 kg
ht 158 cm



DR VIJAYA LAKSHMI M
M.B.B.S, D.L.O, D.N.B(ENT)
Phone No.9972044580,080-25633823/24/23



Apollo Medical
Centre
Expertise. Closer to you

HEALTH CHECK- ENT

NAME: *S. Shiv Kumar* **P** **AGE:** *51*

EAR: **RE:** **LE:**

EXTERNAL EAR

MIDDLE EAR

INNER EAR (FN)

Normal

HEARING ASSESSMENT: **RE:** **LE:**

RHINNE

WEBER

ABC

Normal

NOSE

THROAT

AIRWAY

ORAL CAVITY

SEPTUM

OROPHARYNX

TURBINATES

PHARYNX

OTHERS

LARYNX

Normal

NECK

NECK NODES

OTHER

Normal

AUDIOMETRY

IMPRESSION

Normal

[Signature]

SIGNATURE:

Apollo Health and Lifestyle Limited

(CIN - U85110TG2000PLC046089) Regd. Office: #7-1-617/A, 615 & 616, Imperial Towers, 7th Floor ; Ameerpet, Hyderabad, Telangana - 500 038 | Email ID: enquiry@apollohl.com

APOLLO CLINICS NETWORK KARNATAKA

Bangalore (Basavanagudi | Bellandur | Electronics City | HSR Layout | Indira Nagar | JP Nagar | Kundalahalli | Koramangala | Sarjapur Road) **Mysore** (Kalladasa Road)

Online appointments: www.apolloclinic.com

TO BOOK AN APPOINTMENT

1860 500 7788

Patient Name : Mr.S SHIVA KUMAR	Collected : 04/Dec/2023 09:55AM
Age/Gender : 51 Y 7 M 19 D/M	Received : 04/Dec/2023 11:47AM
UHID/MR No : CKOR.0000248455	Reported : 04/Dec/2023 01:52PM
Visit ID : CKOROPV390252	Status : Final Report
Ref Doctor : Dr.SELF	Sponsor Name : ARCOFEMI HEALTHCARE LIMITED
Emp/Auth/TPA ID : BOBE51827	

DEPARTMENT OF HAEMATOLOGY

ARCOFEMI - MEDIWHEEL - FULL BODY ANNUAL PLUS ABOVE 50Y MALE - 2D ECHO - PAN INDIA - FY2324

Test Name	Result	Unit	Bio. Ref. Range	Method
-----------	--------	------	-----------------	--------

HEMOGRAM , WHOLE BLOOD EDTA

HAEMOGLOBIN	14	g/dL	13-17	Spectrophotometer
PCV	42.30	%	40-50	Electronic pulse & Calculation
RBC COUNT	4.96	Million/cu.mm	4.5-5.5	Electrical Impedence
MCV	85.3	fL	83-101	Calculated
MCH	28.3	pg	27-32	Calculated
MCHC	33.2	g/dL	31.5-34.5	Calculated
R.D.W	15.9	%	11.6-14	Calculated
TOTAL LEUCOCYTE COUNT (TLC)	6,810	cells/cu.mm	4000-10000	Electrical Impedence

DIFFERENTIAL LEUCOCYTIC COUNT (DLC)

NEUTROPHILS	54.5	%	40-80	Electrical Impedence
LYMPHOCYTES	34.7	%	20-40	Electrical Impedence
EOSINOPHILS	2.9	%	1-6	Electrical Impedence
MONOCYTES	7.3	%	2-10	Electrical Impedence
BASOPHILS	0.6	%	<1-2	Electrical Impedence

ABSOLUTE LEUCOCYTE COUNT

NEUTROPHILS	3711.45	Cells/cu.mm	2000-7000	Calculated
LYMPHOCYTES	2363.07	Cells/cu.mm	1000-3000	Calculated
EOSINOPHILS	197.49	Cells/cu.mm	20-500	Calculated
MONOCYTES	497.13	Cells/cu.mm	200-1000	Calculated
BASOPHILS	40.86	Cells/cu.mm	0-100	Calculated

PLATELET COUNT

PLATELET COUNT	274000	cells/cu.mm	150000-410000	Electrical impedence
----------------	--------	-------------	---------------	----------------------

ERYTHROCYTE SEDIMENTATION RATE (ESR)

ERYTHROCYTE SEDIMENTATION RATE (ESR)	21	mm at the end of 1 hour	0-15	Modified Westgren method
--------------------------------------	----	-------------------------	------	--------------------------

PERIPHERAL SMEAR

RBCs: are normocytic normochromic

WBCs: are normal in total number with normal distribution and morphology.

PLATELETS: appear adequate in number.

HEMOPARASITES: negative

Patient Name	: Mr.S SHIVA KUMAR	Collected	: 04/Dec/2023 09:55AM
Age/Gender	: 51 Y 7 M 19 D/M	Received	: 04/Dec/2023 11:47AM
UHID/MR No	: CKOR.0000248455	Reported	: 04/Dec/2023 01:52PM
Visit ID	: CKOROPV390252	Status	: Final Report
Ref Doctor	: Dr.SELF	Sponsor Name	: ARCOFEMI HEALTHCARE LIMITED
Emp/Auth/TPA ID	: BOBE51827		

DEPARTMENT OF HAEMATOLOGY

ARCOFEMI - MEDIWHEEL - FULL BODY ANNUAL PLUS ABOVE 50Y MALE - 2D ECHO - PAN INDIA - FY2324

Test Name	Result	Unit	Bio. Ref. Range	Method
-----------	--------	------	-----------------	--------

IMPRESSION: NORMOCYTIC NORMOCHROMIC BLOOD PICTURE



SIN No:BED230298958

NABL renewal accreditation under process

THIS TEST HAS BEEN PERFORMED AT APOLLO HEALTH AND LIFESTYLE LIMITED- RRL BANGALORE

Apollo Health and Lifestyle Limited (CIN - U85110TG2000PLC115819)
Regd. Office: 1-10-60/62, Ashoka Raghupathi Chambers, 5th Floor, Begumpet, Hyderabad, Telangana - 500 016 |
www.apollohl.com | Email ID: enquiry@apollohl.com, Ph No: 040-4904 7777, Fax No: 4904 7744

APOLLO CLINICS NETWORK

Telangana: Hyderabad (AS Rao Nagar | Chanda Nagar | Kondapur | Nallakunta | Nizampet | Manikonda | Uppal) | **Andhra Pradesh:** Vizag (Seethamma Peta) | **Karnataka:** Bangalore (Basavanagudi | Bellandur | Electronics City | Fraser Town | HSR Layout | Indira Nagar | JP Nagar | Kundalahalli | Koramangala | Sarjapur Road) | **Mysore** (VV Mohalla) | **Tamilnadu:** Chennai (Annanagar | Kotturpuram | Mogappair | T Nagar | Valasaravakkam | Velachery) | **Maharashtra:** Pune (Aundh | Nigdi Pradhikaran | Viman Nagar | Wanowrie) | **Uttar Pradesh:** Ghaziabad (Indrapuram) | **Gujarat:** Ahmedabad (Satellite) | **Punjab:** Amritsar (Court Road) | **Haryana:** Faridabad (Railway Station Road)

Address:
323/100/123, Doddathangur Village, Neeladri Main Road,
Neeladri Nagar, Electronic city, Bengaluru,
Karnataka- 560034

 **1860 500 7788**
www.apolloclinic.com

Patient Name : Mr.S SHIVA KUMAR	Collected : 04/Dec/2023 09:55AM
Age/Gender : 51 Y 7 M 19 D/M	Received : 04/Dec/2023 11:47AM
UHID/MR No : CKOR.0000248455	Reported : 04/Dec/2023 03:44PM
Visit ID : CKOROPV390252	Status : Final Report
Ref Doctor : Dr.SELF	Sponsor Name : ARCOFEMI HEALTHCARE LIMITED
Emp/Auth/TPA ID : BOBE51827	

DEPARTMENT OF HAEMATOLOGY

ARCOFEMI - MEDIWHEEL - FULL BODY ANNUAL PLUS ABOVE 50Y MALE - 2D ECHO - PAN INDIA - FY2324

Test Name	Result	Unit	Bio. Ref. Range	Method
-----------	--------	------	-----------------	--------

BLOOD GROUP ABO AND RH FACTOR , WHOLE BLOOD EDTA

BLOOD GROUP TYPE	O			Microplate Hemagglutination
Rh TYPE	Positive			Microplate Hemagglutination



SIN No:BED230298958

NABL renewal accreditation under process

THIS TEST HAS BEEN PERFORMED AT APOLLO HEALTH AND LIFESTYLE LIMITED- RRL BANGALORE

Apollo Health and Lifestyle Limited (CIN - U85110TG2000PLC115819)

Regd. Office: 1-10-60/62, Ashoka Raghupathi Chambers, 5th Floor, Begumpet, Hyderabad, Telangana - 500 016 |
www.apollohl.com | Email ID: enquiry@apollohl.com, Ph No: 040-4904 7777, Fax No: 4904 7744

APOLLO CLINICS NETWORK

Telangana: Hyderabad (AS Rao Nagar | Chanda Nagar | Kondapur | Nallakunta | Nizampet | Manikonda | Uppal) | **Andhra Pradesh:** Vizag (Seethamma Peta) | **Karnataka:** Bangalore (Basavanagudi | Bellandur | Electronics City | Fraser Town | HSR Layout | Indira Nagar | JP Nagar | Kundalahalli | Koramangala | Sarjapur Road) | **Mysore** (VV Mohalla) | **Tamilnadu:** Chennai (Annanagar | Kotturpuram | Mogappair | T Nagar | Valasaravakkam | Velachery) | **Maharashtra:** Pune (Aundh | Nigdi Pradhikaran | Viman Nagar | Wanowrie) | **Uttar Pradesh:** Ghaziabad (Indrapuram) | **Gujarat:** Ahmedabad (Satellite) | **Punjab:** Amritsar (Court Road) | **Haryana:** Faridabad (Railway Station Road)

Address:
323/100/123, Doddathangur Village, Neeladri Main Road,
Neeladri Nagar, Electronic city, Bengaluru,
Karnataka- 560034



Patient Name : Mr.S SHIVA KUMAR	Collected : 04/Dec/2023 12:43PM
Age/Gender : 51 Y 7 M 19 D/M	Received : 04/Dec/2023 05:17PM
UHID/MR No : CKOR.0000248455	Reported : 04/Dec/2023 05:41PM
Visit ID : CKOROPV390252	Status : Final Report
Ref Doctor : Dr.SELF	Sponsor Name : ARCOFEMI HEALTHCARE LIMITED
Emp/Auth/TPA ID : BOBE51827	

DEPARTMENT OF BIOCHEMISTRY

ARCOFEMI - MEDIWHEEL - FULL BODY ANNUAL PLUS ABOVE 50Y MALE - 2D ECHO - PAN INDIA - FY2324

Test Name	Result	Unit	Bio. Ref. Range	Method
-----------	--------	------	-----------------	--------

GLUCOSE, FASTING , NAF PLASMA	64	mg/dL	70-100	HEXOKINASE
--------------------------------------	-----------	-------	--------	------------

Comment:

As per American Diabetes Guidelines, 2023

Fasting Glucose Values in mg/dL	Interpretation
70-100 mg/dL	Normal
100-125 mg/dL	Prediabetes
≥126 mg/dL	Diabetes
<70 mg/dL	Hypoglycemia

Note:

- The diagnosis of Diabetes requires a fasting plasma glucose of > or = 126 mg/dL and/or a random / 2 hr post glucose value of > or = 200 mg/dL on at least 2 occasions.
- Very high glucose levels (>450 mg/dL in adults) may result in Diabetic Ketoacidosis & is considered critical.

GLUCOSE, POST PRANDIAL (PP), 2 HOURS , SODIUM FLUORIDE PLASMA (2 HR)	111	mg/dL	70-140	HEXOKINASE
---	------------	-------	--------	------------

Comment:

It is recommended that FBS and PPBS should be interpreted with respect to their Biological reference ranges and not with each other.

Conditions which may lead to lower postprandial glucose levels as compared to fasting glucose levels may be due to reactive hypoglycemia, dietary meal content, duration or timing of sampling after food digestion and absorption, medications such as insulin preparations, sulfonylureas, amylin analogues, or conditions such as overproduction of insulin.



SIN No:PLF02065017,PLP1393446

NABL renewal accreditation under process

THIS TEST HAS BEEN PERFORMED AT APOLLO HEALTH AND LIFESTYLE LIMITED- RRL BANGALORE

Apollo Health and Lifestyle Limited (CIN - U85110TG2000PLC115819)

Regd. Office: 1-10-60/62, Ashoka Raghupathi Chambers, 5th Floor, Begumpet, Hyderabad, Telangana - 500 016 | www.apollohl.com | Email ID: enquiry@apollohl.com, Ph No: 040-4904 7777, Fax No: 4904 7744

APOLLO CLINICS NETWORK

Telangana: Hyderabad (AS Rao Nagar | Chanda Nagar | Kondapur | Nallakunta | Nizampet | Manikonda | Uppal) | Andhra Pradesh: Vizag (Seethamma Peta) | Karnataka: Bangalore (Basavanagudi | Bellandur | Electronics City | Fraser Town | HSR Layout | Indira Nagar | JP Nagar | Kundalahalli | Koramangala | Sarjapur Road) | Mysore (VV Mohalla) | Tamilnadu: Chennai (Annanagar | Kotturpuram | Mogappair | T Nagar | Valasaravakkam | Velachery) | Maharashtra: Pune (Aundh | Nigdi Pradhikaran | Viman Nagar | Wanowrie) | Uttar Pradesh: Ghaziabad (Indrapuram) | Gujarat: Ahmedabad (Satellite) | Punjab: Amritsar (Court Road) | Haryana: Faridabad (Railway Station Road)

Address:
323/100/123, Doddathangur Village, Neeladri Main Road,
Neeladri Nagar, Electronic city, Bengaluru,
Karnataka - 560034



Patient Name : Mr.S SHIVA KUMAR	Collected : 04/Dec/2023 09:55AM
Age/Gender : 51 Y 7 M 19 D/M	Received : 04/Dec/2023 11:48AM
UHID/MR No : CKOR.0000248455	Reported : 04/Dec/2023 02:18PM
Visit ID : CKOROPV390252	Status : Final Report
Ref Doctor : Dr.SELF	Sponsor Name : ARCOFEMI HEALTHCARE LIMITED
Emp/Auth/TPA ID : BOBE51827	

DEPARTMENT OF BIOCHEMISTRY

ARCOFEMI - MEDIWHEEL - FULL BODY ANNUAL PLUS ABOVE 50Y MALE - 2D ECHO - PAN INDIA - FY2324

Test Name	Result	Unit	Bio. Ref. Range	Method
HBA1C, GLYCATED HEMOGLOBIN , WHOLE BLOOD EDTA	8.1	%		HPLC
ESTIMATED AVERAGE GLUCOSE (eAG) , WHOLE BLOOD EDTA	186	mg/dL		Calculated

Comment:

Reference Range as per American Diabetes Association (ADA) 2023 Guidelines:

REFERENCE GROUP	HBA1C %
NON DIABETIC	<5.7
PREDIABETES	5.7 – 6.4
DIABETES	≥ 6.5
DIABETICS	
EXCELLENT CONTROL	6 – 7
FAIR TO GOOD CONTROL	7 – 8
UNSATISFACTORY CONTROL	8 – 10
POOR CONTROL	>10

Note: Dietary preparation or fasting is not required.

- HbA1C is recommended by American Diabetes Association for Diagnosing Diabetes and monitoring Glycemic Control by American Diabetes Association guidelines 2023.
- Trends in HbA1C values is a better indicator of Glycemic control than a single test.
- Low HbA1C in Non-Diabetic patients are associated with Anemia (Iron Deficiency/Hemolytic), Liver Disorders, Chronic Kidney Disease. Clinical Correlation is advised in interpretation of low Values.
- Falsely low HbA1c (below 4%) may be observed in patients with clinical conditions that shorten erythrocyte life span or decrease mean erythrocyte age. HbA1c may not accurately reflect glycemic control when clinical conditions that affect erythrocyte survival are present.
- In cases of Interference of Hemoglobin variants in HbA1C, alternative methods (Fructosamine) estimation is recommended for Glycemic Control
 - A: HbF >25%
 - B: Homozygous Hemoglobinopathy.
 (Hb Electrophoresis is recommended method for detection of Hemoglobinopathy)



SIN No:EDT230109768

NABL renewal accreditation under process

THIS TEST HAS BEEN PERFORMED AT APOLLO HEALTH AND LIFESTYLE LIMITED- RRL BANGALORE

Apollo Health and Lifestyle Limited (CIN - U85110TG2000PLC115819)
 Regd. Office: 1-10-60/62, Ashoka Raghupathi Chambers, 5th Floor, Begumpet, Hyderabad, Telangana - 500 016 |
 www.apollohl.com | Email ID: enquiry@apollohl.com, Ph No: 040-4904 7777, Fax No: 4904 7744

APOLLO CLINICS NETWORK

Telangana: Hyderabad (AS Rao Nagar | Chanda Nagar | Kondapur | Nallakunta | Nizampet | Manikonda | Uppal) | Andhra Pradesh: Vizag (Seethamma Peta) | Karnataka: Bangalore (Basavanagudi | Bellandur | Electronics City | Fraser Town | HSR Layout | Indira Nagar | JP Nagar | Kundalahalli | Koramangala | Sarjapur Road) | Mysore (VV Mohalla) | Tamilnadu: Chennai (Annanagar | Kotturpuram | Mogappair | T Nagar | Valasaravakkam | Velachery) | Maharashtra: Pune (Aundh | Nigdi Pradhikaran | Viman Nagar | Wanowrie) | Uttar Pradesh: Ghaziabad (Indrapuram) | Gujarat: Ahmedabad (Satellite) | Punjab: Amritsar (Court Road) | Haryana: Faridabad (Railway Station Road)

Address:
 323/100/123, Doddathangur Village, Neeladri Main Road,
 Neeladri Nagar, Electronic city, Bengaluru,
 Karnataka - 560034

 **1860 500 7788**
 www.apolloclinic.com

Patient Name : Mr.S SHIVA KUMAR	Collected : 04/Dec/2023 09:55AM
Age/Gender : 51 Y 7 M 19 D/M	Received : 04/Dec/2023 11:54AM
UHID/MR No : CKOR.0000248455	Reported : 04/Dec/2023 02:19PM
Visit ID : CKOROPV390252	Status : Final Report
Ref Doctor : Dr.SELF	Sponsor Name : ARCOFEMI HEALTHCARE LIMITED
Emp/Auth/TPA ID : BOBE51827	

DEPARTMENT OF BIOCHEMISTRY

ARCOFEMI - MEDIWHEEL - FULL BODY ANNUAL PLUS ABOVE 50Y MALE - 2D ECHO - PAN INDIA - FY2324

Test Name	Result	Unit	Bio. Ref. Range	Method
-----------	--------	------	-----------------	--------

LIPID PROFILE , SERUM

TOTAL CHOLESTEROL	93	mg/dL	<200	CHO-POD
TRIGLYCERIDES	76	mg/dL	<150	GPO-POD
HDL CHOLESTEROL	34	mg/dL	40-60	Enzymatic Immunoinhibition
NON-HDL CHOLESTEROL	59	mg/dL	<130	Calculated
LDL CHOLESTEROL	44.2	mg/dL	<100	Calculated
VLDL CHOLESTEROL	15.2	mg/dL	<30	Calculated
CHOL / HDL RATIO	2.75		0-4.97	Calculated

Comment:

Reference Interval as per National Cholesterol Education Program (NCEP) Adult Treatment Panel III Report.

	Desirable	Borderline High	High	Very High
TOTAL CHOLESTEROL	< 200	200 - 239	≥ 240	
TRIGLYCERIDES	<150	150 - 199	200 - 499	≥ 500
LDL	Optimal < 100 Near Optimal 100-129	130 - 159	160 - 189	≥ 190
HDL	≥ 60			
NON-HDL CHOLESTEROL	Optimal <130; Above Optimal 130-159	160-189	190-219	>220

1. Measurements in the same patient on different days can show physiological and analytical variations.
2. NCEP ATP III identifies non-HDL cholesterol as a secondary target of therapy in persons with high triglycerides.
3. Primary prevention algorithm now includes absolute risk estimation and lower LDL Cholesterol target levels to determine eligibility of drug therapy.
4. Low HDL levels are associated with Coronary Heart Disease due to insufficient HDL being available to participate in reverse cholesterol transport, the process by which cholesterol is eliminated from peripheral tissues.
5. As per NCEP guidelines, all adults above the age of 20 years should be screened for lipid status. Selective screening of children above the age of 2 years with a family history of premature cardiovascular disease or those with at least one parent with high total cholesterol is recommended.
6. VLDL, LDL Cholesterol Non HDL Cholesterol, CHOL/HDL RATIO, LDL/HDL RATIO are calculated parameters when Triglycerides are below 350mg/dl. When Triglycerides are more than 350 mg/dl LDL cholesterol is a direct measurement.



SIN No:SE04559247

NABL renewal accreditation under process

THIS TEST HAS BEEN PERFORMED AT APOLLO HEALTH AND LIFESTYLE LIMITED- RRL BANGALORE

Apollo Health and Lifestyle Limited (CIN - U85110TG2000PLC115819)

Regd. Office: 1-10-60/62, Ashoka Raghupathi Chambers, 5th Floor, Begumpet, Hyderabad, Telangana - 500 016 | www.apollohl.com | Email ID: enquiry@apollohl.com, Ph No: 040-4904 7777, Fax No: 4904 7744

APOLLO CLINICS NETWORK

Telangana: Hyderabad (AS Rao Nagar | Chanda Nagar | Kondapur | Nallakunta | Nizampet | Manikonda | Uppal) Andhra Pradesh: Vizag (Seethamma Peta) Karnataka: Bangalore (Basavanagudi | Bellandur | Electronics City | Fraser Town | HSR Layout | Indira Nagar | JP Nagar | Kundalahalli | Koramangala | Sarjapur Road) Mysore (VV Mohalla) Tamilnadu: Chennai (Annanagar | Kotturpuram | Mogappair | T Nagar | Valasaravakkam | Velachery) Maharashtra: Pune (Aundh | Nigdi Pradhikaran | Viman Nagar | Wanowrie) Uttar Pradesh: Ghaziabad (Indrapuram) Gujarat: Ahmedabad (Satellite) Punjab: Amritsar (Court Road) Haryana: Faridabad (Railway Station Road)

Address:
323/100/123, Doddathangur Village, Neeladri Main Road,
Neeladri Nagar, Electronic city, Bengaluru,
Karnataka- 560034

 **1860 500 7788**
www.apolloclinic.com

Patient Name : Mr.S SHIVA KUMAR	Collected : 04/Dec/2023 09:55AM
Age/Gender : 51 Y 7 M 19 D/M	Received : 04/Dec/2023 11:54AM
UHID/MR No : CKOR.0000248455	Reported : 04/Dec/2023 02:19PM
Visit ID : CKOROPV390252	Status : Final Report
Ref Doctor : Dr.SELF	Sponsor Name : ARCOFEMI HEALTHCARE LIMITED
Emp/Auth/TPA ID : BOBE51827	

DEPARTMENT OF BIOCHEMISTRY

ARCOFEMI - MEDIWHEEL - FULL BODY ANNUAL PLUS ABOVE 50Y MALE - 2D ECHO - PAN INDIA - FY2324

Test Name	Result	Unit	Bio. Ref. Range	Method
-----------	--------	------	-----------------	--------

LIVER FUNCTION TEST (LFT) , SERUM

BILIRUBIN, TOTAL	0.71	mg/dL	0.3-1.2	DPD
BILIRUBIN CONJUGATED (DIRECT)	0.17	mg/dL	<0.2	DPD
BILIRUBIN (INDIRECT)	0.54	mg/dL	0.0-1.1	Dual Wavelength
ALANINE AMINOTRANSFERASE (ALT/SGPT)	18	U/L	<50	IFCC
ASPARTATE AMINOTRANSFERASE (AST/SGOT)	21.0	U/L	<50	IFCC
ALKALINE PHOSPHATASE	126.00	U/L	30-120	IFCC
PROTEIN, TOTAL	6.91	g/dL	6.6-8.3	Biuret
ALBUMIN	4.28	g/dL	3.5-5.2	BROMO CRESOL GREEN
GLOBULIN	2.63	g/dL	2.0-3.5	Calculated
A/G RATIO	1.63		0.9-2.0	Calculated

Comment:

LFT results reflect different aspects of the health of the liver, i.e., hepatocyte integrity (AST & ALT), synthesis and secretion of bile (Bilirubin, ALP), cholestasis (ALP, GGT), protein synthesis (Albumin)

Common patterns seen:

1. Hepatocellular Injury:

- AST – Elevated levels can be seen. However, it is not specific to liver and can be raised in cardiac and skeletal injuries.
- ALT – Elevated levels indicate hepatocellular damage. It is considered to be most specific lab test for hepatocellular injury. Values also correlate well with increasing BMI.
- Disproportionate increase in AST, ALT compared with ALP.
- Bilirubin may be elevated.
- AST: ALT (ratio) – In case of hepatocellular injury AST: ALT > 1 In Alcoholic Liver Disease AST: ALT usually >2. This ratio is also seen to be increased in NAFLD, Wilson's diseases, Cirrhosis, but the increase is usually not >2.

2. Cholestatic Pattern:

- ALP – Disproportionate increase in ALP compared with AST, ALT.
- Bilirubin may be elevated.
- ALP elevation also seen in pregnancy, impacted by age and sex.
- To establish the hepatic origin correlation with GGT helps. If GGT elevated indicates hepatic cause of increased ALP.

3. Synthetic function impairment:

- Albumin- Liver disease reduces albumin levels.
- Correlation with PT (Prothrombin Time) helps.

Patient Name : Mr.S SHIVA KUMAR	Collected : 04/Dec/2023 09:55AM
Age/Gender : 51 Y 7 M 19 D/M	Received : 04/Dec/2023 11:54AM
UHID/MR No : CKOR.0000248455	Reported : 04/Dec/2023 02:19PM
Visit ID : CKOROPV390252	Status : Final Report
Ref Doctor : Dr.SELF	Sponsor Name : ARCOFEMI HEALTHCARE LIMITED
Emp/Auth/TPA ID : BOBE51827	

DEPARTMENT OF BIOCHEMISTRY

ARCOFEMI - MEDIWHEEL - FULL BODY ANNUAL PLUS ABOVE 50Y MALE - 2D ECHO - PAN INDIA - FY2324

Test Name	Result	Unit	Bio. Ref. Range	Method
-----------	--------	------	-----------------	--------



SIN No:SE04559247

NABL renewal accreditation under process

THIS TEST HAS BEEN PERFORMED AT APOLLO HEALTH AND LIFESTYLE LIMITED- RRL BANGALORE

Apollo Health and Lifestyle Limited (CIN - U85110TG2000PLC115819)
 Regd. Office: 1-10-60/62, Ashoka Raghupathi Chambers, 5th Floor, Begumpet, Hyderabad, Telangana - 500 016 |
 www.apollohl.com | Email ID: enquiry@apollohl.com, Ph No: 040-4904 7777, Fax No: 4904 7744

APOLLO CLINICS NETWORK

Telangana: Hyderabad (AS Rao Nagar | Chanda Nagar | Kondapur | Nallakunta | Nizampet | Manikonda | Uppal) | **Andhra Pradesh:** Vizag (Seethamma Peta) | **Karnataka:** Bangalore (Basavanagudi | Bellandur | Electronics City | Fraser Town | HSR Layout | Indira Nagar | JP Nagar | Kundalahalli | Koramangala | Sarjapur Road) | **Mysore** (VV Mohalla) | **Tamilnadu:** Chennai (Annanagar | Kotturpuram | Mogappair | T Nagar | Valasaravakkam | Velachery) | **Maharashtra:** Pune (Aundh | Nigdi Pradhikaran | Viman Nagar | Wanowrie) | **Uttar Pradesh:** Ghaziabad (Indrapuram) | **Gujarat:** Ahmedabad (Satellite) | **Punjab:** Amritsar (Court Road) | **Haryana:** Faridabad (Railway Station Road)

Address:
 323/100/123, Doddathangur Village, Neeladri Main Road,
 Neeladri Nagar, Electronic city, Bengaluru,
 Karnataka - 560034



Patient Name : Mr.S SHIVA KUMAR	Collected : 04/Dec/2023 09:55AM
Age/Gender : 51 Y 7 M 19 D/M	Received : 04/Dec/2023 11:54AM
UHID/MR No : CKOR.0000248455	Reported : 04/Dec/2023 02:19PM
Visit ID : CKOROPV390252	Status : Final Report
Ref Doctor : Dr.SELF	Sponsor Name : ARCOFEMI HEALTHCARE LIMITED
Emp/Auth/TPA ID : BOBE51827	

DEPARTMENT OF BIOCHEMISTRY

ARCOFEMI - MEDIWHEEL - FULL BODY ANNUAL PLUS ABOVE 50Y MALE - 2D ECHO - PAN INDIA - FY2324

Test Name	Result	Unit	Bio. Ref. Range	Method
-----------	--------	------	-----------------	--------

RENAL PROFILE/KIDNEY FUNCTION TEST (RFT/KFT) , SERUM

CREATININE	0.63	mg/dL	0.72 – 1.18	JAFFE METHOD
UREA	23.90	mg/dL	17-43	GLDH, Kinetic Assay
BLOOD UREA NITROGEN	11.2	mg/dL	8.0 - 23.0	Calculated
URIC ACID	4.25	mg/dL	3.5–7.2	Uricase PAP
CALCIUM	9.00	mg/dL	8.8-10.6	Arsenazo III
PHOSPHORUS, INORGANIC	3.37	mg/dL	2.5-4.5	Phosphomolybdate Complex
SODIUM	138	mmol/L	136–146	ISE (Indirect)
POTASSIUM	4.1	mmol/L	3.5–5.1	ISE (Indirect)
CHLORIDE	101	mmol/L	101–109	ISE (Indirect)



SIN No:SE04559247

NABL renewal accreditation under process

THIS TEST HAS BEEN PERFORMED AT APOLLO HEALTH AND LIFESTYLE LIMITED- RRL BANGALORE

Apollo Health and Lifestyle Limited (CIN - U85110TG2000PLC115819)

Regd. Office: 1-10-60/62, Ashoka Raghupathi Chambers, 5th Floor, Begumpet, Hyderabad, Telangana - 500 016 | www.apollohl.com | Email ID: enquiry@apollohl.com, Ph No: 040-4904 7777, Fax No: 4904 7744

APOLLO CLINICS NETWORK

Telangana: Hyderabad (AS Rao Nagar | Chanda Nagar | Kondapur | Nallakunta | Nizampet | Manikonda | Uppal) Andhra Pradesh: Vizag (Seethamma Peta) Karnataka: Bangalore (Basavanagudi | Bellandur | Electronics City | Fraser Town | HSR Layout | Indira Nagar | JP Nagar | Kundalahalli | Koramangala | Sarjapur Road) Mysore (VV Mohalla) Tamilnadu: Chennai (Annanagar | Kotturpuram | Mogappair | T Nagar | Valasaravakkam | Velachery) Maharashtra: Pune (Aundh | Nigdi Pradhikaran | Viman Nagar | Wanowrie) Uttar Pradesh: Ghaziabad (Indrapuram) Gujarat: Ahmedabad (Satellite) Punjab: Amritsar (Court Road) Haryana: Faridabad (Railway Station Road)

Address:
323/100/123, Doddathangur Village, Neeladri Main Road,
Neeladri Nagar, Electronic city, Bengaluru,
Karnataka - 560034

 **1860 500 7788**
www.apolloclinic.com

Patient Name : Mr.S SHIVA KUMAR	Collected : 04/Dec/2023 09:55AM
Age/Gender : 51 Y 7 M 19 D/M	Received : 04/Dec/2023 11:54AM
UHID/MR No : CKOR.0000248455	Reported : 04/Dec/2023 12:47PM
Visit ID : CKOROPV390252	Status : Final Report
Ref Doctor : Dr.SELF	Sponsor Name : ARCOFEMI HEALTHCARE LIMITED
Emp/Auth/TPA ID : BOBE51827	

DEPARTMENT OF BIOCHEMISTRY

ARCOFEMI - MEDIWHEEL - FULL BODY ANNUAL PLUS ABOVE 50Y MALE - 2D ECHO - PAN INDIA - FY2324

Test Name	Result	Unit	Bio. Ref. Range	Method
GAMMA GLUTAMYL TRANSPEPTIDASE (GGT) , SERUM	17.00	U/L	<55	IFCC



SIN No:SE04559247

NABL renewal accreditation under process

THIS TEST HAS BEEN PERFORMED AT APOLLO HEALTH AND LIFESTYLE LIMITED- RRL BANGALORE

Apollo Health and Lifestyle Limited (CIN - U85110TG2000PLC115819)
Regd. Office: 1-10-60/62, Ashoka Raghupathi Chambers, 5th Floor, Begumpet, Hyderabad, Telangana - 500 016 |
www.apollohl.com | Email ID: enquiry@apollohl.com, Ph No: 040-4904 7777, Fax No: 4904 7744

APOLLO CLINICS NETWORK

Telangana: Hyderabad (AS Rao Nagar | Chanda Nagar | Kondapur | Nallakunta | Nizampet | Manikonda | Uppal) | **Andhra Pradesh:** Vizag (Seethamma Peta) | **Karnataka:** Bangalore (Basavanagudi | Bellandur | Electronics City | Fraser Town | HSR Layout | Indira Nagar | JP Nagar | Kundalahalli | Koramangala | Sarjapur Road) | **Mysore** (VV Mohalla) | **Tamilnadu:** Chennai (Annanagar | Kotturpuram | Mogappair | T Nagar | Valasaravakkam | Velachery) | **Maharashtra:** Pune (Aundh | Nigdi Pradhikaran | Viman Nagar | Wanowrie) | **Uttar Pradesh:** Ghaziabad (Indrapuram) | **Gujarat:** Ahmedabad (Satellite) | **Punjab:** Amritsar (Court Road) | **Haryana:** Faridabad (Railway Station Road)

Address:
323/100/123, Doddathangur Village, Neeladri Main Road,
Neeladri Nagar, Electronic city, Bengaluru,
Karnataka- 560034

 **1860 500 7788**
www.apolloclinic.com

Patient Name : Mr.S SHIVA KUMAR	Collected : 04/Dec/2023 09:55AM
Age/Gender : 51 Y 7 M 19 D/M	Received : 04/Dec/2023 11:55AM
UHID/MR No : CKOR.0000248455	Reported : 04/Dec/2023 02:09PM
Visit ID : CKOROPV390252	Status : Final Report
Ref Doctor : Dr.SELF	Sponsor Name : ARCOFEMI HEALTHCARE LIMITED
Emp/Auth/TPA ID : BOBE51827	

DEPARTMENT OF IMMUNOLOGY

ARCOFEMI - MEDIWHEEL - FULL BODY ANNUAL PLUS ABOVE 50Y MALE - 2D ECHO - PAN INDIA - FY2324

Test Name	Result	Unit	Bio. Ref. Range	Method
-----------	--------	------	-----------------	--------

THYROID PROFILE TOTAL (T3, T4, TSH) , SERUM

TRI-IODOTHYRONINE (T3, TOTAL)	1.37	ng/mL	0.64-1.52	CMIA
THYROXINE (T4, TOTAL)	9.74	µg/dL	4.87-11.72	CMIA
THYROID STIMULATING HORMONE (TSH)	3.590	µIU/mL	0.35-4.94	CMIA

Comment:

For pregnant females	Bio Ref Range for TSH in uIU/ml (As per American Thyroid Association)
First trimester	0.1 - 2.5
Second trimester	0.2 - 3.0
Third trimester	0.3 - 3.0

- TSH is a glycoprotein hormone secreted by the anterior pituitary. TSH activates production of T3 (Triiodothyronine) and its prohormone T4 (Thyroxine). Increased blood level of T3 and T4 inhibit production of TSH.
- TSH is elevated in primary hypothyroidism and will be low in primary hyperthyroidism. Elevated or low TSH in the context of normal free thyroxine is often referred to as sub-clinical hypo- or hyperthyroidism respectively.
- Both T4 & T3 provides limited clinical information as both are highly bound to proteins in circulation and reflects mostly inactive hormone. Only a very small fraction of circulating hormone is free and biologically active.
- Significant variations in TSH can occur with circadian rhythm, hormonal status, stress, sleep deprivation, medication & circulating antibodies.

TSH	T3	T4	FT4	Conditions
High	Low	Low	Low	Primary Hypothyroidism, Post Thyroidectomy, Chronic Autoimmune Thyroiditis
High	N	N	N	Subclinical Hypothyroidism, Autoimmune Thyroiditis, Insufficient Hormone Replacement Therapy.
N/Low	Low	Low	Low	Secondary and Tertiary Hypothyroidism
Low	High	High	High	Primary Hyperthyroidism, Goitre, Thyroiditis, Drug effects, Early Pregnancy
Low	N	N	N	Subclinical Hyperthyroidism
Low	Low	Low	Low	Central Hypothyroidism, Treatment with Hyperthyroidism
Low	N	High	High	Thyroiditis, Interfering Antibodies
N/Low	High	N	N	T3 Thyrotoxicosis, Non thyroidal causes
High	High	High	High	Pituitary Adenoma; TSHoma/Thyrotropinoma



SIN No:SPL23174806

NABL renewal accreditation under process

THIS TEST HAS BEEN PERFORMED AT APOLLO HEALTH AND LIFESTYLE LIMITED- RRL BANGALORE

Apollo Health and Lifestyle Limited (CIN - U85110TG2000PLC115819)
 Regd. Office: 1-10-60/62, Ashoka Raghupathi Chambers, 5th Floor, Begumpet, Hyderabad, Telangana - 500 016 |
 www.apollohl.com | Email ID: enquiry@apollohl.com, Ph No: 040-4904 7777, Fax No: 4904 7744

APOLLO CLINICS NETWORK

Telangana: Hyderabad (AS Rao Nagar | Chanda Nagar | Kondapur | Nallakunta | Nizampet | Manikonda | Uppal) | Andhra Pradesh: Vizag (Seethamma Peta) | Karnataka: Bangalore (Basavanagudi | Bellandur | Electronics City | Fraser Town | HSR Layout | Indira Nagar | JP Nagar | Kundalahalli | Koramangala | Sarjapur Road) | Mysore (VV Mohalla) | Tamilnadu: Chennai (Annanagar | Kotturpuram | Mogappair | T Nagar | Valasaravakkam | Velachery) | Maharashtra: Pune (Aundh | Nigdi Pradhikaran | Viman Nagar | Wanowrie) | Uttar Pradesh: Ghaziabad (Indrapuram) | Gujarat: Ahmedabad (Satellite) | Punjab: Amritsar (Court Road) | Haryana: Faridabad (Railway Station Road)

Address:
 323/100/123, Doddathangur Village, Neeladri Main Road,
 Neeladri Nagar, Electronic city, Bengaluru,
 Karnataka- 560034



Patient Name : Mr.S SHIVA KUMAR	Collected : 04/Dec/2023 09:55AM
Age/Gender : 51 Y 7 M 19 D/M	Received : 04/Dec/2023 11:55AM
UHID/MR No : CKOR.0000248455	Reported : 04/Dec/2023 02:09PM
Visit ID : CKOROPV390252	Status : Final Report
Ref Doctor : Dr.SELF	Sponsor Name : ARCOFEMI HEALTHCARE LIMITED
Emp/Auth/TPA ID : BOBE51827	

DEPARTMENT OF IMMUNOLOGY

ARCOFEMI - MEDIWHEEL - FULL BODY ANNUAL PLUS ABOVE 50Y MALE - 2D ECHO - PAN INDIA - FY2324

Test Name	Result	Unit	Bio. Ref. Range	Method
TOTAL PROSTATIC SPECIFIC ANTIGEN (tPSA) , SERUM	0.378	ng/mL	<4	CMIA



SIN No:SPL23174806

NABL renewal accreditation under process

THIS TEST HAS BEEN PERFORMED AT APOLLO HEALTH AND LIFESTYLE LIMITED- RRL BANGALORE

Apollo Health and Lifestyle Limited (CIN - U85110TG2000PLC115819)

Regd. Office: 1-10-60/62, Ashoka Raghupathi Chambers, 5th Floor, Begumpet, Hyderabad, Telangana - 500 016 | www.apollohl.com | Email ID: enquiry@apollohl.com, Ph No: 040-4904 7777, Fax No: 4904 7744

APOLLO CLINICS NETWORK

Telangana: Hyderabad (AS Rao Nagar | Chanda Nagar | Kondapur | Nallakunta | Nizampet | Manikonda | Uppal) | **Andhra Pradesh:** Vizag (Seethamma Peta) | **Karnataka:** Bangalore (Basavanagudi | Bellandur | Electronics City | Fraser Town | HSR Layout | Indira Nagar | JP Nagar | Kundalahalli | Koramangala | Sarjapur Road) | **Mysore** (VV Mohalla) | **Tamilnadu:** Chennai (Annanagar | Kotturpuram | Mogappair | T Nagar | Valasaravakkam | Velachery) | **Maharashtra:** Pune (Aundh | Nigdi Pradhikaran | Viman Nagar | Wanowrie) | **Uttar Pradesh:** Ghaziabad (Indrapuram) | **Gujarat:** Ahmedabad (Satellite) | **Punjab:** Amritsar (Court Road) | **Haryana:** Faridabad (Railway Station Road)

Address:
323/100/123, Doddathangur Village, Neeladri Main Road,
Neeladri Nagar, Electronic city, Bengaluru,
Karnataka - 560034

 **1860 500 7788**
www.apolloclinic.com

Patient Name : Mr.S SHIVA KUMAR	Collected : 04/Dec/2023 09:54AM
Age/Gender : 51 Y 7 M 19 D/M	Received : 04/Dec/2023 12:09PM
UHID/MR No : CKOR.0000248455	Reported : 04/Dec/2023 06:07PM
Visit ID : CKOROPV390252	Status : Final Report
Ref Doctor : Dr.SELF	Sponsor Name : ARCOFEMI HEALTHCARE LIMITED
Emp/Auth/TPA ID : BOBE51827	

DEPARTMENT OF CLINICAL PATHOLOGY

ARCOFEMI - MEDIWHEEL - FULL BODY ANNUAL PLUS ABOVE 50Y MALE - 2D ECHO - PAN INDIA - FY2324

Test Name	Result	Unit	Bio. Ref. Range	Method
-----------	--------	------	-----------------	--------

COMPLETE URINE EXAMINATION (CUE) , URINE

PHYSICAL EXAMINATION

COLOUR	PALE YELLOW		PALE YELLOW	Visual
TRANSPARENCY	CLEAR		CLEAR	Visual
pH	5.5		5-7.5	DOUBLE INDICATOR
SP. GRAVITY	1.025		1.002-1.030	Bromothymol Blue

BIOCHEMICAL EXAMINATION

URINE PROTEIN	NEGATIVE		NEGATIVE	PROTEIN ERROR OF INDICATOR
GLUCOSE	POSITIVE ++++		NEGATIVE	GLUCOSE OXIDASE
URINE BILIRUBIN	NEGATIVE		NEGATIVE	AZO COUPLING REACTION
URINE KETONES (RANDOM)	NEGATIVE		NEGATIVE	SODIUM NITRO PRUSSIDE
UROBILINOGEN	NORMAL		NORMAL	MODIFIED EHRlich REACTION
BLOOD	NEGATIVE		NEGATIVE	Peroxidase
NITRITE	NEGATIVE		NEGATIVE	Diazotization
LEUCOCYTE ESTERASE	NEGATIVE		NEGATIVE	LEUCOCYTE ESTERASE

CENTRIFUGED SEDIMENT WET MOUNT AND MICROSCOPY

PUS CELLS	3-4	/hpf	0-5	Microscopy
EPITHELIAL CELLS	2-3	/hpf	<10	MICROSCOPY
RBC	NIL	/hpf	0-2	MICROSCOPY
CASTS	NIL		0-2 Hyaline Cast	MICROSCOPY
CRYSTALS	ABSENT		ABSENT	MICROSCOPY

Result Rechecked



SIN No:UR2233868

NABL renewal accreditation under process

THIS TEST HAS BEEN PERFORMED AT APOLLO HEALTH AND LIFESTYLE LIMITED- RRL BANGALORE

Apollo Health and Lifestyle Limited (CIN - U85110TG2000PLC115819)
 Regd. Office: 1-10-60/62, Ashoka Raghupathi Chambers, 5th Floor, Begumpet, Hyderabad, Telangana - 500 016 |
 www.apollohl.com | Email ID: enquiry@apollohl.com, Ph No: 040-4904 7777, Fax No: 4904 7744

APOLLO CLINICS NETWORK

Telangana: Hyderabad (AS Rao Nagar | Chanda Nagar | Kondapur | Nallakunta | Nizampet | Manikonda | Uppal) Andhra Pradesh: Vizag (Seethamma Peta) Karnataka: Bangalore (Basavanagudi | Bellandur | Electronics City | Fraser Town | HSR Layout | Indira Nagar | JP Nagar | Kundalahalli | Koramangala | Sarjapur Road) Mysore (VV Mohalla) Tamilnadu: Chennai (Annanagar | Kotturpuram | Mogappair | T Nagar | Valasaravakkam | Velachery) Maharashtra: Pune (Aundh | Nigdi Pradhikaran | Viman Nagar | Wanowrie) Uttar Pradesh: Ghaziabad (Indrapuram) Gujarat: Ahmedabad (Satellite) Punjab: Amritsar (Court Road) Haryana: Faridabad (Railway Station Road)

Address:
 323/100/123, Doddathangur Village, Neeladri Main Road,
 Neeladri Nagar, Electronic city, Bengaluru,
 Karnataka- 560034

 **1860 500 7788**
 www.apolloclinic.com

Patient Name : Mr.S SHIVA KUMAR	Collected : 04/Dec/2023 12:42PM
Age/Gender : 51 Y 7 M 19 D/M	Received : 08/Dec/2023 05:16PM
UHID/MR No : CKOR.0000248455	Reported : 08/Dec/2023 07:26PM
Visit ID : CKOROPV390252	Status : Final Report
Ref Doctor : Dr.SELF	Sponsor Name : ARCOFEMI HEALTHCARE LIMITED
Emp/Auth/TPA ID : BOBE51827	

DEPARTMENT OF CLINICAL PATHOLOGY

ARCOFEMI - MEDIWHEEL - FULL BODY ANNUAL PLUS ABOVE 50Y MALE - 2D ECHO - PAN INDIA - FY2324

Test Name	Result	Unit	Bio. Ref. Range	Method
URINE GLUCOSE(POST PRANDIAL)	POSITIVE (++)		NEGATIVE	Dipstick



SIN No:UPP015928

NABL renewal accreditation under process

THIS TEST HAS BEEN PERFORMED AT APOLLO HEALTH AND LIFESTYLE LIMITED- RRL BANGALORE

Apollo Health and Lifestyle Limited (CIN - U85110TG2000PLC115819)
 Regd. Office: 1-10-60/62, Ashoka Raghupathi Chambers, 5th Floor, Begumpet, Hyderabad, Telangana - 500 016 |
 www.apollohl.com | Email ID: enquiry@apollohl.com, Ph No: 040-4904 7777, Fax No: 4904 7744

APOLLO CLINICS NETWORK

Telangana: Hyderabad (AS Rao Nagar | Chanda Nagar | Kondapur | Nallakunta | Nizampet | Manikonda | Uppal) | **Andhra Pradesh:** Vizag (Seethamma Peta) | **Karnataka:** Bangalore (Basavanagudi | Bellandur | Electronics City | Fraser Town | HSR Layout | Indira Nagar | JP Nagar | Kundalahalli | Koramangala | Sarjapur Road) | **Mysore** (VV Mohalla) | **Tamilnadu:** Chennai (Annanagar | Kotturpuram | Mogappair | T Nagar | Valasaravakkam | Velachery) | **Maharashtra:** Pune (Aundh | Nigdi Pradhikaran | Viman Nagar | Wanowrie) | **Uttar Pradesh:** Ghaziabad (Indrapuram) | **Gujarat:** Ahmedabad (Satellite) | **Punjab:** Amritsar (Court Road) | **Haryana:** Faridabad (Railway Station Road)

Address:
 323/100/123, Doddathangur Village, Neeladri Main Road,
 Neeladri Nagar, Electronic city, Bengaluru,
 Karnataka- 560034

 **1860 500 7788**
 www.apolloclinic.com

Patient Name : Mr.S SHIVA KUMAR	Collected : 04/Dec/2023 09:54AM
Age/Gender : 51 Y 7 M 19 D/M	Received : 04/Dec/2023 12:09PM
UHID/MR No : CKOR.0000248455	Reported : 04/Dec/2023 06:07PM
Visit ID : CKOROPV390252	Status : Final Report
Ref Doctor : Dr.SELF	Sponsor Name : ARCOFEMI HEALTHCARE LIMITED
Emp/Auth/TPA ID : BOBE51827	

DEPARTMENT OF CLINICAL PATHOLOGY

ARCOFEMI - MEDIWHEEL - FULL BODY ANNUAL PLUS ABOVE 50Y MALE - 2D ECHO - PAN INDIA - FY2324

Test Name	Result	Unit	Bio. Ref. Range	Method
URINE GLUCOSE(FASTING)	NEGATIVE		NEGATIVE	Dipstick

*** End Of Report ***


Result/s to Follow:
PERIPHERAL SMEAR



DR.SHIVARAJA SHETTY
M.B.B.S,M.D(Biochemistry)
CONSULTANT BIOCHEMIST



Dr.Shobha Emmanuel
M.B.B.S,M.D(Pathology)
Consultant Pathologist



Dr. Chinki Anupam
M.B.B.S,M.D(Pathology)
Consultant Pathologist

Patient Name : Mr. S SHIVA KUMAR

Age/Gender : 51 Y/M

UHID/MR No. : CKOR.0000248455

OP Visit No : CKOROPV390252

Sample Collected on :

Reported on : 04-12-2023 11:41

LRN# : RAD2168357

Specimen :

Ref Doctor : SELF

Emp/Auth/TPA ID : BOBE51827

DEPARTMENT OF RADIOLOGY

X-RAY CHEST PA

Both lungs fields appear normal.

Both hila are normal.

Both costophrenic and cardiophrenic angles are normal.

The cardiac and mediastinal shadows appear normal.

Bones and soft tissues appear normal.

IMPRESSION : NORMAL STUDY.

DR VINOD JOSEPH DNB,DMRD
RADIOLOGIST

Patient Name : Mr. S SHIVA KUMAR

Age/Gender : 51 Y/M

UHID/MR No. : CKOR.0000248455

OP Visit No : CKOROPV390252

Sample Collected on :

Reported on : 04-12-2023 12:15

LRN# : RAD2168357

Specimen :

Ref Doctor : SELF

Emp/Auth/TPA ID : BOBE51827

DEPARTMENT OF RADIOLOGY

ULTRASOUND - WHOLE ABDOMEN

Liver is normal in size and shows increased echotexture. No biliary dilatation. No focal lesion
CBD is not dilated. **Portal vein** is normal in size, course and calibre.

Gall bladder is normal without evidence of calculi, wall thickening or pericholecystic fluid.

Pancreas to the extent visualized, appears normal in size, contour and echogenicity

Spleen is normal in size, shape, contour and echopattern. No evidence of mass or focal lesions.

Right Kidney is normal in size, position, shape and echopattern. Corticomedullary differentiation is maintained. No evidence of calculi or hydronephrosis.

Left Kidney is normal in size, position, shape and echopattern. Corticomedullary differentiation is maintained. No evidence of calculi or hydronephrosis.

Urinary Bladder is well distended. Wall thickness is normal. No evidence of calculi, mass or mural lesion.

Prostate: normal in size and echotexture.

There is no ascites.

IMPRESSION: GRADE-I FATTY LIVER

DR VINOD JOSEPH DNB,DMRD
RADIOLOGIST

Name : Mr. S SHIVA KUMAR

Age: 51 Y

UHID:CKOR.0000248455

Sex: M



Address : kmg

OP Number:CKOROPV390252

 Plan : ARCOFEMI MEDIWHEEL MALE AHC CREDIT PAN
 INDIA OP AGREEMENT

Bill No :CKOR-OCR-79338

Date : 04.12.2023 09:51

Sno	Service Type/ServiceName	Department
1	ARCOFEMI - MEDIWHEEL - FULL BODY ANNUAL PLUS ABOVE 50Y MALE - 2D ECHO - PAN INDIA - FY2324	
1	URINE GLUCOSE(FASTING)	
2	GAMMA GLUTAMYL TRANSFERASE (GGT)	
3	PROSTATIC SPECIFIC ANTIGEN (PSA TOTAL)	
4	HbA1c, GLYCATED HEMOGLOBIN	
5	2 D ECHO → (10)	
6	LIVER FUNCTION TEST (LFT)	
7	X-RAY CHEST PA → (11)	
8	GLUCOSE, FASTING	
9	HEMOGRAM + PERIPHERAL SMEAR	
10	ENT CONSULTATION	(11) (23) Dr. Vijay
11	FITNESS BY GENERAL PHYSICIAN	
12	DIET CONSULTATION	
13	COMPLETE URINE EXAMINATION	
14	URINE GLUCOSE(POST PRANDIAL)	
15	PERIPHERAL SMEAR	
16	ECG	
17	BLOOD GROUP ABO AND RH FACTOR	
18	LIPID PROFILE	
19	BODY MASS INDEX (BMI)	
20	OPHTHAL BY GENERAL PHYSICIAN	opp Rm (11)
21	RENAL PROFILE/RENAL FUNCTION TEST (RFT/KFT)	
22	ULTRASOUND - WHOLE ABDOMEN → (17)	
23	THYROID PROFILE (TOTAL T3, TOTAL T4, TSH)	
24	DENTAL CONSULTATION	
25	GLUCOSE, POST PRANDIAL (PP), 2 HOURS (POST MEAL)	

26 physio - (11)

wt 77 kg

ht 158 cm

NAME: MR. S SHIVAKUMAR

AGE: 51Y

SEX: MALE

DATE: 04/12/2023

ECHOCARDIOGRAPHY REPORT

MEASUREMENT

AO -23(20 – 35)mm	LIVD d – 38(36-52)mm	IVS - 10 (06 - 11)mm
LA -27(19- 40)mm	LVID s – 26(23- 39)mm	PWD – 10(06- 11)mm
EF - 60% (>50%)	RVID-22	

VALVES

Mitral Valve : Normal
Aortic Valve : Normal
Tricuspid Valve : Normal
Pulmonary Valve : Normal

CHAMBERS

Left Atrium : Normal
Right Atrium : Normal
Left Ventricle : Normal
Right Ventricle : Normal

SEPTAE

IVS : Intact
IAS : Intact

GREAT ARTERIES

Aorta : Normal
Pulmonary Artery : Normal

DOPPLER DATA

Mitral : E > A
Aortic : Normal
Tricuspid : TRIVIAL TR
Pulmonary : Normal

WALL MOTION ABNORMALITIES : No RWMA

Pericardium : Normal

FINAL DIAGNOSIS

**NORMAL CHAMBERS AND VALVES
NORMAL BIVENTRICULAR FUNCTION
NO RWMA AT REST, LV EF -60%**



**DR. MOHAN MURALI
CONSULTANT
CARDIOLOGIST**

Patient Name : Mr. S SHIVA KUMAR
UHID : CKOR.0000248455
Reported on : 04-12-2023 11:41
Adm/Consult Doctor :

Age : 51 Y M
OP Visit No : CKOROPV390252
Printed on : 04-12-2023 11:45
Ref Doctor : SELF

DEPARTMENT OF RADIOLOGY

X-RAY CHEST PA

Both lungs fields appear normal.

Both hila are normal.

Both costophrenic and cardiophrenic angles are normal.

The cardiac and mediastinal shadows appear normal.

Bones and soft tissues appear normal.

IMPRESSION : NORMAL STUDY.


For **DR VINOD JOSEPH DNB,DMRD**
RADIOLOGIST

Printed on:04-12-2023 11:41

---End of the Report---



Apollo Clinic

Consent Form

Patient Name: SHIVA KUMAR Age: 51 yrs

UHID Number: Company Name:

I Mr/Mrs/Miss: Employee of

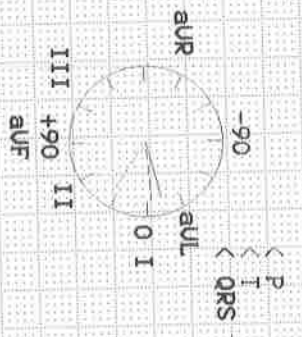
(Company) want to inform you that I am not getting the
Test which is a part of health check package.

Reason If any: Consultation will be on this week

And I claim the above statement in my full consciousness

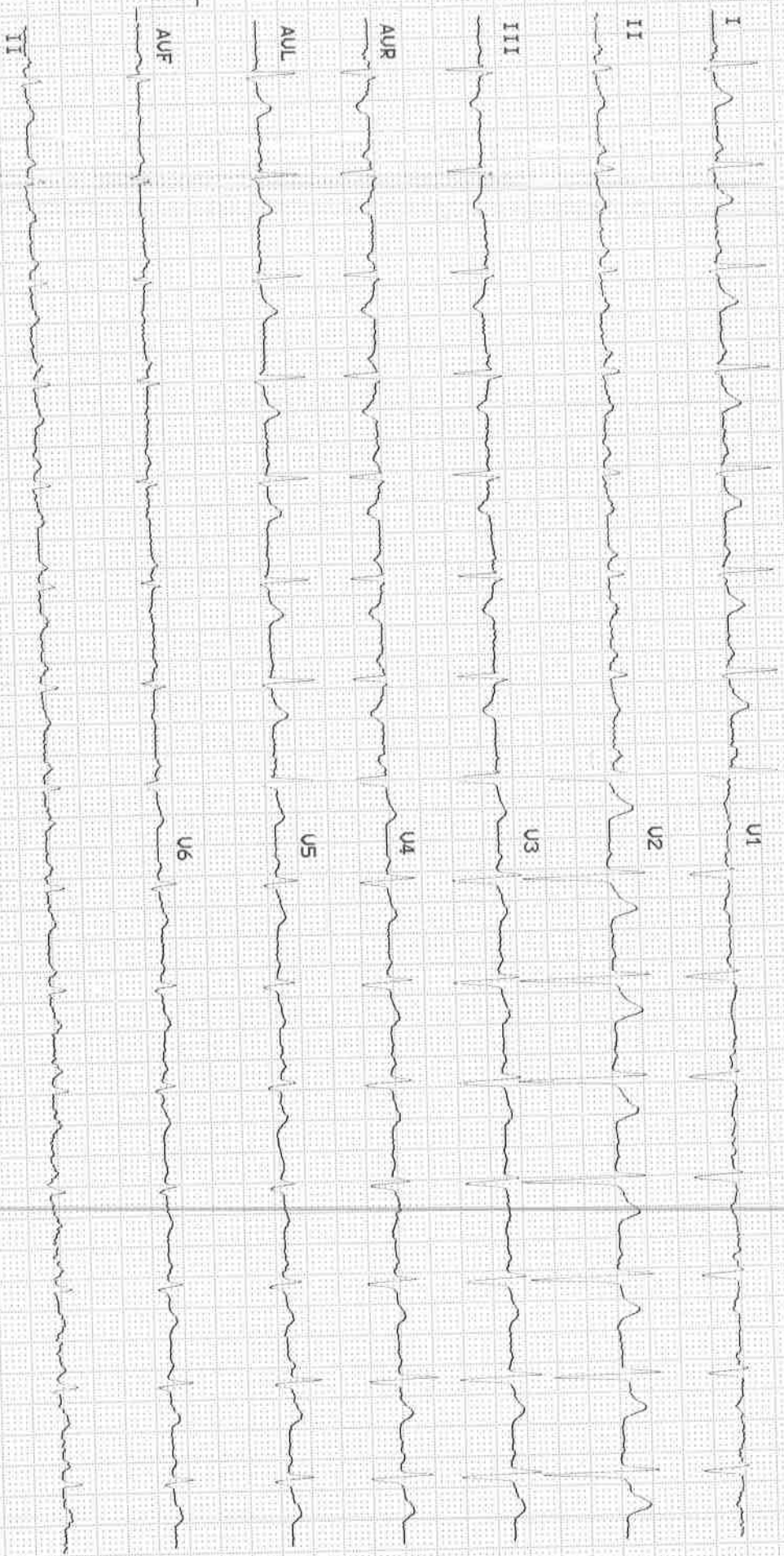
Patient Signature: Date:

AGE: 51
 Measurement Results:
 PRS : 102 ms
 QT/QTcB : 350 / 432 ms
 PR : 128 ms
 P : 102 ms
 RR/PP : 656 / 650 ms
 P/ORS/T : 35 / -15 / -5 degrees
 QTd/QTcBd : 24 / 30 ms
 Sokolow : 0.9 mV
 NK : 13



SRV

Unconfirmed report.



Patient Name	: Mr. S SHIVA KUMAR	Age	: 51 Y/M
UHID	: CKOR.0000248455	OP Visit No	: CKOROPV390252
Reported By:	: Dr. MOHAN MURALI	Conducted Date	: 04-12-2023 13:05
Referred By	: SELF		

ECG REPORT

Observation :-

1. Normal Sinus Rhythm.
2. Heart rate is 91beats per minutes.
3. No pathological Q wave or S-T,T changes seen.
4. Normal P,Q,R,S,T waves and axis.
5. No evidence of chamber, hypertrophy or enlargement seen

Impression:

NORMAL RESTING ECG.

Dr. MOHAN MURALI
CARDIOLOGIST

NOTE : KINDLY TAKE A PHOTOCOPY OF THE GRAPH
FOR FUTURE REFERENCE IF NEEDED.

----- END OF THE REPORT -----

Patient Name : Mr S Shiva Kumar

Patient ID: 248455

Age : 51 Year(s)

Sex : Male

Referring Doctor : H/C

Date : 04.12.2023

ULTRASOUND ABDOMEN AND PELVIS

FINDINGS:

Liver is normal in size and shows increased echotexture. No biliary dilatation. No focal lesion
CBD is not dilated. **Portal vein** is normal in size, course and calibre.

Gall bladder is normal without evidence of calculi, wall thickening or pericholecystic fluid.

Pancreas to the extent visualized, appears normal in size, contour and echogenicity

Spleen is normal in size, shape, contour and echopattern. No evidence of mass or focal lesions.

Right Kidney is normal in size, position, shape and echopattern. Corticomedullary differentiation is maintained. No evidence of calculi or hydronephrosis.

Left Kidney is normal in size, position, shape and echopattern. Corticomedullary differentiation is maintained. No evidence of calculi or hydronephrosis.

Urinary Bladder is well distended. Wall thickness is normal. No evidence of calculi, mass or mural lesion.

Prostate: normal in size and echotexture.

There is no ascites.

IMPRESSION: GRADE-I FATTY LIVER

**DR VINOD JOSEPH DNB,DMRD
RADIOLOGIST**

Name : Mr. S SHIVA KUMAR

Age: 51 Y

UHID:CKOR.0000248455

Sex: M



Address : kmg

OP Number:CKOROPV390252

 Plan : ARCOFEMI MEDIWHEEL MALE AHC CREDIT PAN
 INDIA OP AGREEMENT

Bill No :CKOR-OCR-79338

Date : 04.12.2023 09:51

Sno	Service Type/ServiceName	Department
1	ARCOFEMI - MEDIWHEEL - FULL BODY ANNUAL PLUS ABOVE 50Y MALE - 2D ECHO - PAN INDIA - FY2324	
1	URINE GLUCOSE(FASTING)	
2	GAMMA GLUTAMYL TRANSFERASE (GGT)	
3	PROSTATIC SPECIFIC ANTIGEN (PSA TOTAL)	
4	HbA1c, GLYCATED HEMOGLOBIN	
5	2 D ECHO → (10)	
6	LIVER FUNCTION TEST (LFT)	
7	X-RAY CHEST PA → (11)	
8	GLUCOSE, FASTING	
9	HEMOGRAM + PERIPHERAL SMEAR	
10	ENT CONSULTATION	(11) (23) Dr. Vijay
11	FITNESS BY GENERAL PHYSICIAN	
12	DIET CONSULTATION	
13	COMPLETE URINE EXAMINATION	
14	URINE GLUCOSE(POST PRANDIAL)	
15	PERIPHERAL SMEAR	
16	ECG	
17	BLOOD GROUP ABO AND RH FACTOR	
18	LIPID PROFILE	
19	BODY MASS INDEX (BMI)	
20	OPHTHAL BY GENERAL PHYSICIAN	opp Rm (11)
21	RENAL PROFILE/RENAL FUNCTION TEST (RFT/KFT)	
22	ULTRASOUND - WHOLE ABDOMEN → (11) (17)	
23	THYROID PROFILE (TOTAL T3, TOTAL T4, TSH)	
24	DENTAL CONSULTATION	
25	GLUCOSE, POST PRANDIAL (PP), 2 HOURS (POST MEAL)	

26 physio - (11)

wt 77 kg

ht 158 cm

NAME: MR. S SHIVAKUMAR

AGE: 51Y

SEX: MALE

DATE: 04/12/2023

ECHOCARDIOGRAPHY REPORT

MEASUREMENT

AO -23(20 – 35)mm	LIVD d – 38(36-52)mm	IVS - 10 (06 - 11)mm
LA -27(19- 40)mm	LVID s – 26(23- 39)mm	PWD – 10(06- 11)mm
EF - 60% (>50%)	RVID-22	

VALVES

Mitral Valve : Normal
Aortic Valve : Normal
Tricuspid Valve : Normal
Pulmonary Valve : Normal

CHAMBERS

Left Atrium : Normal
Right Atrium : Normal
Left Ventricle : Normal
Right Ventricle : Normal

SEPTAE

IVS : Intact
IAS : Intact

GREAT ARTERIES

Aorta : Normal
Pulmonary Artery : Normal

DOPPLER DATA

Mitral : E > A
Aortic : Normal
Tricuspid : TRIVIAL TR
Pulmonary : Normal

WALL MOTION ABNORMALITIES : No RWMA

Pericardium : Normal

FINAL DIAGNOSIS

**NORMAL CHAMBERS AND VALVES
NORMAL BIVENTRICULAR FUNCTION
NO RWMA AT REST, LV EF -60%**



**DR. MOHAN MURALI
CONSULTANT
CARDIOLOGIST**

Patient Name : Mr. S SHIVA KUMAR
UHID : CKOR.0000248455
Reported on : 04-12-2023 11:41
Adm/Consult Doctor :

Age : 51 Y M
OP Visit No : CKOROPV390252
Printed on : 04-12-2023 11:45
Ref Doctor : SELF

DEPARTMENT OF RADIOLOGY

X-RAY CHEST PA

Both lungs fields appear normal.

Both hila are normal.

Both costophrenic and cardiophrenic angles are normal.

The cardiac and mediastinal shadows appear normal.

Bones and soft tissues appear normal.

IMPRESSION : NORMAL STUDY.


For **DR VINOD JOSEPH DNB,DMRD**
RADIOLOGIST

Printed on:04-12-2023 11:41

---End of the Report---



Apollo Clinic

Consent Form

Patient Name: SHIVA KUMAR Age: 51 yrs

UHID Number: Company Name:

I Mr/Mrs/Miss: Employee of

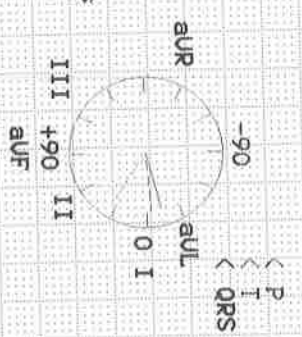
(Company) want to inform you that I am not getting the
Test which is a part of health check package.

Reason If any: Consultation will be on this week

And I claim the above statement in my full consciousness

Patient Signature: Date:

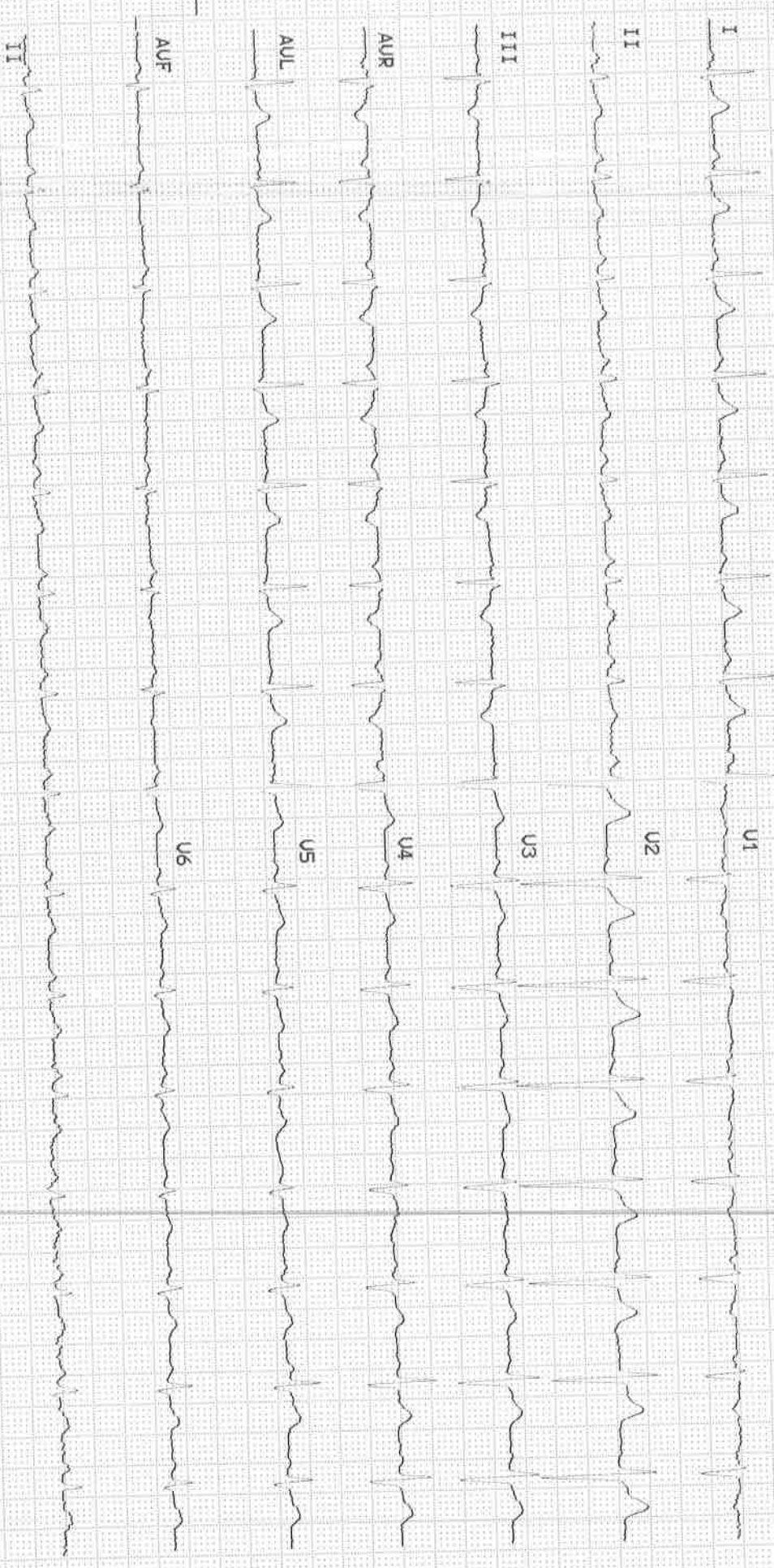
AGE: 51
 Measurement Results:
 PRS : 102 ms
 QT/QTcB : 350 / 432 ms
 PR : 128 ms
 P : 102 ms
 RR/PP : 656 / 650 ms
 P/ORS/T : 35 / -15 / -5 degrees
 QTd/QTcBd : 24 / 30 ms
 Sokolow : 0.9 mV
 NK : 13



Interpretation:

SRV

Unconfirmed report.



Patient Name	: Mr. S SHIVA KUMAR	Age	: 51 Y/M
UHID	: CKOR.0000248455	OP Visit No	: CKOROPV390252
Reported By:	: Dr. MOHAN MURALI	Conducted Date	: 04-12-2023 13:05
Referred By	: SELF		

ECG REPORT

Observation :-

1. Normal Sinus Rhythm.
2. Heart rate is 91beats per minutes.
3. No pathological Q wave or S-T,T changes seen.
4. Normal P,Q,R,S,T waves and axis.
5. No evidence of chamber, hypertrophy or enlargement seen

Impression:

NORMAL RESTING ECG.

Dr. MOHAN MURALI
CARDIOLOGIST

NOTE : KINDLY TAKE A PHOTOCOPY OF THE GRAPH
FOR FUTURE REFERENCE IF NEEDED.

----- END OF THE REPORT -----

Patient Name : Mr S Shiva Kumar

Patient ID: 248455

Age : 51 Year(s)

Sex : Male

Referring Doctor : H/C

Date : 04.12.2023

ULTRASOUND ABDOMEN AND PELVIS

FINDINGS:

Liver is normal in size and shows increased echotexture. No biliary dilatation. No focal lesion
CBD is not dilated. **Portal vein** is normal in size, course and calibre.

Gall bladder is normal without evidence of calculi, wall thickening or pericholecystic fluid.

Pancreas to the extent visualized, appears normal in size, contour and echogenicity

Spleen is normal in size, shape, contour and echopattern. No evidence of mass or focal lesions.

Right Kidney is normal in size, position, shape and echopattern. Corticomedullary differentiation is maintained. No evidence of calculi or hydronephrosis.

Left Kidney is normal in size, position, shape and echopattern. Corticomedullary differentiation is maintained. No evidence of calculi or hydronephrosis.


Urinary Bladder is well distended. Wall thickness is normal. No evidence of calculi, mass or mural lesion.

Prostate: normal in size and echotexture.

There is no ascites.

IMPRESSION: GRADE-I FATTY LIVER

DR VINOD JOSEPH DNB,DMRD
RADIOLOGIST

Name : Mr. S SHIVA KUMAR	Age : 51 Y	UHID :CKOR.0000248455
	Sex : M	
Address : kmg		OP Number :CKOROPV390252
Plan : ARCOFEMI MEDIWHEEL MALE AHC CREDIT PAN INDIA OP AGREEMENT		Bill No :CKOR-OCR-79338
		Date : 04.12.2023 09:51

Sno	Service Type/ServiceName	Department
1	ARCOFEMI - MEDIWHEEL - FULL BODY ANNUAL PLUS ABOVE 50Y MALE - 2D ECHO - PAN INDIA - FY2324	
1	URINE GLUCOSE(FASTING)	
2	GAMMA GLUTAMYL TRANSFERASE (GGT)	
3	PROSTATIC SPECIFIC ANTIGEN (PSA TOTAL)	
4	HbA1c, GLYCATED HEMOGLOBIN	
5	2 D ECHO → (10)	
6	LIVER FUNCTION TEST (LFT)	
7	X-RAY CHEST PA → (11)	
8	GLUCOSE, FASTING	
9	HEMOGRAM + PERIPHERAL SMEAR	
10	ENT CONSULTATION	11 (23) Dr. Nijar
11	FITNESS BY GENERAL PHYSICIAN	
12	DIET CONSULTATION	
13	COMPLETE URINE EXAMINATION	
14	URINE GLUCOSE(POST PRANDIAL)	
15	PERIPHERAL SMEAR	
16	ECG	
17	BLOOD GROUP ABO AND RH FACTOR	
18	LIPID PROFILE	
19	BODY MASS INDEX (BMI)	
20	OPHTHAL BY GENERAL PHYSICIAN	opp Rm (1)
21	RENAL PROFILE/RENAL FUNCTION TEST (RFT/KFT)	
22	ULTRASOUND - WHOLE ABDOMEN → (17)	
23	THYROID PROFILE (TOTAL T3, TOTAL T4, TSH)	
24	DENTAL CONSULTATION	
25	GLUCOSE, POST PRANDIAL (PP), 2 HOURS (POST MEAL)	

26 physio - (10)

wt 77 kg
 ht 158 cm



DR VIJAYA LAKSHMI M
M.B.B.S, D.L.O, D.N.B(ENT)
Phone No.9972044580,080-25633823/24/23



Apollo Medical
Centre
Expertise. Closer to you

HEALTH CHECK- ENT

NAME: *S. Shiv Kumar* **P** **AGE:** *51*

EAR: **RE:** **LE:**

EXTERNAL EAR

MIDDLE EAR

INNER EAR (FN)

Normal

HEARING ASSESSMENT: **RE:** **LE:**

RHINNE

WEBER

ABC

Normal

NOSE

THROAT

AIRWAY

ORAL CAVITY

SEPTUM

OROPHARYNX

TURBINATES

PHARYNX

OTHERS

LARYNX

Normal

NECK

NECK NODES

OTHER

Normal

AUDIOMETRY

IMPRESSION

Normal

[Signature]

SIGNATURE:

Apollo Health and Lifestyle Limited

(CIN - U85110TG2000PLC046089) Regd. Office: #7-1-617/A, 615 & 616, Imperial Towers, 7th Floor ; Ameerpet, Hyderabad, Telangana - 500 038 | Email ID: enquiry@apollohl.com

APOLLO CLINICS NETWORK KARNATAKA

Bangalore (Basavanagudi | Bellandur | Electronics City | HSR Layout | Indira Nagar | JP Nagar | Kundalahalli | Koramangala | Sarjapur Road) **Mysore** (Kalladasa Road)

Online appointments: www.apolloclinic.com

TO BOOK AN APPOINTMENT

1860 500 7788